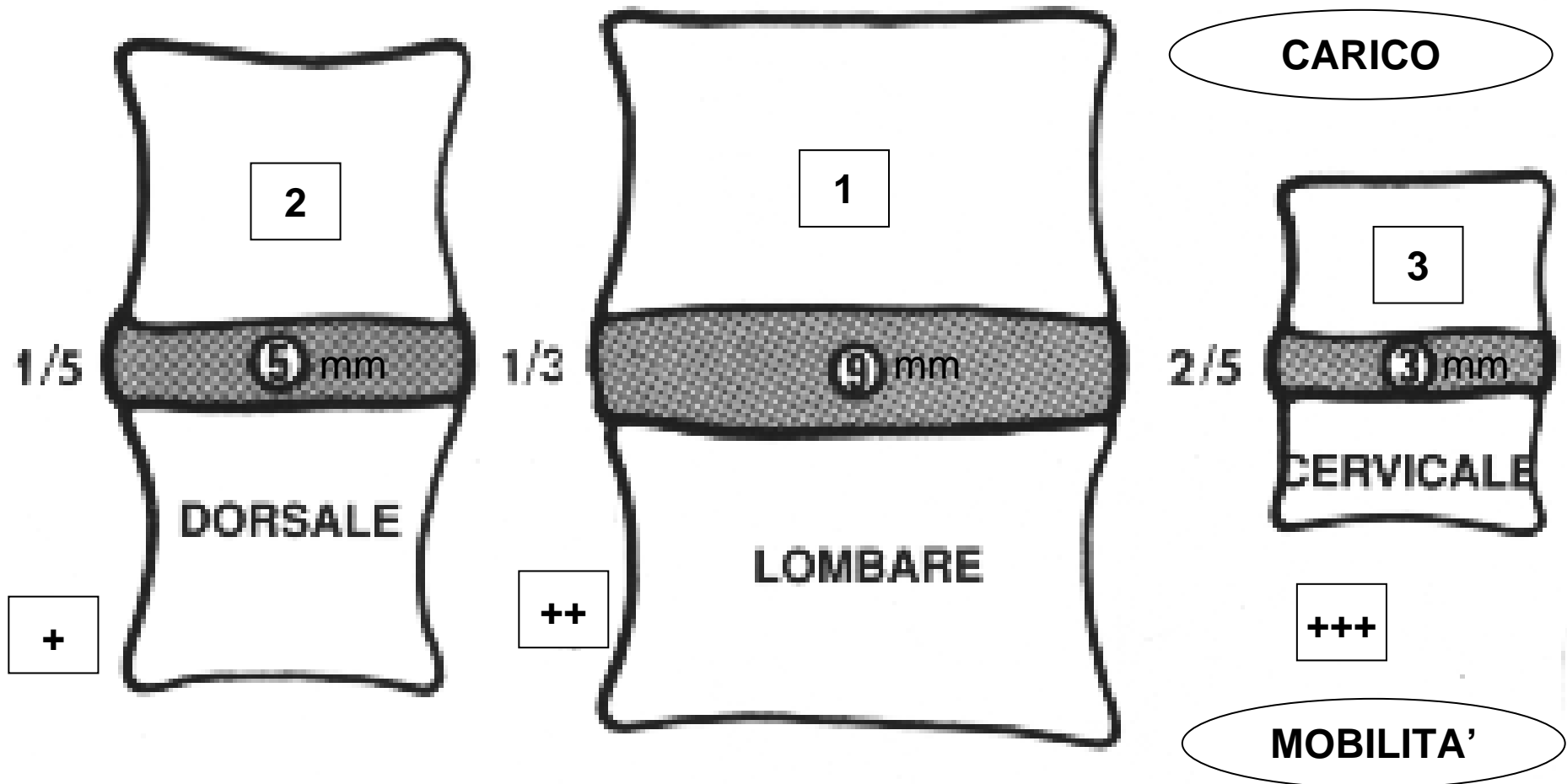


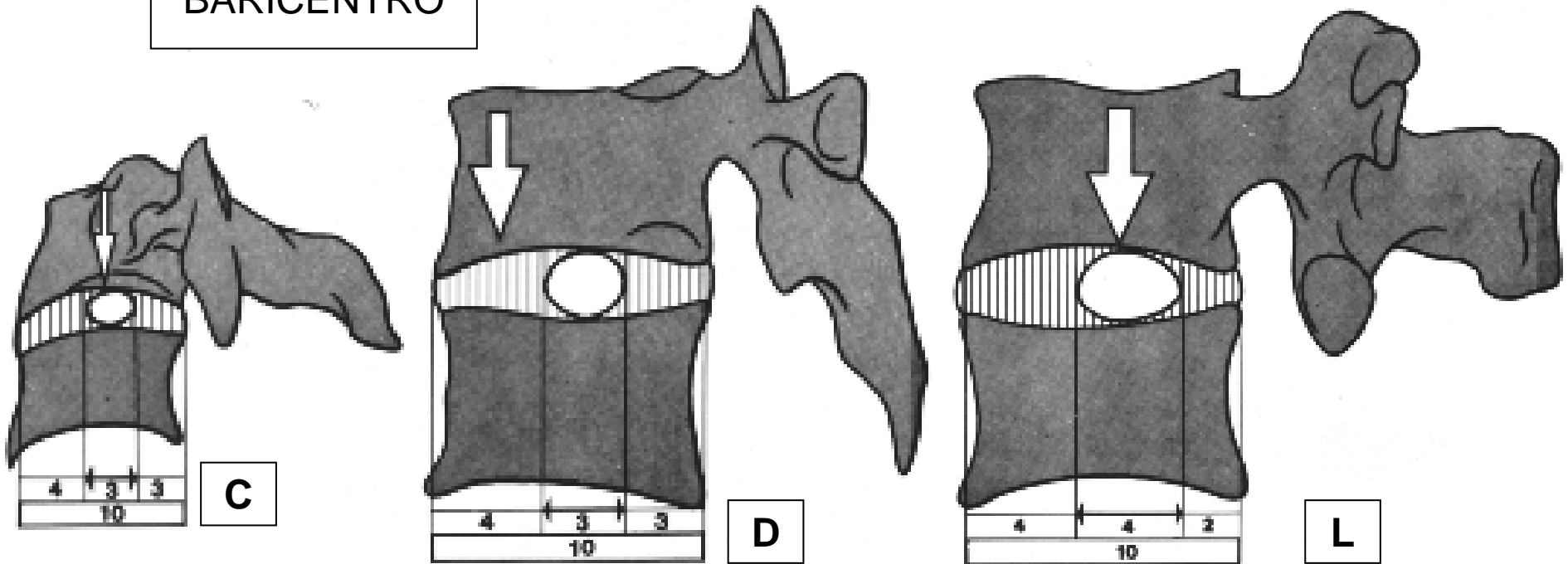
SPESSORE ASSOLUTO DEL DIV



RAPPORTO D.I.V./CORPO VERTEBRALE

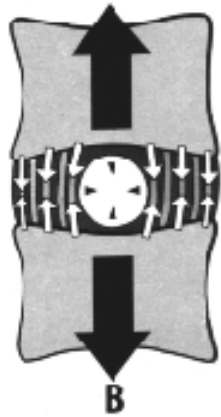POSIZIONI DEL N.P.

BARICENTRO

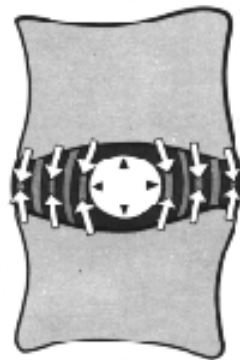


MASSIMA RESISTENZA
AGLI SFORZI ASSIALI

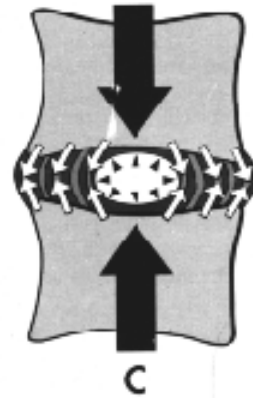
ELONGAZIONE ASSIALE
TRAZIONE VERTEBRALE



BARRA PRECOMPRESSA

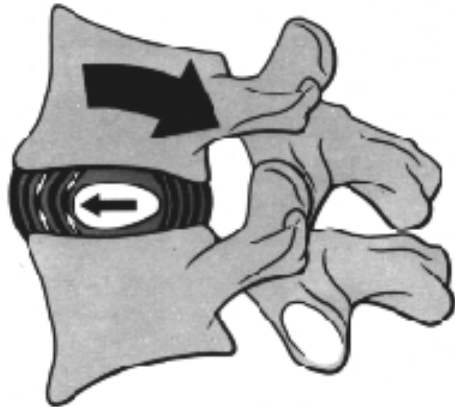


45

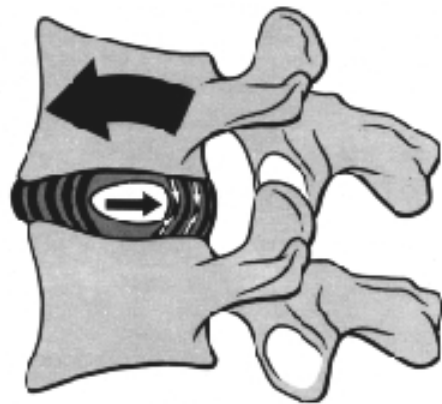

COMPRESSIONE ASSIALE

ESTENSIONE



46

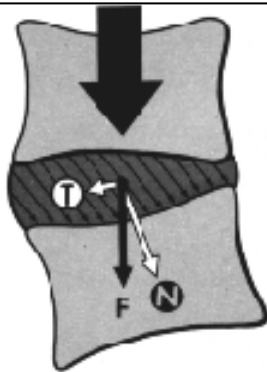
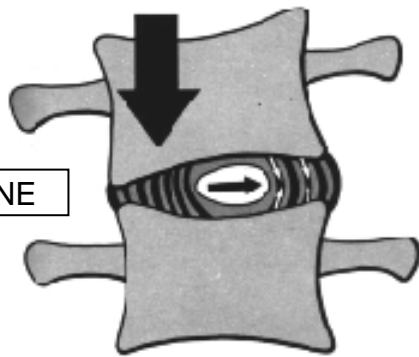


47

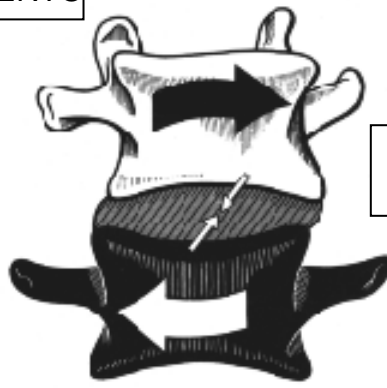
FLESSIONE

VERTEBRA INCLINATA=SCIVOLAMENTO

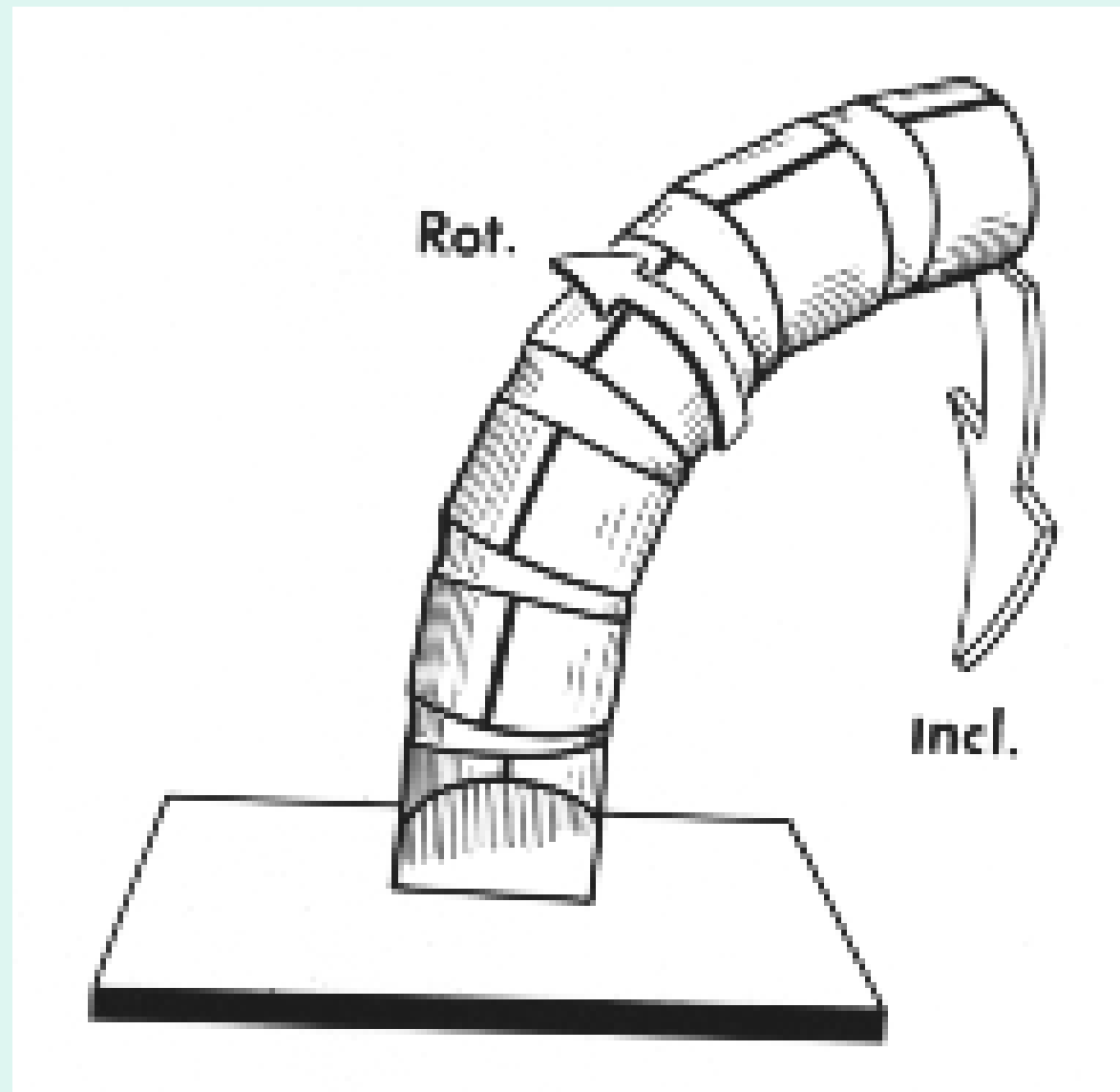
INCLINAZIONE



ROTAZIONE ASSIALE



ROTAZIONE AUTOMATICA DEL RACHIDE DURANTE L'INFLESSIONE LATERALE





LINEA DELLE SPINOSE

IL PROCESSO TRASVERSO
DEL LATO CONVESSO
APPARE RIMPICCIOLITO

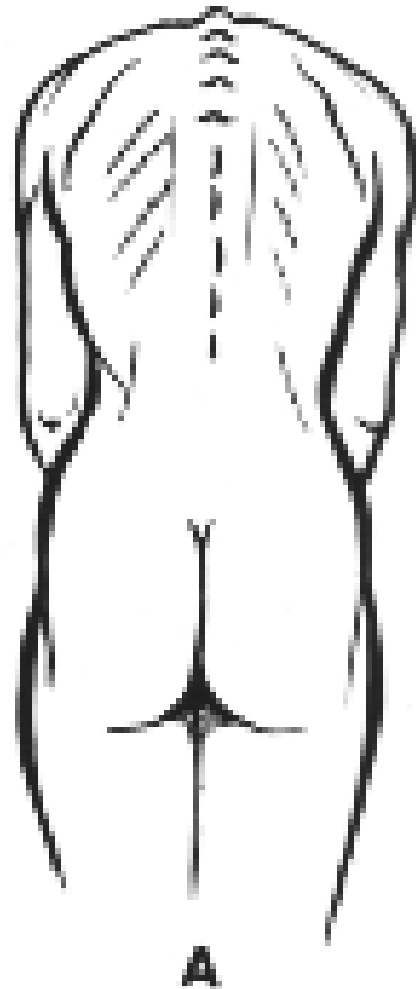IL PROCESSO TRASVERSO
DEL LATO CONCAVO
E' IN GRANDEZZA REALE

1) SPOSTAMENTO
DEL D.I.V.

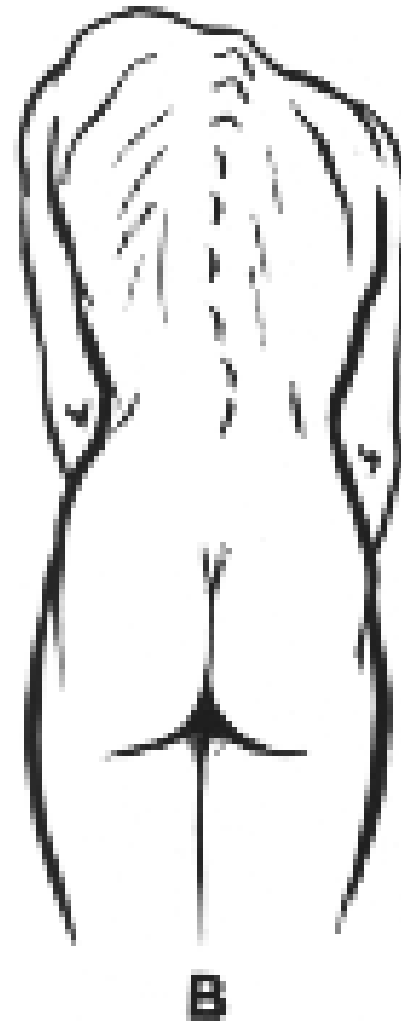2) INESTENSIBILITA'
DEI LEGAMENTI

SCOLIOSI= FISSAZIONE DELLA ROTAZIONE IN FLESSIONE

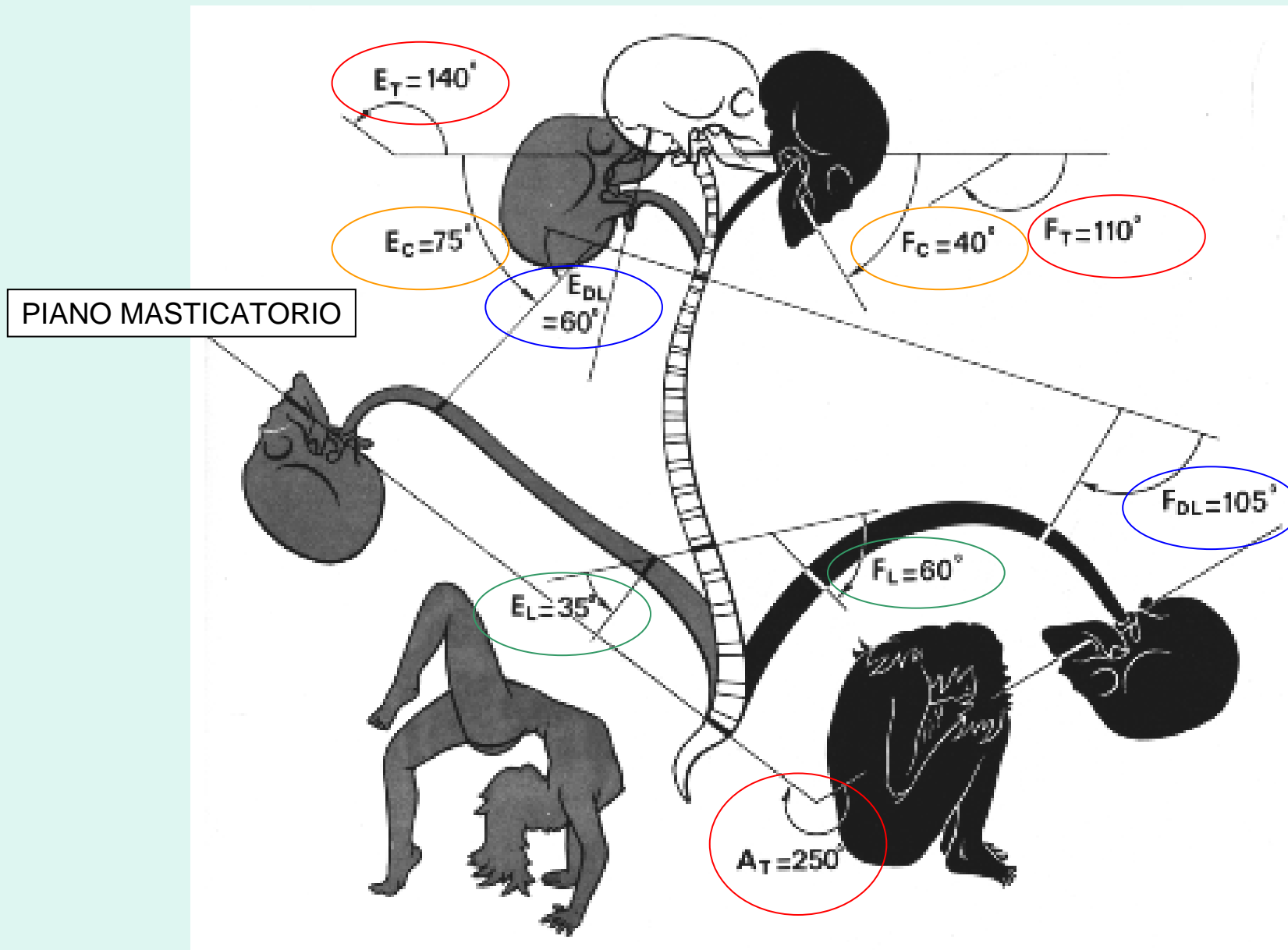
PROFILO
DORSALE
SIMMETRICO



SPORGENZA
DAL LATO
DELLA CONVESSITA'
DELLA CURVA



FLESSO-ESTENSIONE RACHIDEA



VALUTAZIONE PRATICA

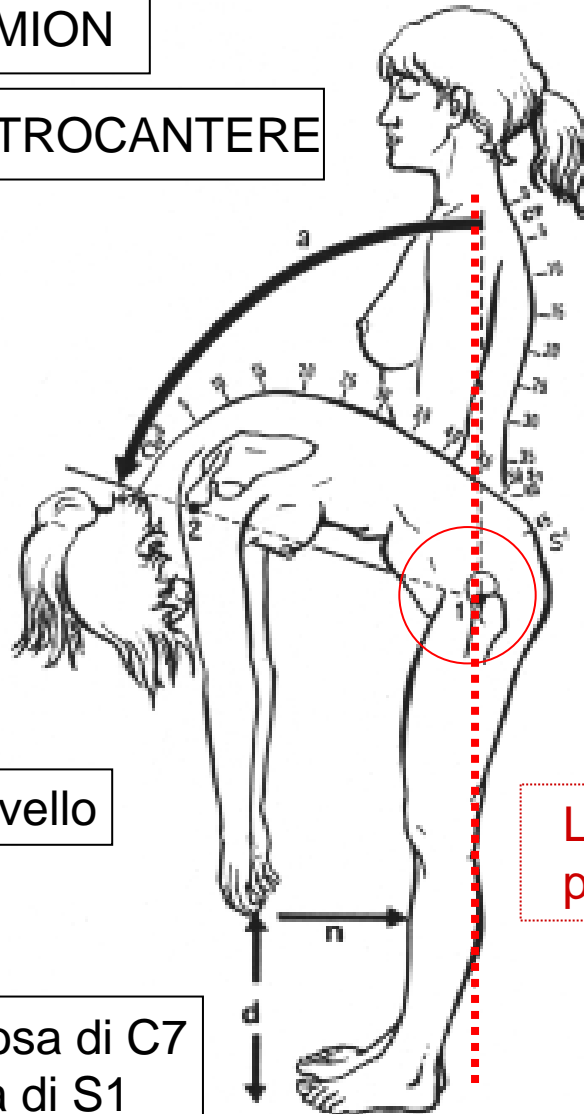
APICE ACROMION

GRANDE TROCANTERE

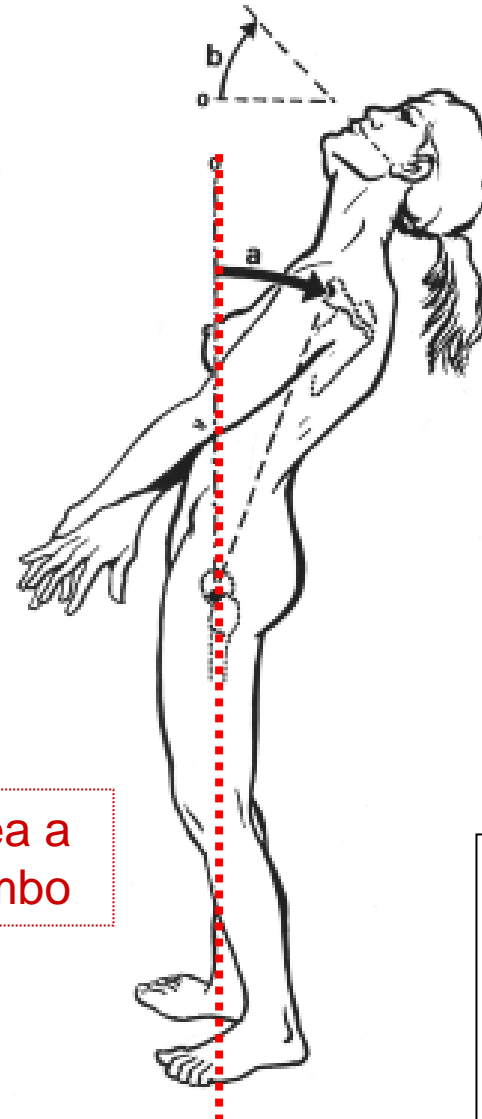
F 105°

Distanze / Livello

Cm tra la Spinosa di C7
E la Spinosa di S1



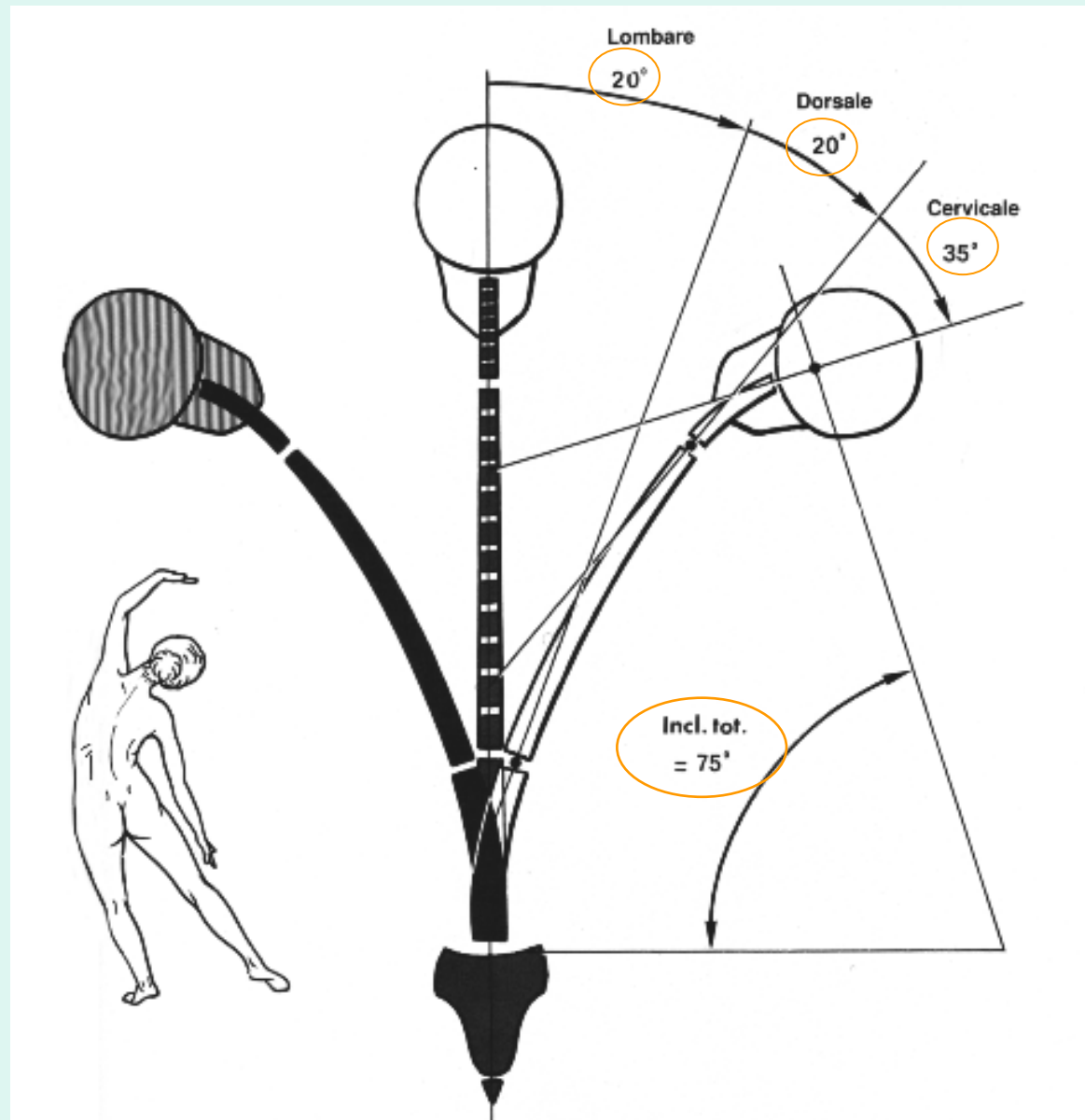
Linea a
piombo



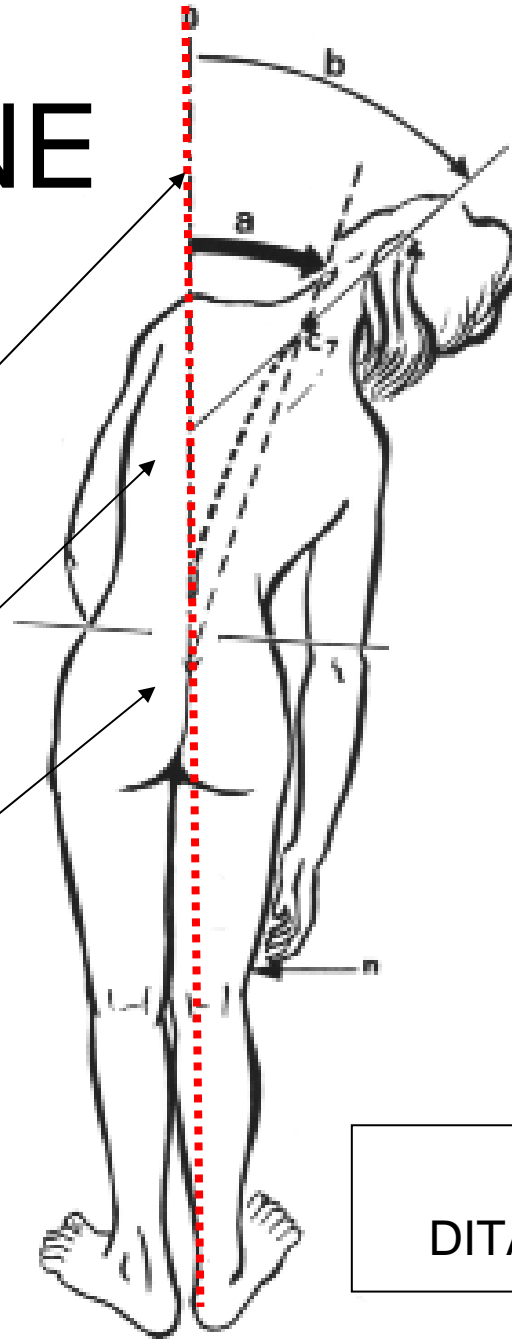
E 60°

OPPURE
Est.Tot. MENO
ESTENSIONE
CERVICALE

INFLESSIONE LATERALE



INCLINAZIONE



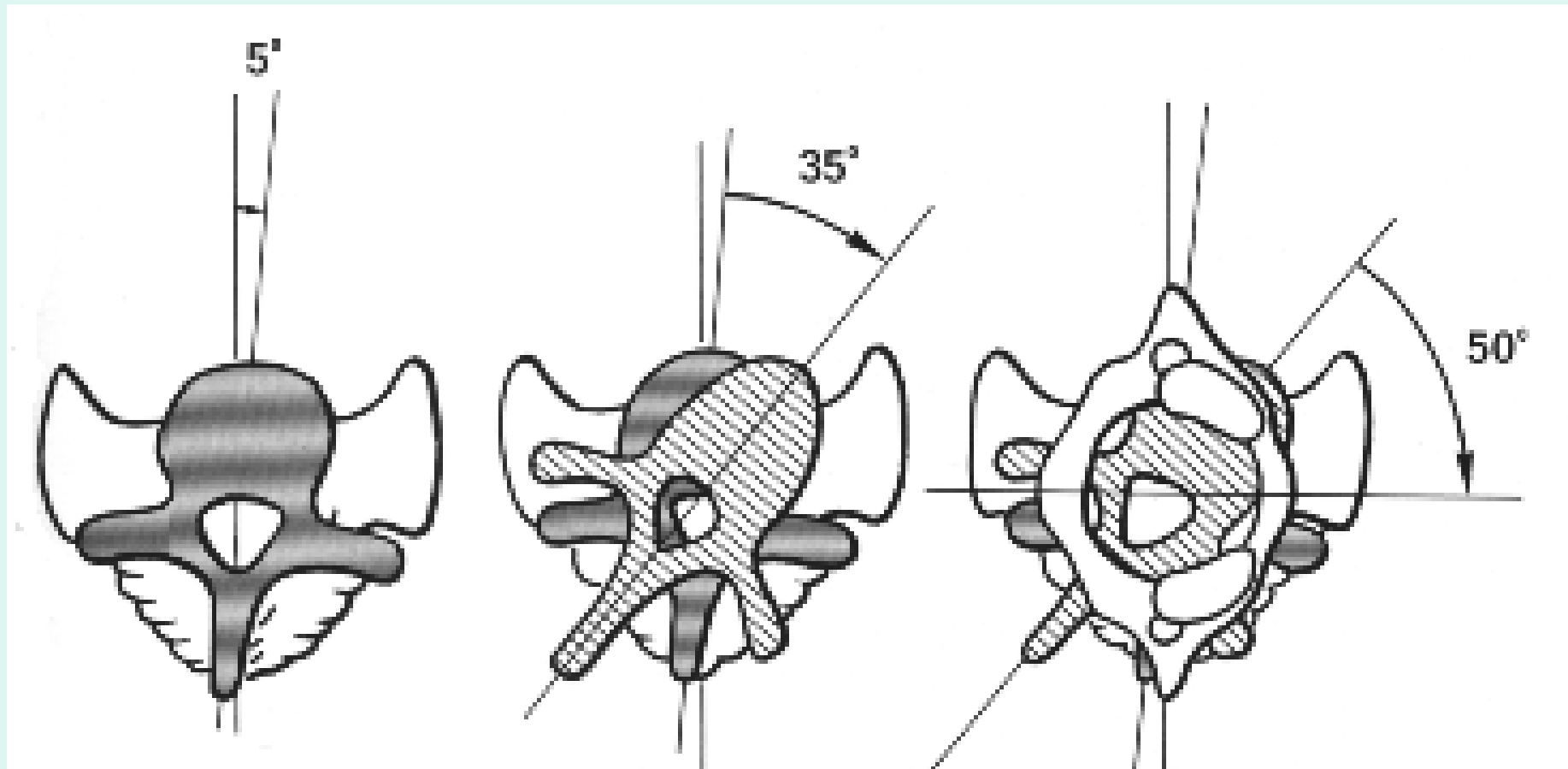
APPIOMBO

APOFISI SPINOSA DI C7

APICE SOLCO INTERGLUTEO

LIVELLO "N"
DITA / ARTO INFERIORE

ROTAZIONE

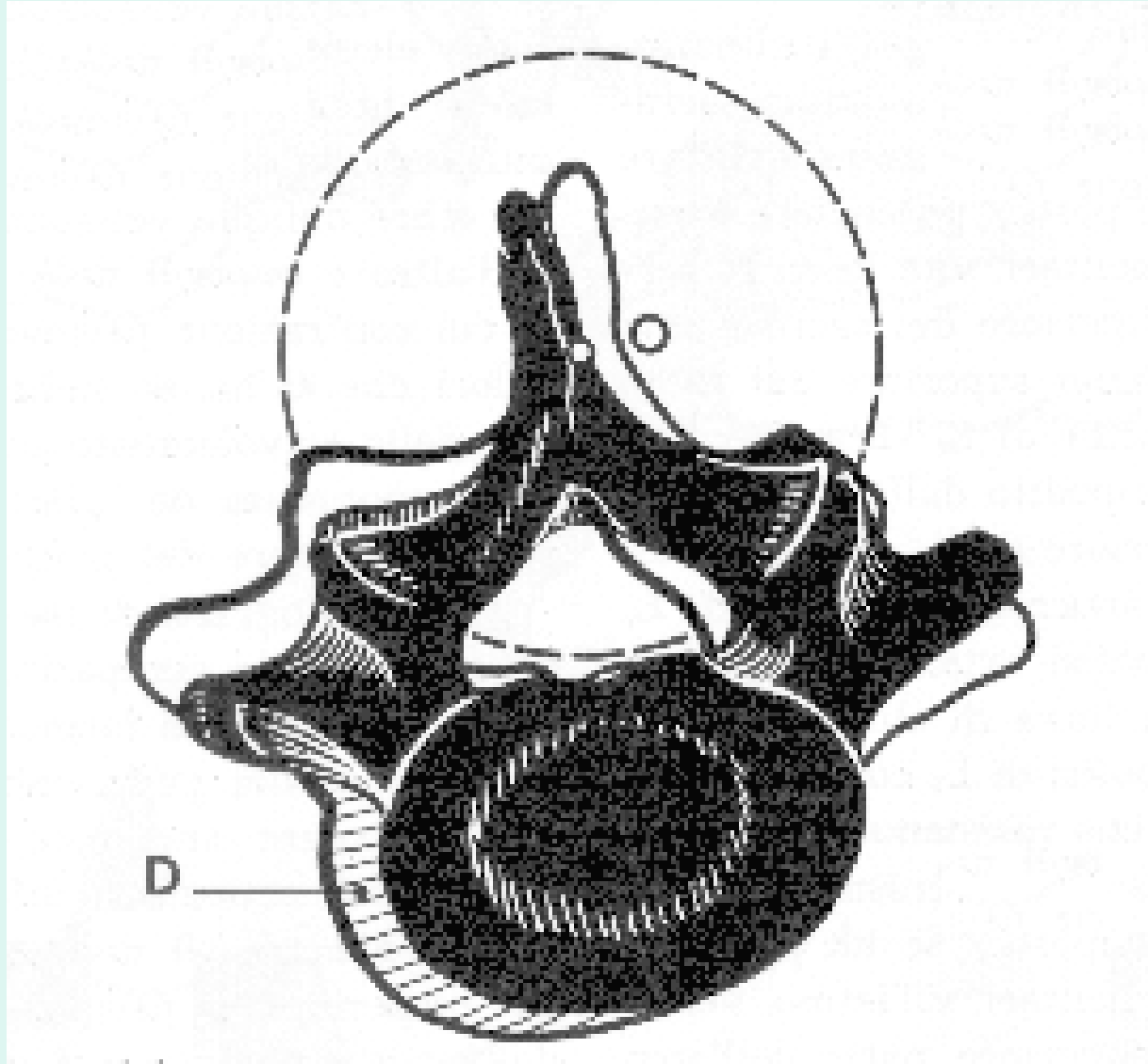


L

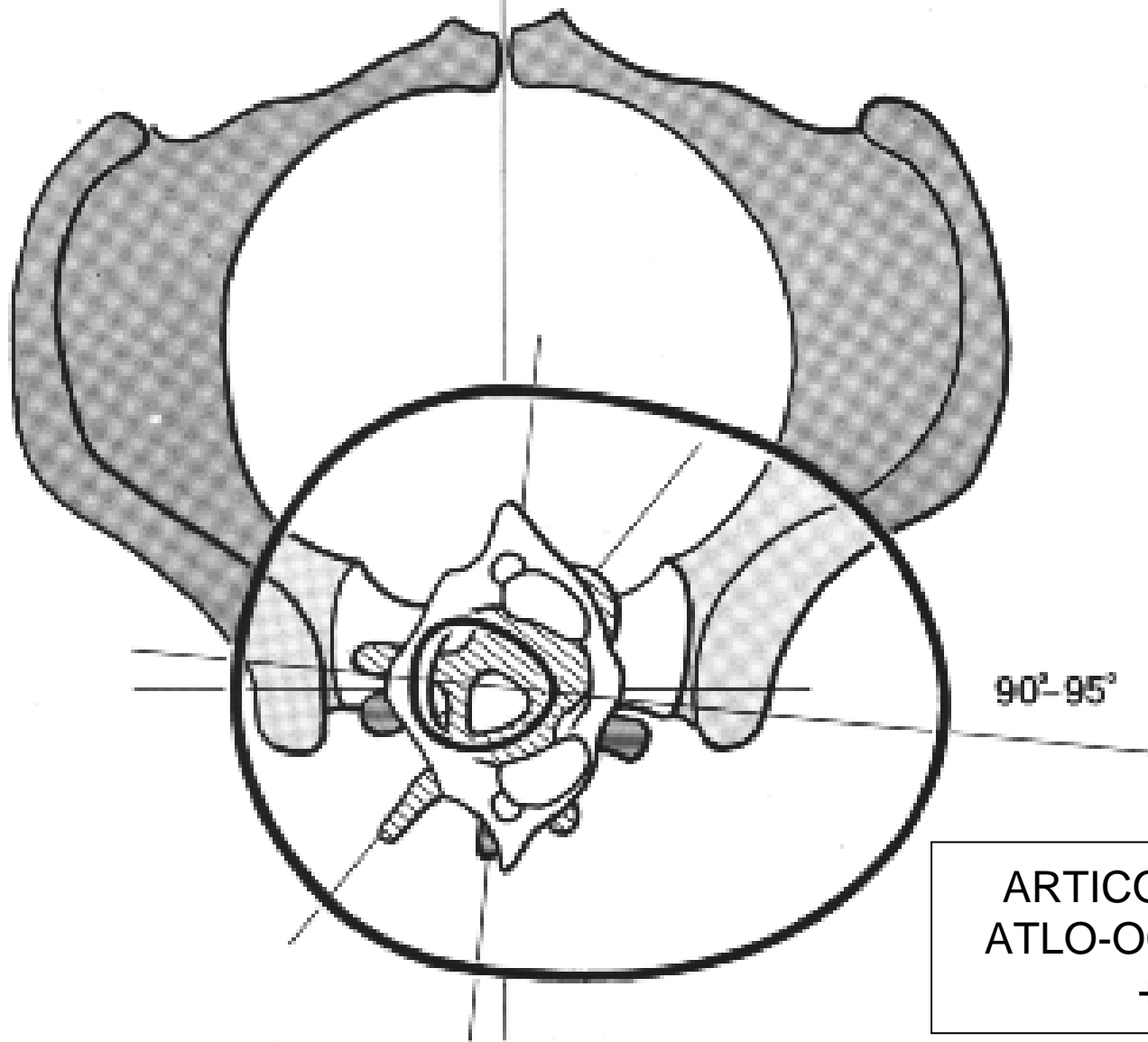
T

C

ROTAZIONE LOMBARE



ROTAZIONE ASSIALE

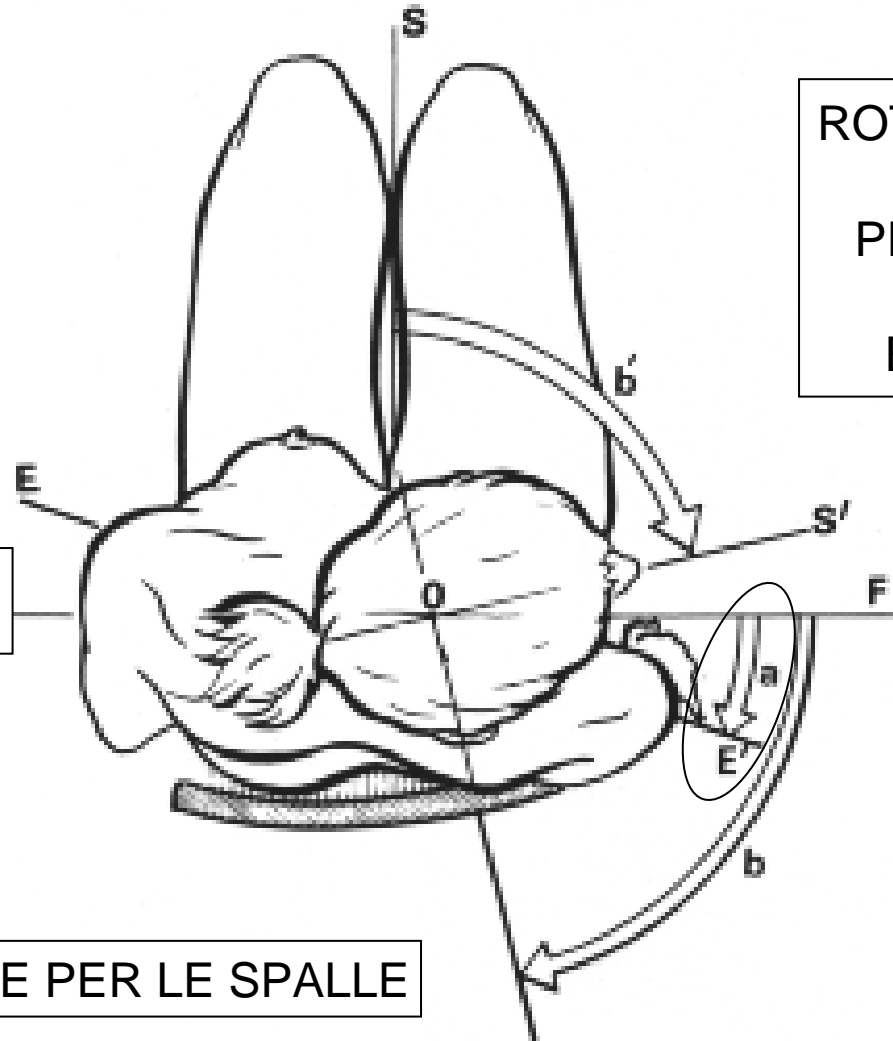


ROTAZIONE

RDL(a)

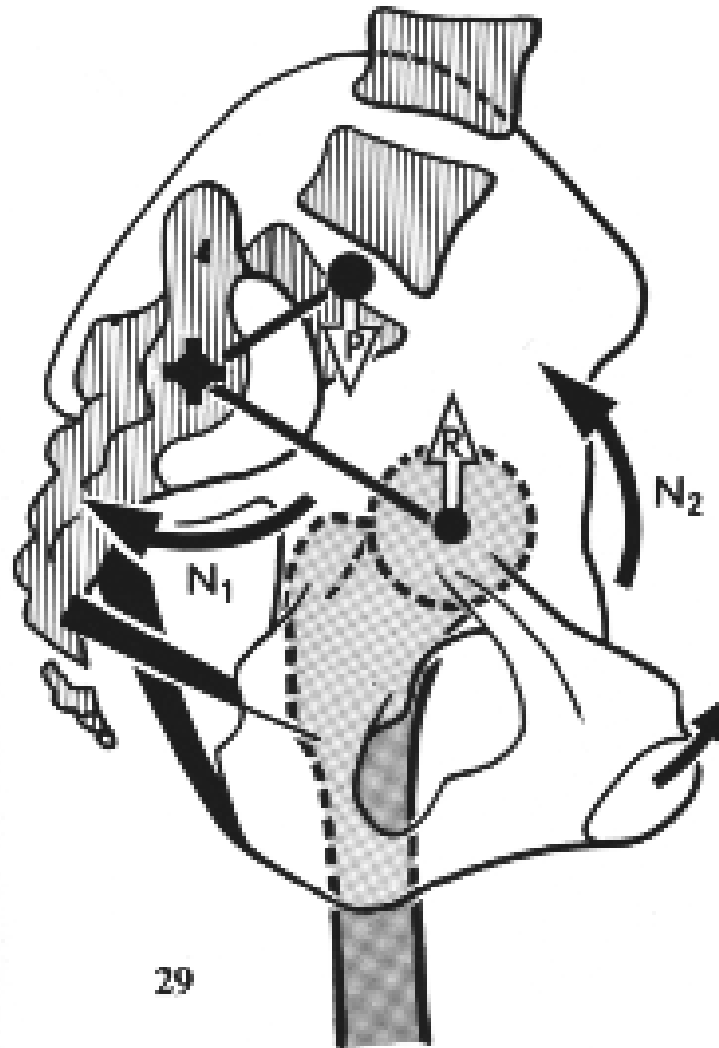
PIANO FRONTALE (F)

LINEA (EE') PASSANTE PER LE SPALLE



ROTAZIONE TOTALE:
(b)
PIANO FRONTALE
PIANO
BIAURICOLARE

TENDENZA “NATURALE” ALLA NUTAZIONE

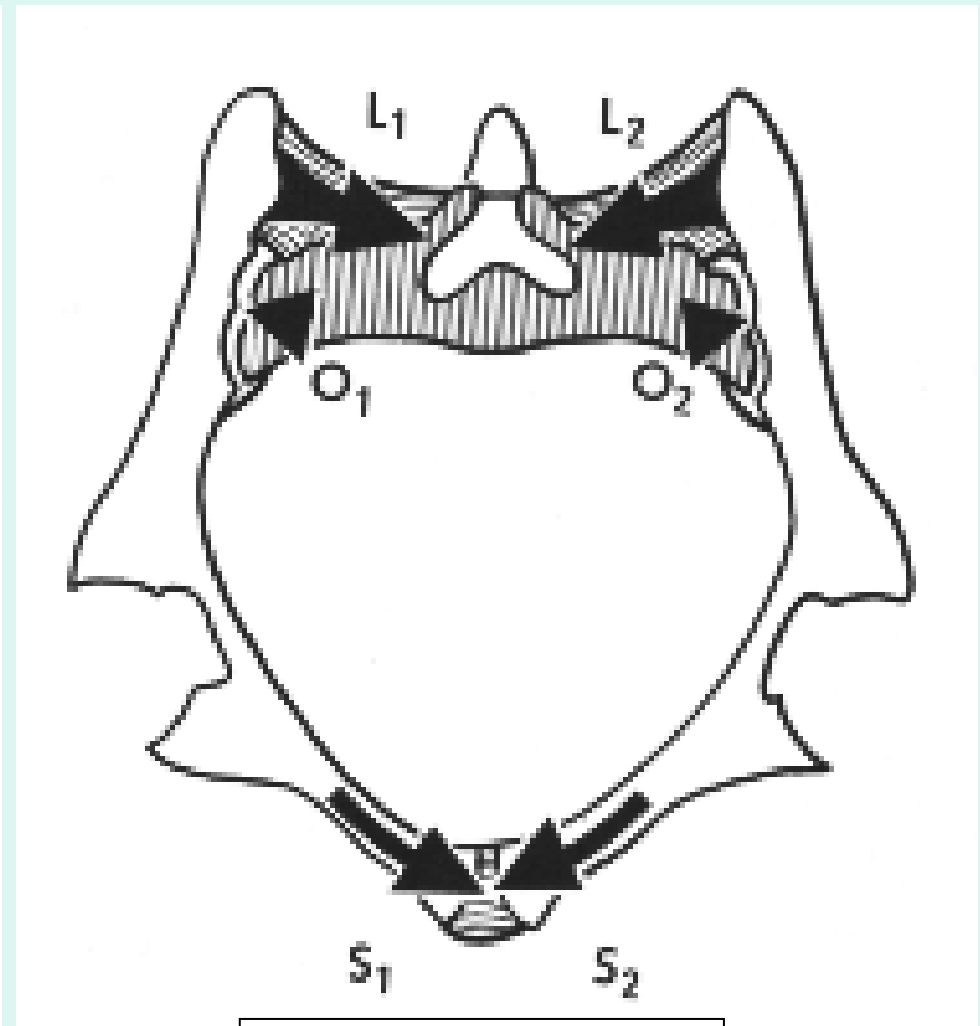
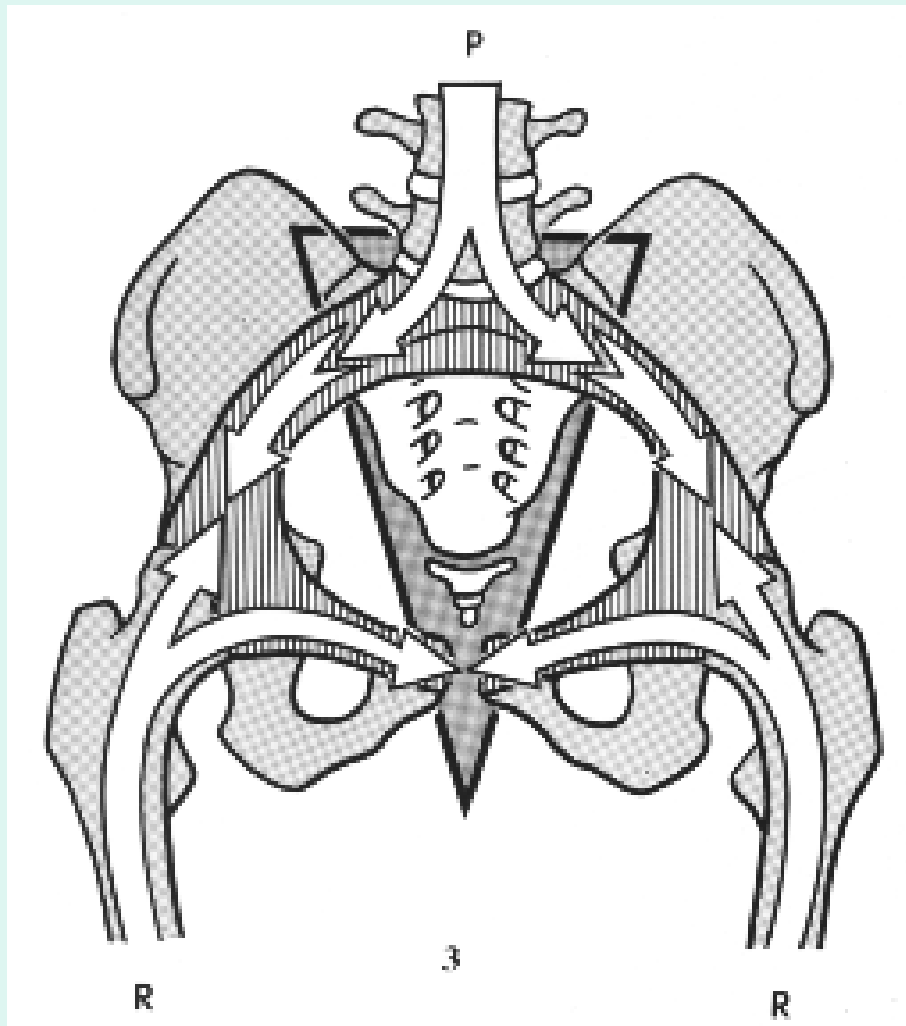


ADDOMINALI

CONTRONUTAZIONE:
Glutei,
Bicipite femorale
Semitendinoso,
Semimembranoso,
Grande Adduttore

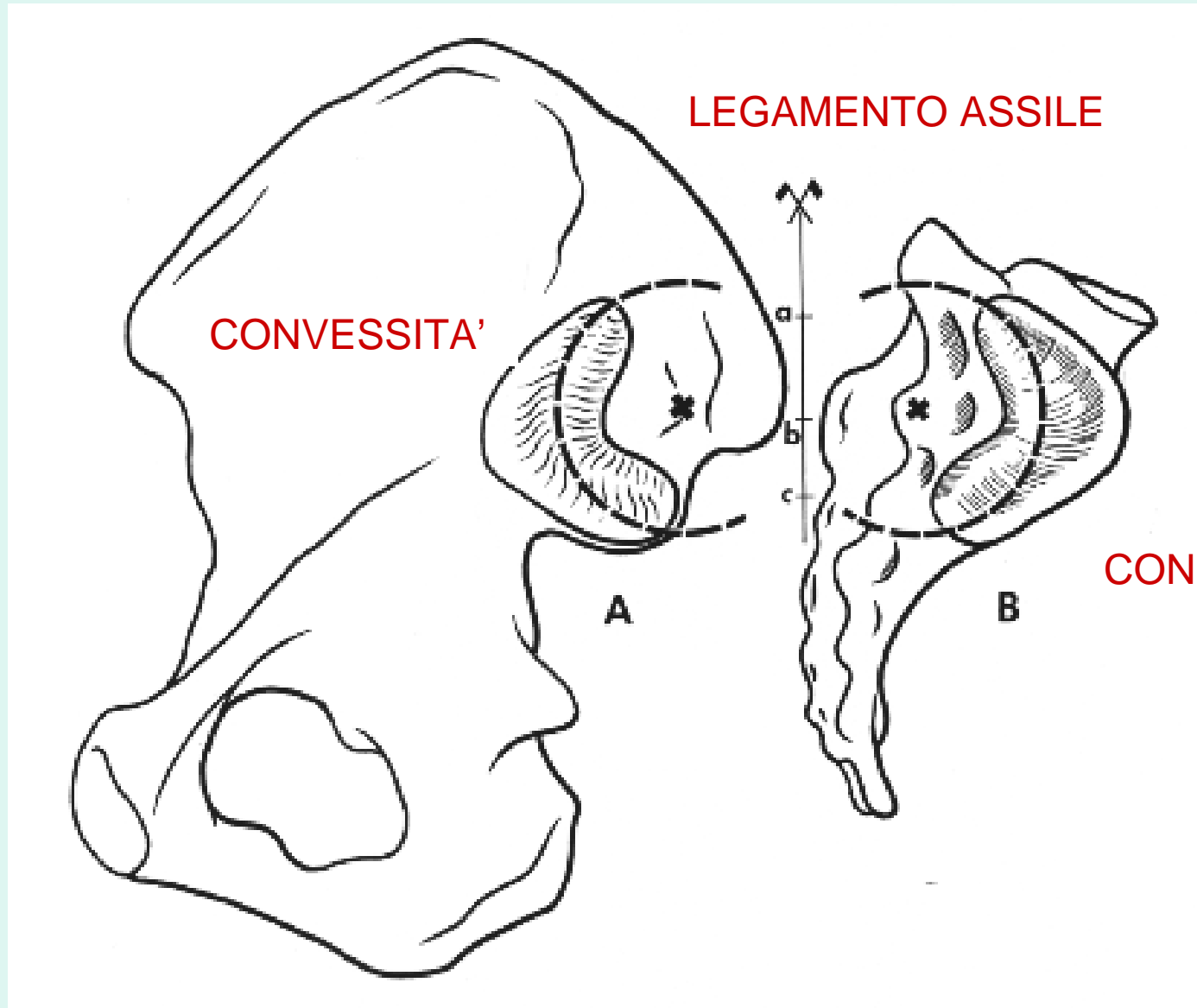
ANELLO PELVICO

ANFIARTROSI SACRO ILIACA

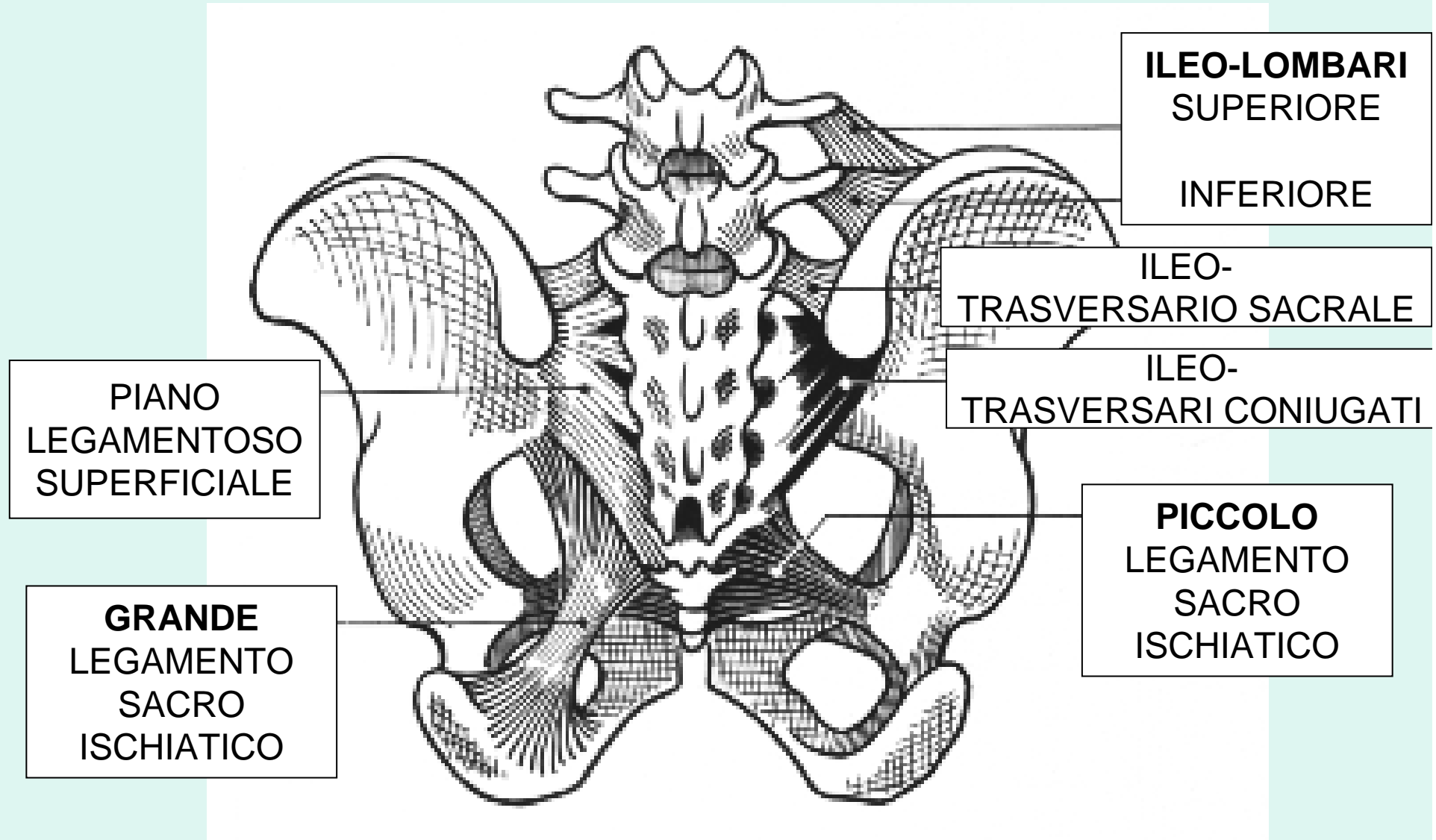


SINFISI PUBICA

ARTIC. SACRO-ILIACA

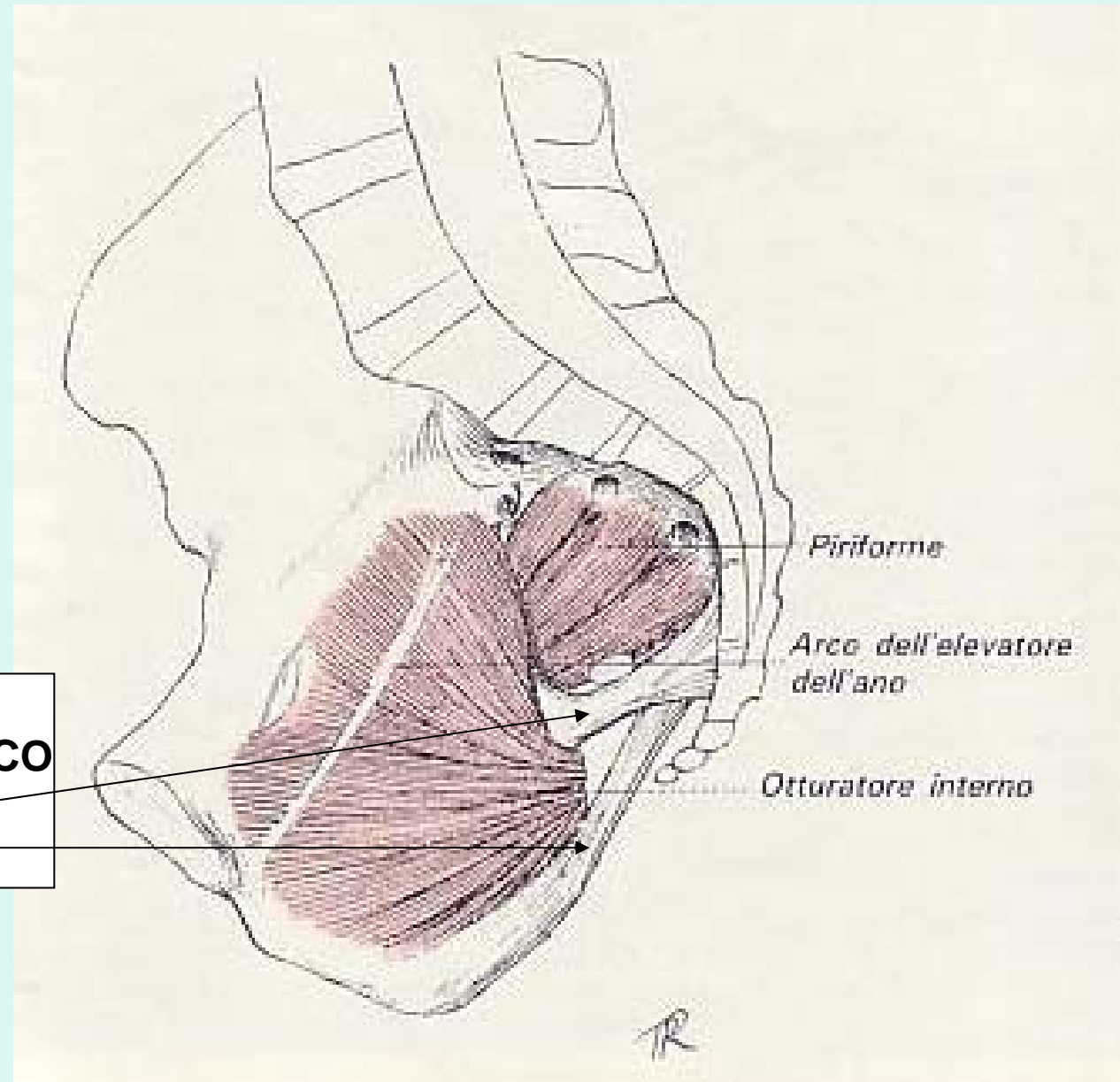


LEGAMENTI



VEDUTA ENDOPELVICA

LEG.
SACRO-ISCHIATICO
PICCOLO
GRANDE



PIRIFORME E OTTURATORE INTERNO

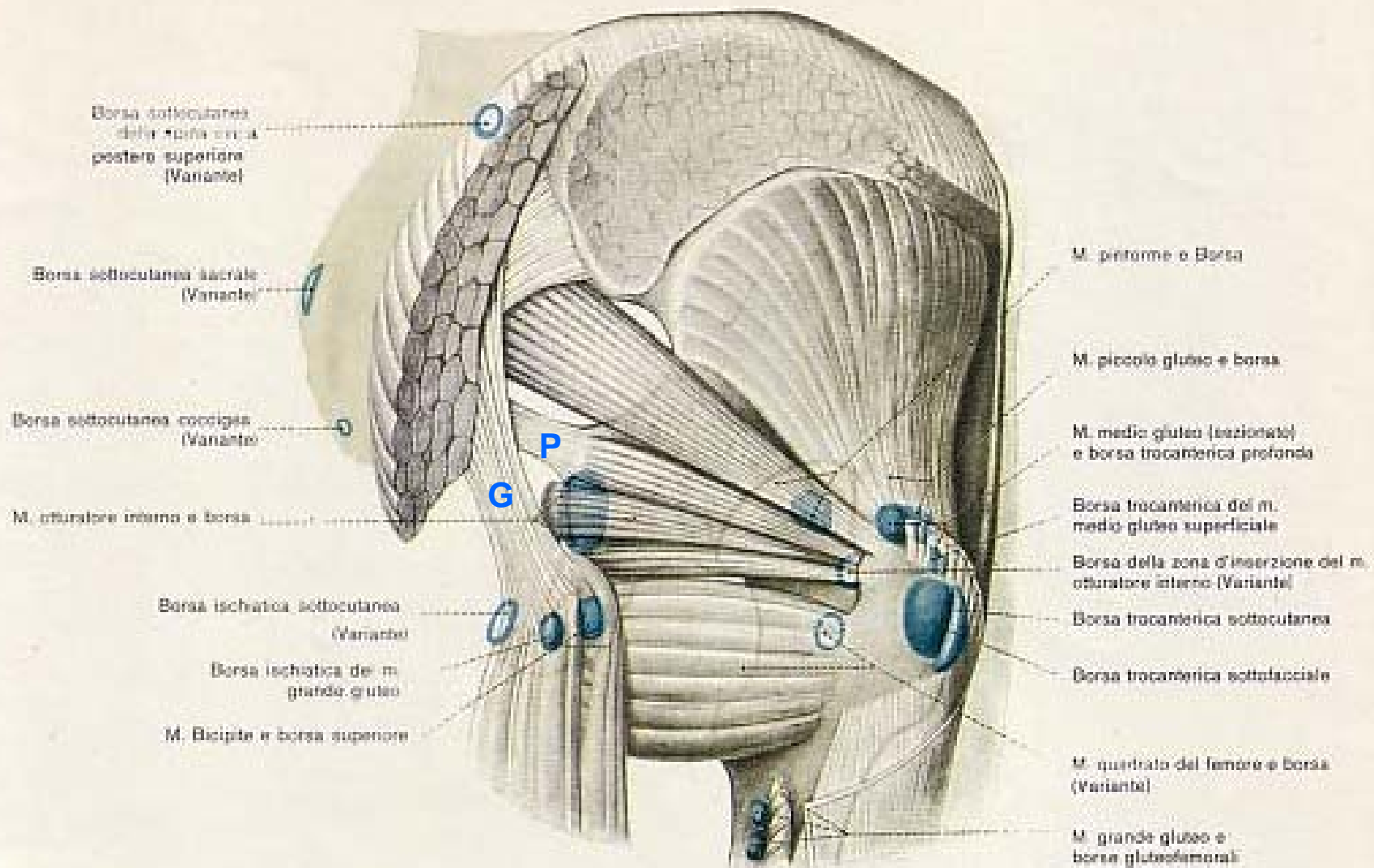


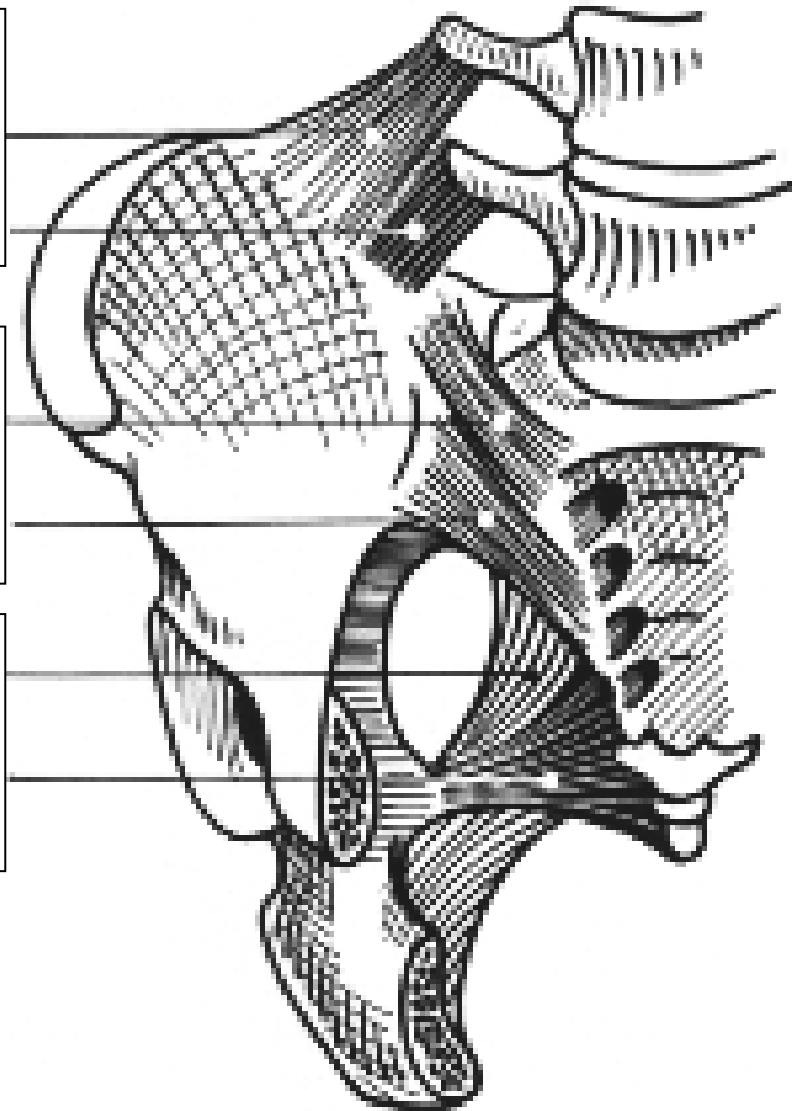
Fig. 12.11. Le borse sinoviali della regione glutea. In azzurro le borse principali; le borse accessorie sono indicate soltanto dal contorno azzurro (da Lang e Wachsmuth).

Legamenti visti anteriormente

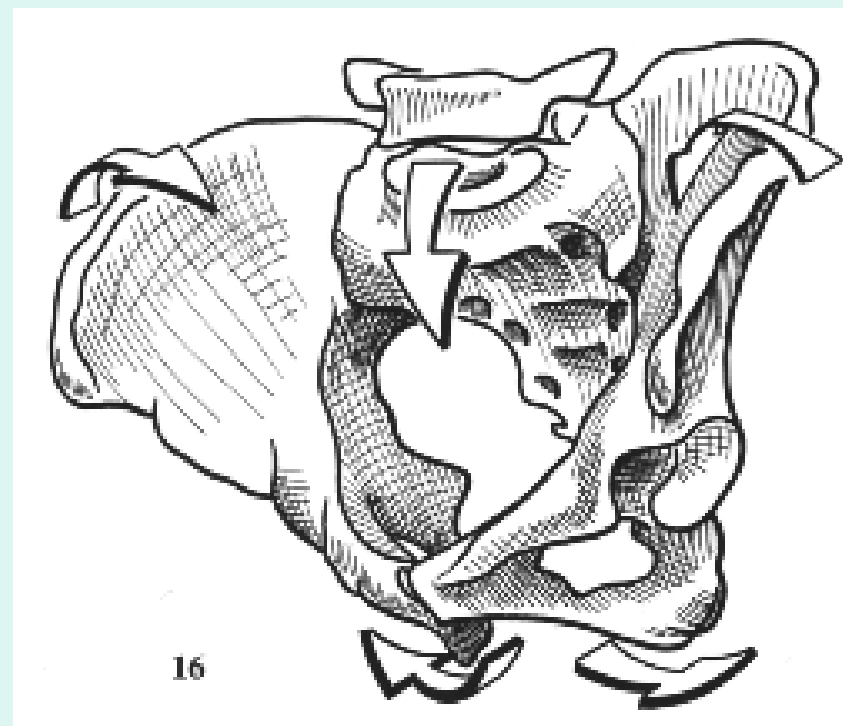
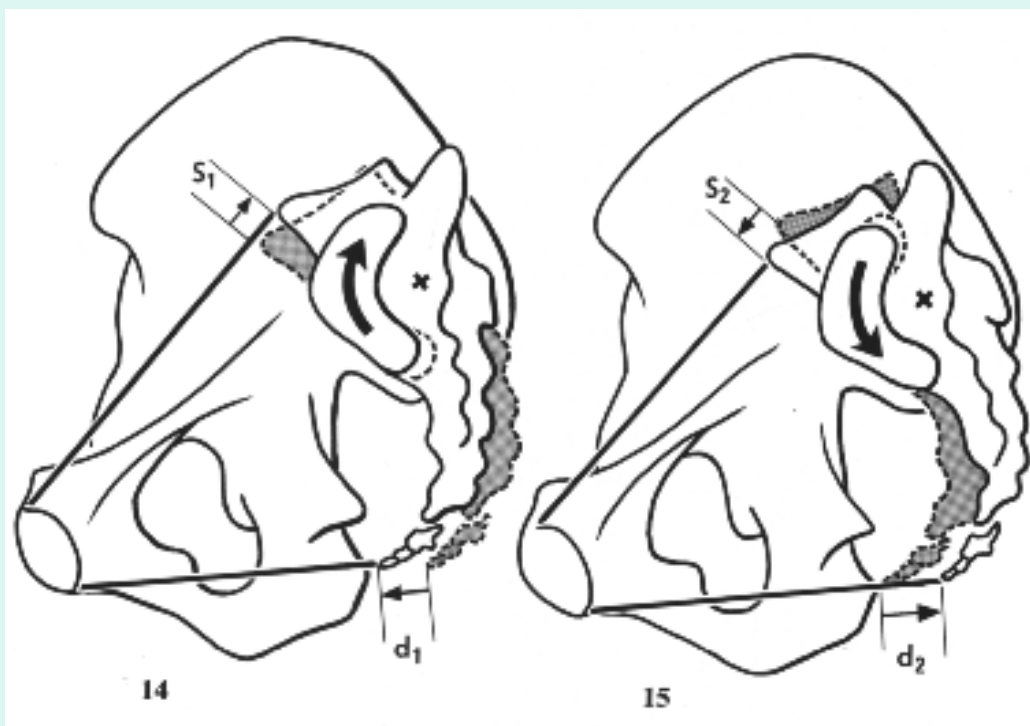
LEGAMENTI
ILEO-LOMBARE
SUPERIORE
INFERIORE

LEGAMENTI
SACRO-ILIACO ANTERIORE
SUPERIORE
INFERIORE

LEGAMENTI
SACRO-ISCHIATICO
GRANDE E
PICCOLO

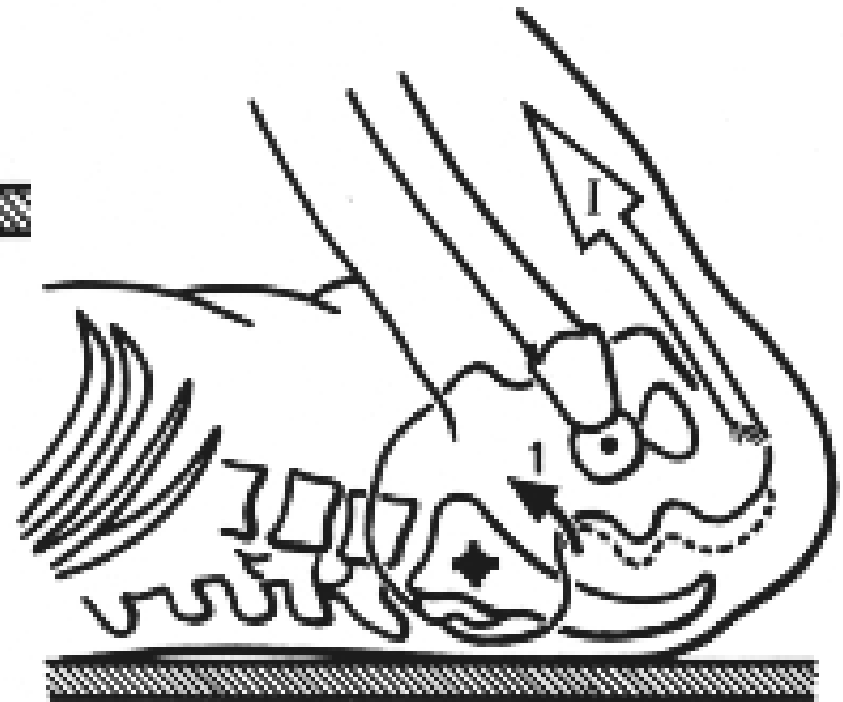
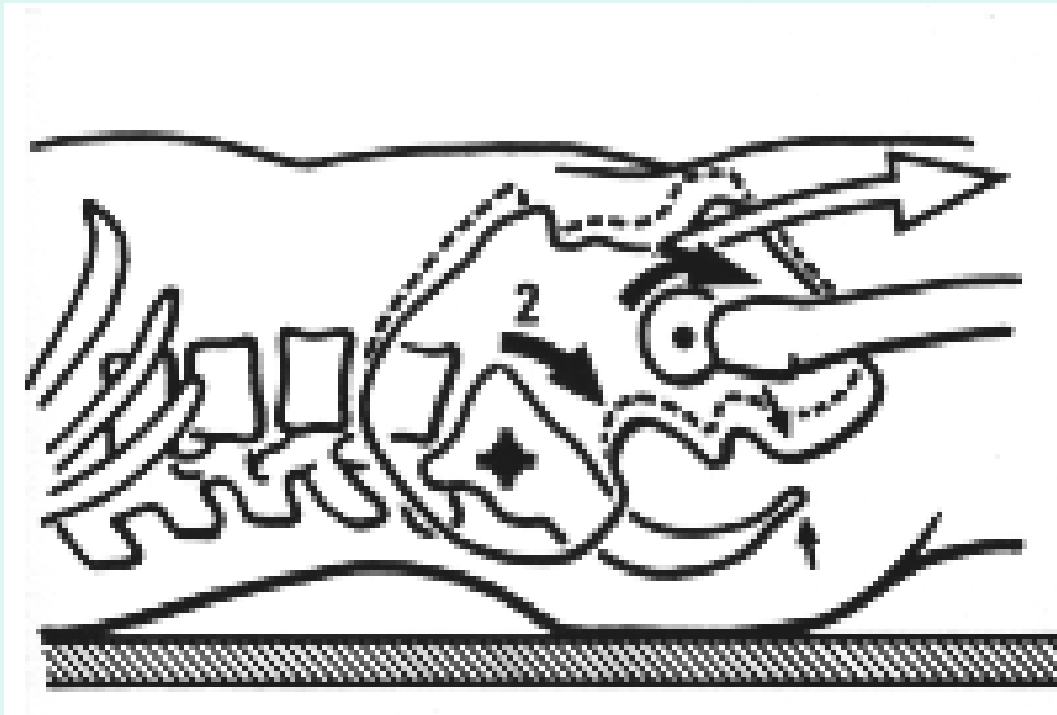


NUTAZIONE / CONTRONUTAZIONE



www.fisiokinesiterapia.biz

POSIZIONI E CINGOLO PELVICO



SPONDILOLISTESI / SPONDILOLISI

