

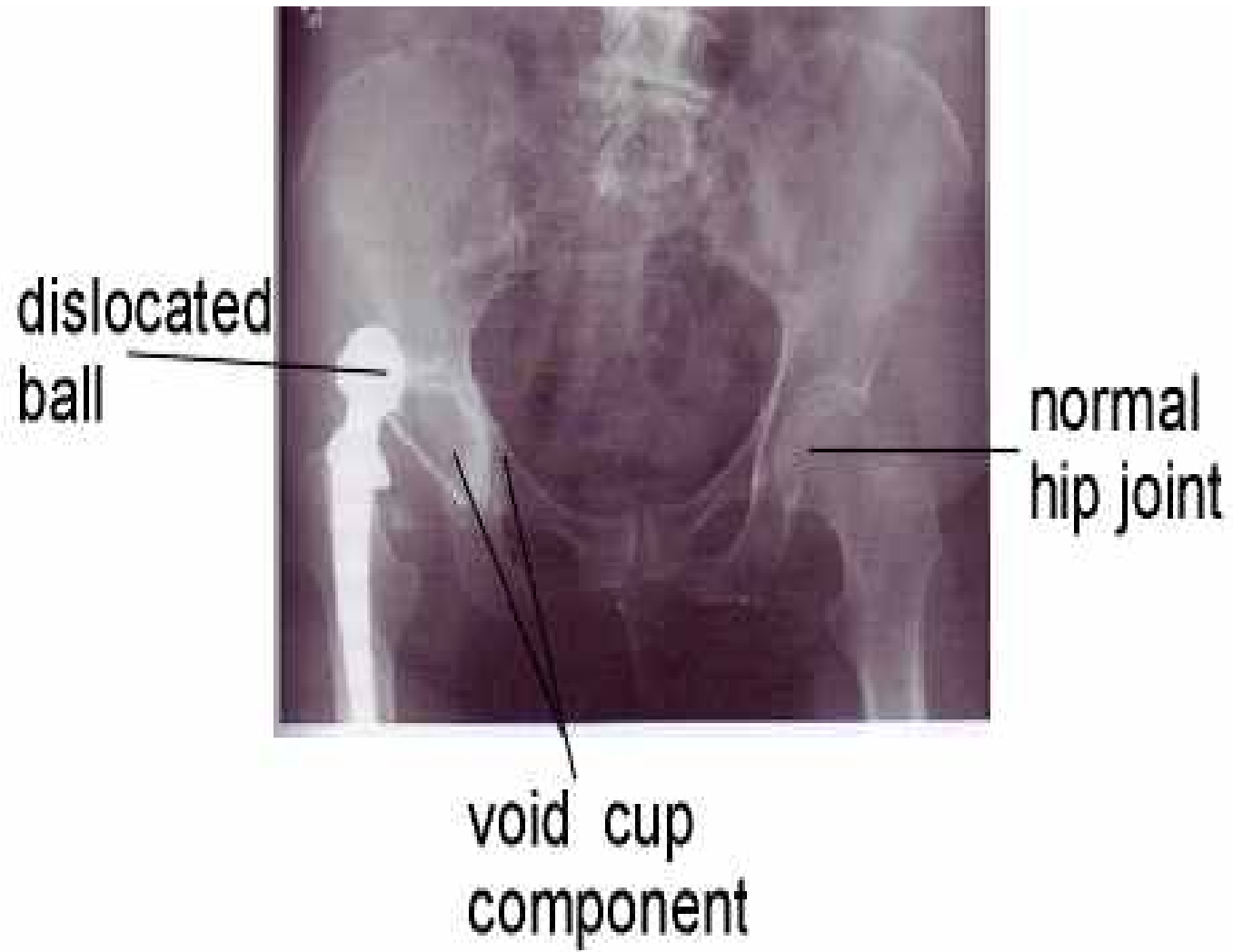
DISLOCATION OF THE TOTAL HIP Arthroplasty

www.fisiokinesiterapia.biz

The point must be made that an occasional post-operative dislocation ... is no disgrace. Patients can sometimes be quite irresponsible and unreasonable during this period ... It is only in recurrent subluxation or dislocation that the surgeon might have to hold himself responsible.. " (???)

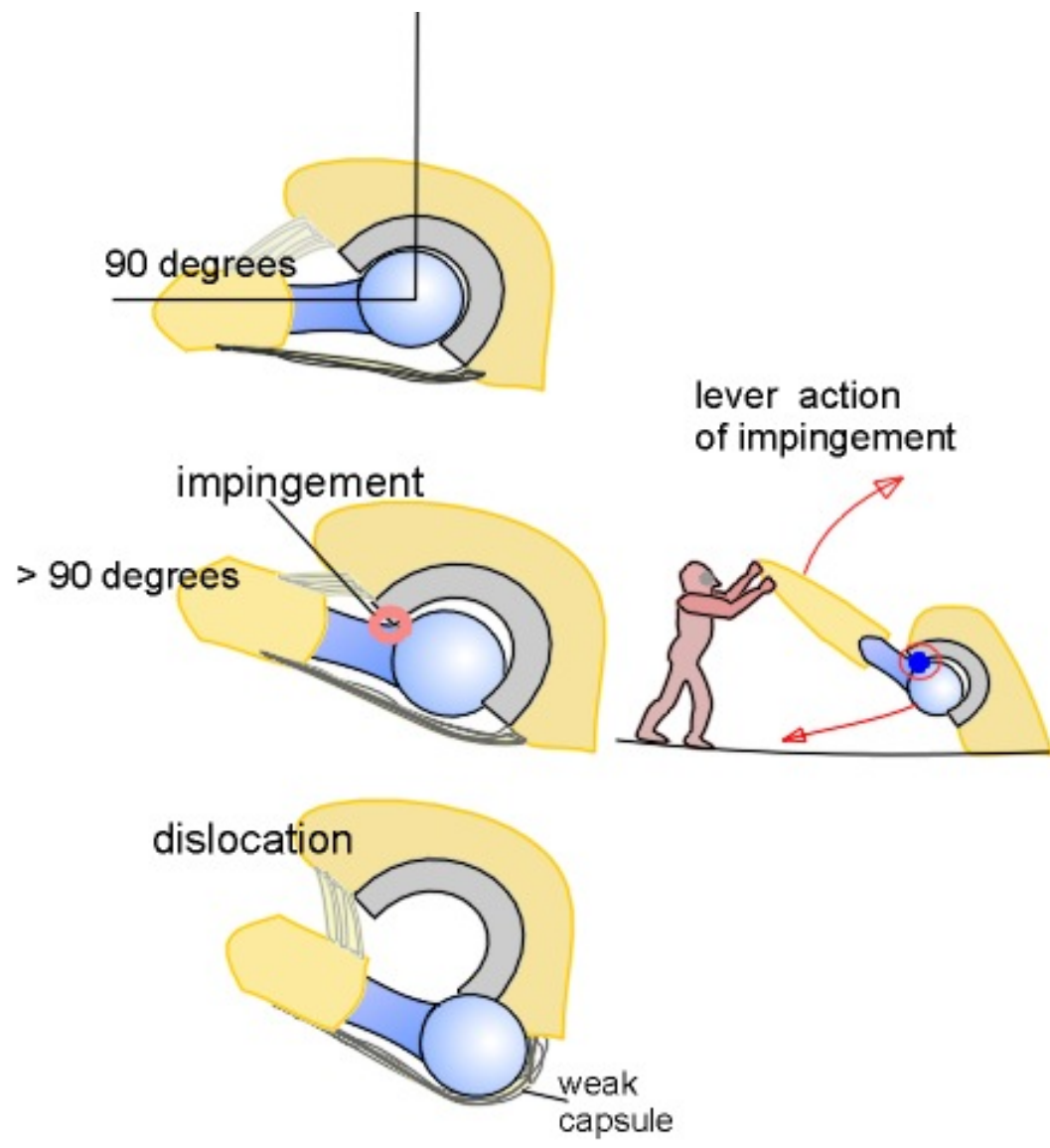
Sir John Charnley 1979, one of the Founding Fathers of the total hip surgery.

The total hip dislocation is a painful complication in which the femoral ball component comes out (dislocates) of its place in the cup component and moves outside the total hip.



The mechanisms of dislocation

impingement of the neck of the femoral component against the rim of the cup

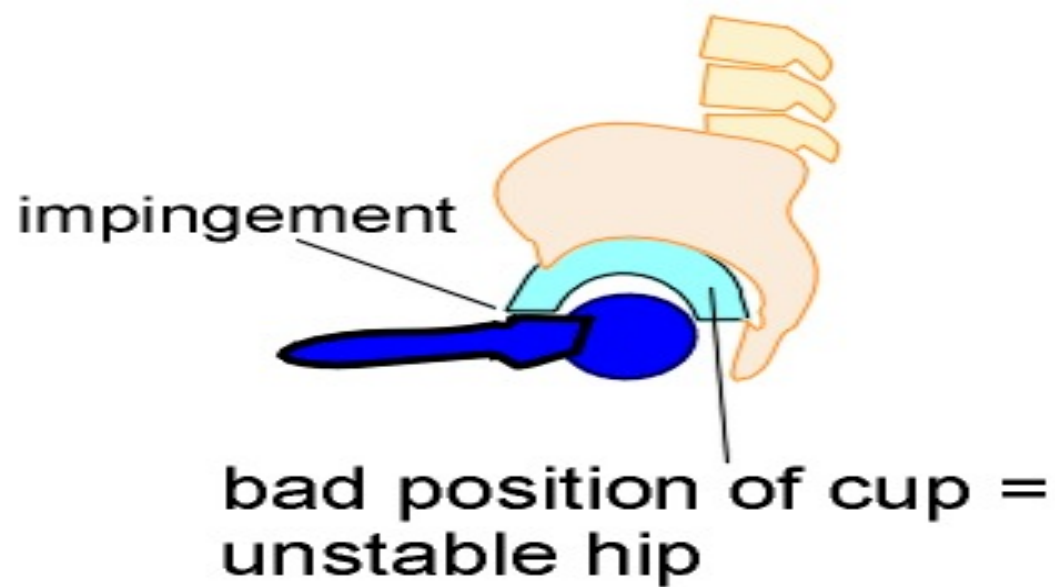
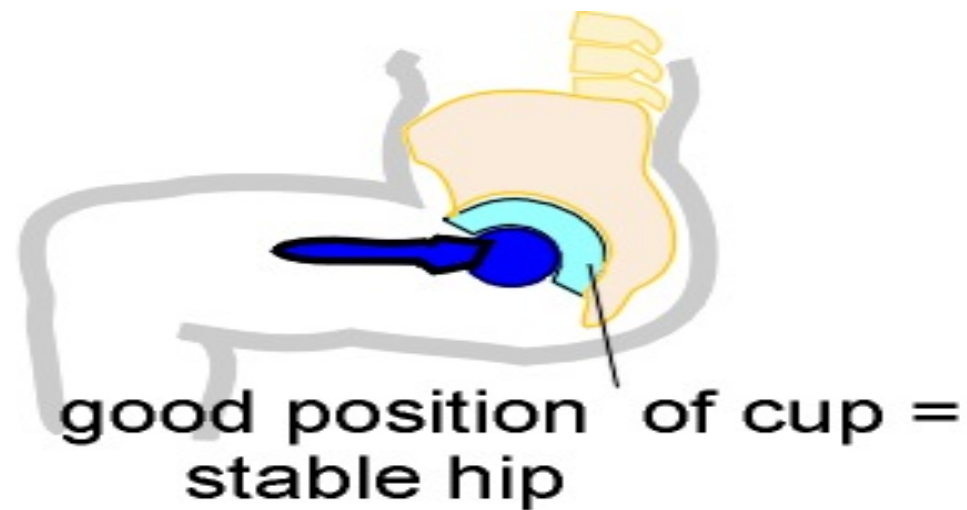


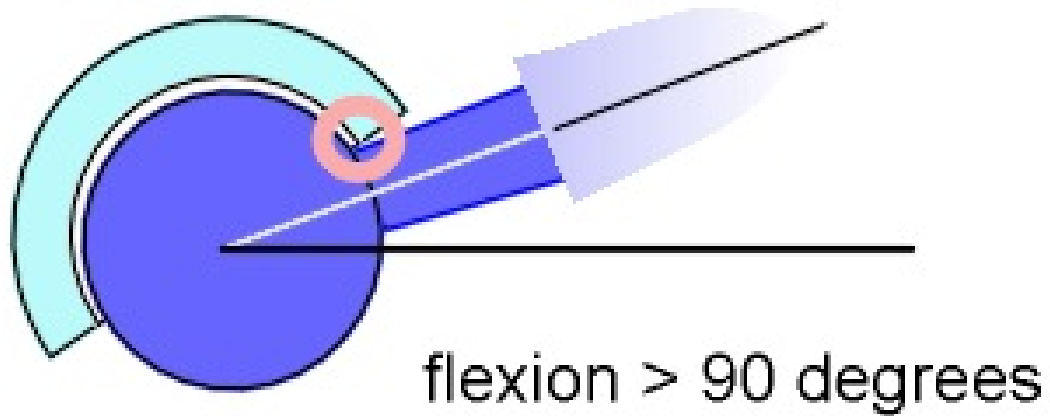
Other causes

- Weak soft tissue; abductors, capsule,...
- Wrong component position

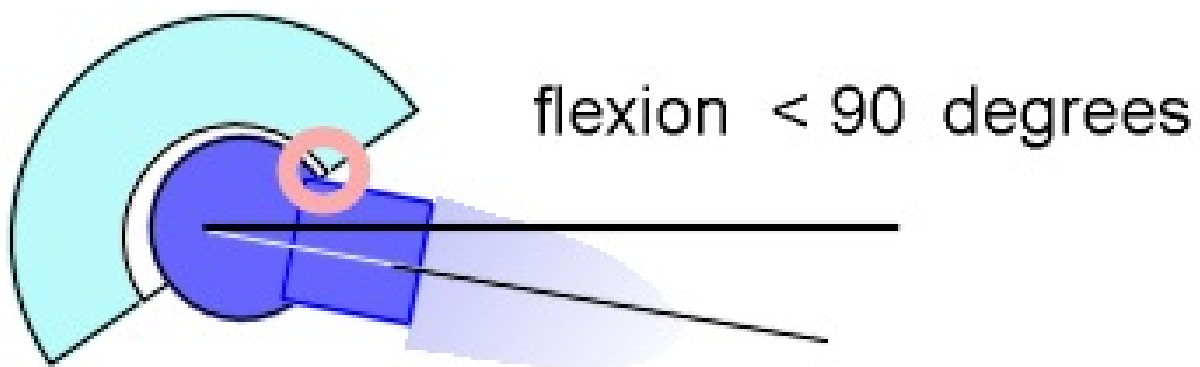
Stability of the total hip joint

1. Restoration of balance in soft tissues around the total hip
2. Good position of the components
4. The size of the head component
5. Large head makes the total hip joint more stable





outer size of cups
is
equal



How often does it happen?

- %0.3 - %3
- Medicare patients in the United States: patients operated on by surgeons who performed less than 6 THR annually experienced 4.2% dislocations, patients operated on by surgeons with > 50 THR annually experienced only 1.5% dislocations

Factors increasing risks of dislocation

Usually, not one but several risk factors collaborate.

Patient risk factors include:

- advancing age
- female gender
- prior surgery
- fracture through the hip joint
- posterior approach
- weak abductors
- neuromuscular disorders
- dementia
- alcohol abuse

Important surgical risk factors leading to dislocation include

- wrong positioning of the total hip components,
- failure to restore leg length and / or proper tension of the tissues around the total hip
- failure to preserve the strength in the abductor muscles (the strong muscles that move the leg sideways and keep the femoral ball in the cup).

Implant risk factors

- include total hip models with small femoral heads (22 mm)
- femoral heads with thick femoral neck component.

How to reduce the chance of DX

-Right component selection & position

Acetabulum; 11-28 Ante, 40+ Inclination

Femoral stem; 10 Ante version

- good soft tissue management
- Patient training

Soft tissue management

Repair of capsule, short external rotators

Not to damage abductor system

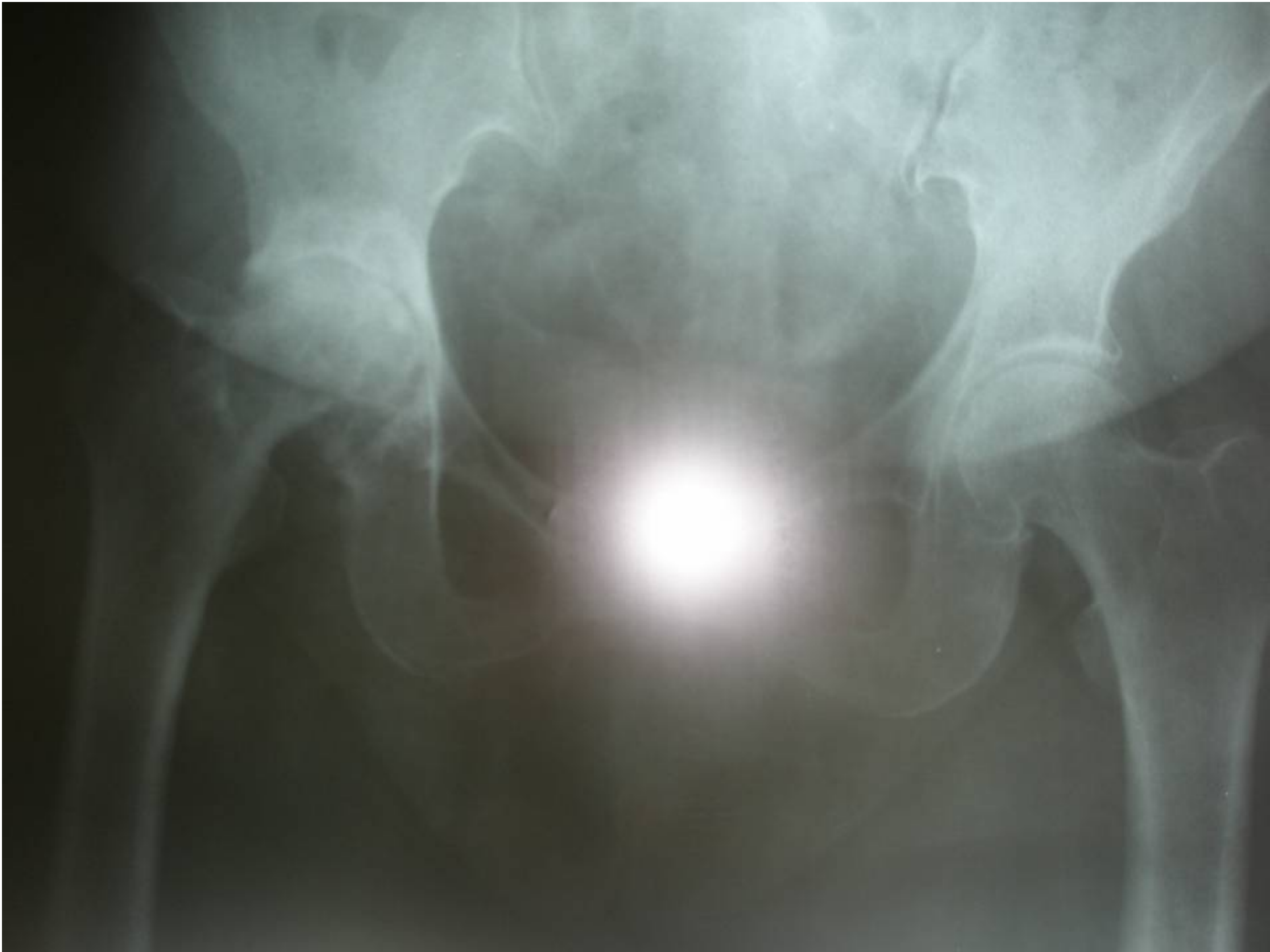Minimal invasive surgery

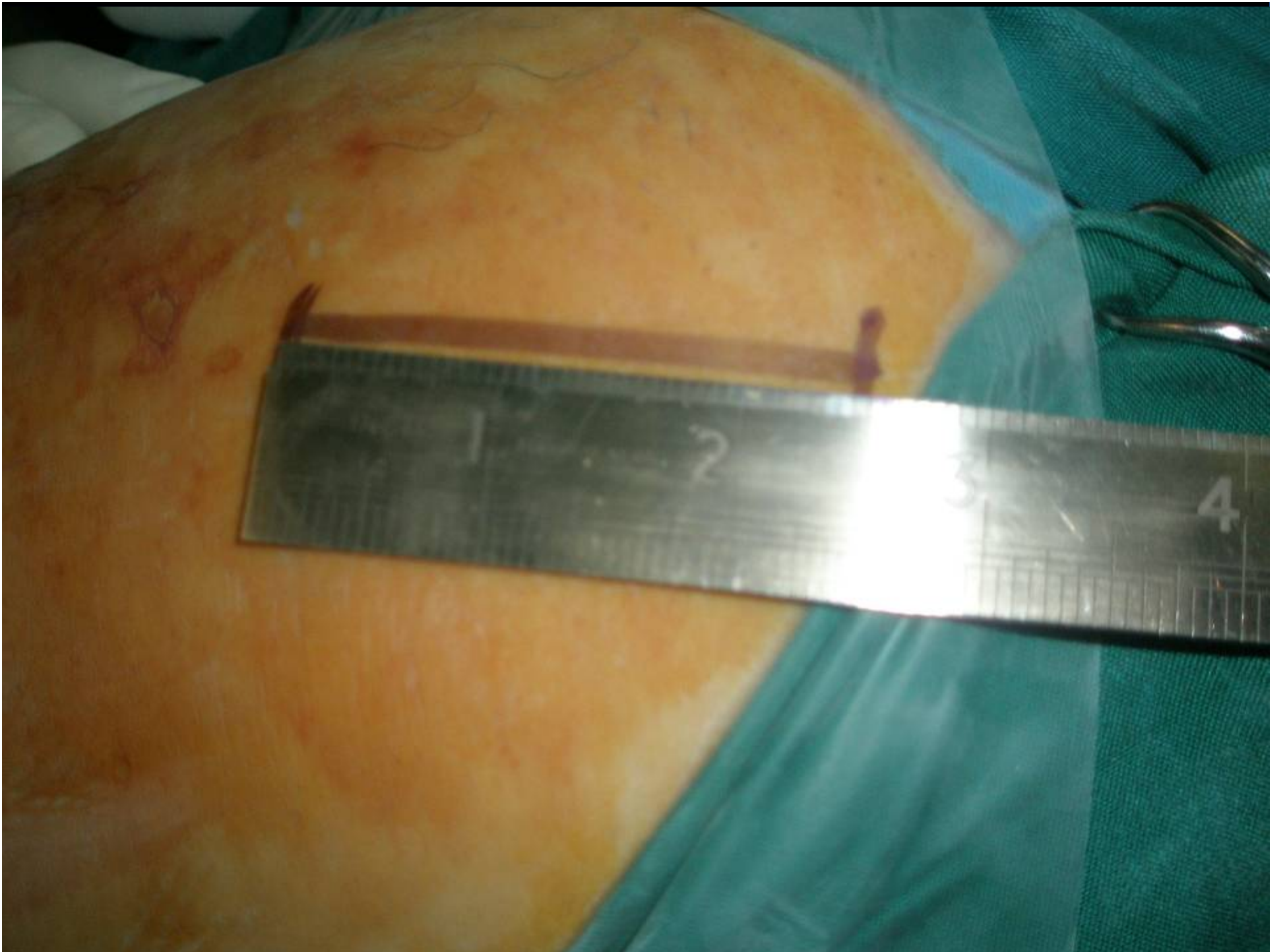
- 2 incisions,
- one short incision

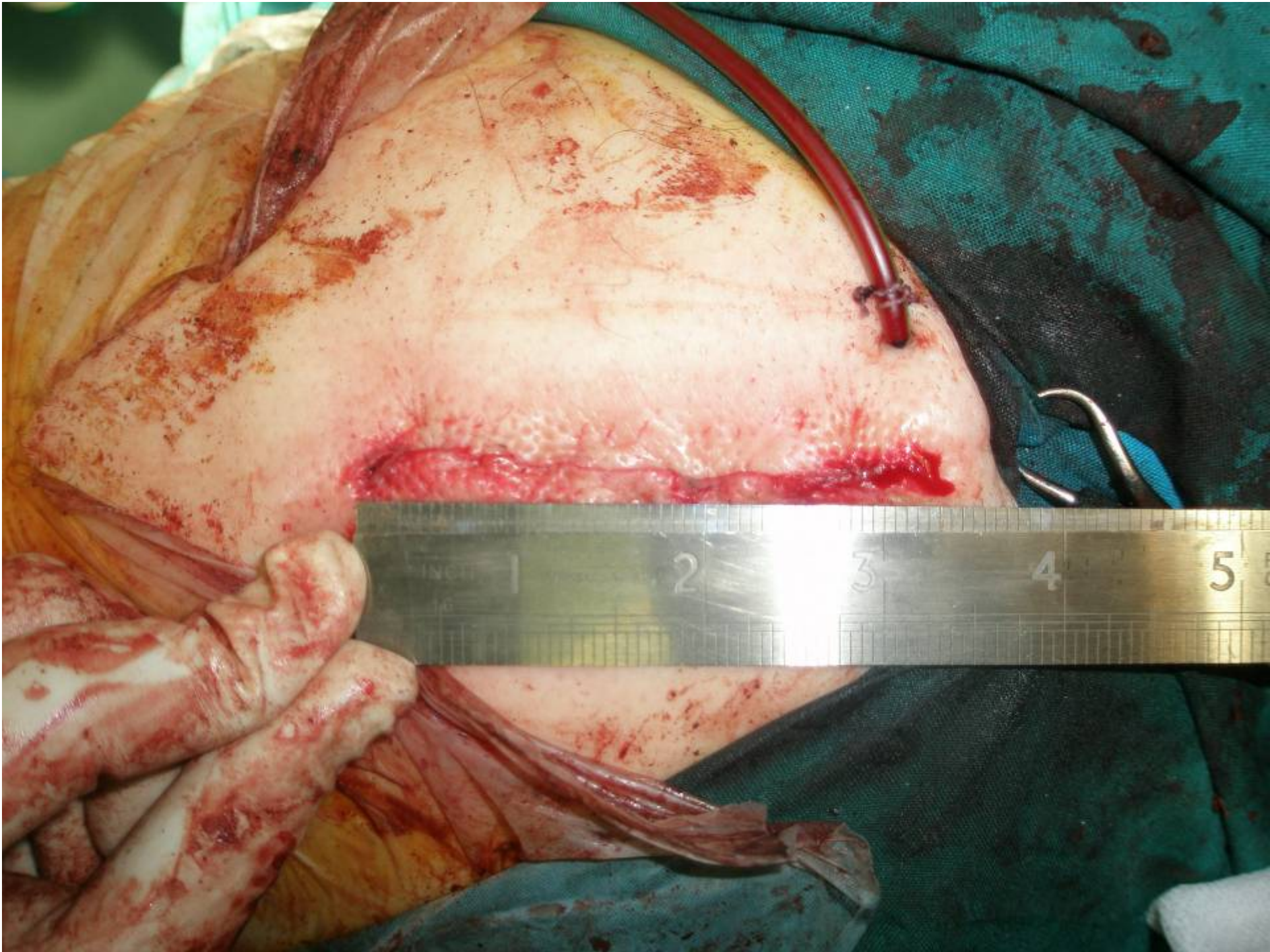
www.fisiokinesiterapia.biz

My experience with minimal incision

- poster lateral approach
- 6-8 Cm
- Just from posterior tip of greater trochanter as to rim of acetabulum
- 10 patients with Zimmer and Stryker system



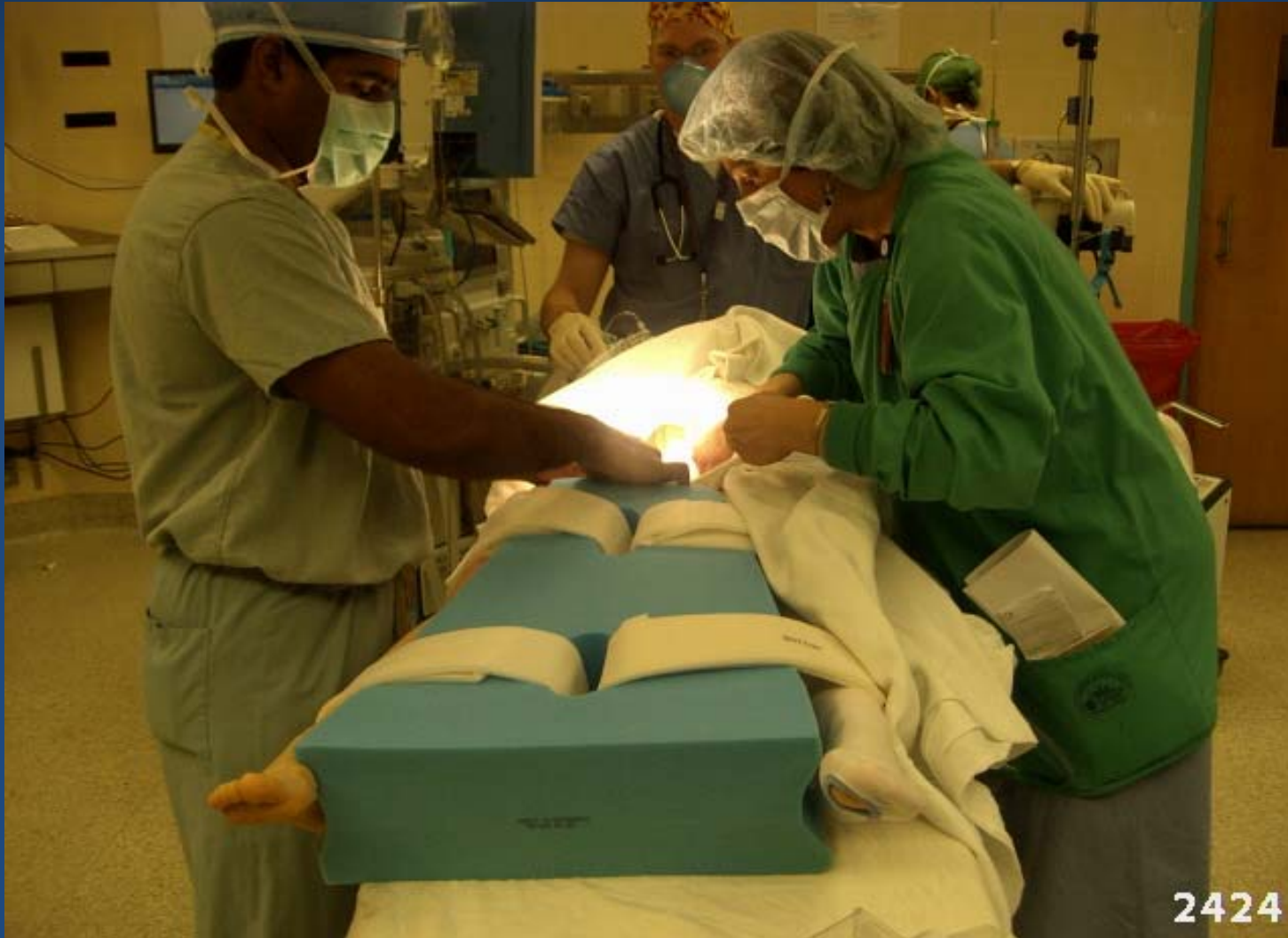



Patient training

- Using an abduction pillow; Massachusetts General hospital protocol for all THAs
- ----Tavantoos aduction pillow

Massachusetts General Hospital



Tavan-Toos Abduction Pillow



Patient training

- Noncompliance patients, spica cast
- How to start sitting, standing and sitting
- Restroom sitting
- Not to sleep prone

Symptoms and Signs of total hip dislocation

Total hip dislocation is a very painful condition

Symptoms and Signs of total hip dislocation

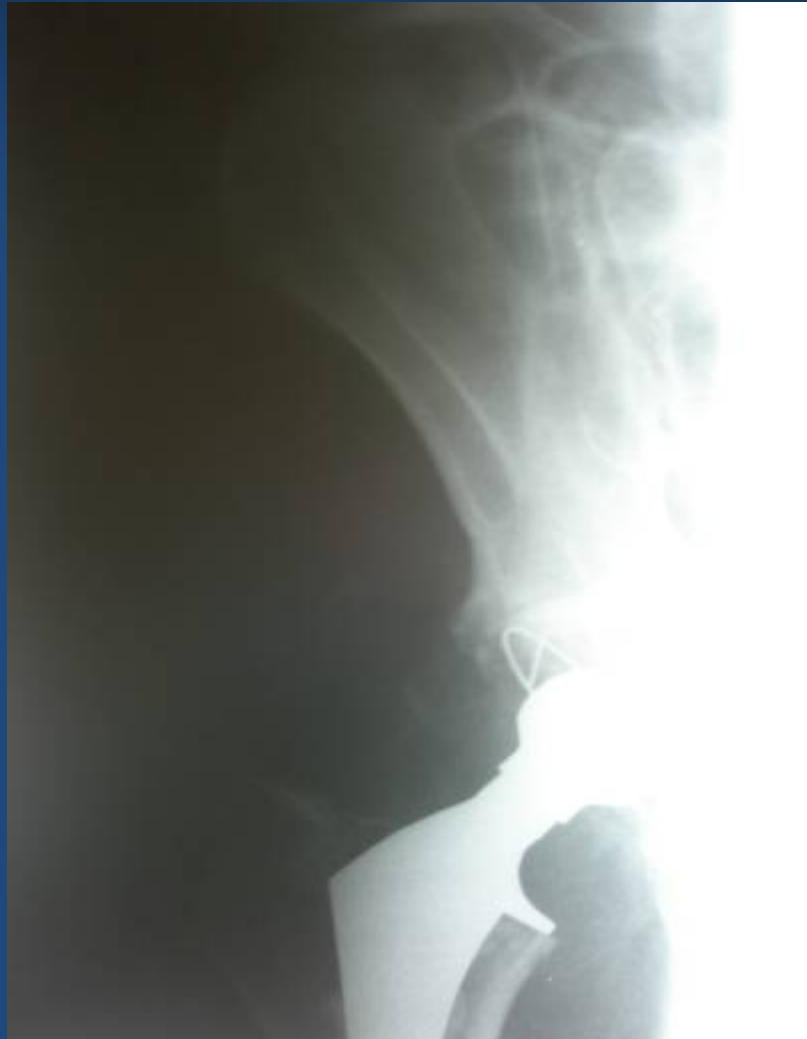- feels very painful "popping" in the total hip joint.
- keeping the whole leg stiff and firmly pushed to the midline and the other leg
- In patient with many dislocations in the past, the pain may be only moderate

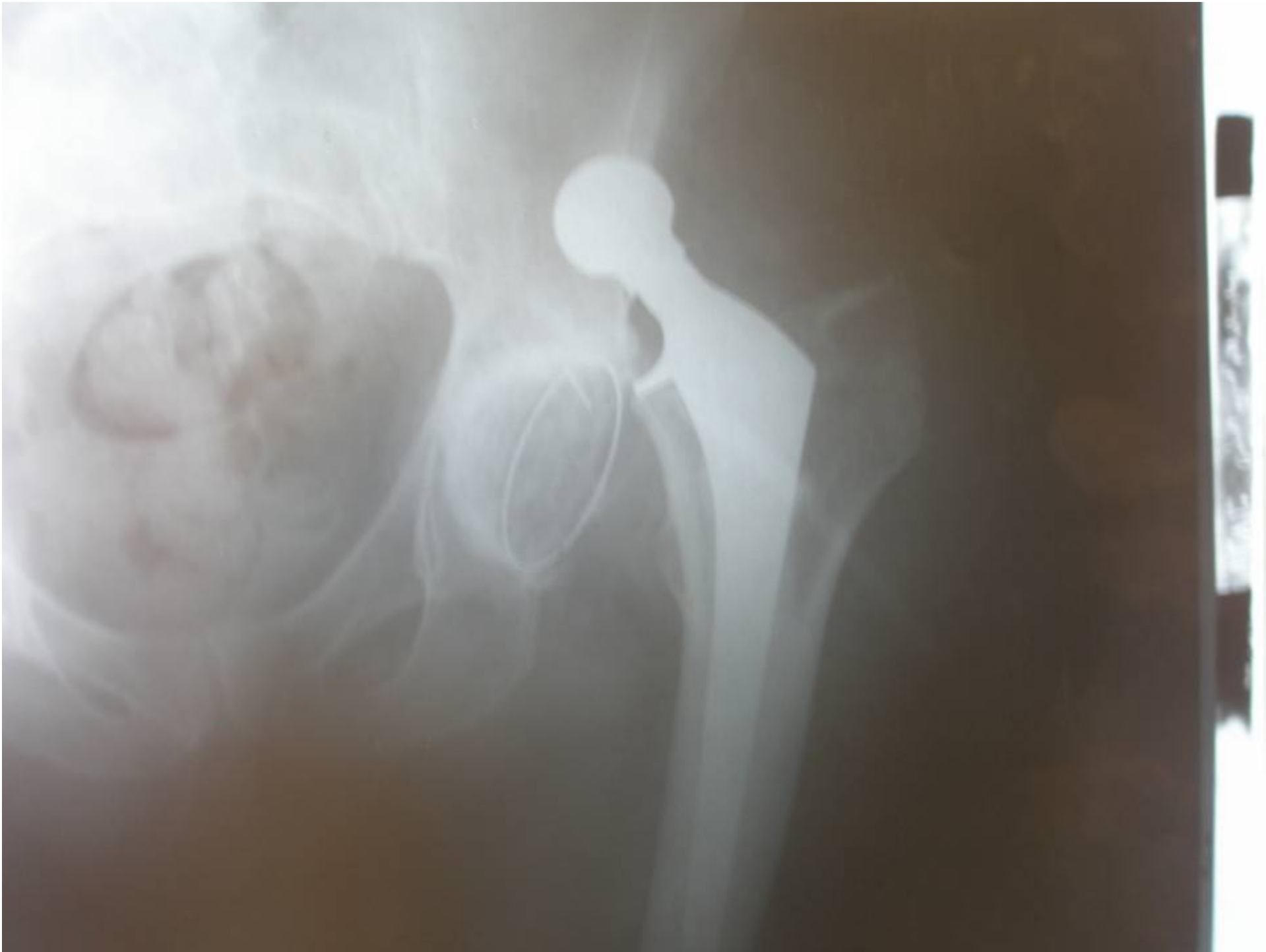Treatment of the first dislocation

CR: Longitudinal traction and slight abduction when the head is at the level of the acetabulum

Post care: adduction orthosis (15°), traction, spica cast for 6 weeks

**An 80-years man, Department of Orthopedic
Surgery, Ghaem Hospital 1383**





It dislocated for 2 times

- We manage the patients with a spica cast

The repeated dislocation

The first dislocation that occurred during the first three postoperative weeks and was treated accordingly has a low risk of recurrence: about 20 to 30 % during the next years.

After another (second) dislocation the risk that the total hip will continue dislocate increases substantially; according to some statistics about 50% of patients who had two dislocations will continue to dislocate their total hip repeatedly; this risk is especially high if the total hip operation was done through posterior approach or if the total hip is a model with a small femoral head.

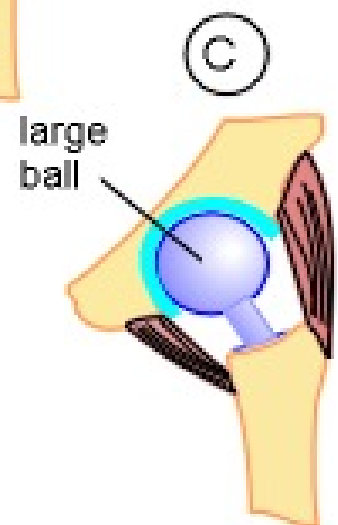
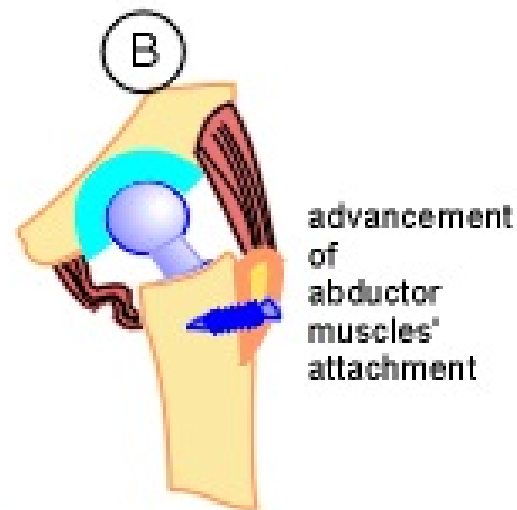
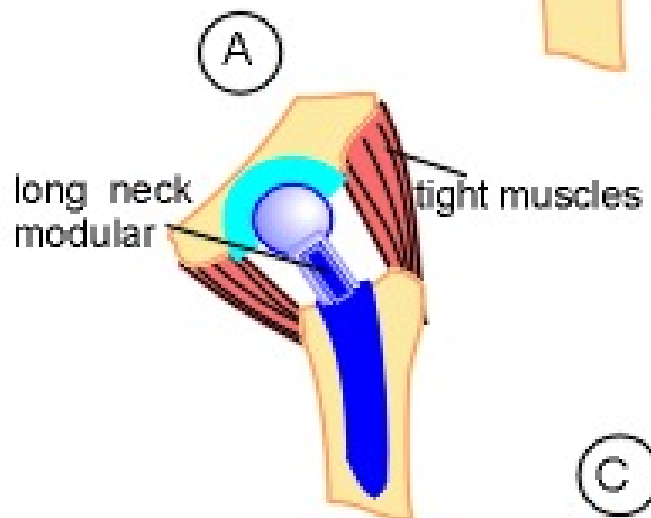
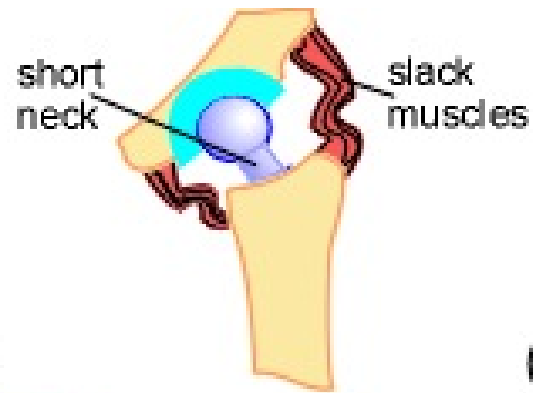
Examinations after second and further dislocations

Comprehensive x-ray
CT-Scan

Fluoroscopic study under sedation

OPERATIONS TO IMPROVE THE STABILITY

1. Revision of faulty positioned components
2. Operations to relieve slackness of soft tissues around a total hip
 - A: soft tissue advancement
 - B: Change the length of neck
 - C: Revision
 - D: Constrained cups
 - E: Bipolar hip prosthesis

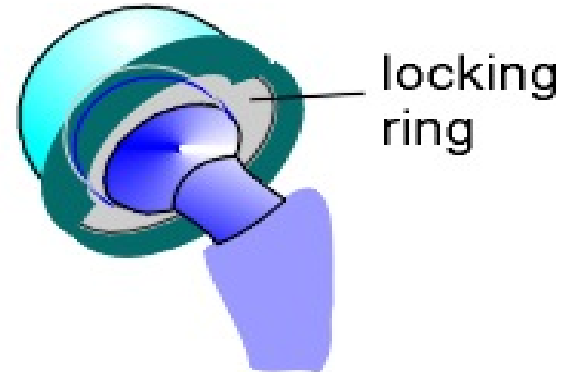


UNSTABLE TOTAL HIP

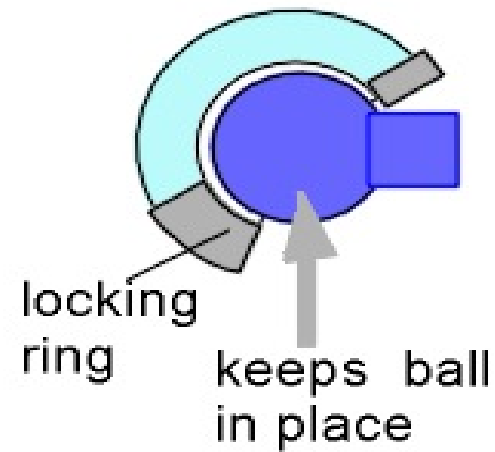
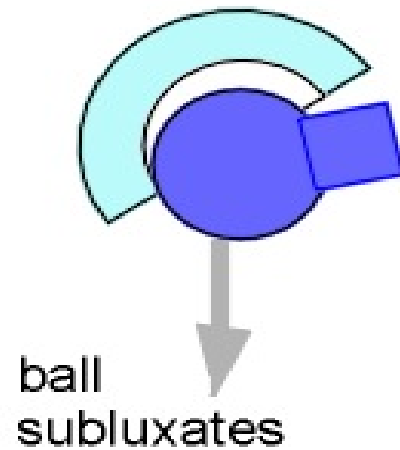
NORMAL
CUP

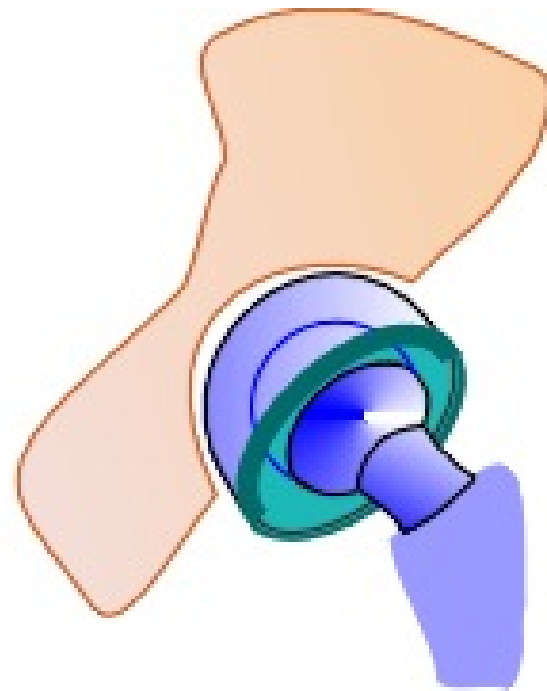

CONSTRAINED
CUP

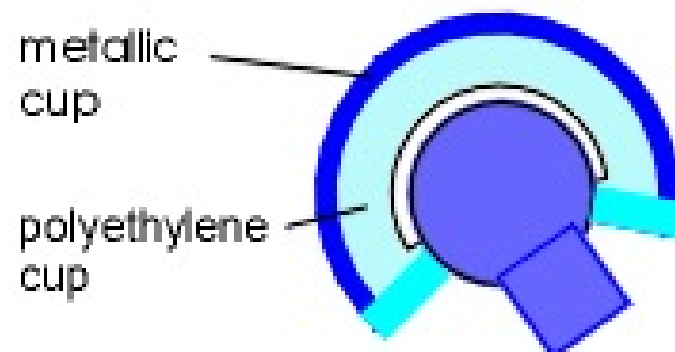


in flexion





cup
articulates
directly with
hip socket



metallic
cup

polyethylene
cup

BIPOLAR
PROSTHESIS

Dislocation of the polyethylene liner

Dislodgment of the polyethylene liner is an increasingly common complication following total hip arthroplasty

www.fisiokinesiterapia.biz

What are the symptoms

painful limp and shortening of the limb

Treatment

Operation of the dislodged liner is necessary, the surgery should be done as soon as possible

References

1. Bourne J, Mehin R.: J Arthroplasty 2004, Suppl 1, 111- 4
2. Charnley J Low Friction Arthroplasty of the Hip, Springer Verlag,1979, p 319
3. Von Koch M et al.: J Bone Joint Surg-Am 2002; 84-A: 1949-53
4. Della Valle et al . J Bone Joint Surg - Am, 83-A, 2001, 553-9
5. Brien WW, Salvati EA, Wright TM. Burstein AH: Dislocation following total hip arthroplasty: comparison of two acetabular component designs, orthopedics 16:869, 1993.
6. Hedley AK, Hendren DH, Mead LP: A posterior approach to the joint with complete posterior capsular and muscular repair, J Arthroplasty 5 (suppl): 57, 1990.