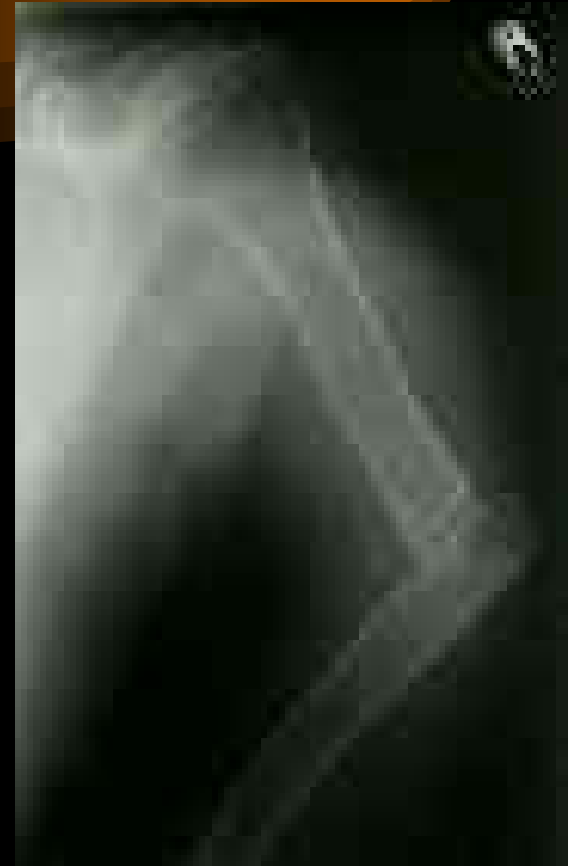
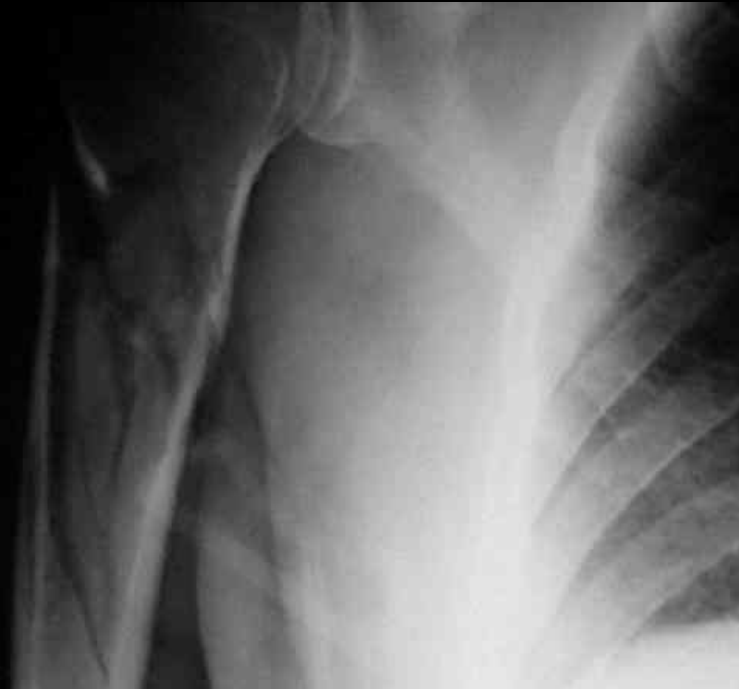
*Upper Arm, Elbow, Wrist and Hand
Injuries*

www.fisiokinesiterapia.biz

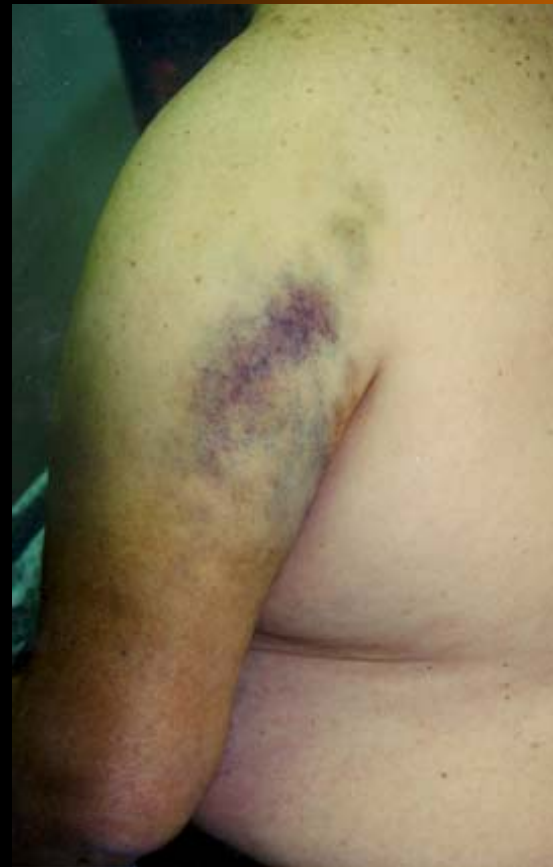Upper Arm, Elbow, Wrist and Hand Injuries

- Upper Arm Fractures
 - Mechanism
 - Signs and Symptoms



Upper Arm, Elbow, Wrist and Hand Injuries

- Upper Arm Fractures
 - Mechanism
 - Signs and Symptoms



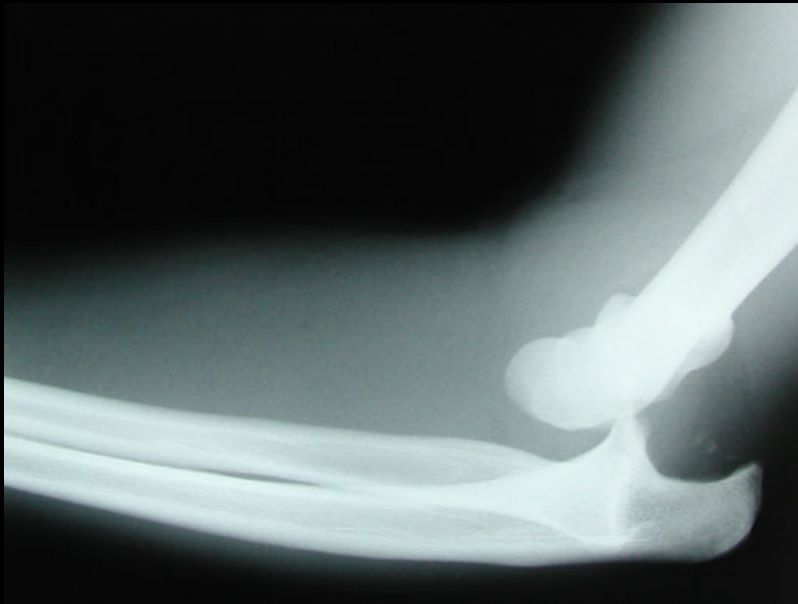
Upper Arm, Elbow, Wrist and Hand Injuries



- Elbow Dislocations
 - Mechanism
 - Signs and Symptoms

Upper Arm, Elbow, Wrist and Hand Injuries

- Elbow Dislocations
 - Mechanism
 - Signs and Symptoms



Upper Arm, Elbow, Wrist and Hand Injuries

Figure 2: Mary Albury-Noyes

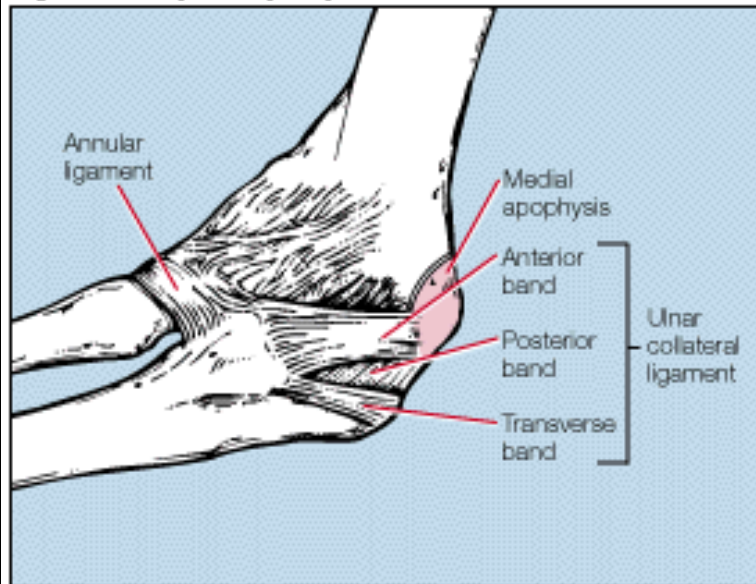


Figure 2. The primary ligamentous stabilizer of the elbow in any age thrower is the anterior band of the ulnar collateral ligament (UCL). Chronic valgus distraction during pitching and throwing can partially separate the medial apophysis from the humerus (double line). If the medial apophysis avulses from the epicondyle, the UCL remains intact but cannot provide medial support.

- Medial Collateral Ligament Sprain
 - Mechanism
 - Valgus Loading
 - Signs and Symptoms

Upper Arm, Elbow, Wrist and Hand Injuries

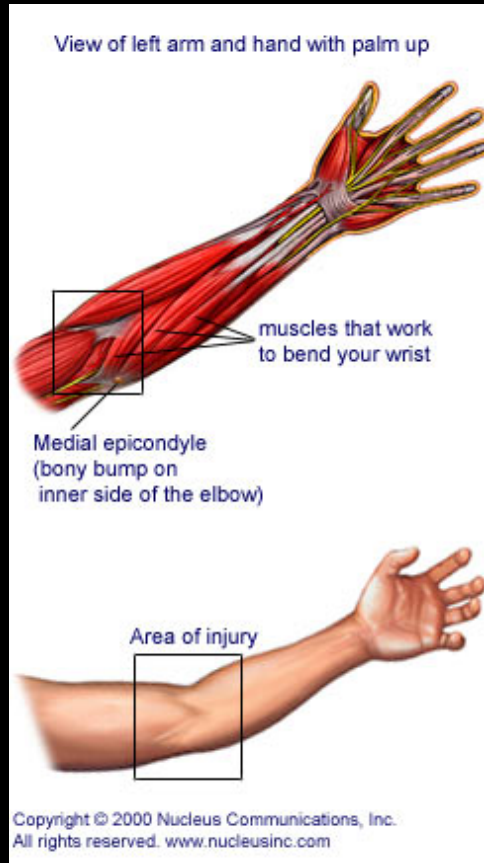


Figure 2: Mary Albury-Noyes

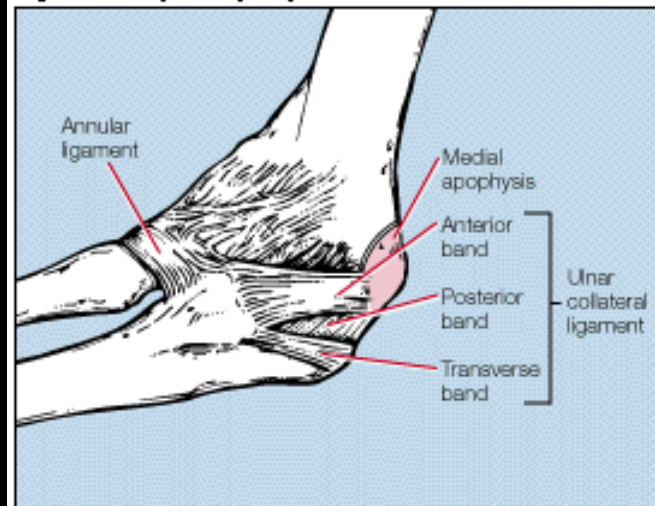
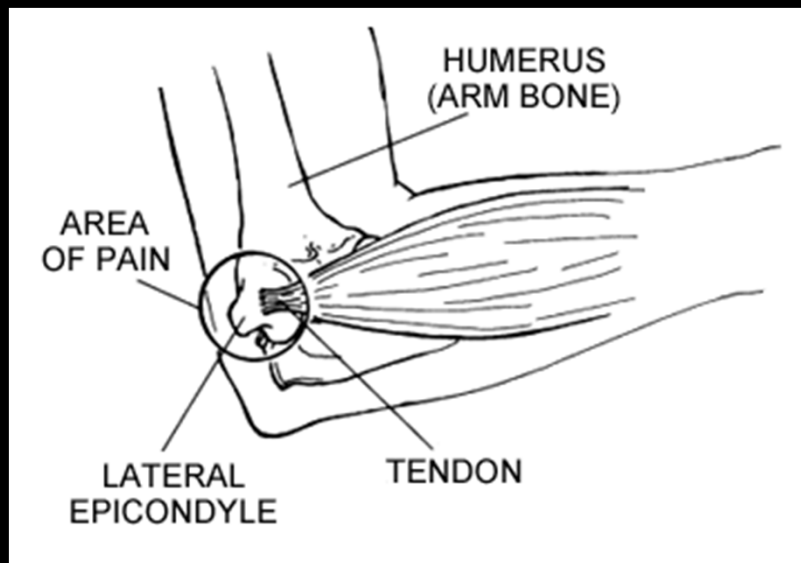


Figure 2. The primary ligamentous stabilizer of the elbow in any age thrower is the anterior band of the ulnar collateral ligament (UCL). Chronic valgus distraction during pitching and throwing can partially separate the medial apophysis from the humerus (double line). If the medial apophysis avulses from the epicondyle, the UCL remains intact but cannot provide medial support.

- Medial Epicondylitis
 - Little Leaguer's Elbow
 - Golfer's Elbow
 - Mechanism
 - Signs and Symptoms

Upper Arm, Elbow, Wrist and Hand Injuries



- Lateral Epicondylitis
 - Tennis Elbow
 - Mechanism
 - Signs and Symptoms

Upper Arm, Elbow, Wrist and Hand Injuries

- Contusions
 - Mechanism
 - Signs and Symptoms



Upper Arm, Elbow, Wrist and Hand Injuries

- Distal Biceps Tendon Rupture

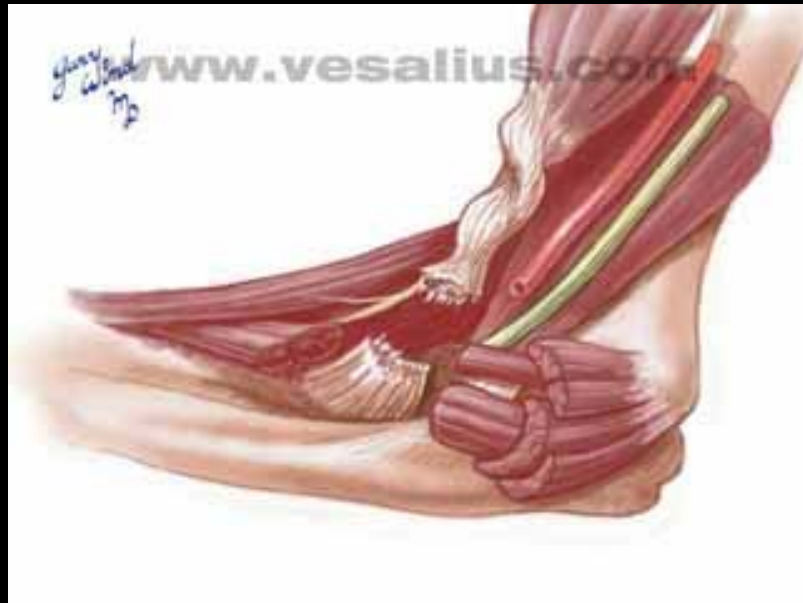

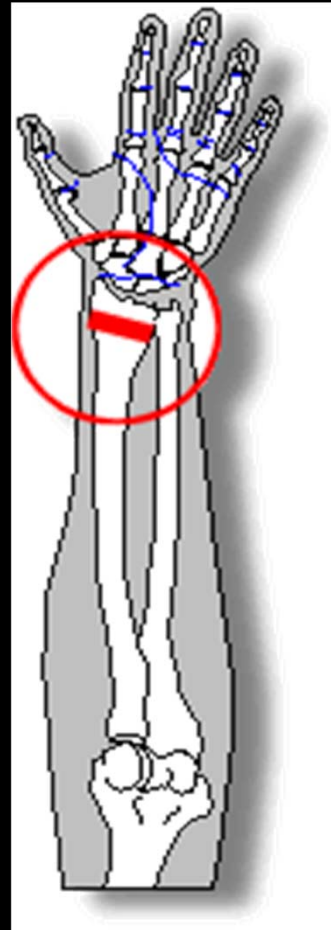
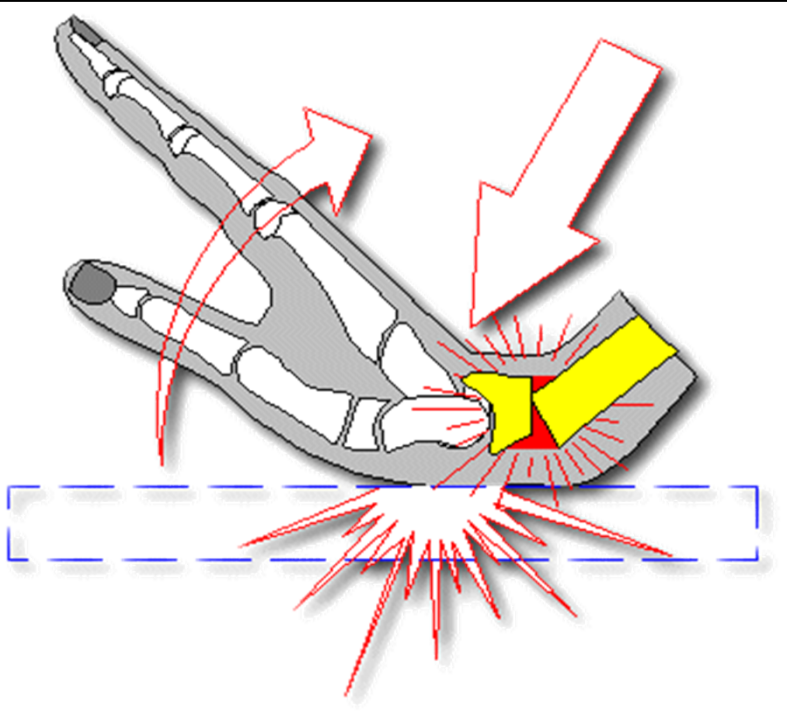
Figure 2: Courtesy of Amy M. Carter, MD

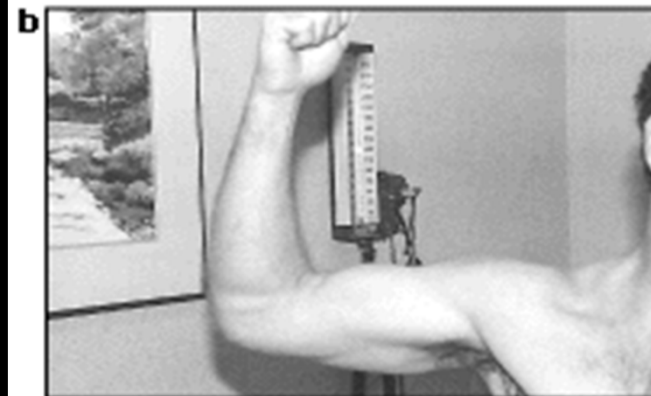
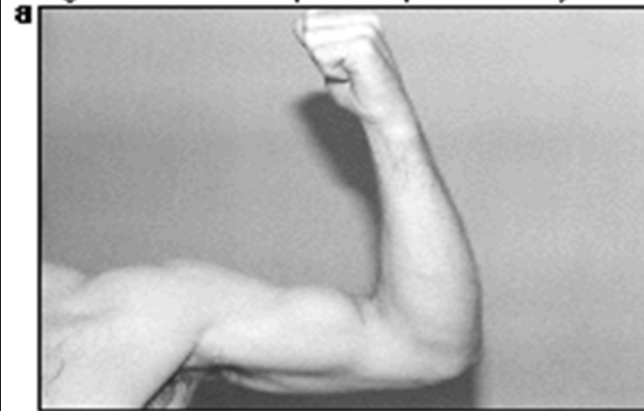
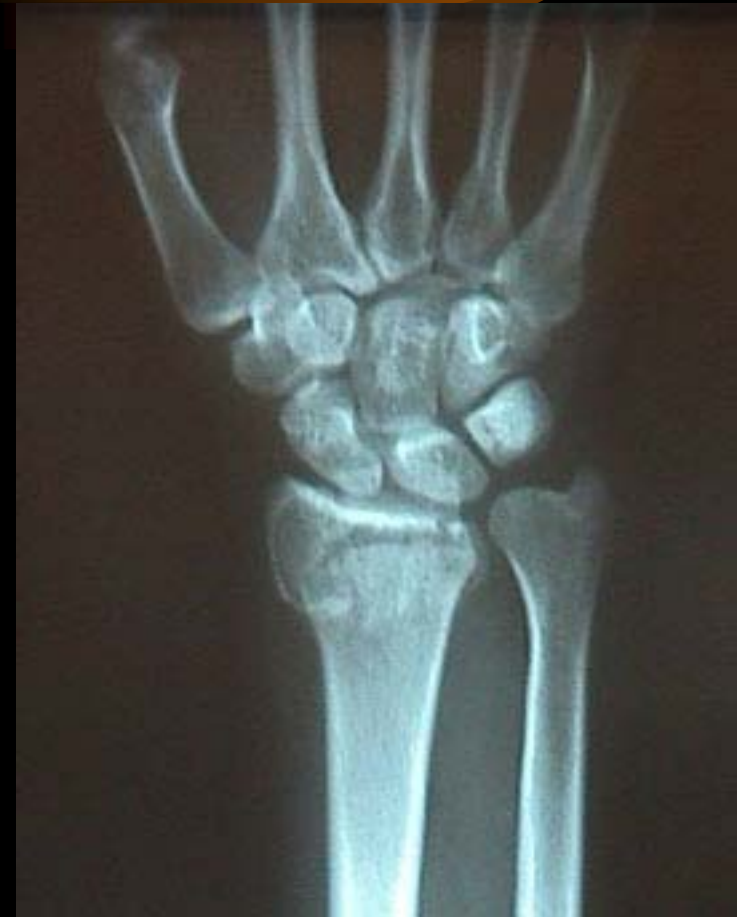Figure 2. The deformity of the patient's injured left biceps (a) is noticeable when compared with the normal right biceps (b).

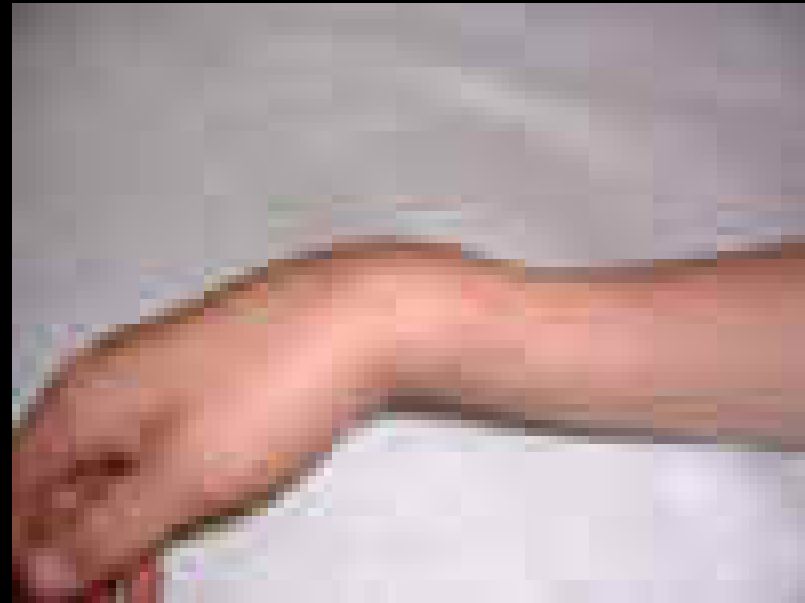Upper Arm, Elbow, Wrist and Hand Injuries

- Colles Fracture
 - Mechanism
 - Fall on outstretched arm



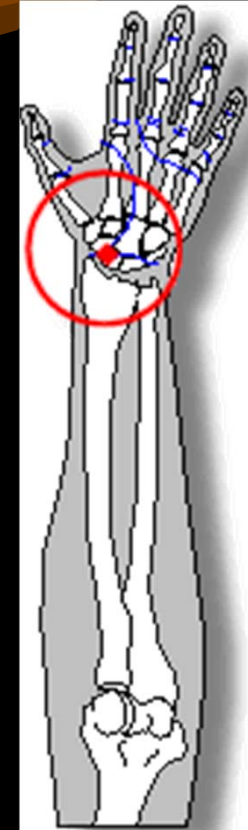
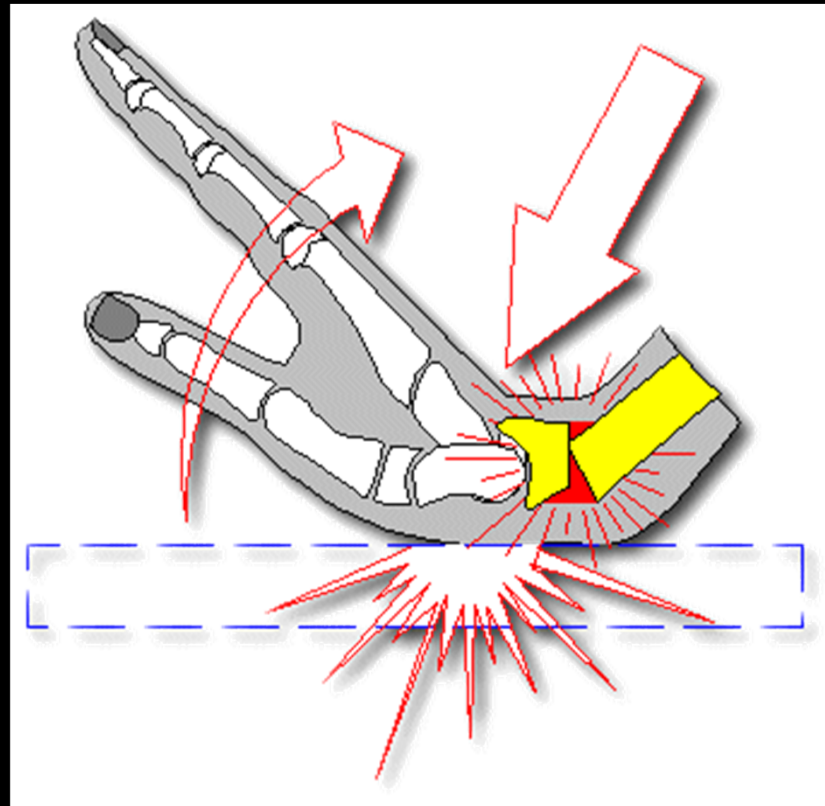
Upper Arm, Elbow, Wrist and Hand Injuries

- Colles Fracture
 - Mechanism
 - Fall on outstretched arm
 - Signs and Symptoms
 - Silver Fork Deformity



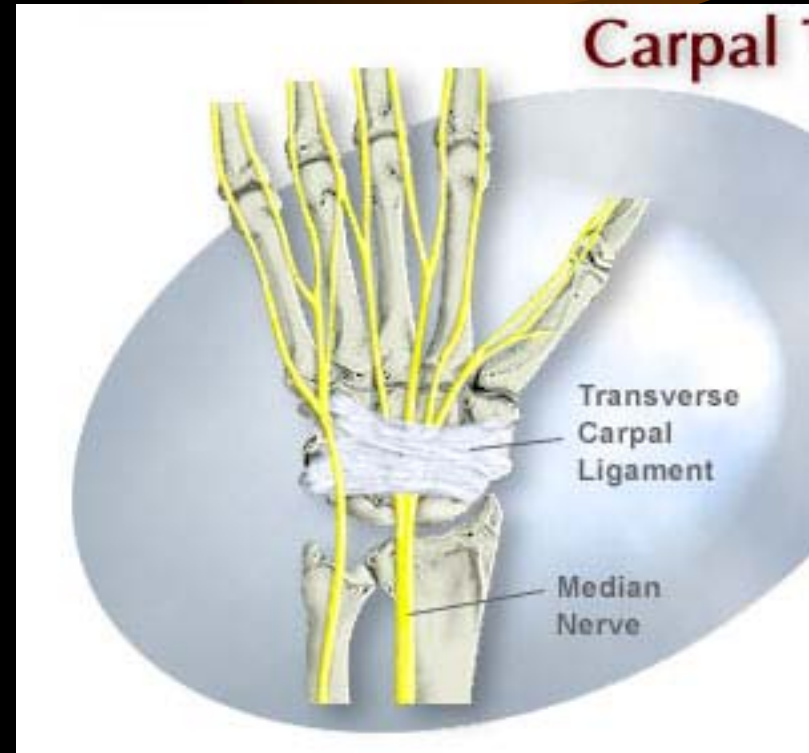
Upper Arm, Elbow, Wrist and Hand Injuries

- Scaphoid Fracture
 - Mechanism
 - Falling on outstretched arm
 - Signs and Symptoms
 - Pain in Anatomical Snuff Box

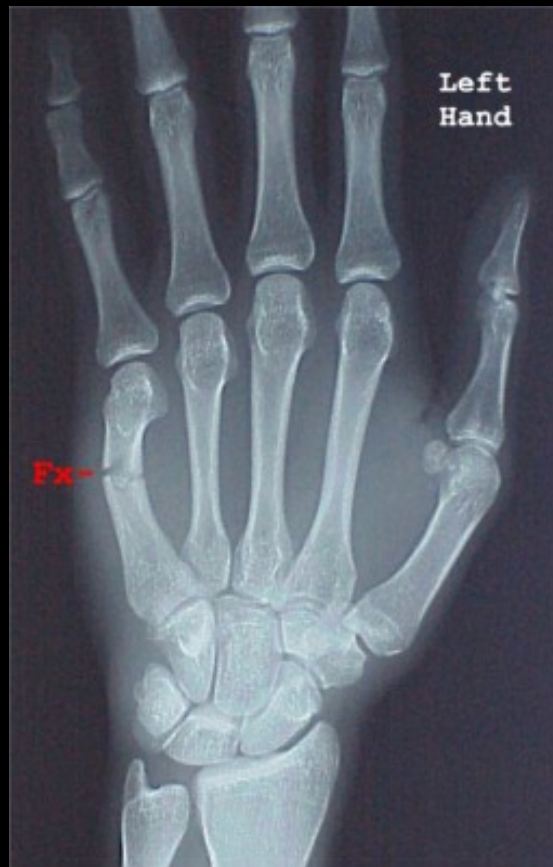

Upper Arm, Elbow, Wrist and Hand Injuries

- Carpal Tunnel Syndrome
 - Mechanism
 - Repetitive flexion/extension
 - Signs and Symptoms
 - Tingling
 - AROM
 - PROM
 - RROM

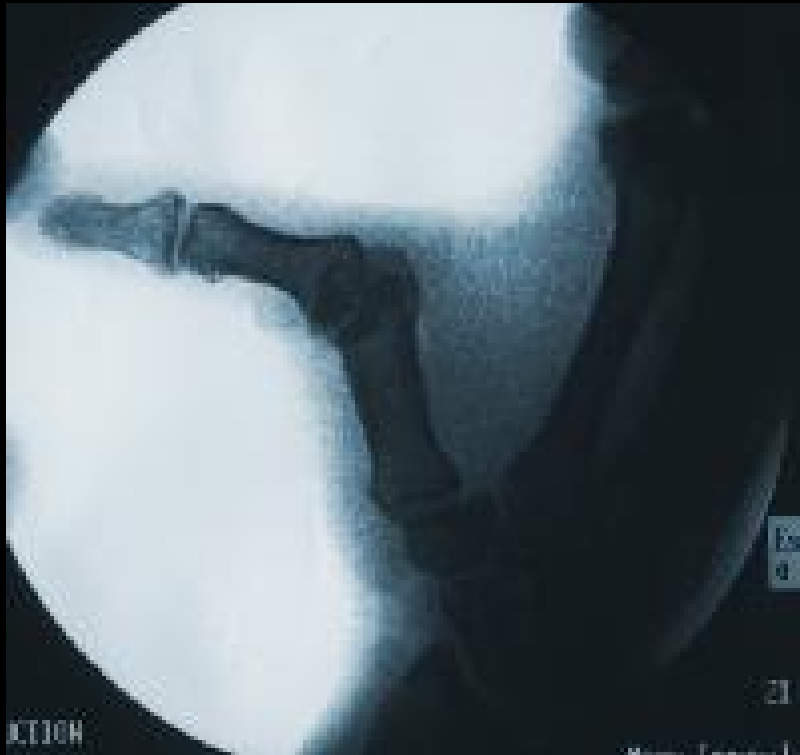

Upper Arm, Elbow, Wrist and Hand Injuries



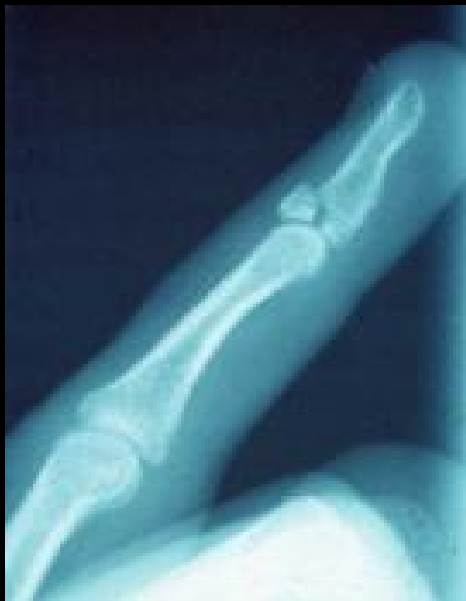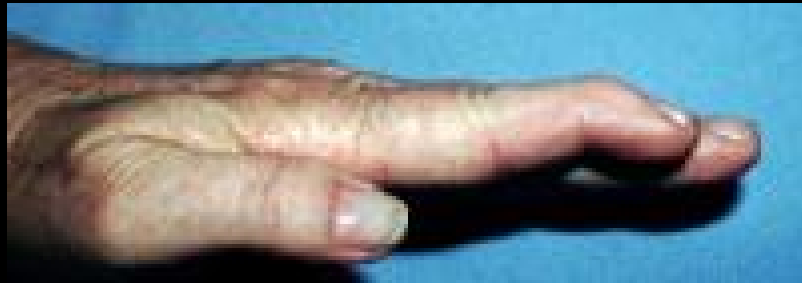- Boxer's Fracture
 - Injury to 5th metacarpal

Upper Arm, Elbow, Wrist and Hand Injuries



- Gamekeeper's Thumb
 - Injury to Ulnar Collateral Ligament of the Thumb
 - Mechanism
 - Signs and Symptoms

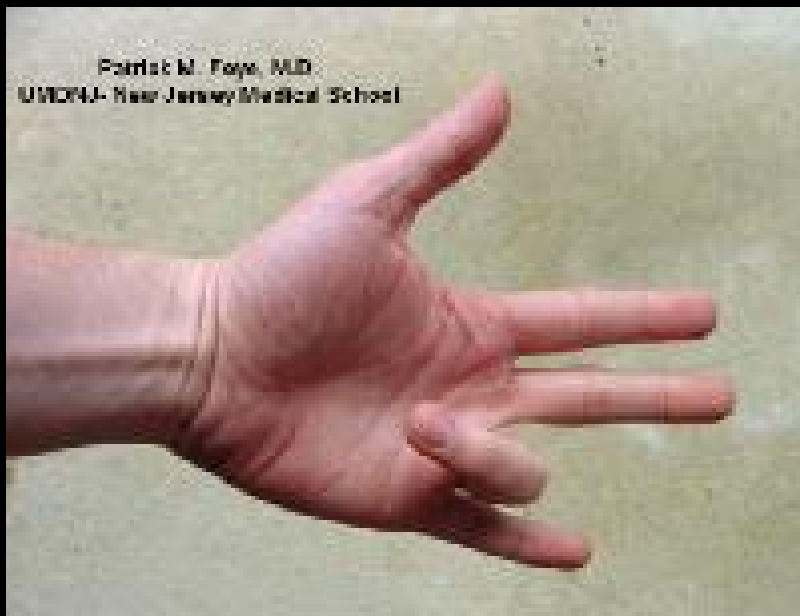Upper Arm, Elbow, Wrist and Hand Injuries



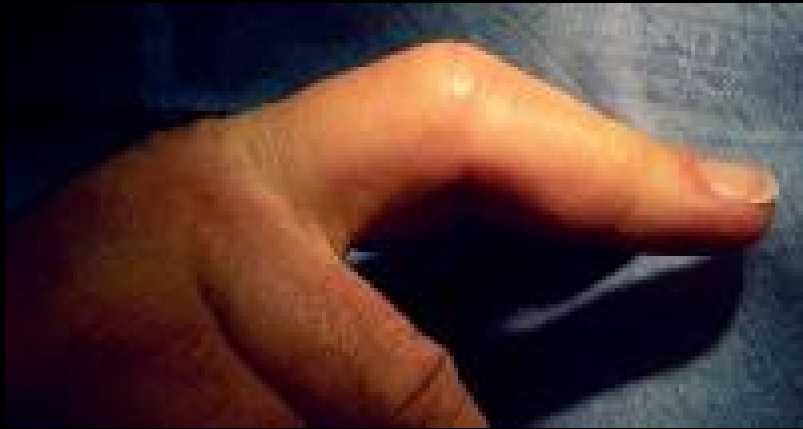- Mallet Finger
 - Injury to extensor tendon
 - Mechanism
 - Signs and Symptoms
 - Flexion deformity

Upper Arm, Elbow, Wrist and Hand Injuries

- Jersey Finger
 - Injury to Flexor Digitorum Profundus
 - Mechanism
 - Signs and Symptoms



Upper Arm, Elbow, Wrist and Hand Injuries



- Boutonniere Deformity
 - Mechanism
 - Signs and Symptoms

