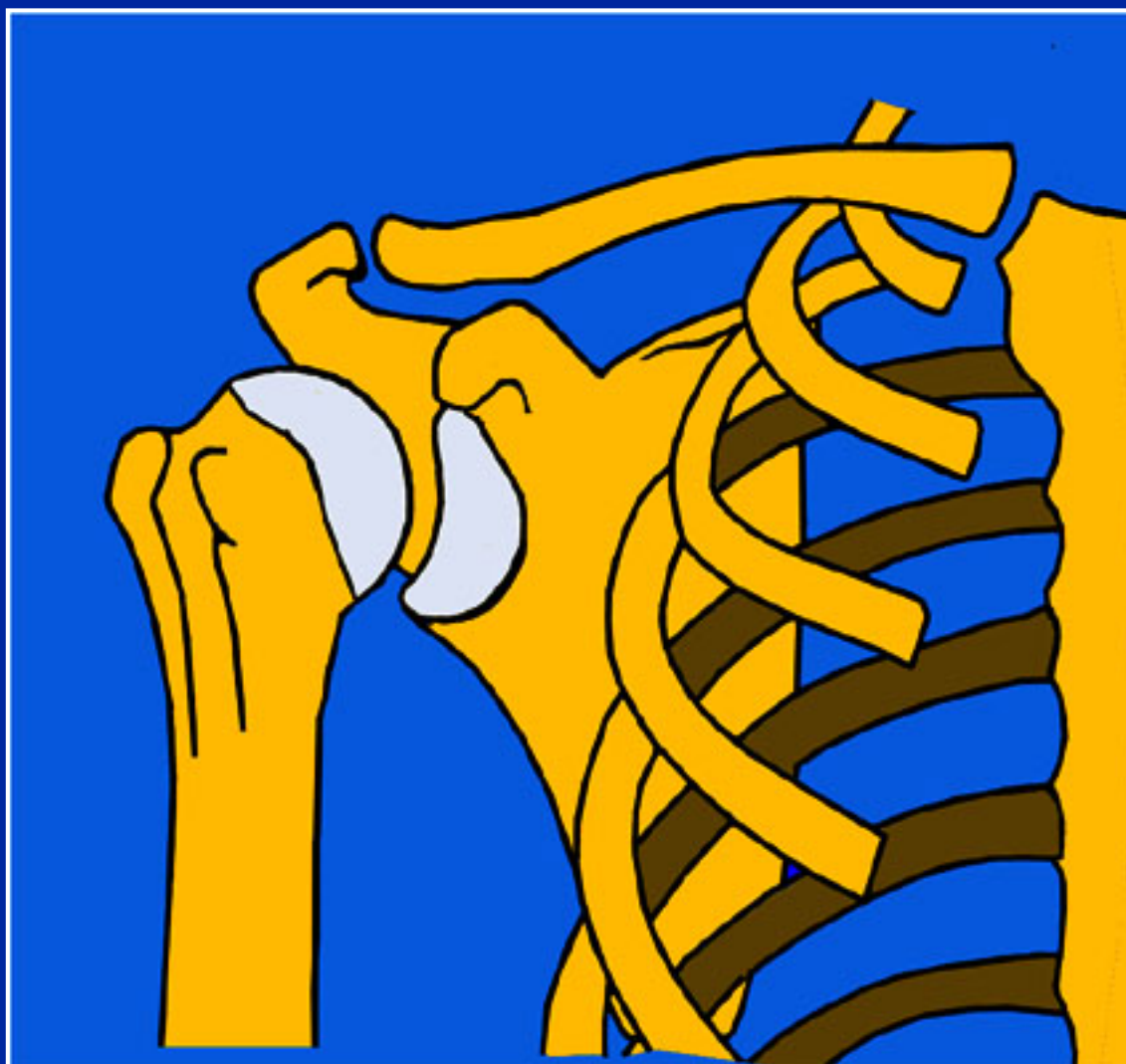
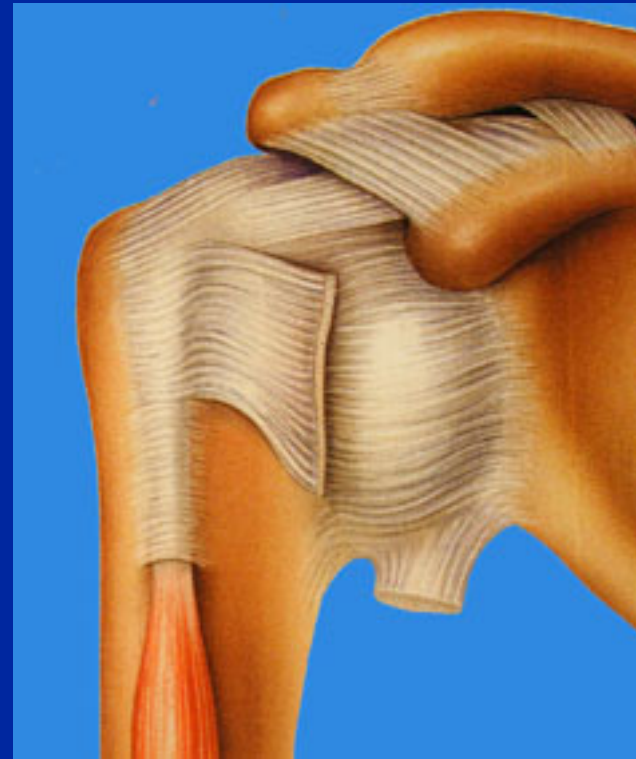
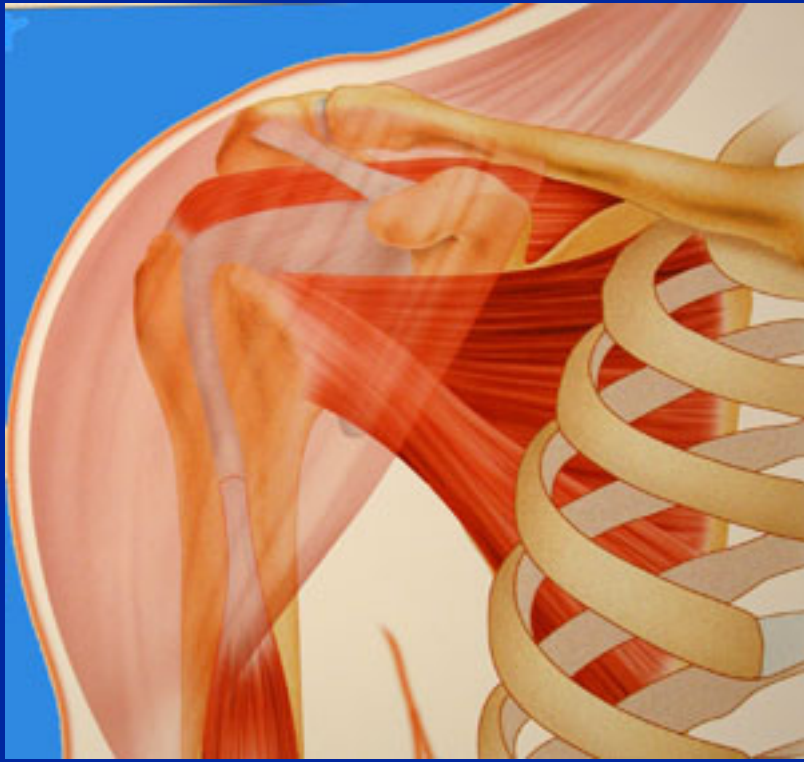


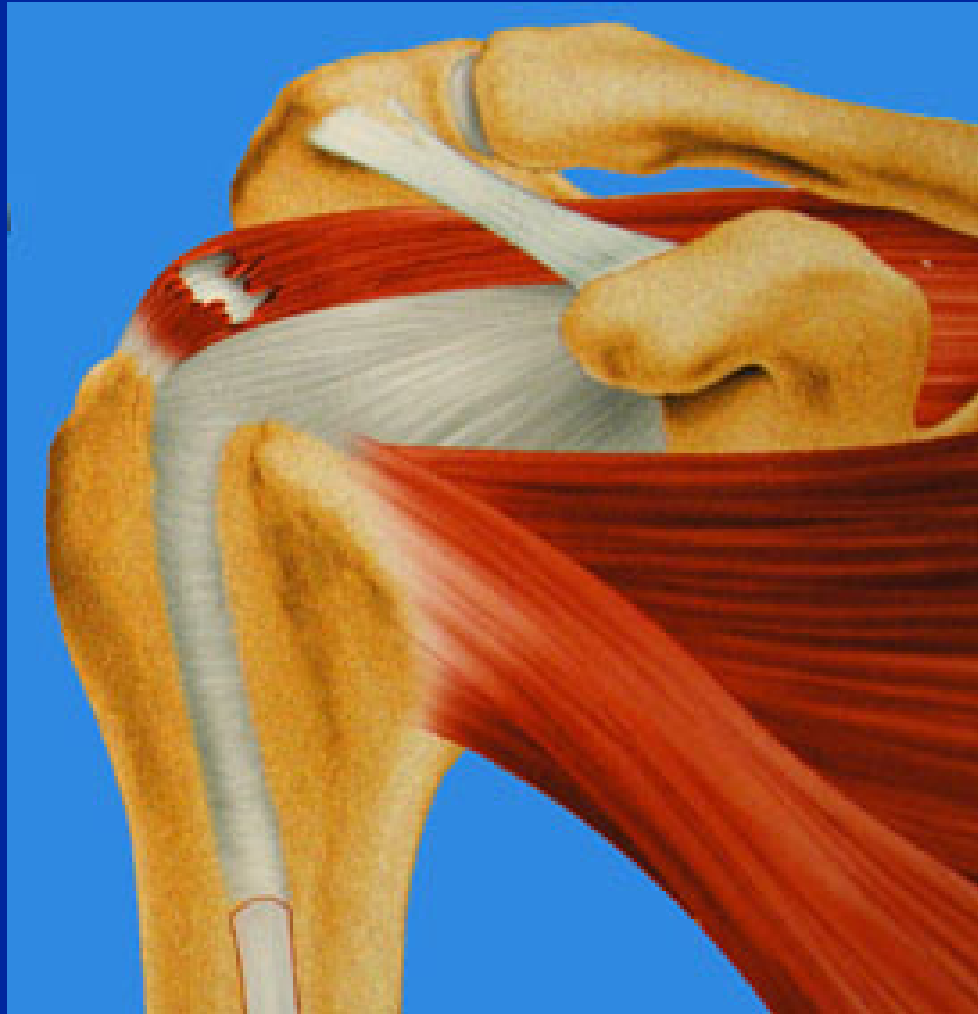Spalla

www.fisiokinesiterapia.biz

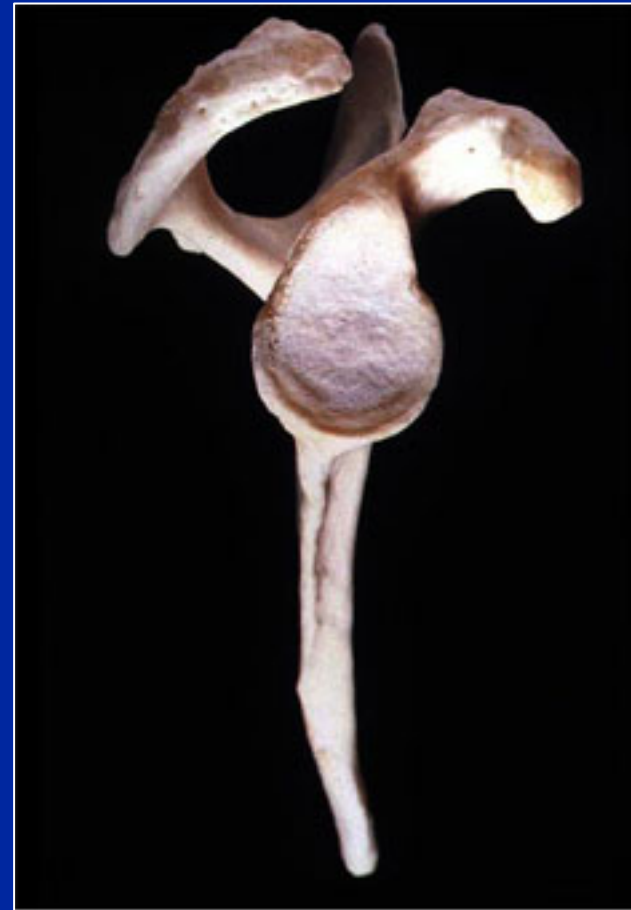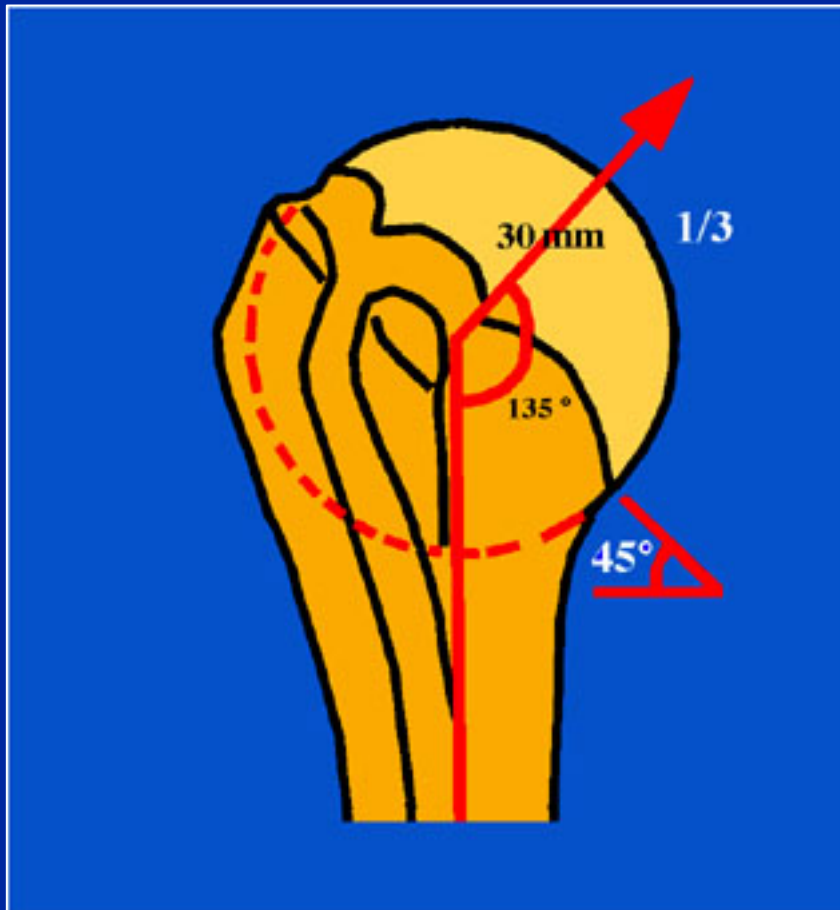
Cenni di anatomia



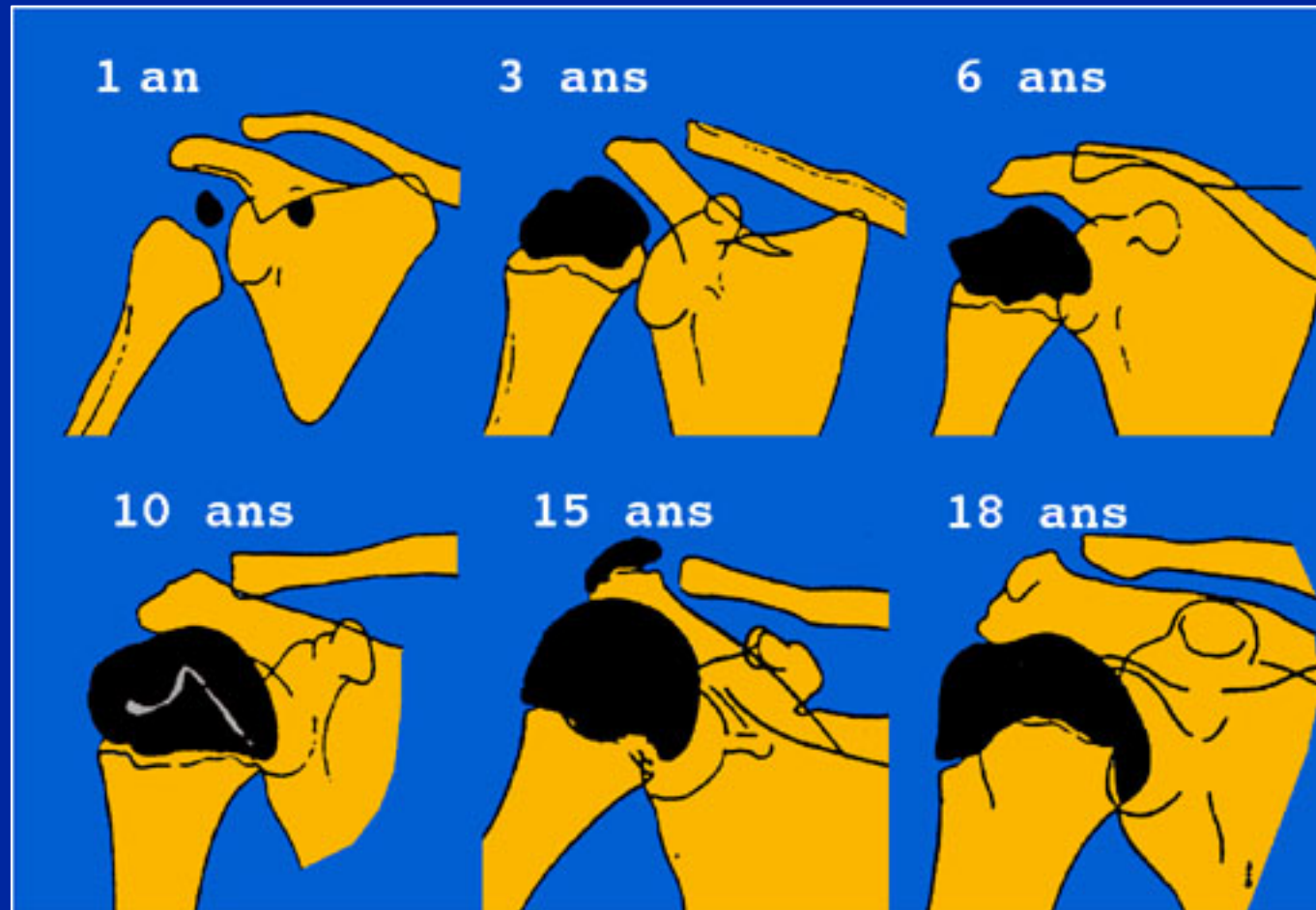


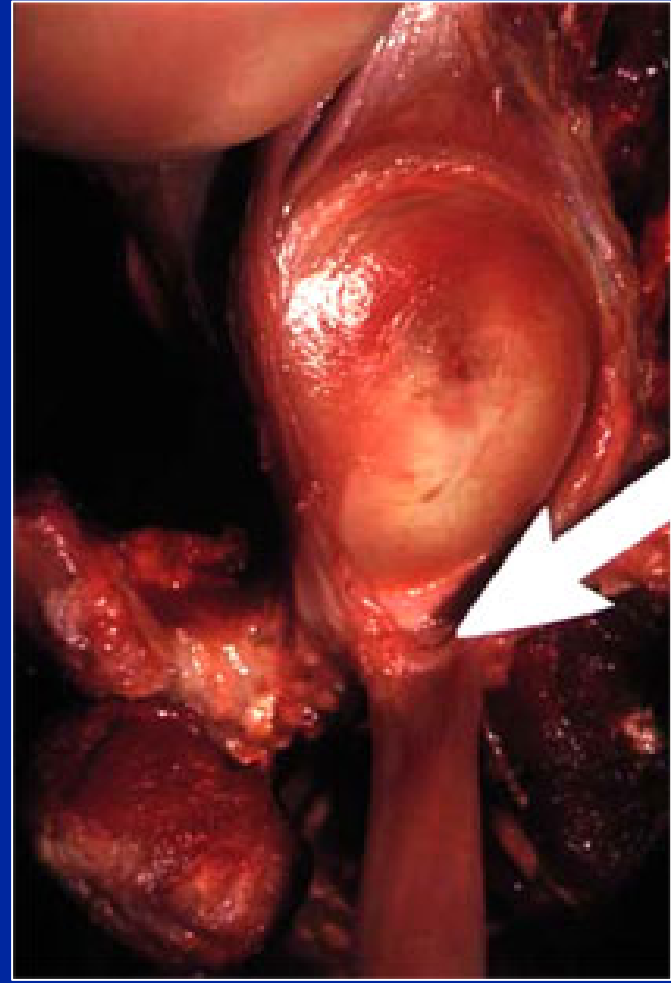
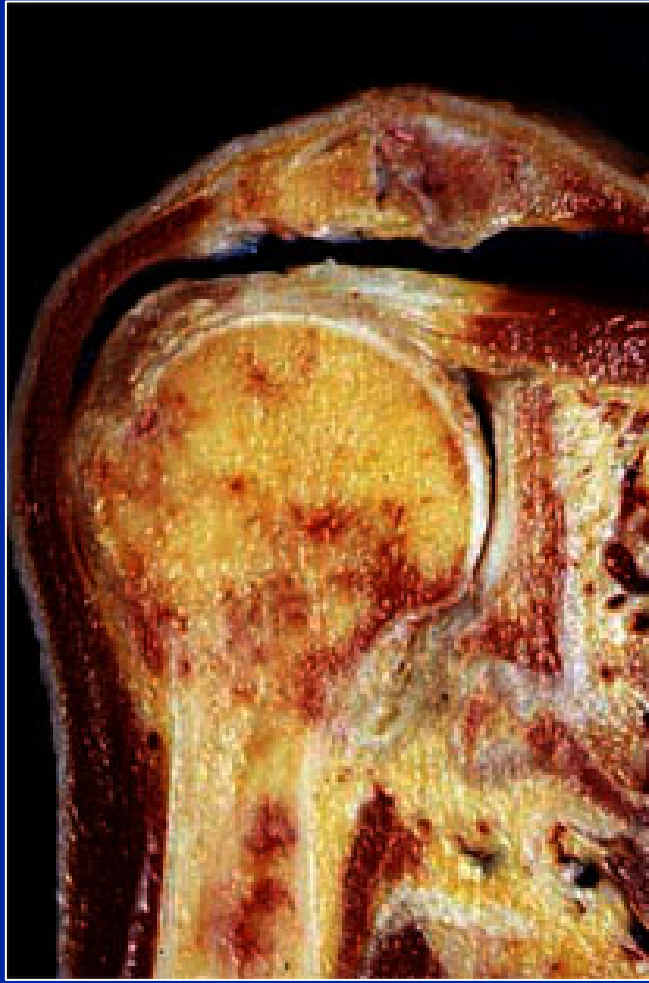
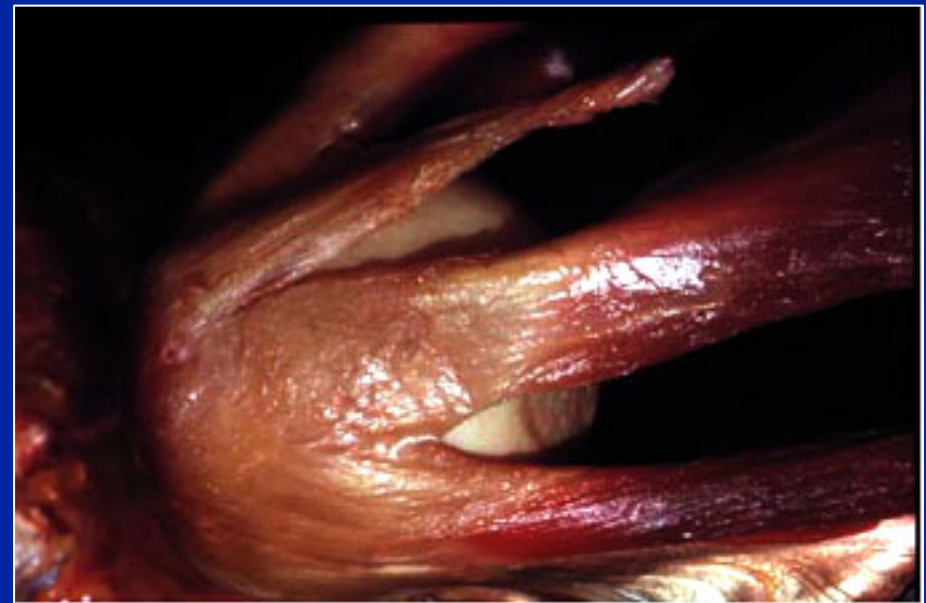
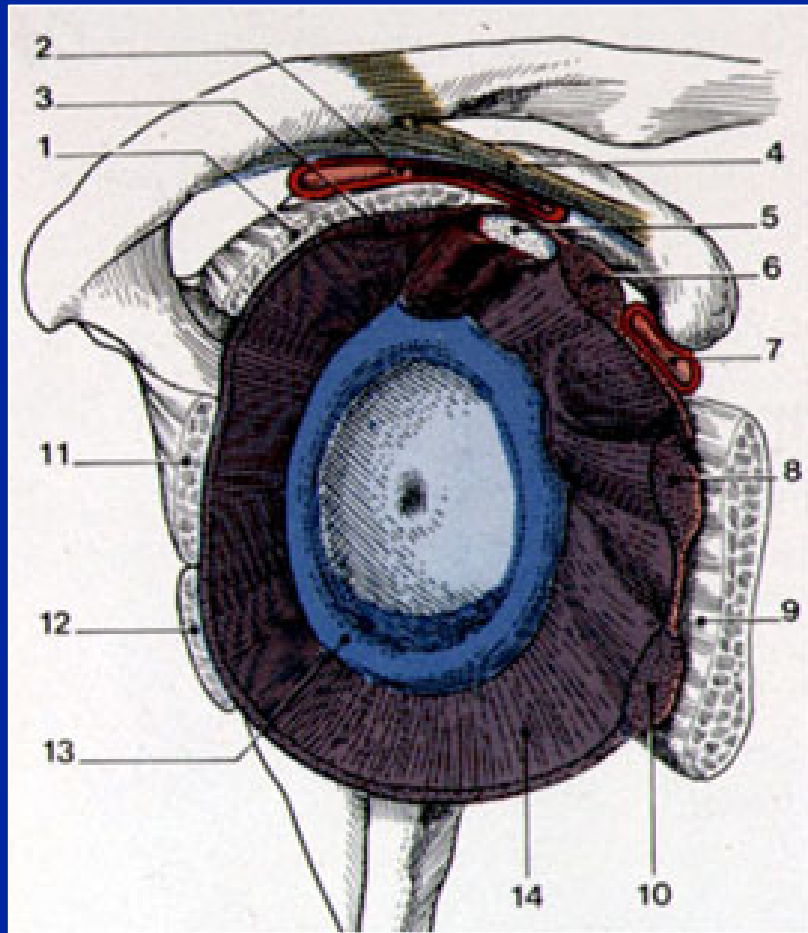
Cenni di anatomia



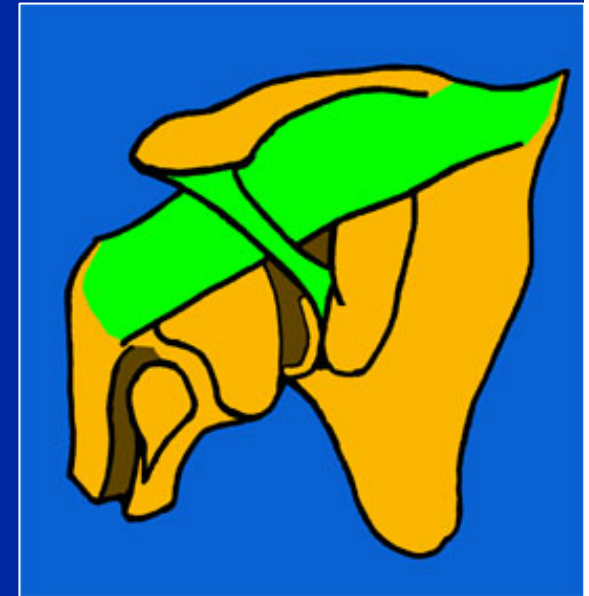
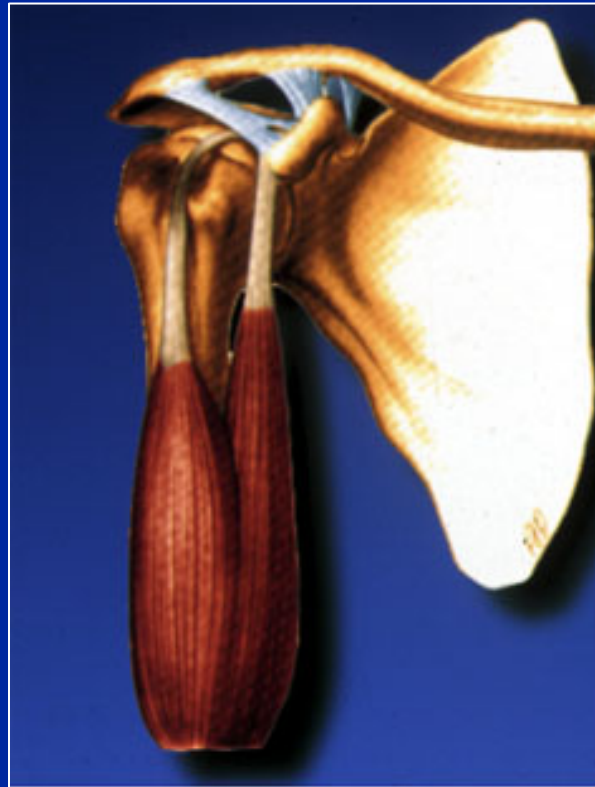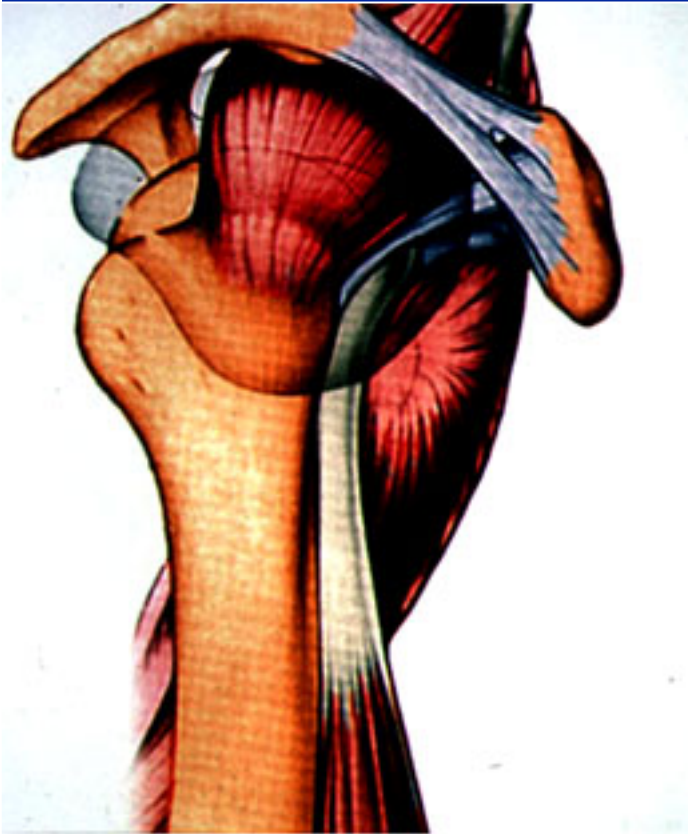
Sviluppo della spalla





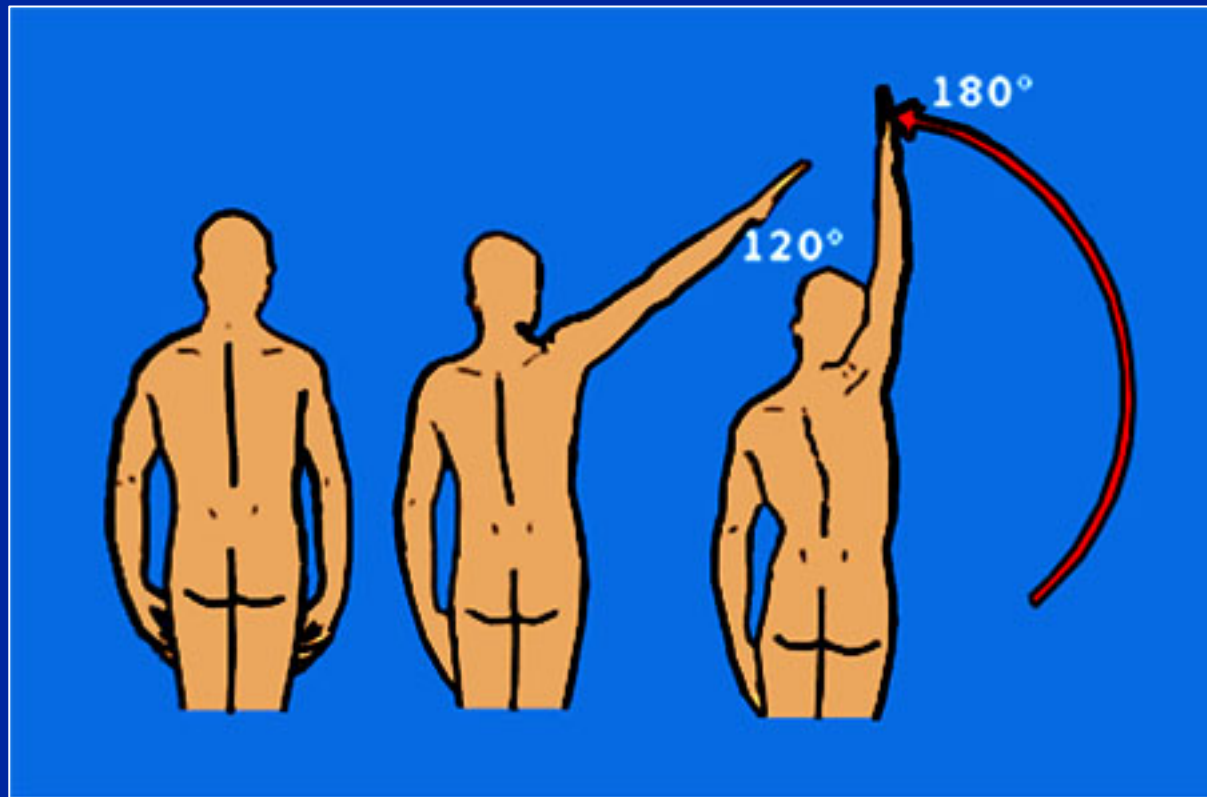


Cenni di anatomia

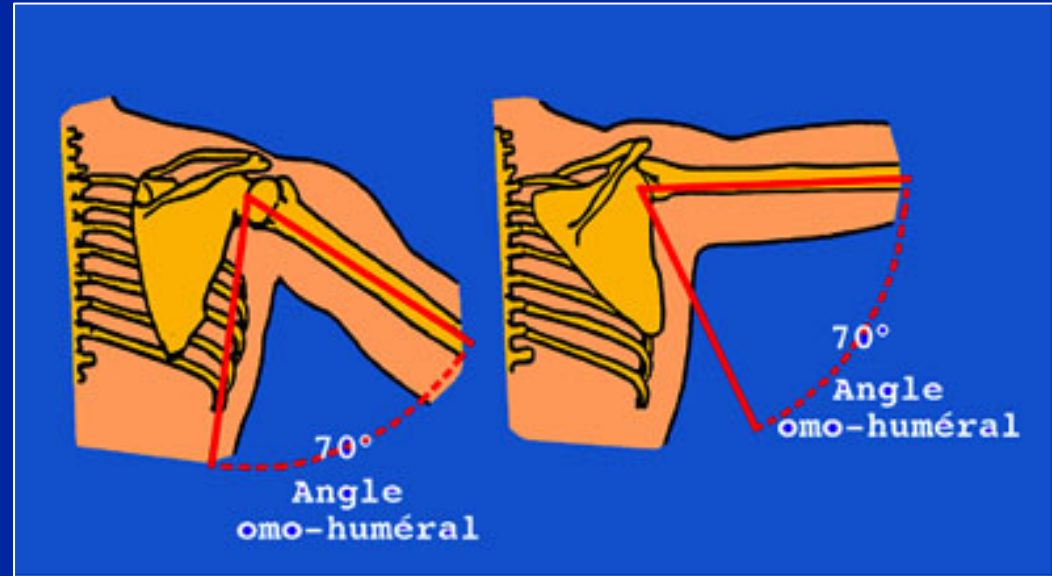
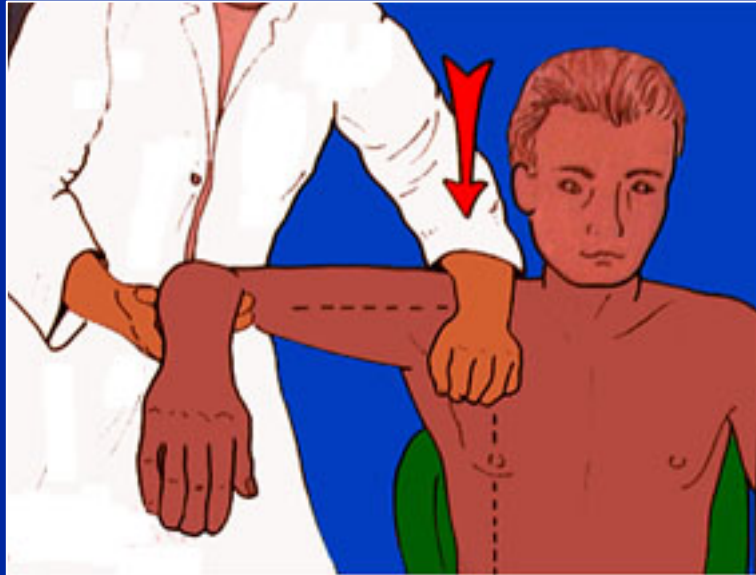


www.fisiokinesiterapia.biz

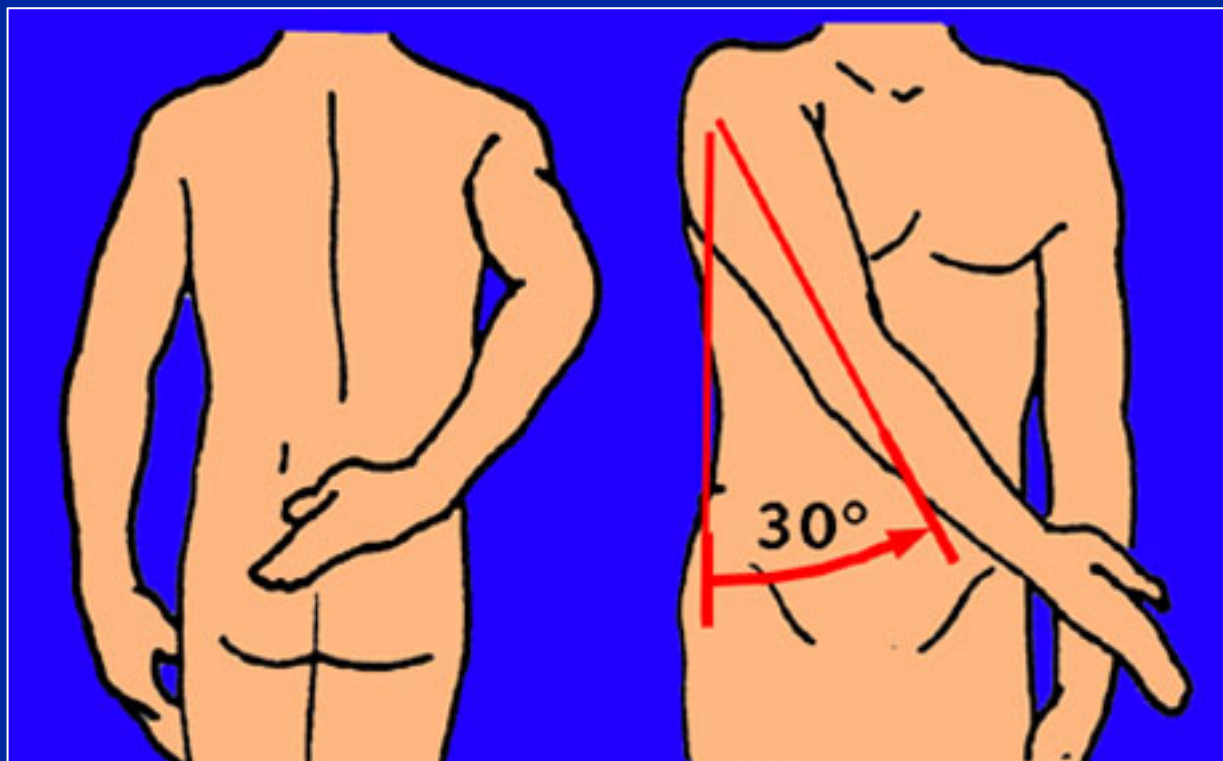
Mobilità



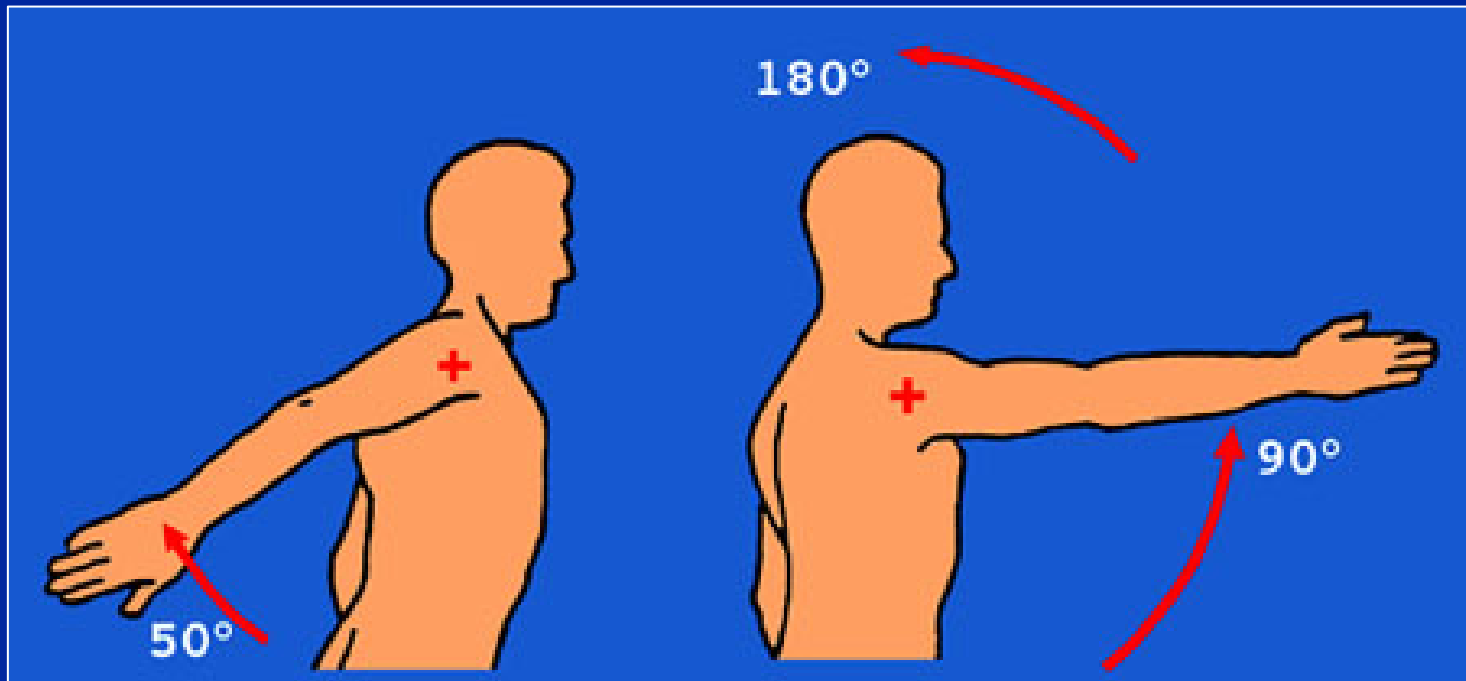
Abduzione



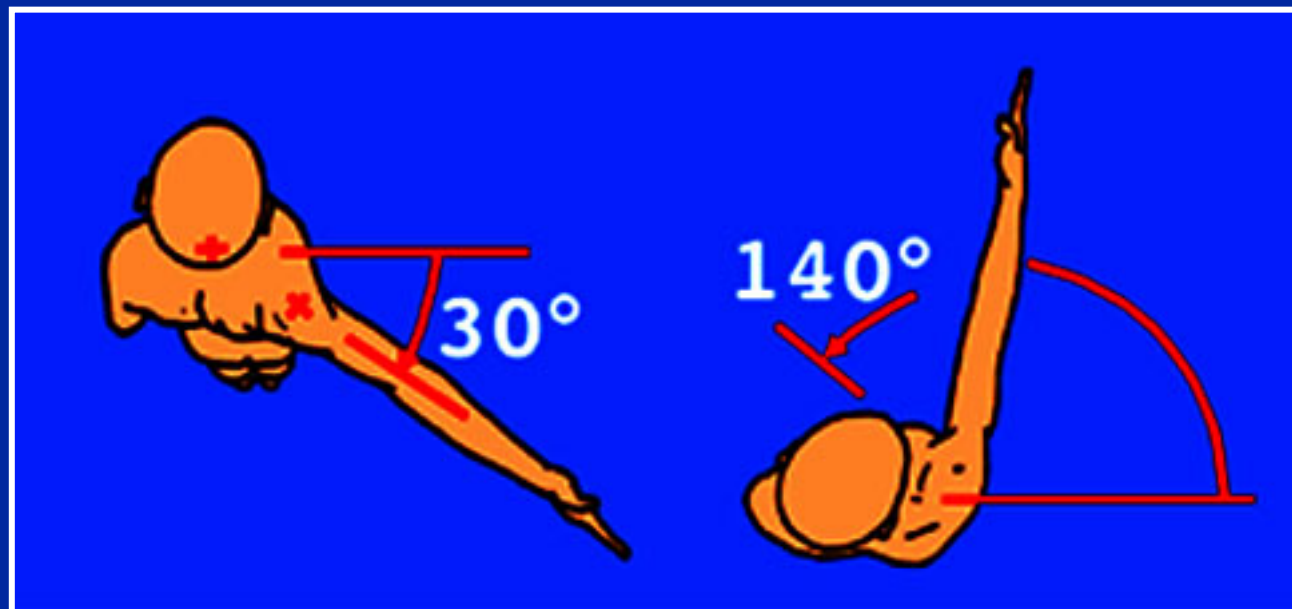
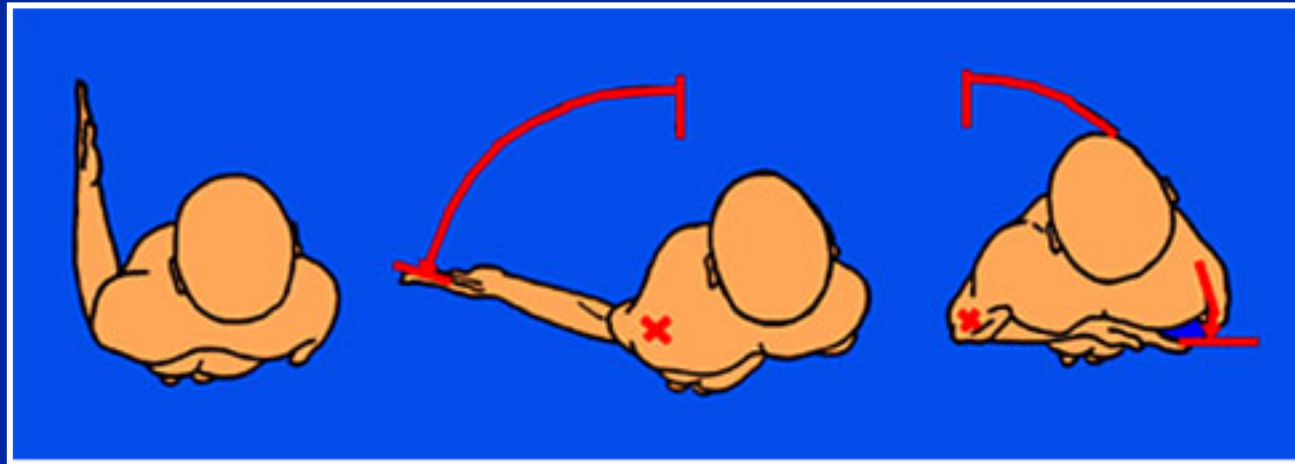
Adduzione



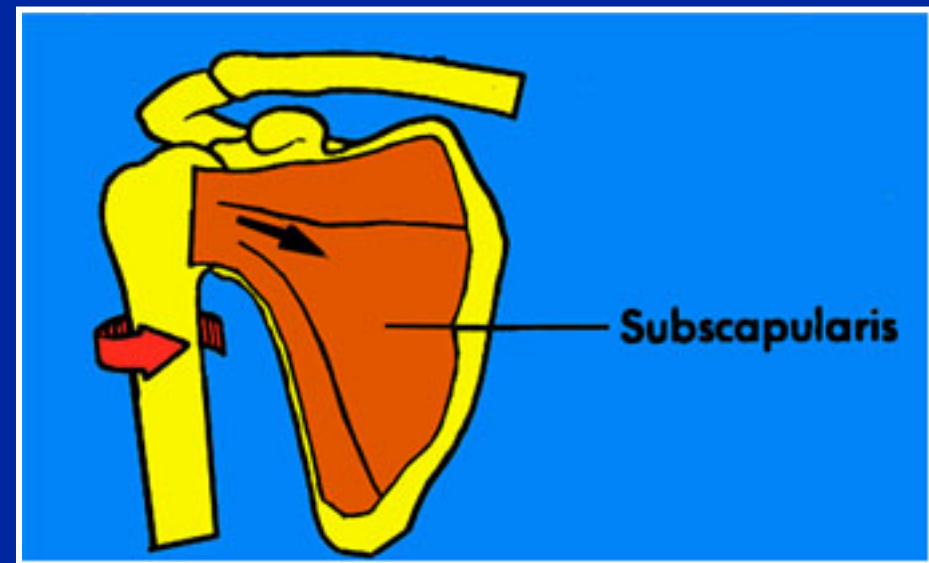
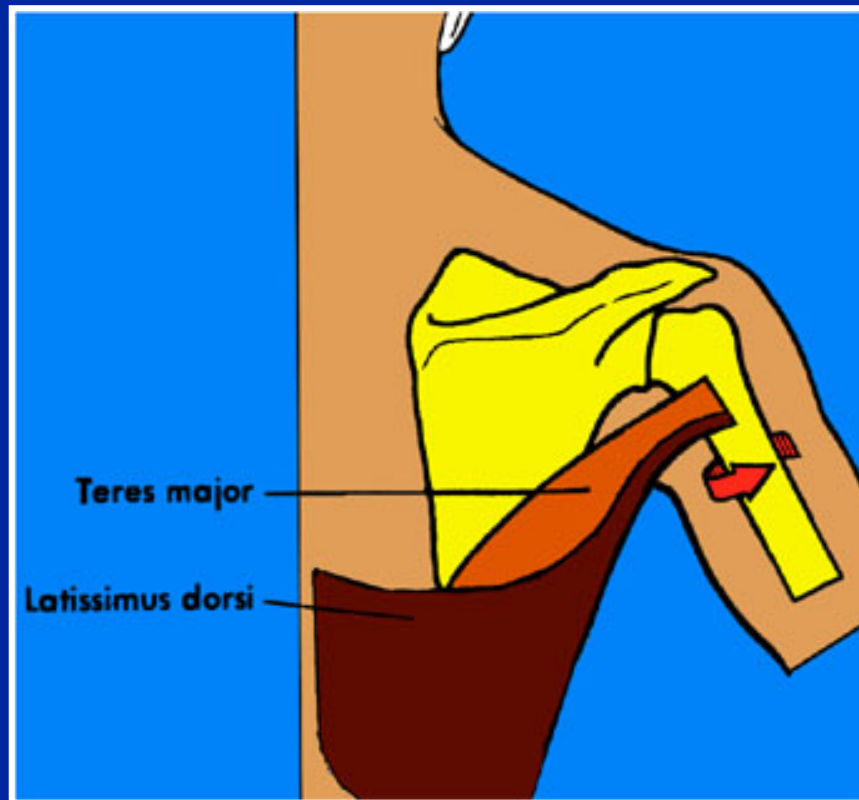
Retro e anti-versionsione



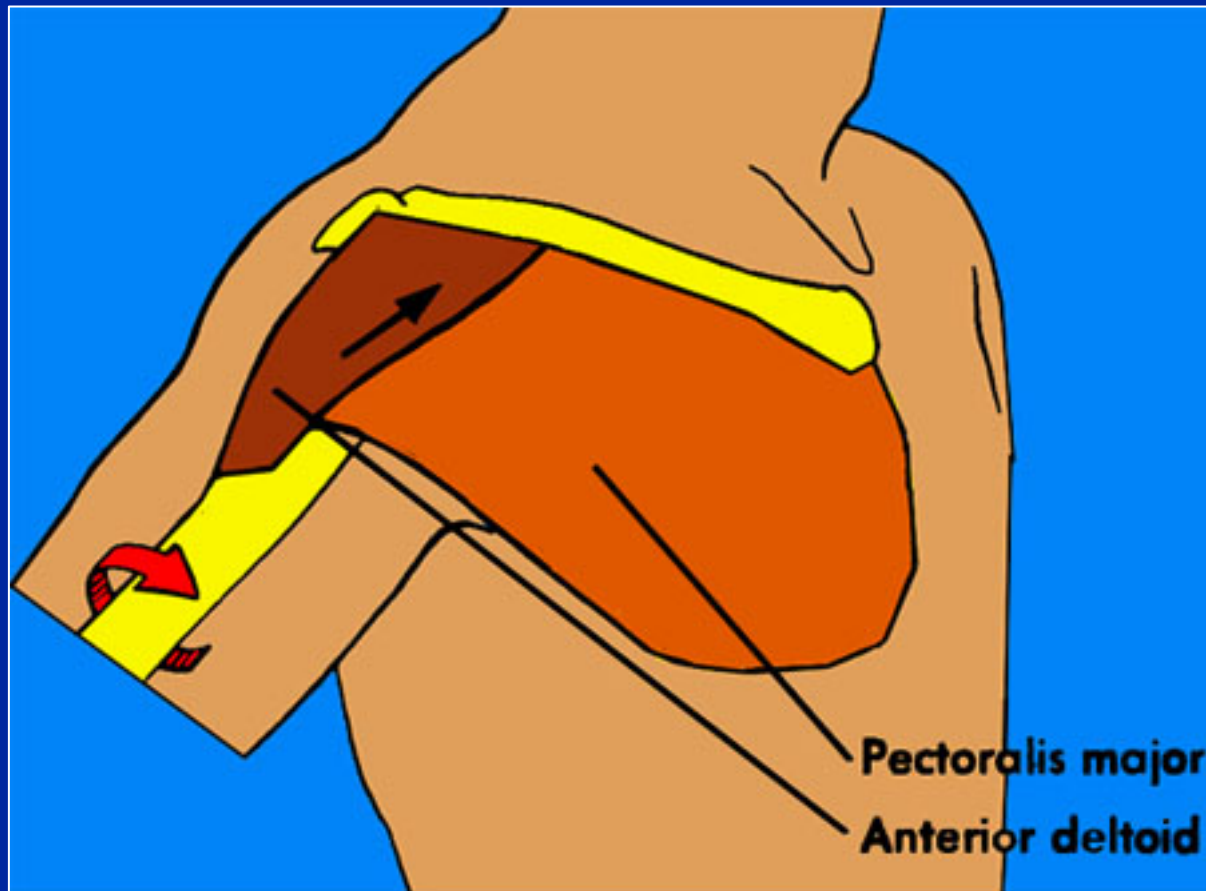
Rotazione



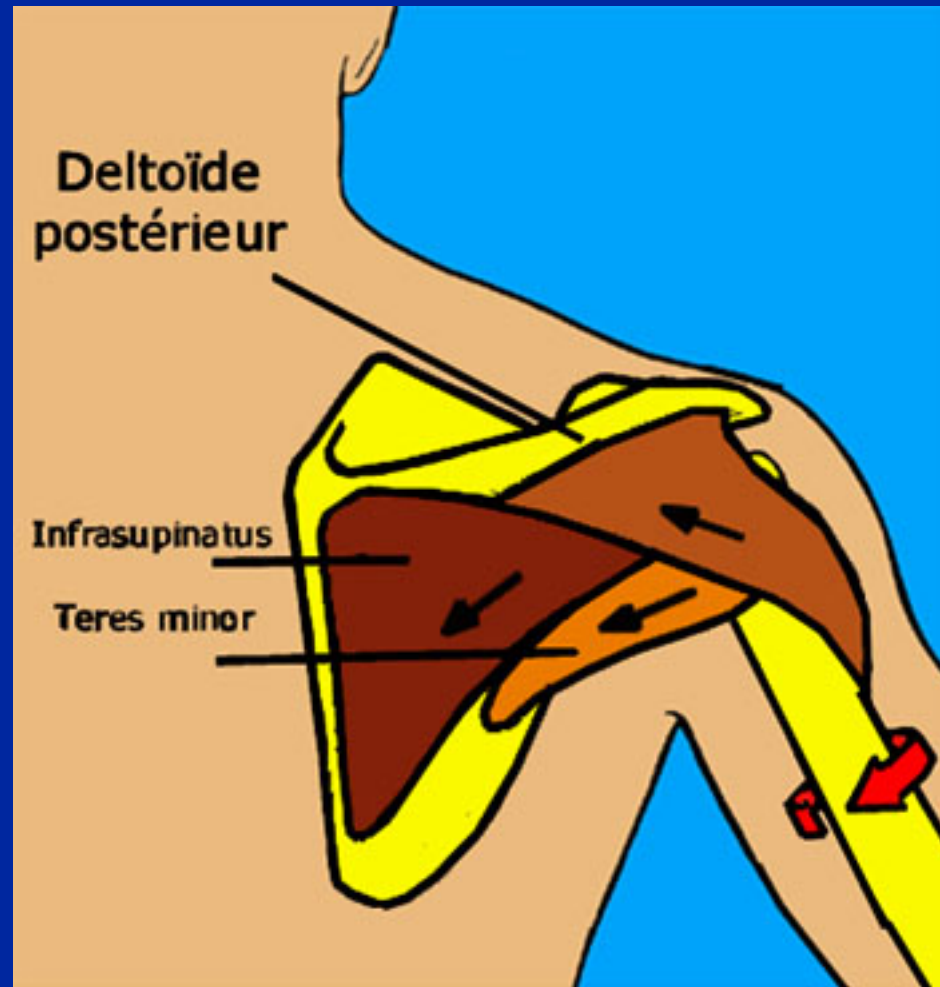
Rotazione interna



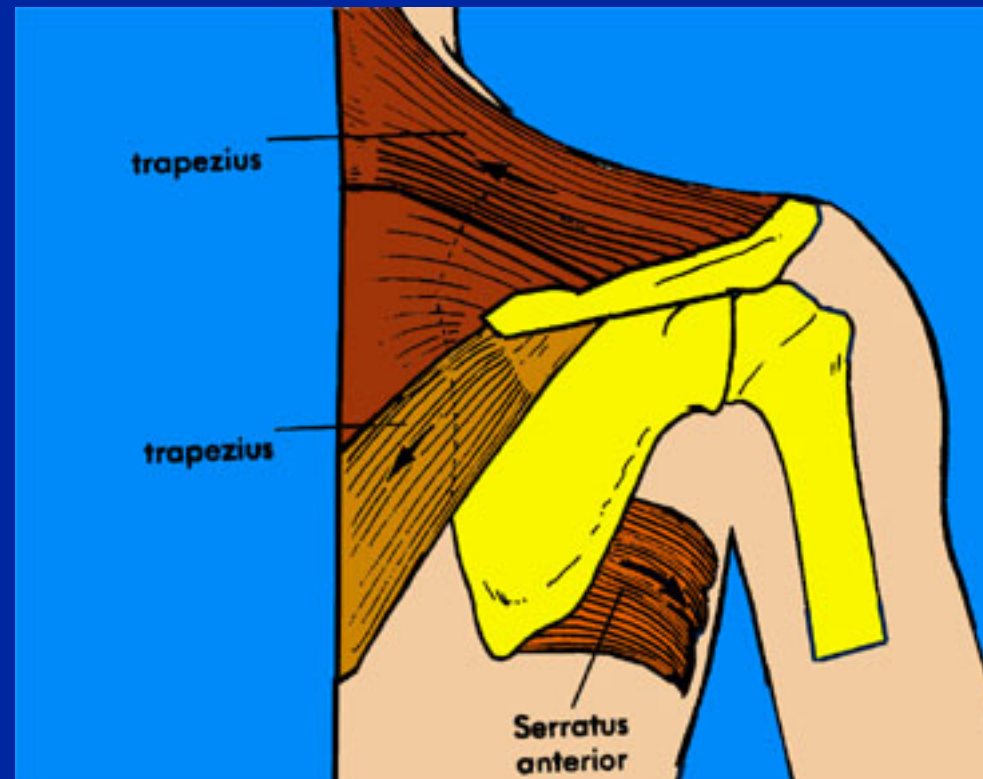
Rotazione interna



Rotazione esterna



Cenni di anatomia



www.fisiokinesiterapia.biz

Cenni di anatomia

