APPARATO LOCOMOTORE

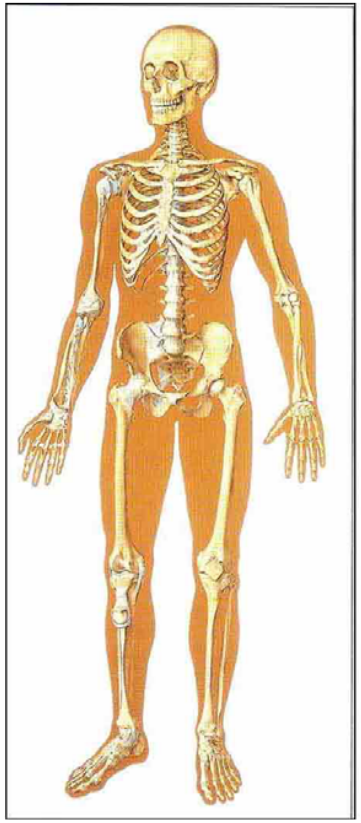

SISTEMA SCHELETRICO

SISTEMA MUSCOLARE

SORREGGE IL NOSTRO CORPO CONSENTENDOGLI IL MOVIMENTO

APPARATO LOCOMOTORE

- **SISTEMA SCHELETRICO**
- **SISTEMA MUSCOLARE**

www.fisiokinesiterapia.biz

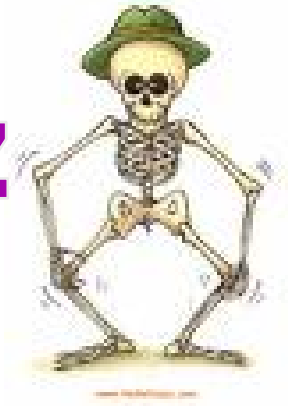

SISTEMA SCHELETRICO

E' L'INSIEME DELLE OSSA, DELLE CARILAGINI E DELLE ARTICOLAZIONI

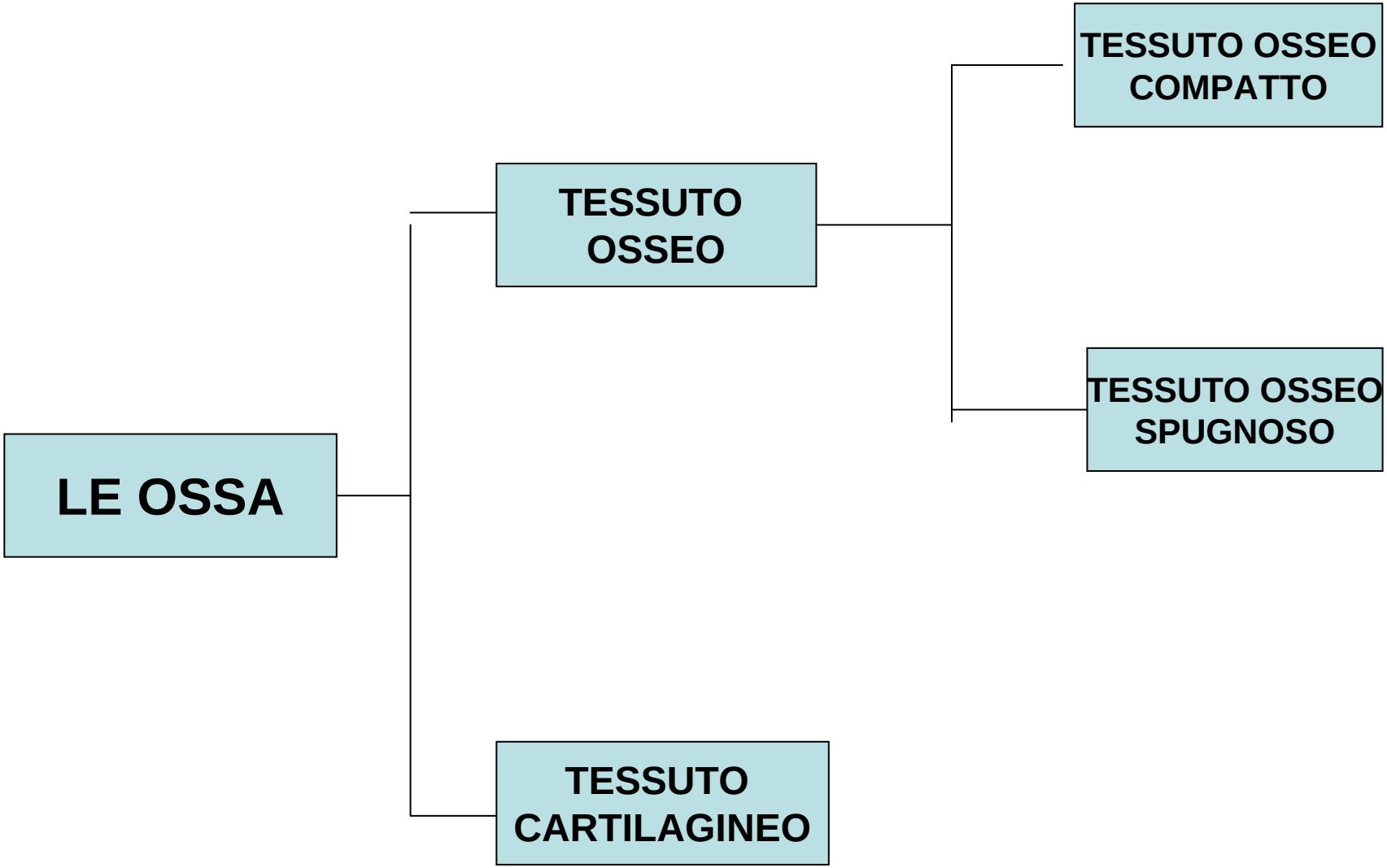
LE OSSA
TESSUTO OSSEO
TESSUTO OSSEO COMPATTO
TESSUTO OSSEO SPUGNOSO
TESSUTO CARTILAGINEO

TESSUTO OSSEO

LEGENDA

sostanza organica (30%)
sostanza inorganica (70%)

CELLULE

Cellule osteoprogenitrici

Osteoblasti

Osteoclasti

Osteociti

MATRICE EXTRACELLULARE

COMPONENTE FIBROSA

Collagene

SOSTANZA AMORFA FONDAMENTALE

Sostanza organica: osseina conferisce elasticità.

Sostanza inorganica: Sali minerali lo rendono rigido e duro

(idrossiapatite)

lcio

TESSUTO OSSEO COMPATTO

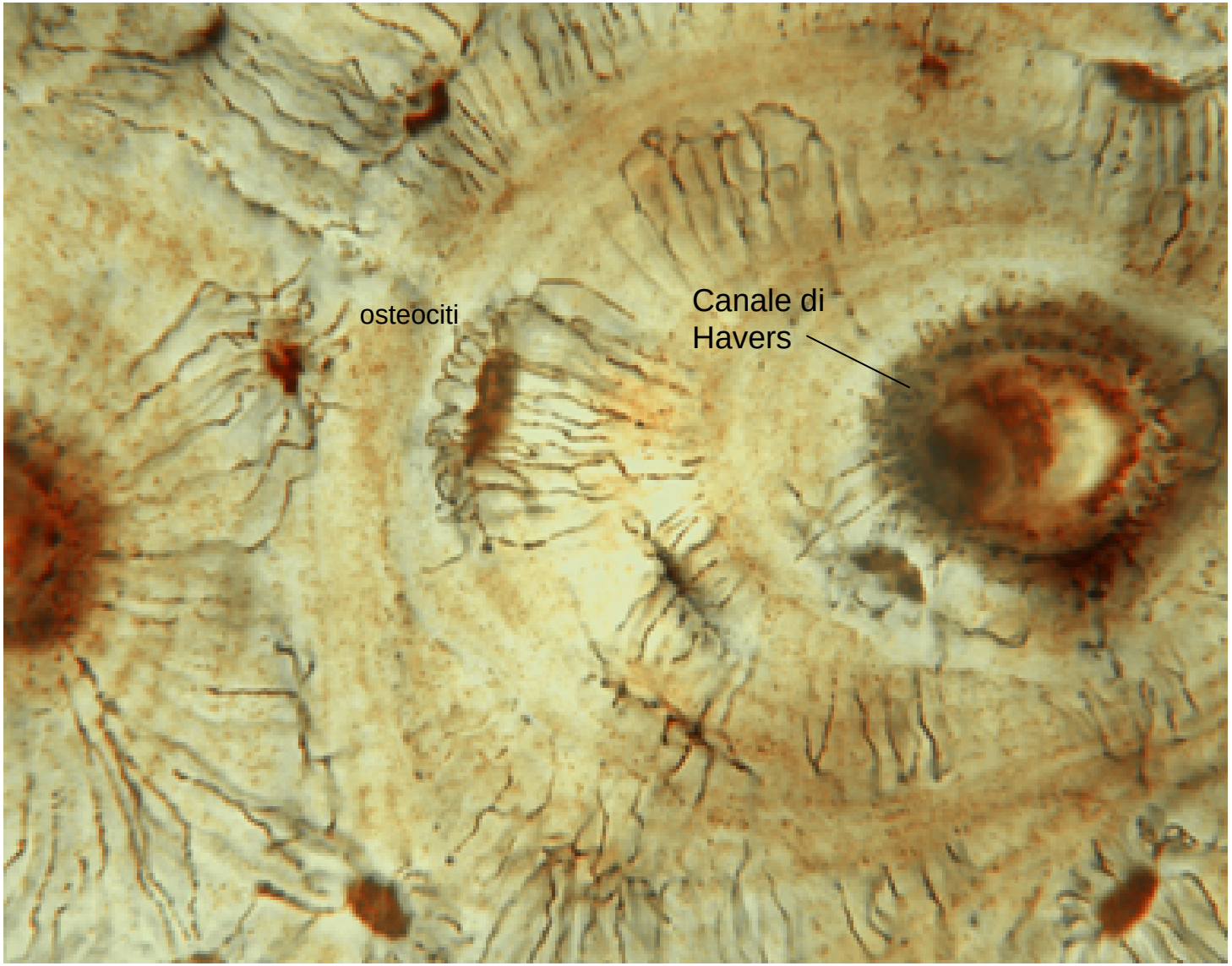

TESSUTO OSSEO COMPATTO

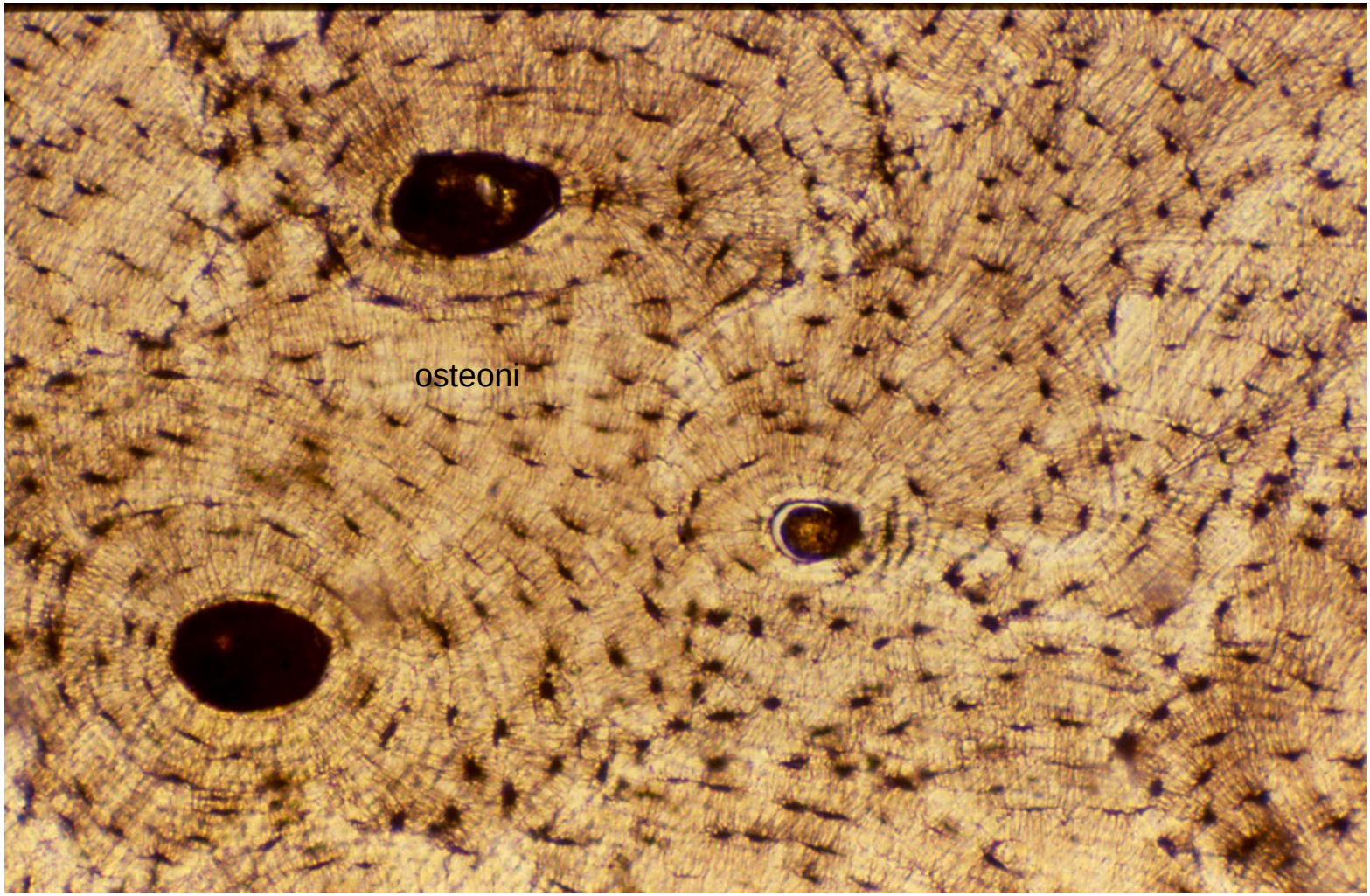

TESSUTO OSSEO SPUGNOSO

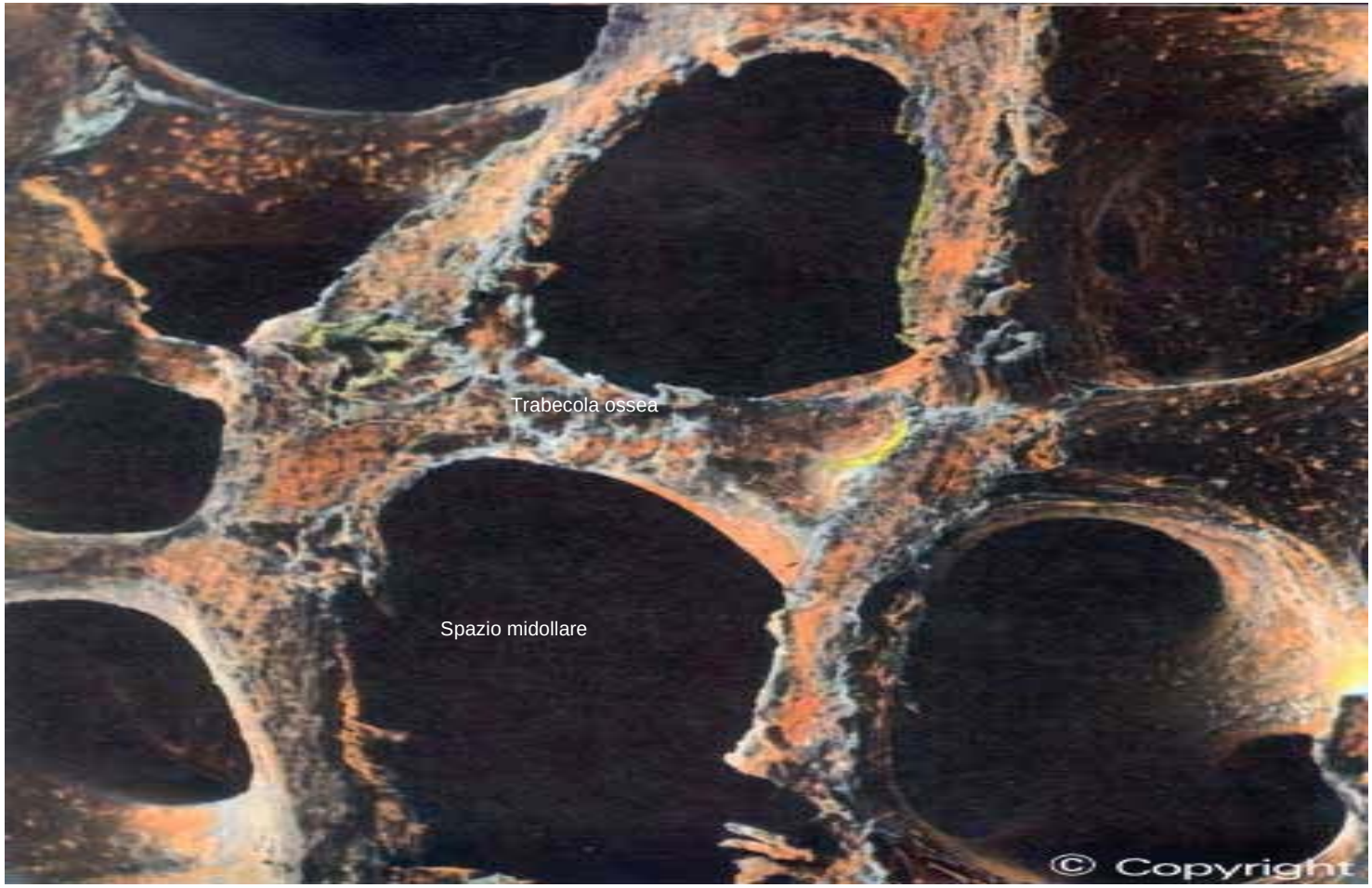

TESSUTO CARTILAGINEO

CONSISTENTE

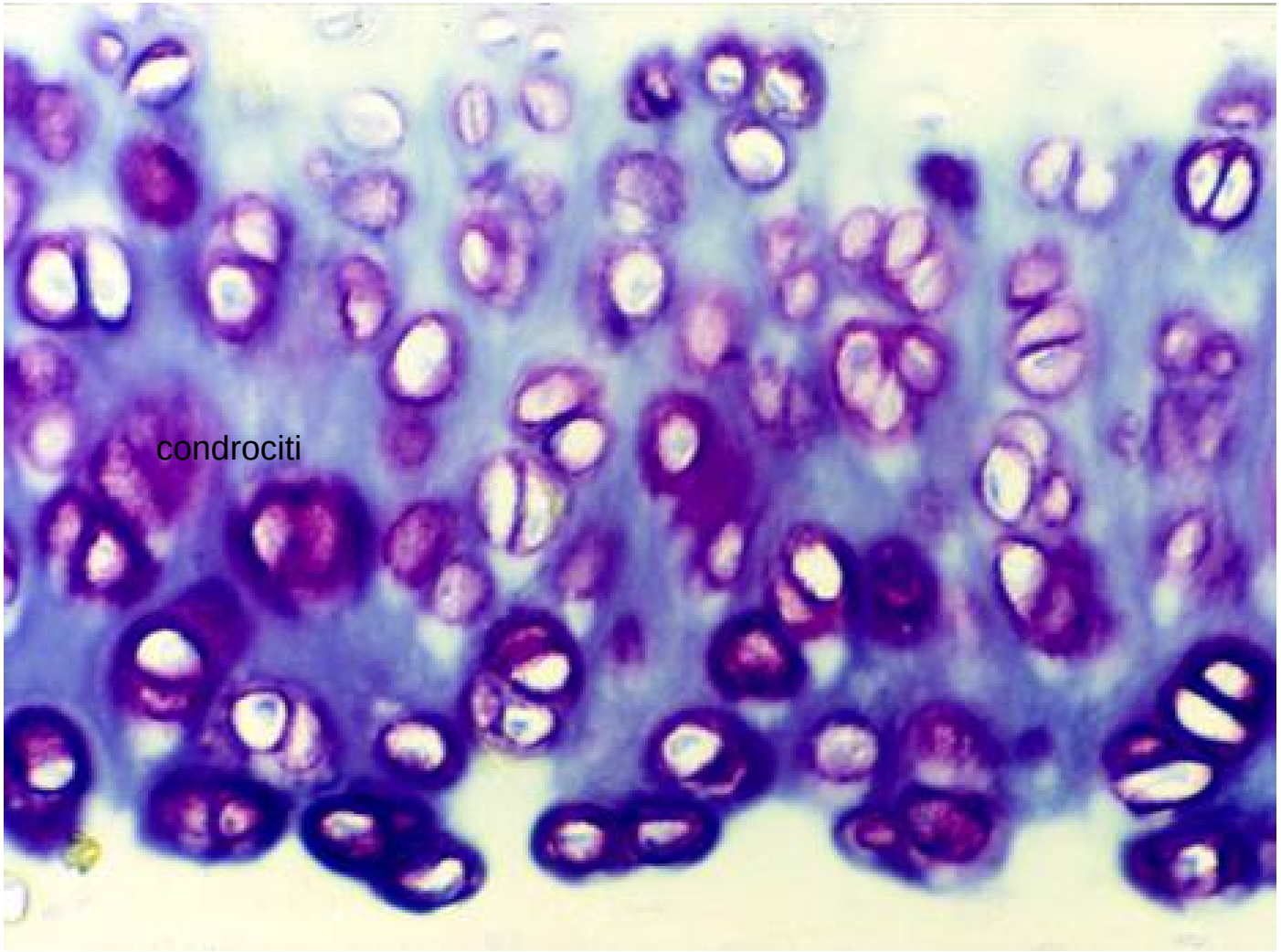

ELASTICO E FLESSIBILE

non è attraversato né da vasi sanguigni né da nervi

TIPI DI OSSA

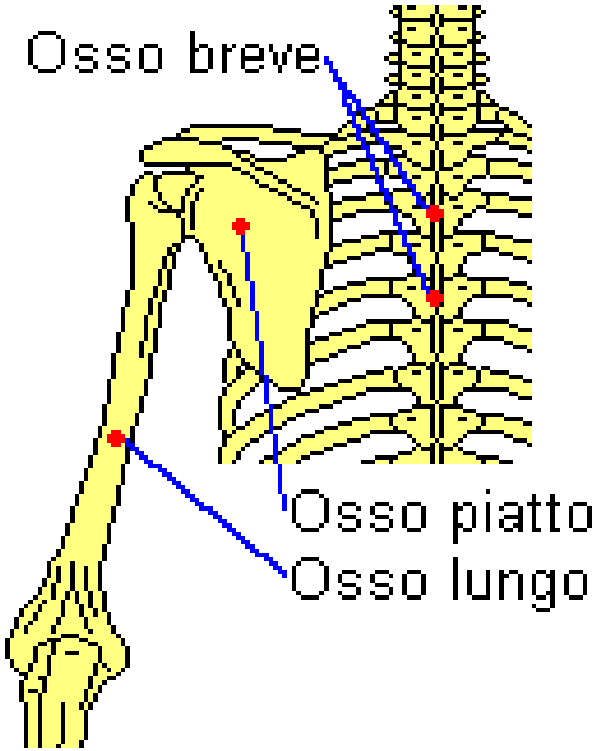
Osso breve
Osso piatto
Osso lungo

epifisi
osso piatto
diafisi
osso lungo
osso corto
epifisi

OSSA LUNGHE

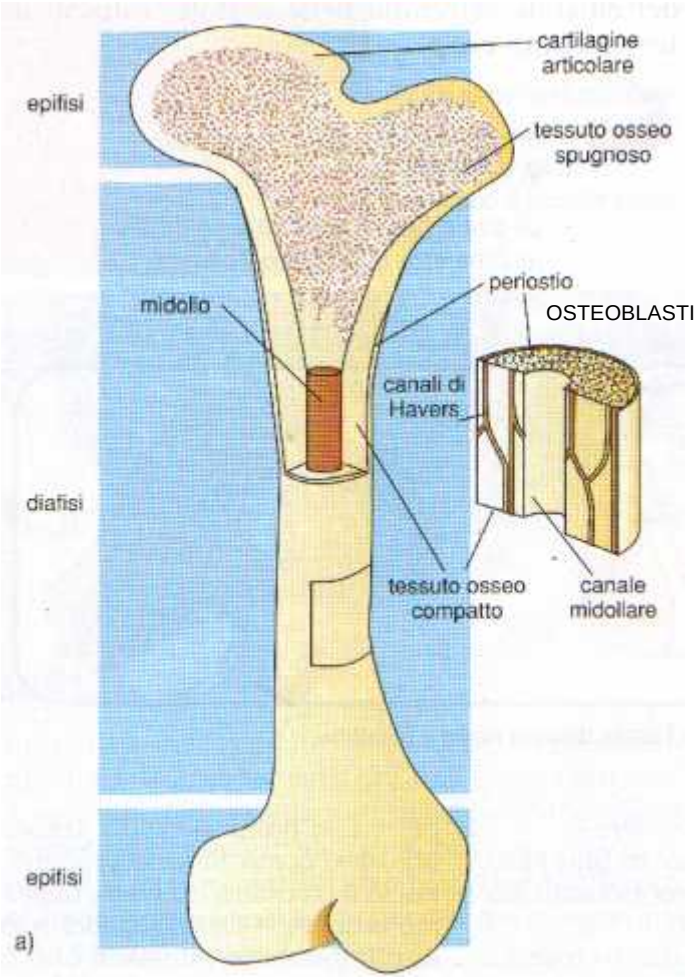
cartilagine articolare
epifisi
tessuto osseo spugnoso
periostio
OSTEOBLASTI
midollo
canali di Havers
diafisi
tessuto osseo compatto
canale midollare
epifisi
a)

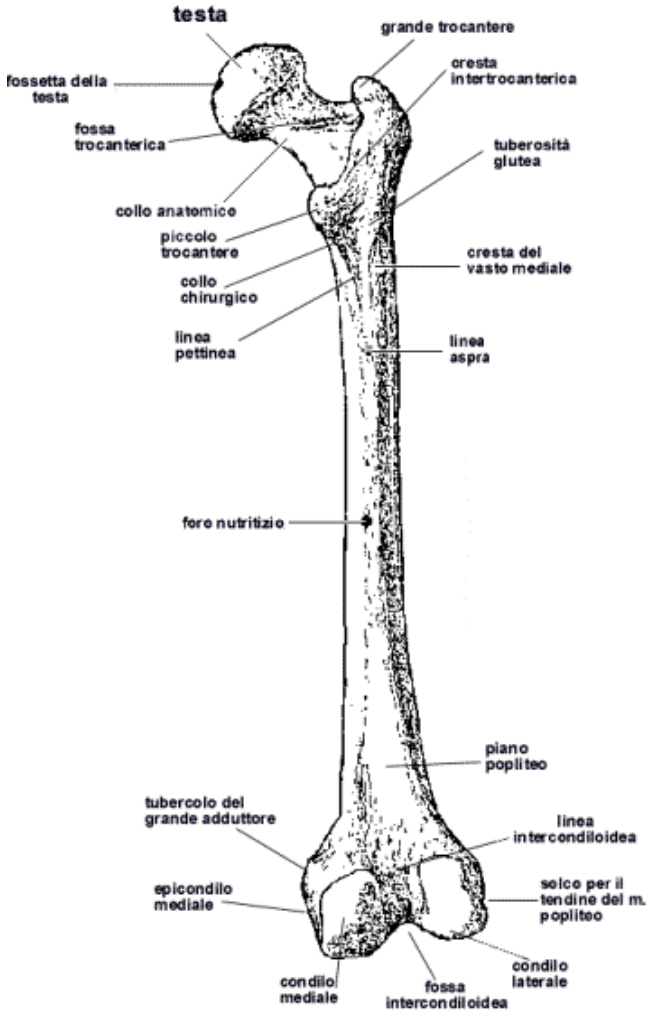
testa
grande trocantere
fossetta della testa
cresta intertrocanterica
fossa trocanterica
tuberosità glutea
collo anatomico
piccolo trocantere
cresta del vasto mediale
collo chirurgico
linea pettinea
linea aspra
foro nutritizio
piano popliteo
tubercolo del grande adduttore
linea intercondiloidea
epicondilo mediale
solco per il tendine del m. popliteo
condilo laterale
condilo mediale
fossa intercondiloidea

OSSA PIATTE

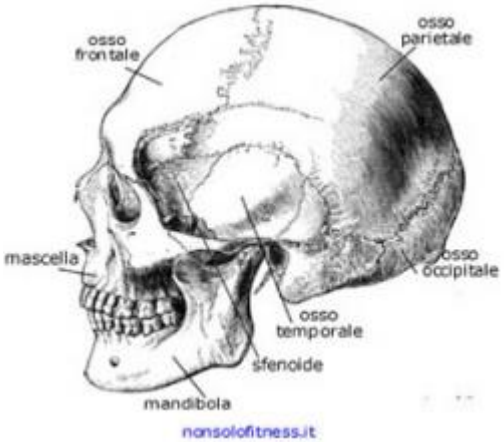
osso frontale
osso parietale
mascella
osso occipitale
osso temporale
sfenoide
mandibola
nonsolofitness.it

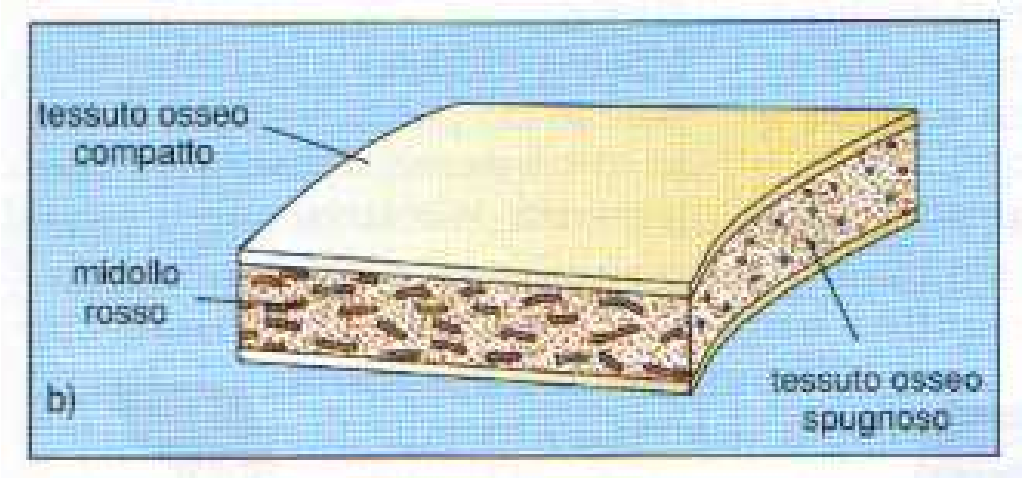
tessuto osseo compatto
midollo rosso
tessuto osseo spugnoso
b)

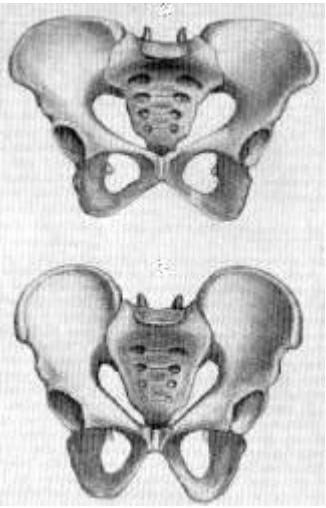

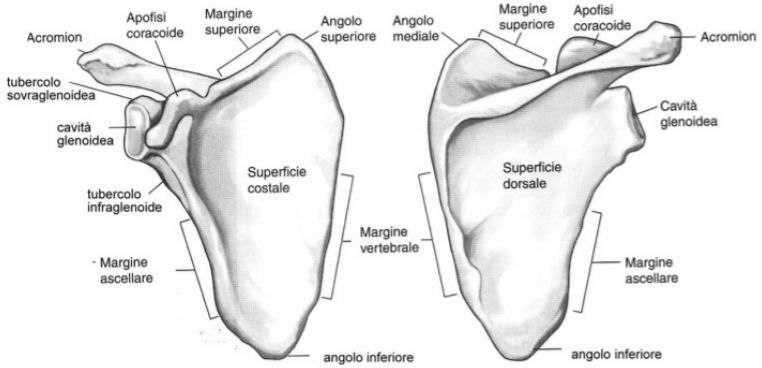
Acromion
Apofisi coracoide
Margine superiore
Angolo superiore
tubercolo sovraglenoidea
cavità glenoidea
tubercolo infraglenoide
Margine ascellare
Superficie costale
Margine vertebrale
angolo inferiore
Angolo mediale
Margine superiore
Apofisi coracoide
Acromion
Cavità glenoidea
Superficie dorsale
Margine ascellare
angolo inferiore

OSSA CORTE

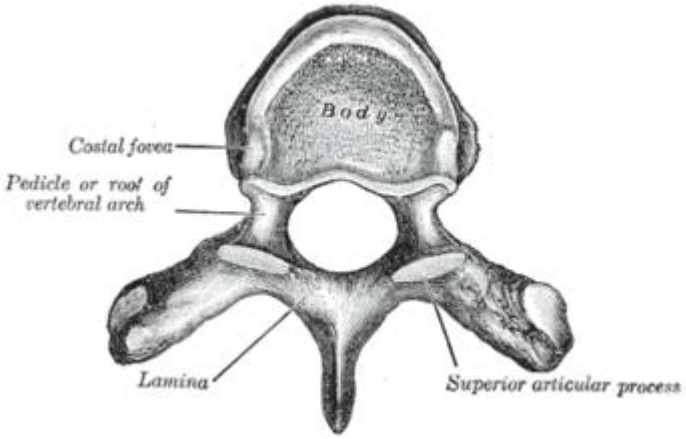

VERTEBRE

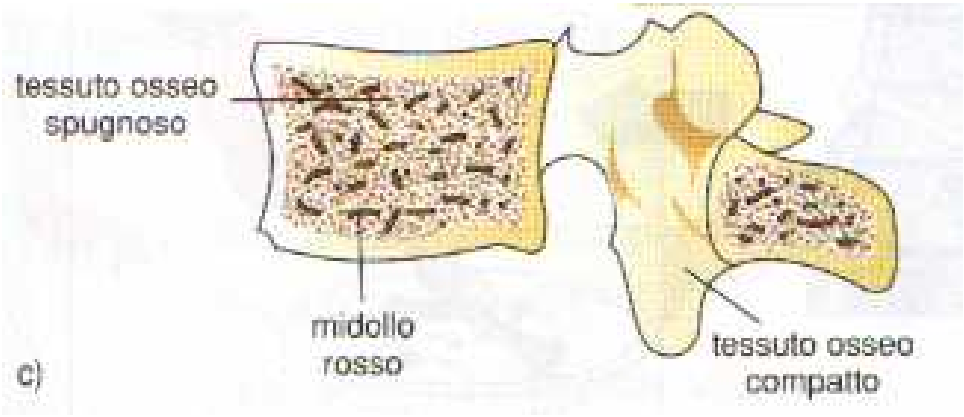

LE ARTICOLAZIONI

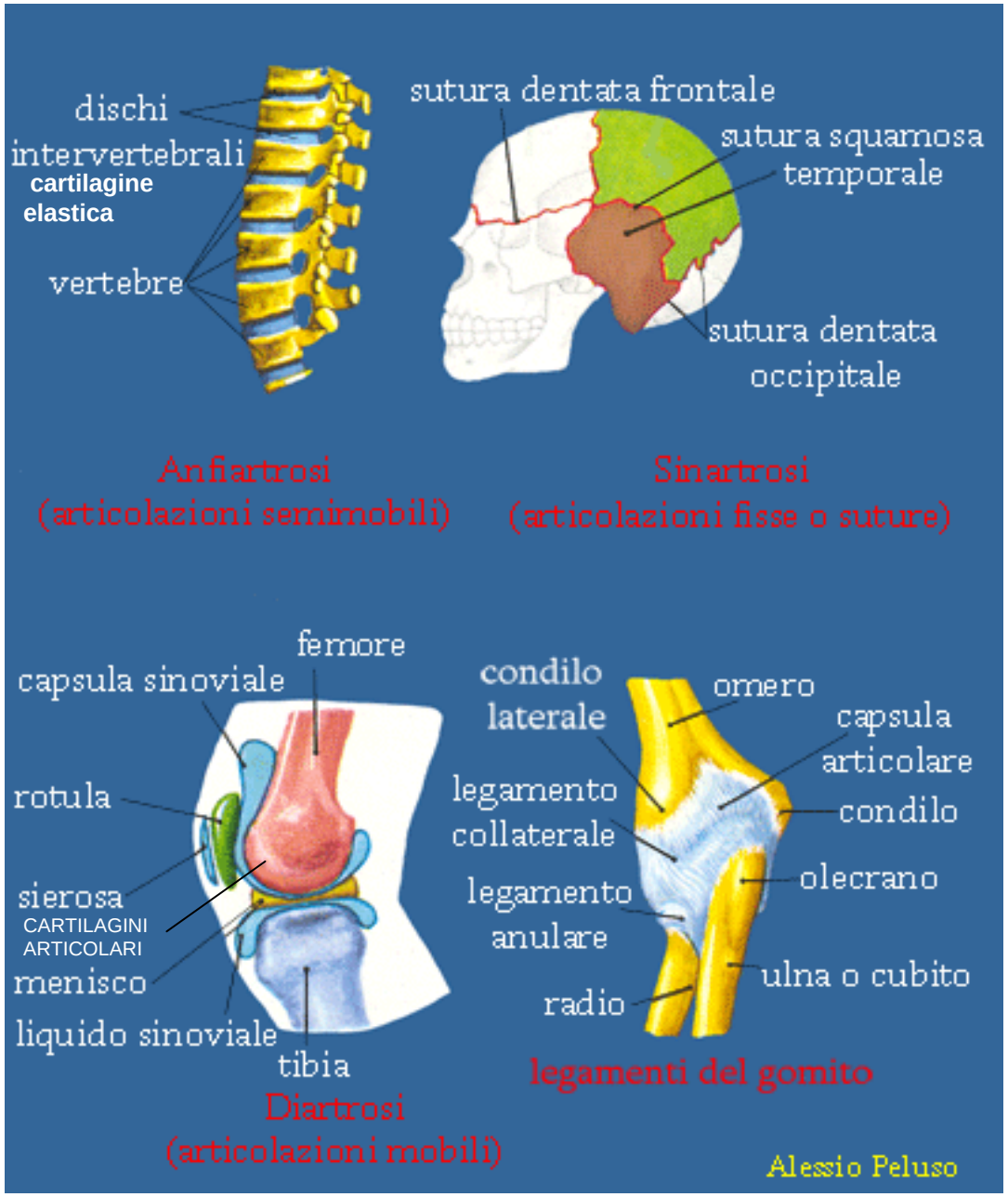

Nelle articolazioni mobili:

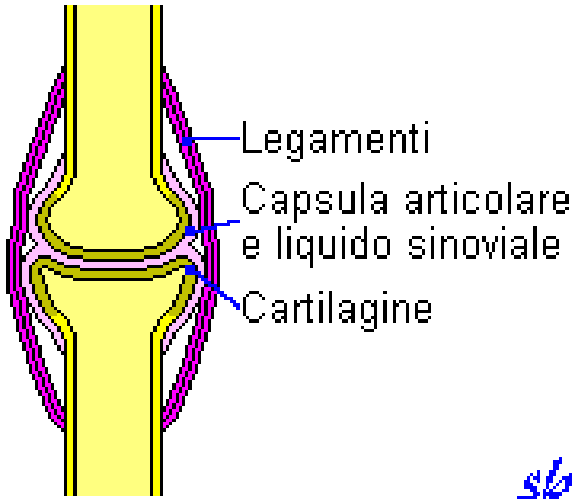

le superficie di contatto delle ossa non sono unite ma accostate e trattenute da legamenti fibrosi e da una capsula articolare che è rivestita dalla membrana sinoviale che secerne un liquido la sinovia, che lubrifica l'articolazione.

La struttura dello scheletro

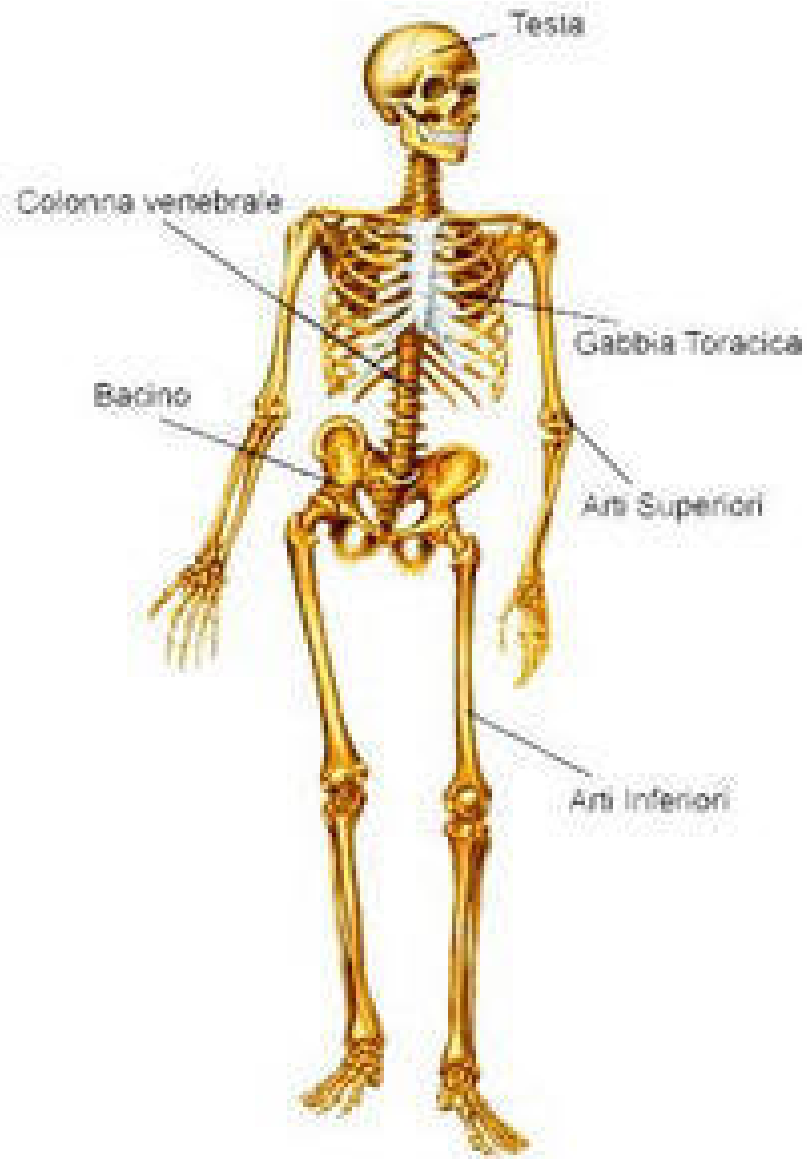

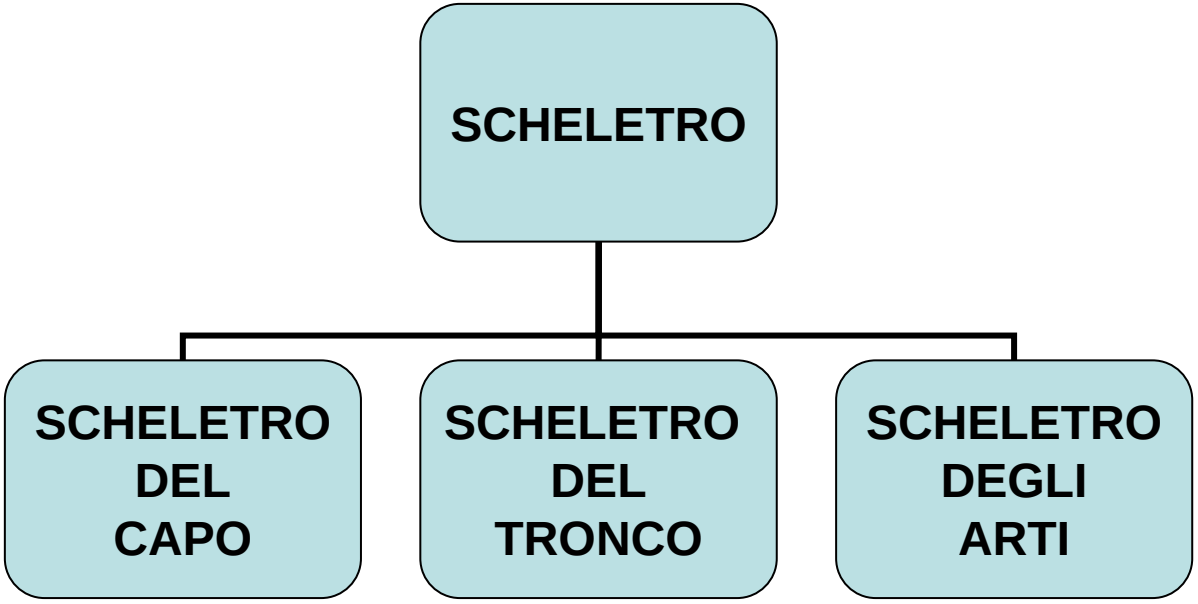
SCHELETRO
SCHELETRO DEL CAPO
SCHELETRO DEL TRONCO
SCHELETRO DEGLI ARTI

SCHELETRO DEL CAPO

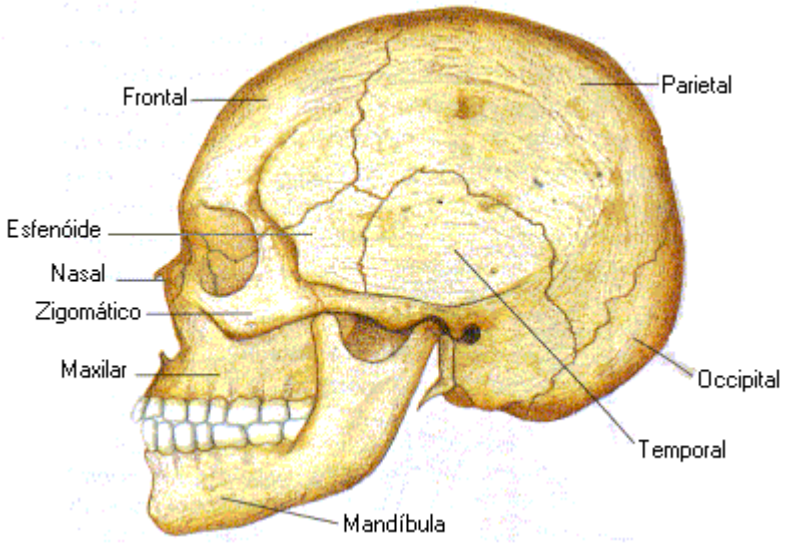

SCATOLA CRANICA

SCHELETRO FACCIALE

E' COSTITUITO DA 34 OSSA

SCHELETRO DEL TRONCO

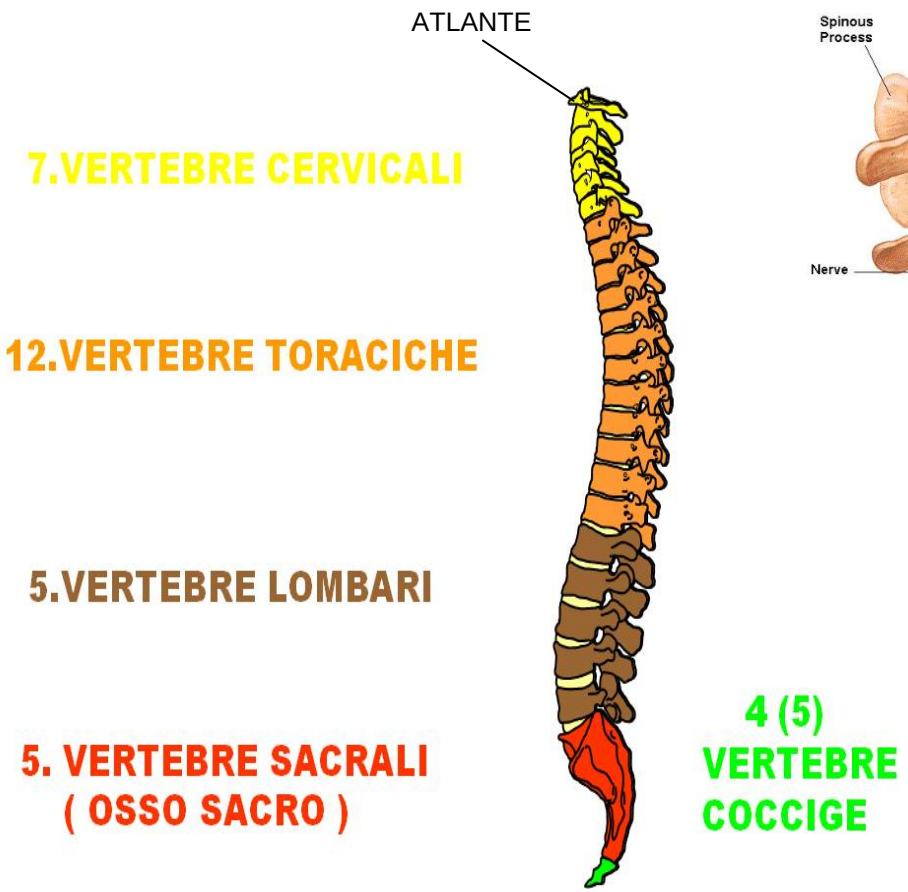

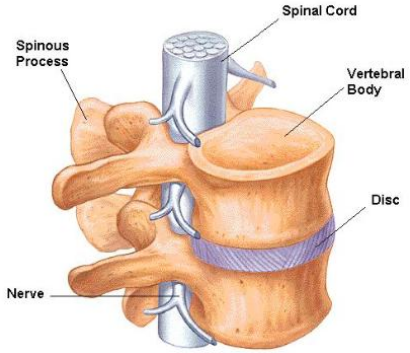

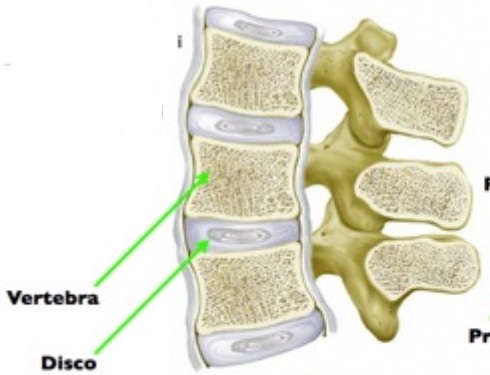

1. COLONNA VERTEBRALE

SCHELETRO DEL TRONCO

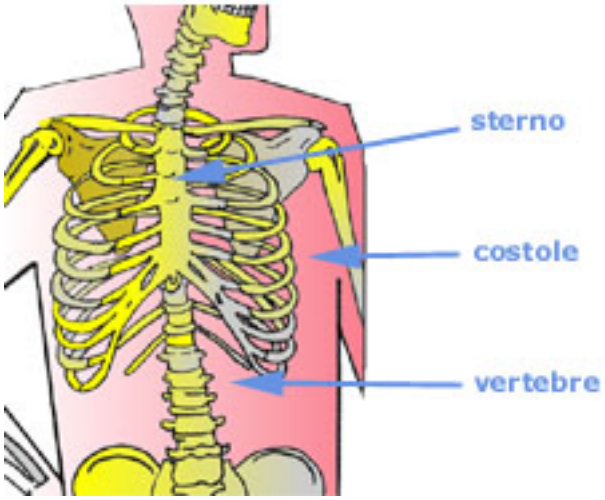

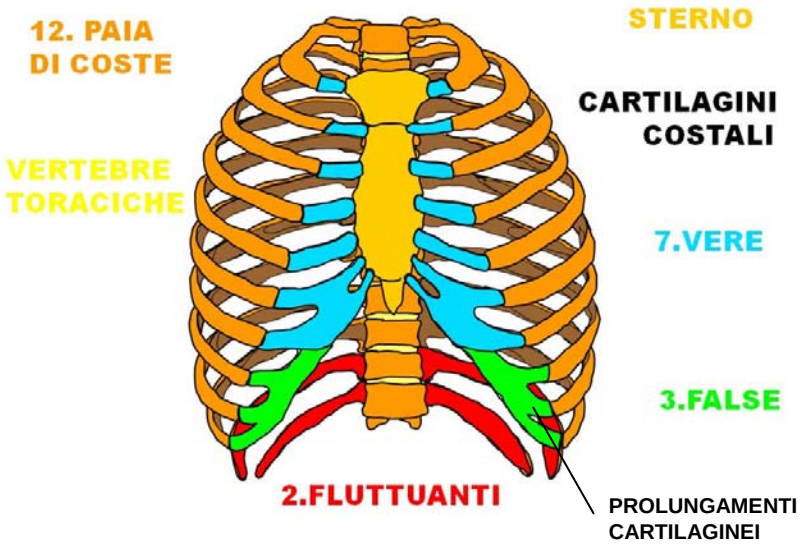

2. GABBIA TORACICA

SCHELETRO DEGLI ARTI

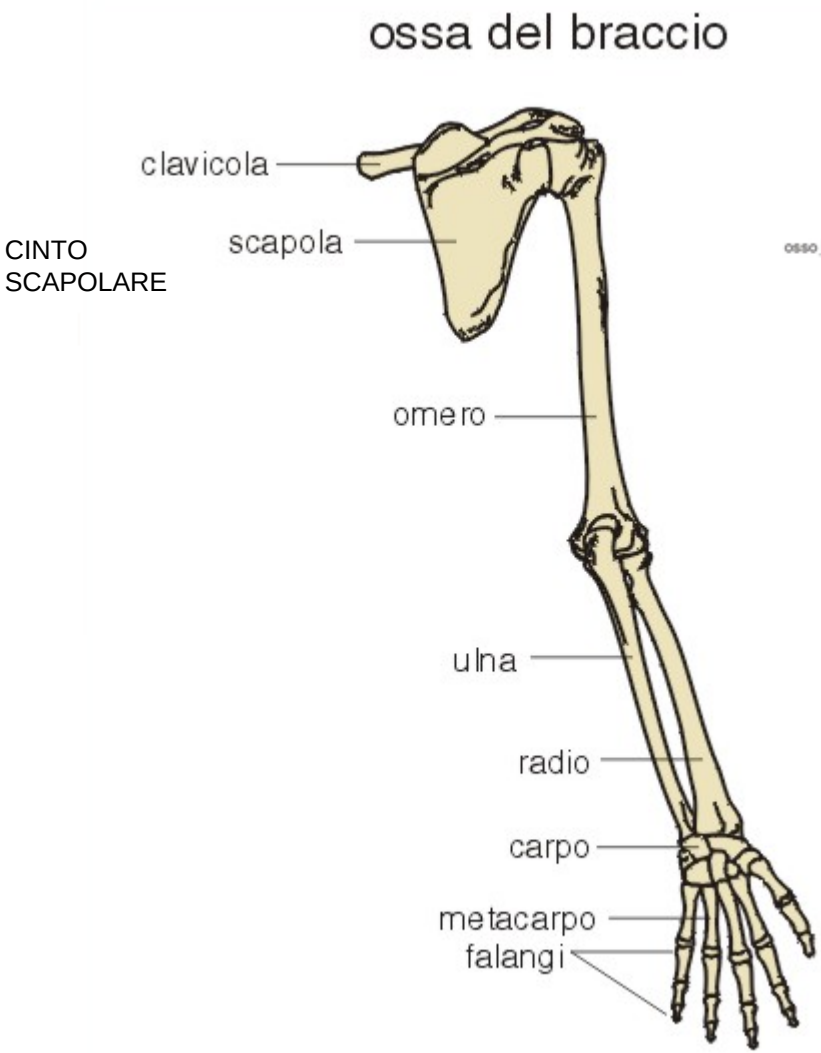

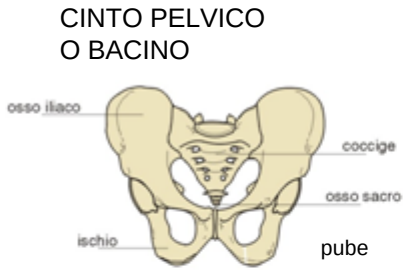

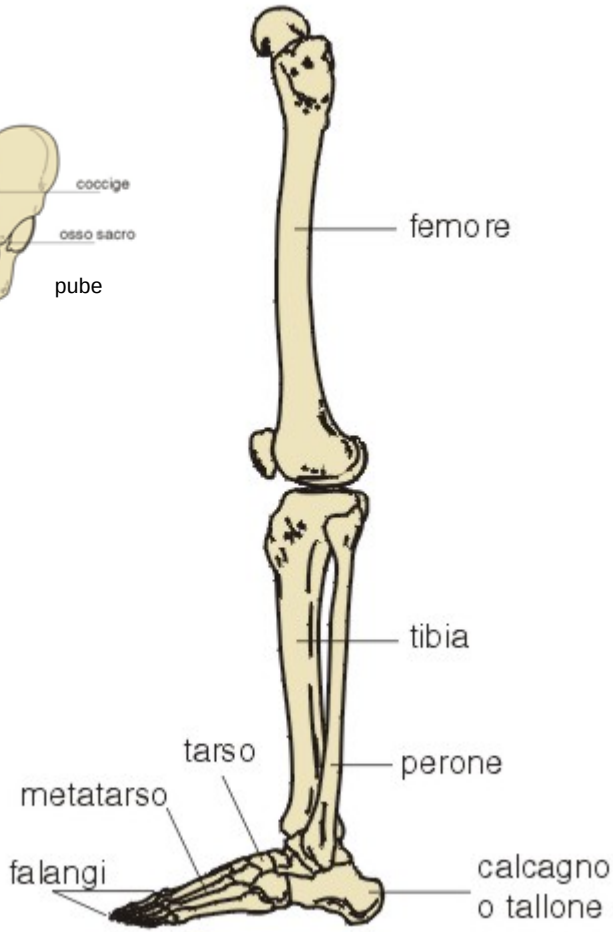

ARTO SUPERIORE **ARTO INFERIORE**

SCHELETRO DELL'UOMO

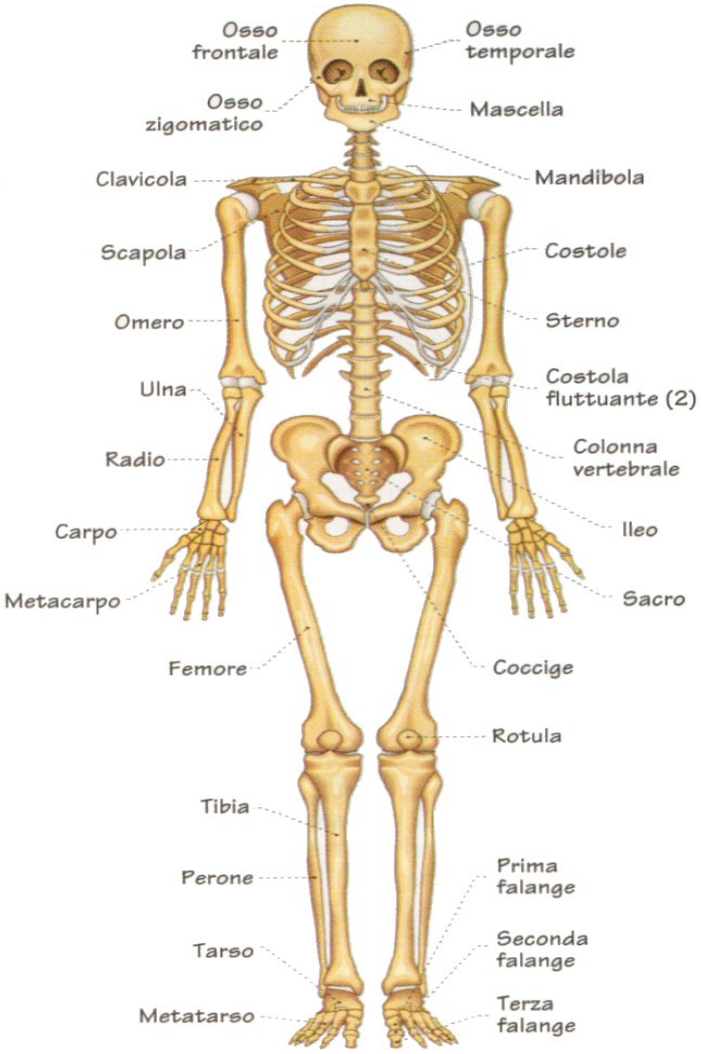

Vista anteriore

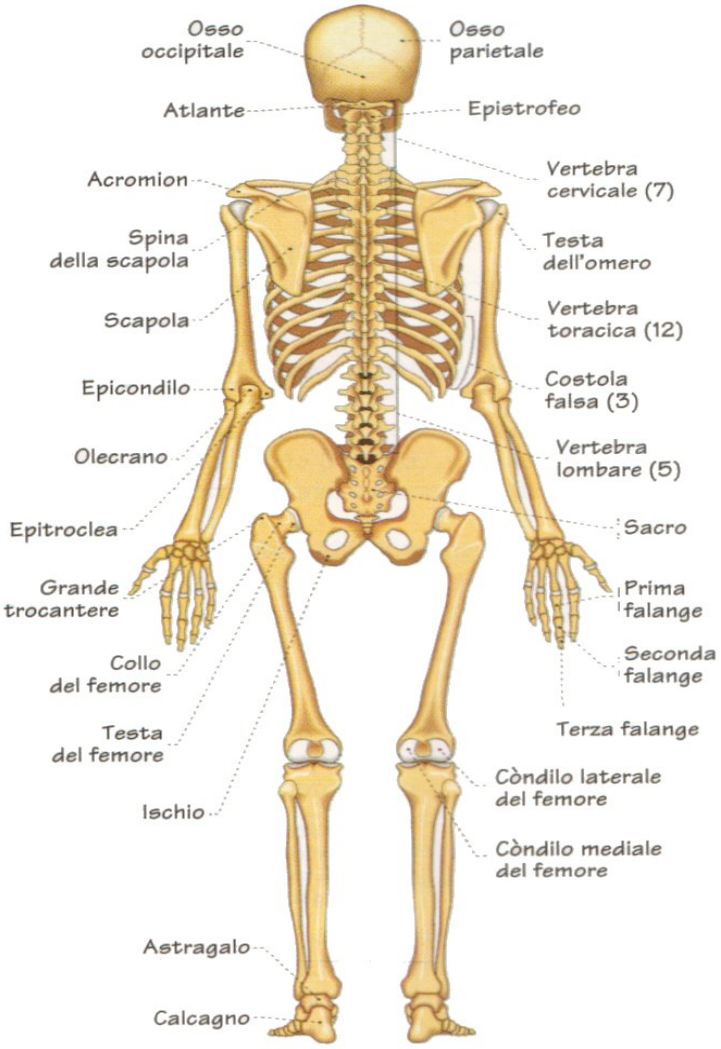

Vista posteriore

FUNZIONI DEL SISTEMA SCHELETRICO

- SOSTIENE IL CORPO
- PROTEGGE GLI ORGANI
- PRODUCE LE CELLULE DEL SANGUE
- COSTITUISCE UNA RISERVA DI SALI MINERALI