# TECNICHE DI
# RISONANZA MAGNETICA CONVENZIONALE ED AVANZATE
# NELLA
# SCLEROSI MULTIPLA

www.fisiokinesiterapia.biz

# Localizzazioni Encefaliche

Corpo Calloso (CC)

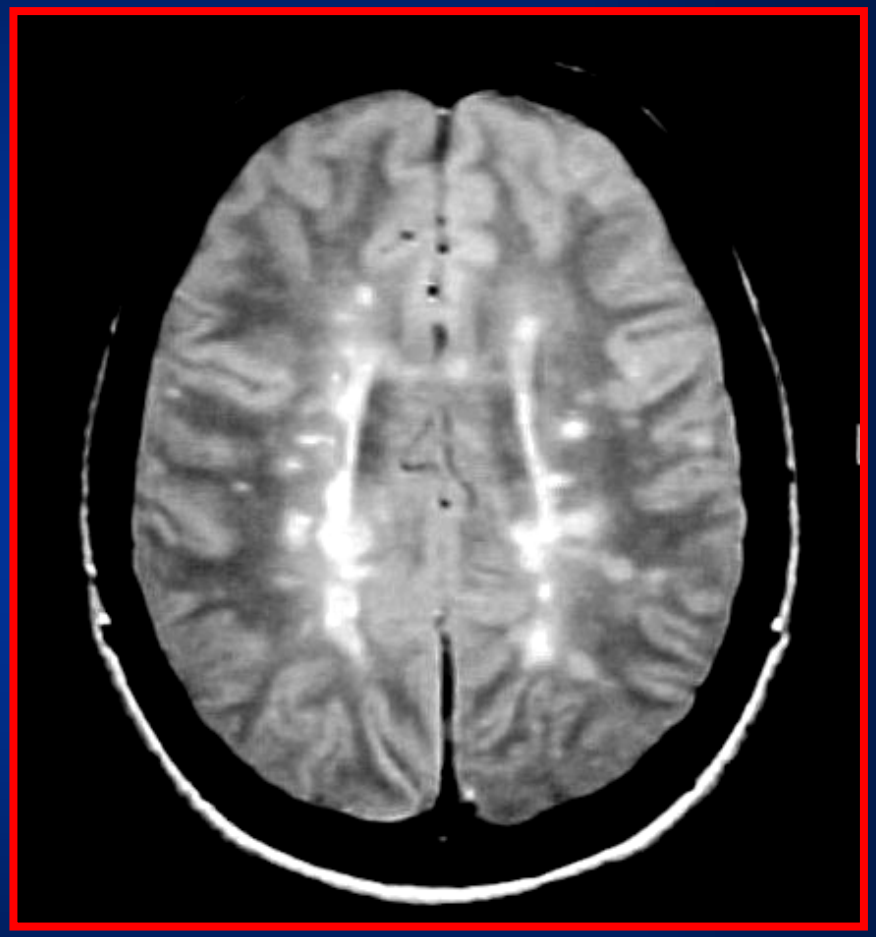

Periventricolare

# Valutazione delle localizzazioni particolari

Midollo

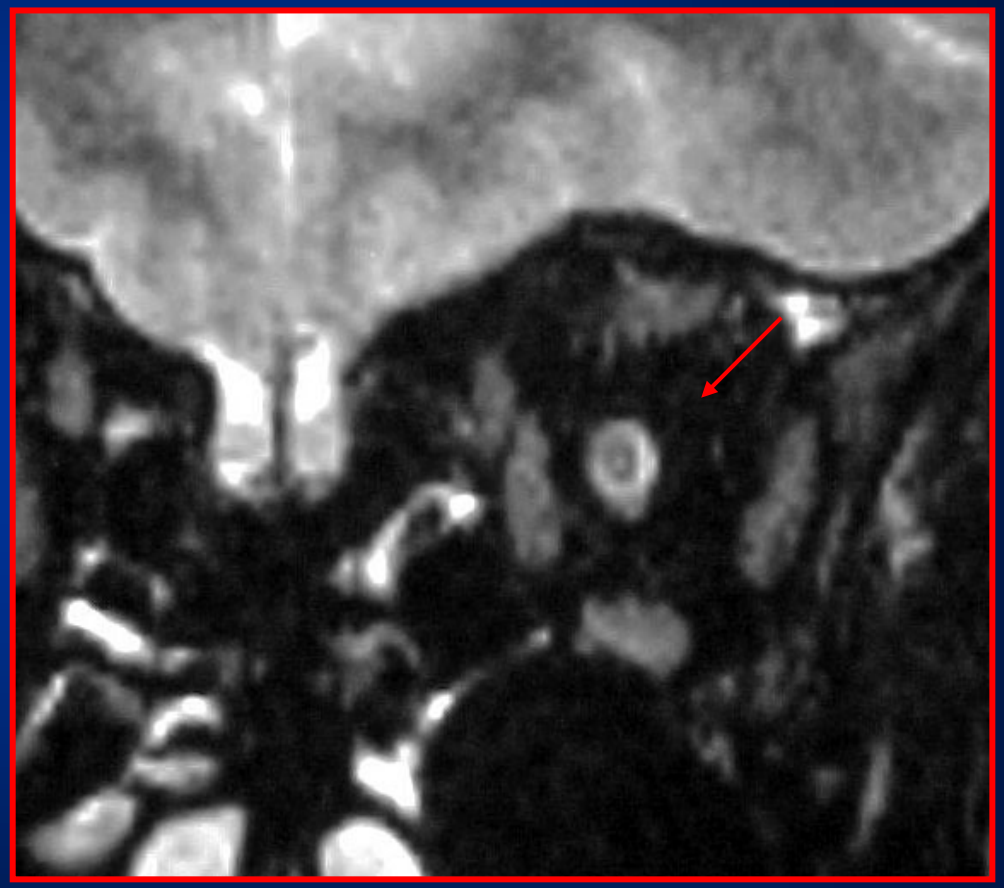

Nervo ottico

# Valutazione dell'attività della malattia

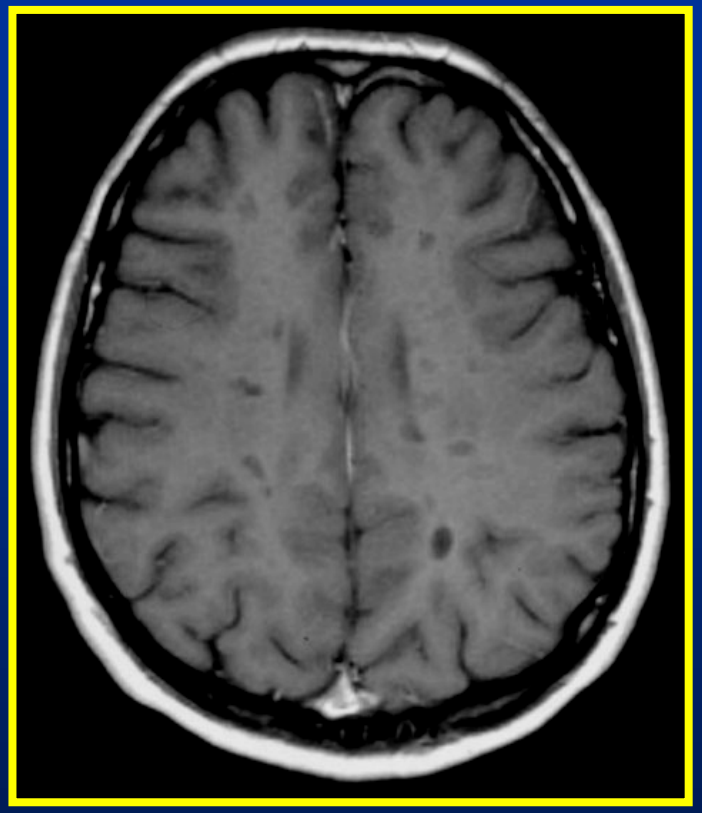

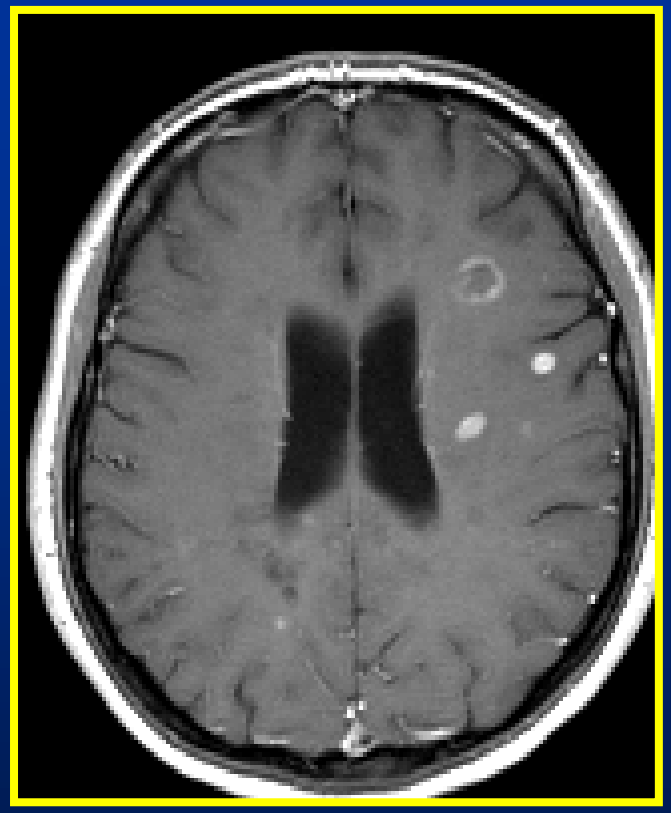

Rottura della barriera Emato-encefalica → passaggio del gadolinio → Aumento del segnale in risonanza

# Valutazione del carico lesionale

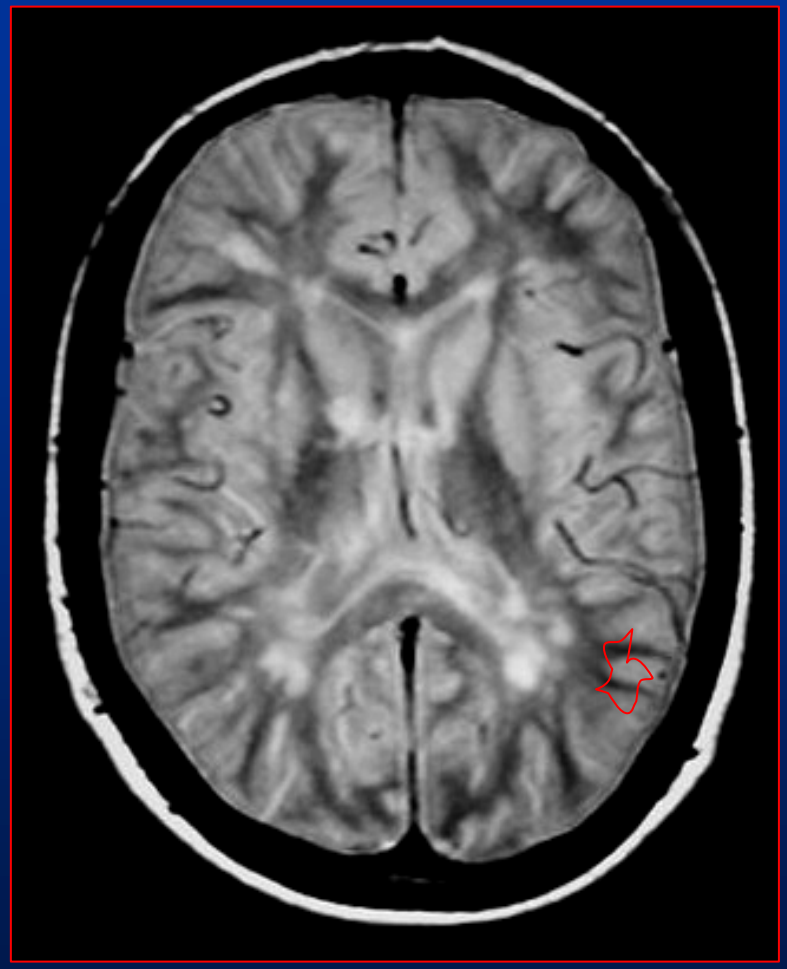

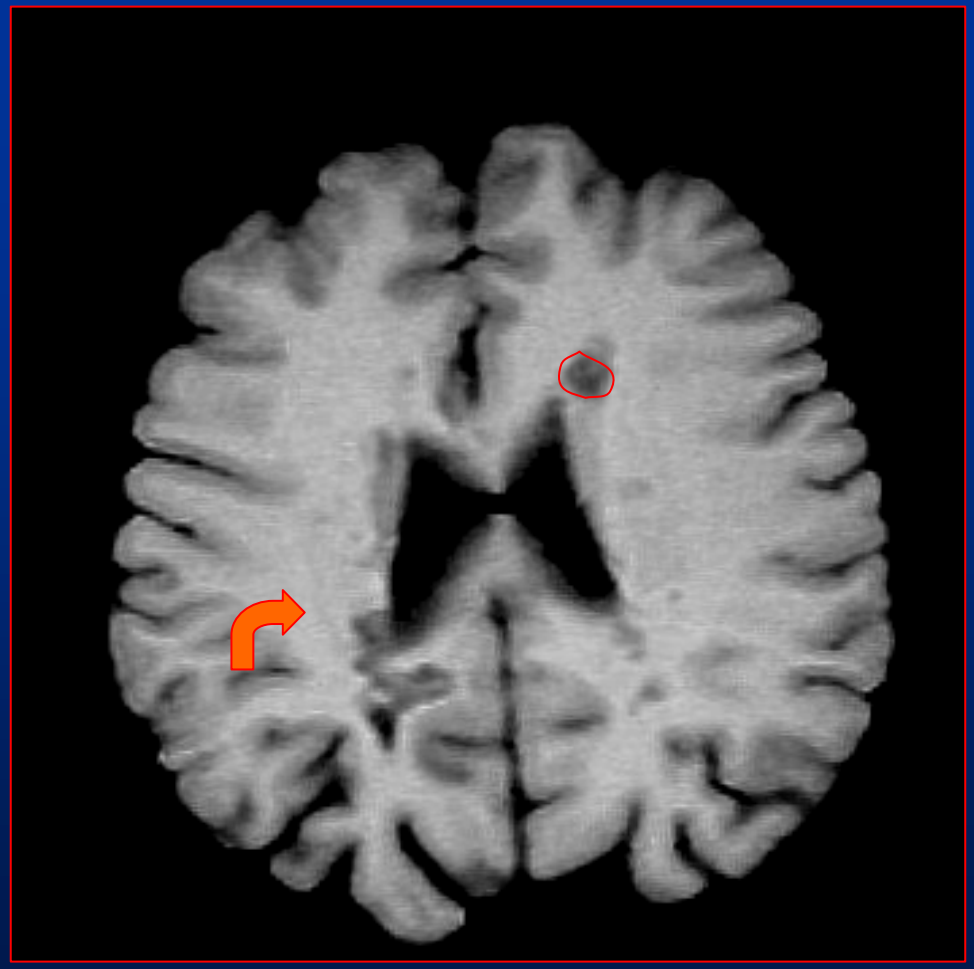

# Analisi quantitativa

## Spettroscopia

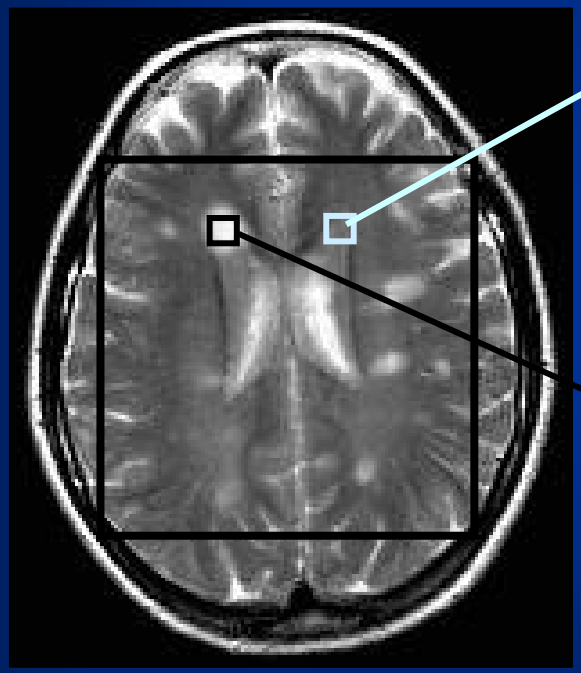

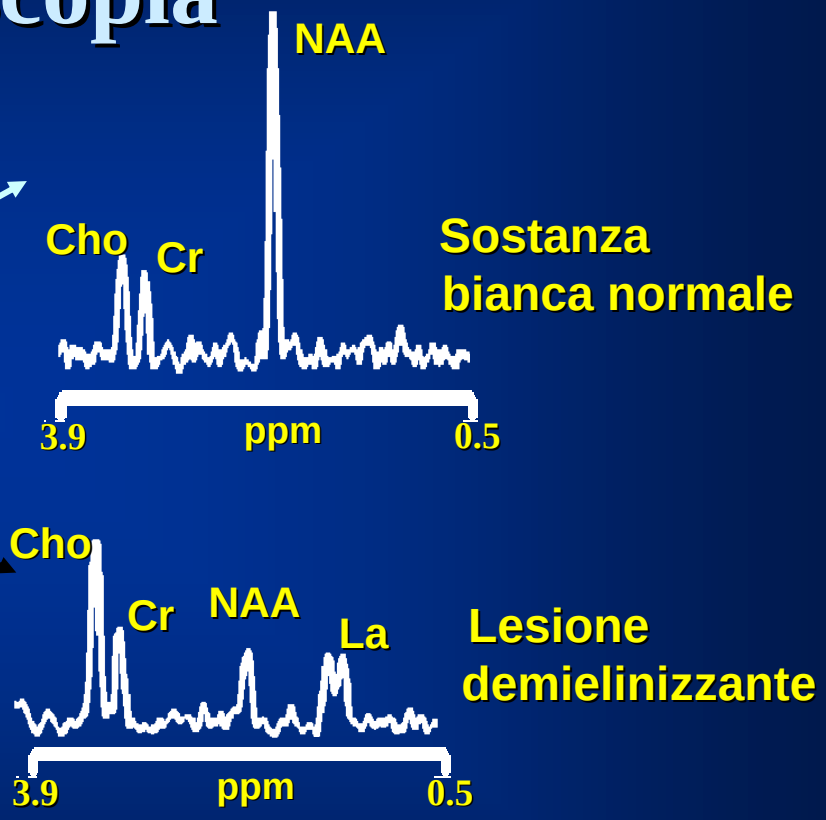


- N-acetilaspartato (NAA, marker di integrità assonale)
- Colina (Cho, marker di integrità mielinica)
- Lattato (Lac, marker di riduzione del metabolismo ossidativo)

*De Stefano et al AAN 2000 S39.005*

# Valutazione dell’atrofia

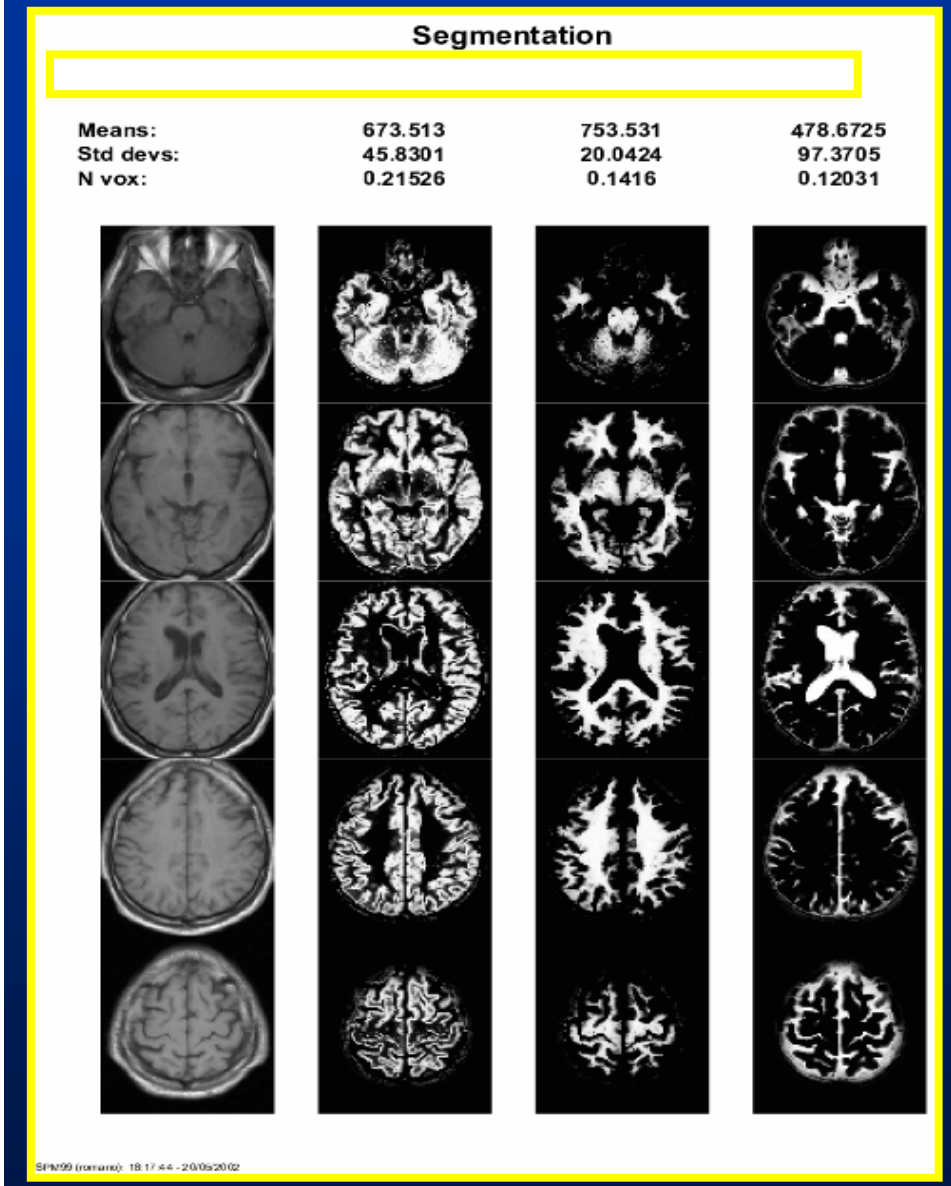


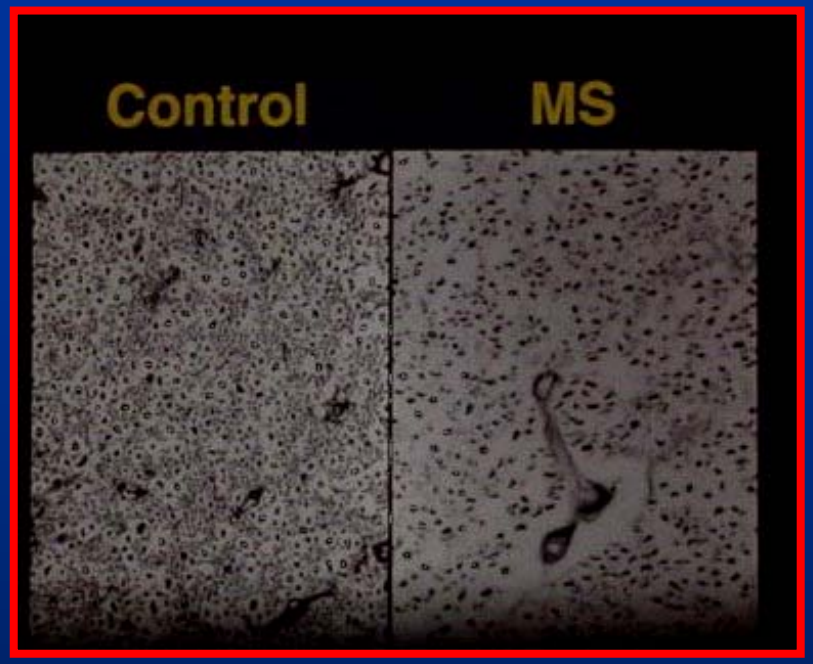

# Valutazione funzionale
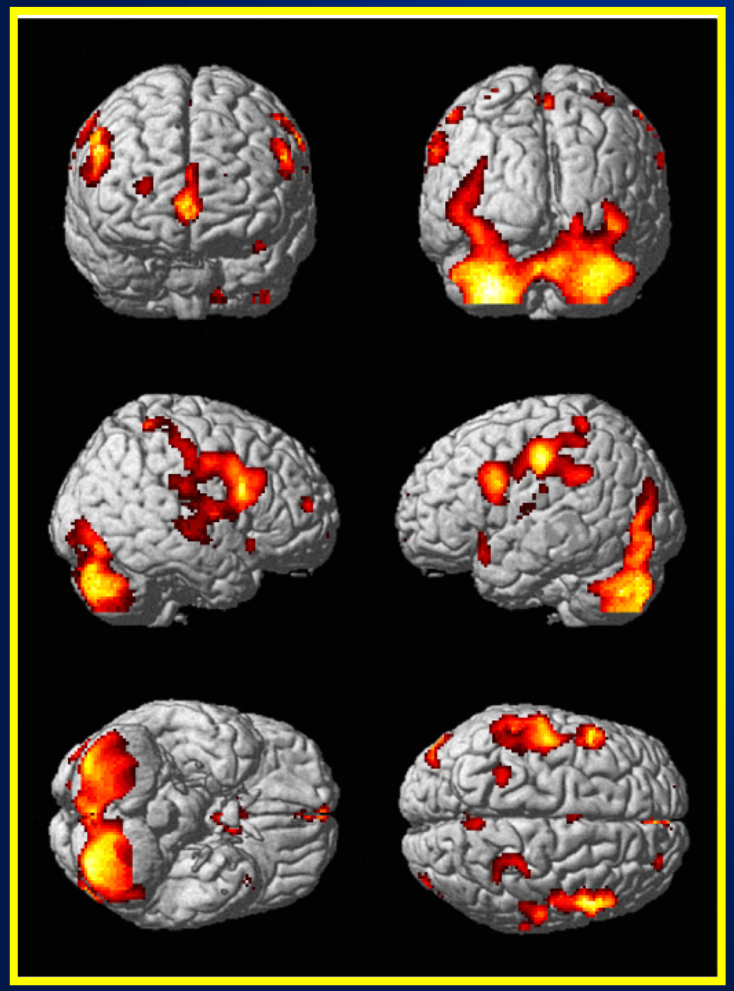
## Risonanza Magnetica funzionale (fMRI)