

[www.fisiokinesiterapia.biz](http://www.fisiokinesiterapia.biz)

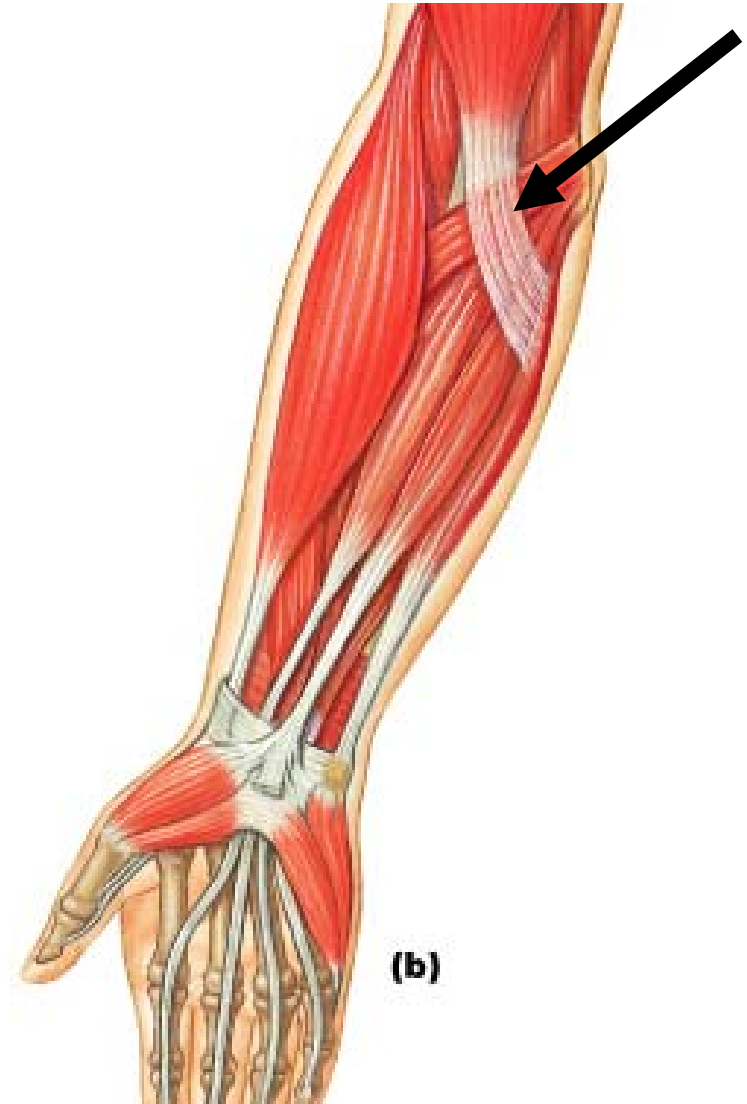
---

Muscles

# Pronator Teres

---

- **Origin:** Medial epicondyle of humerus and coronoid process of ulna
- **Insertion:** Middle portion of radius
- **Action:** Pronates and flexes forearm

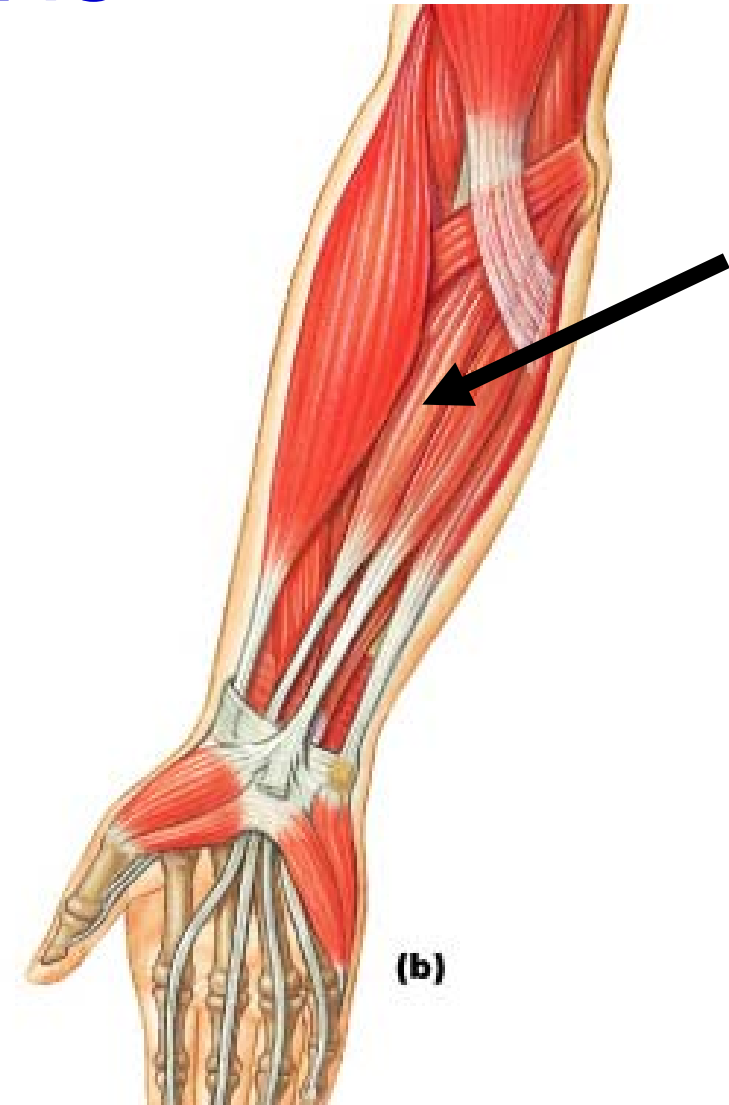


Anterior, Superficial Layer

# Flexor Carpi Radialis

---

- **Origin:** Medial epicondyle of humerus
- **Insertion:** Base of second metacarpal
- **Action:** Flexes wrist and elbow and abducts wrist

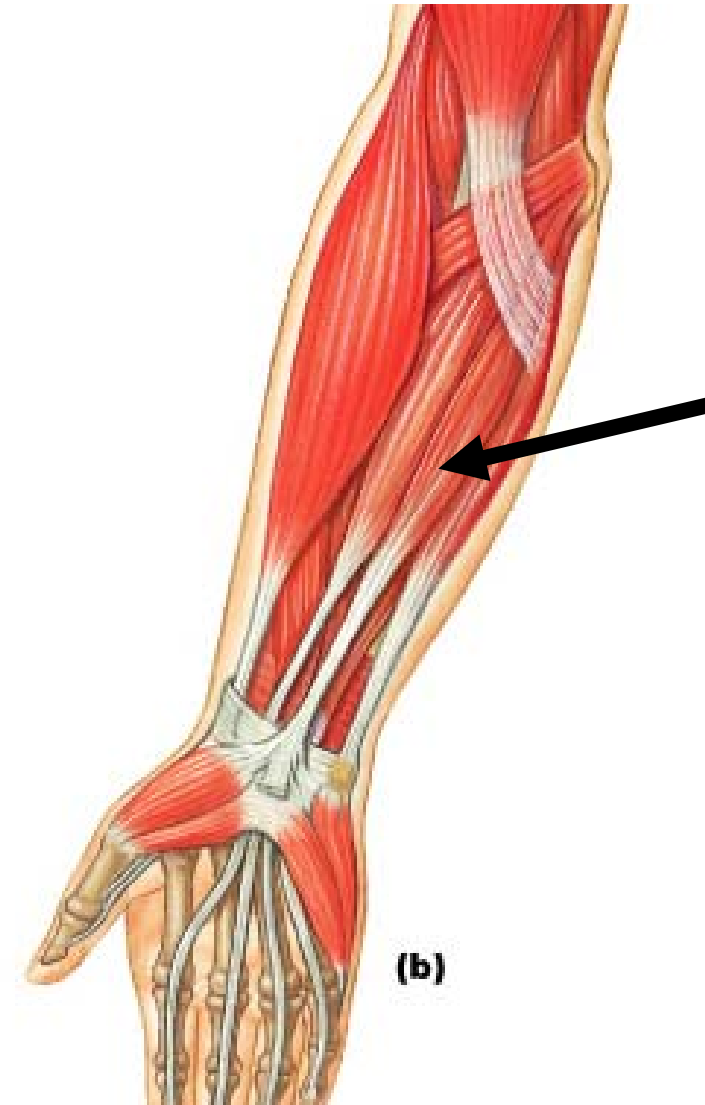


Anterior, Superficial Layer

# Palmaris Longus

---

- **Origin:** Medial epicondyle of the humerus
- **Insertion:** Palmar aponeurosis
- **Action:** Weak flexion of wrist, tenses skin of palm

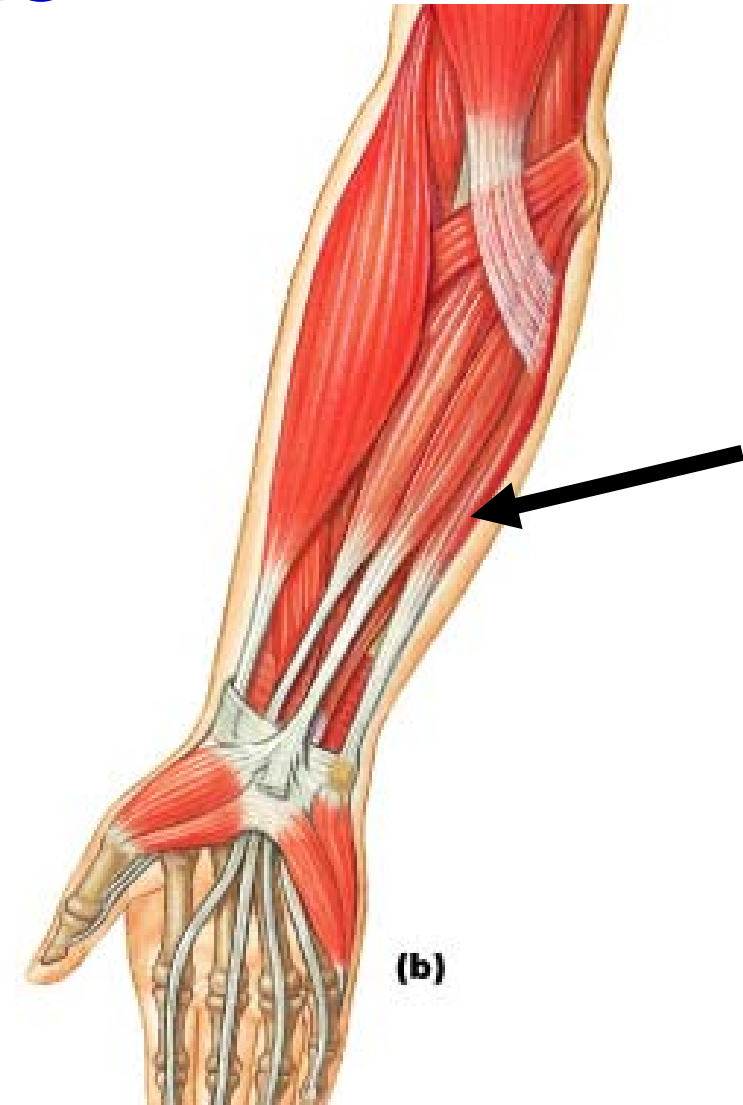


Anterior, Superficial Layer

# Flexor Carpi Ulnaris

---

- **Origin:** Medial epicondyle of humerus, olecranon process, & posterior ulna
- **Insertion:** Pisiform, hamate, and fifth metacarpal
- **Action:** Flexes and adducts wrist

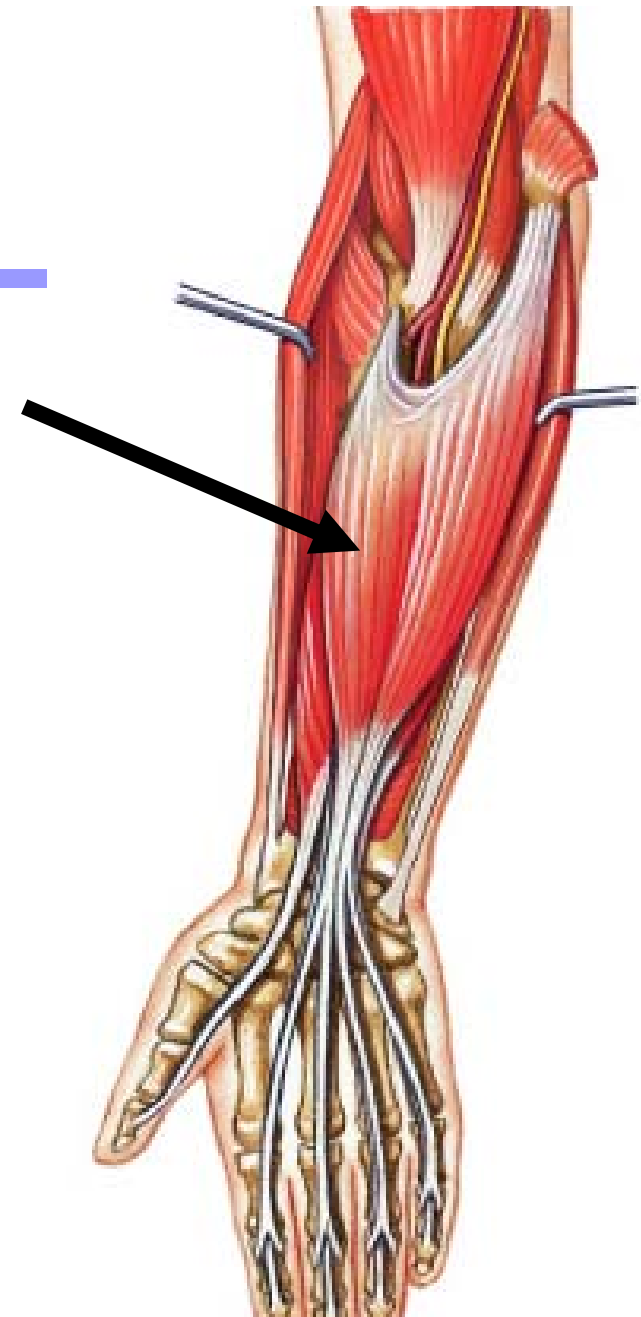


Anterior, Superficial Layer

# Flexor Digitorum Superficialis

---

- **Origin:** Medial epicondyle of humerus and coronoid process of ulna
- **Insertion:** Middle phalanges of fingers
- **Action:** Flexes fingers and wrist

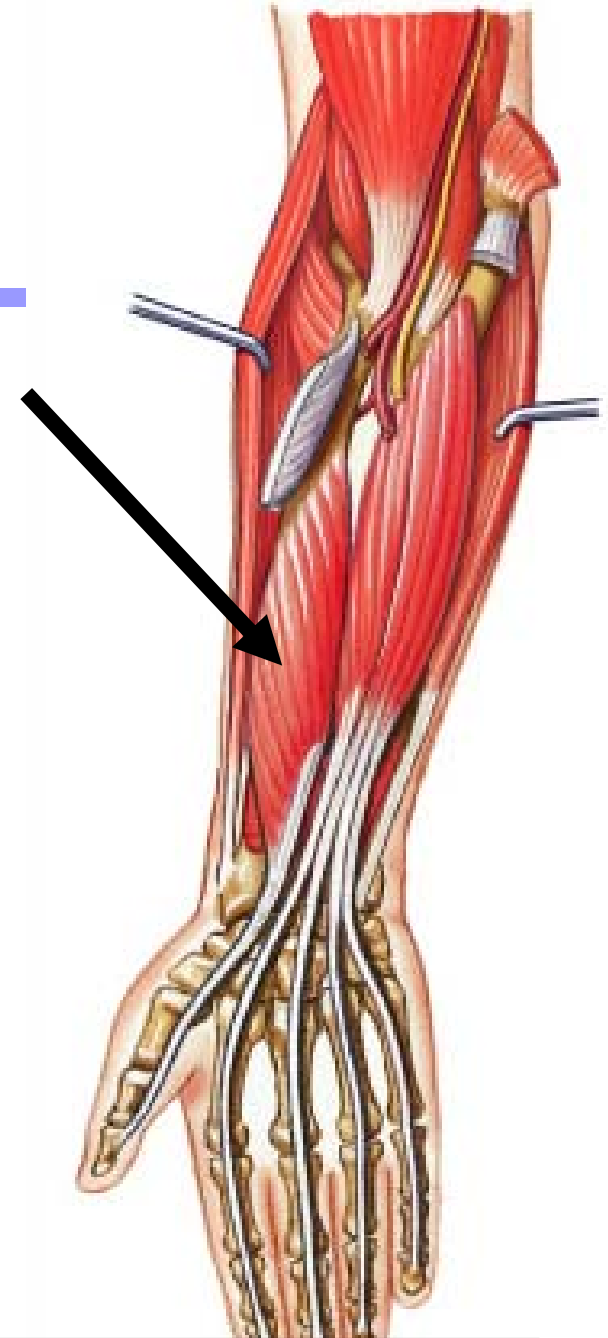


Anterior, Middle Layer

# Flexor Pollicis Longus

---


- **Origin:** Middle half of radius, interosseous membrane, coronoid process of ulna
- **Insertion:** Distal phalanx of thumb
- **Action:** Flexes thumb and wrist



Anterior, Deepest Layer

# MUSCLES OF POSTEROLATERAL FOREARM

---

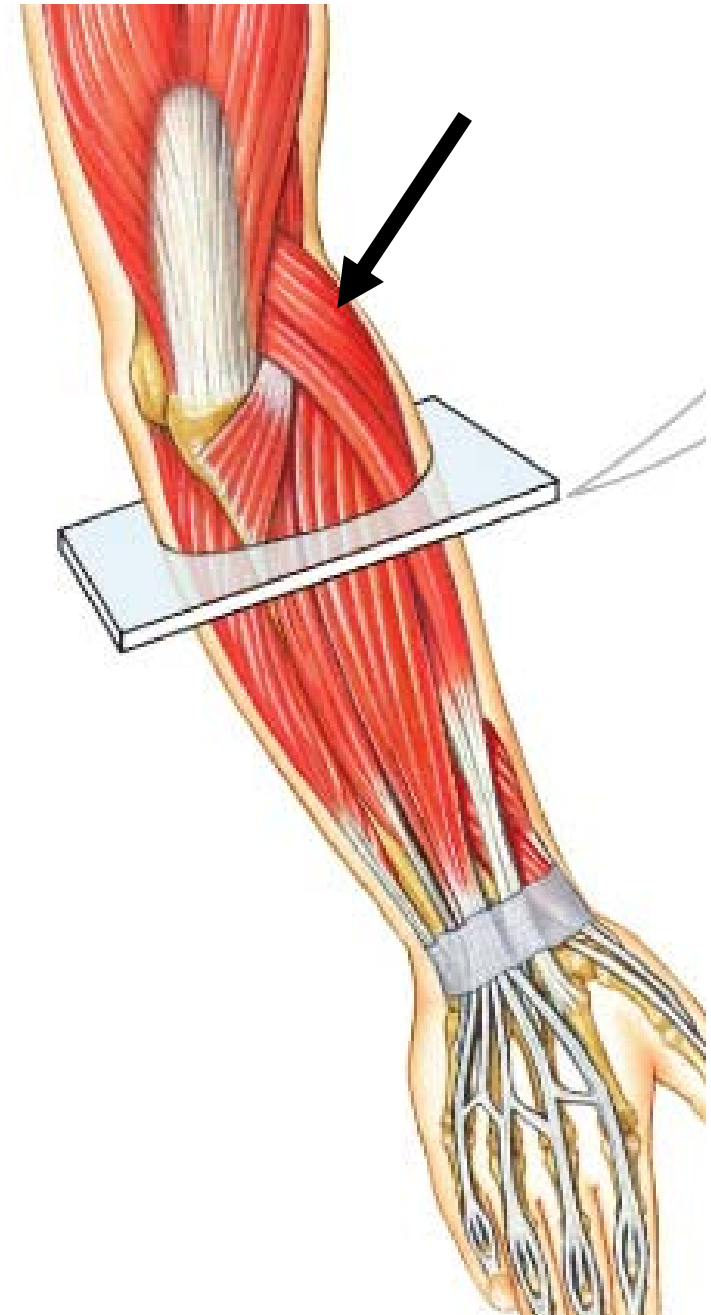




# Brachioradialis

---

- **Origin:** Lateral supracondylar ridge
- **Insertion:** Styloid process of radius
- **Action:** Flexes forearm

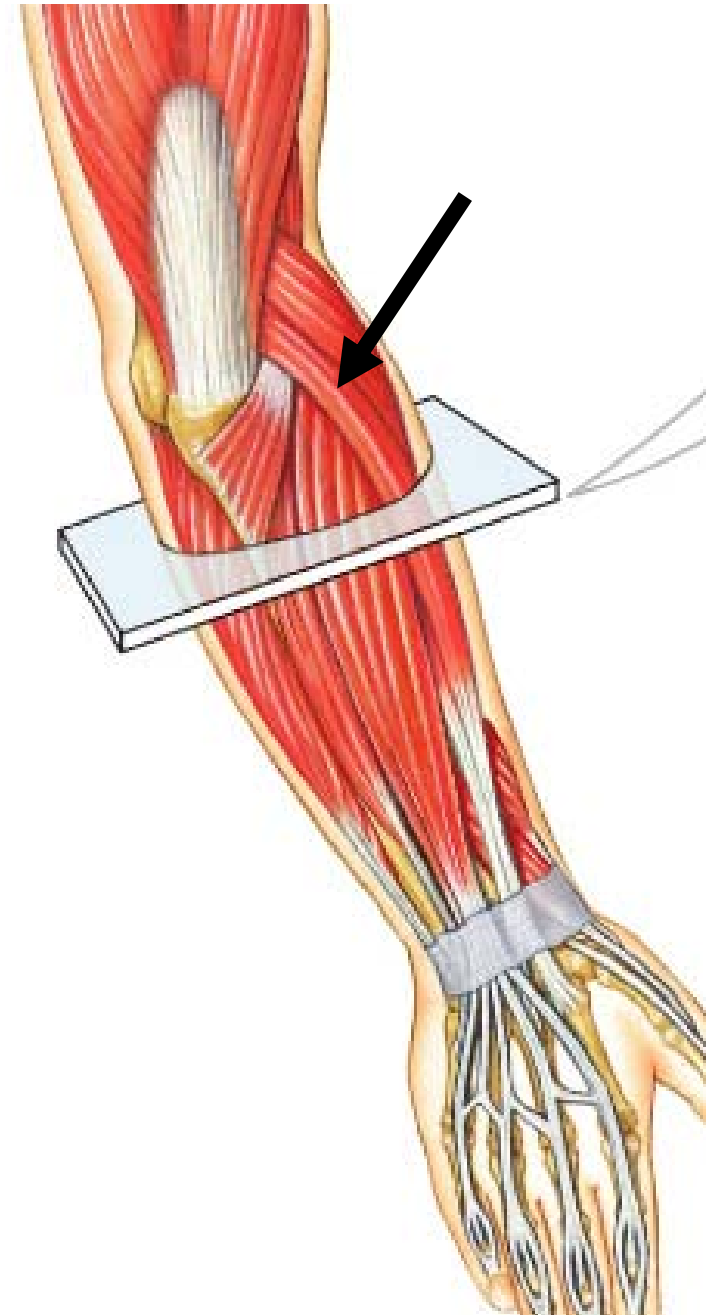


Posterior, Superficial Layer

# Extensor Carpi Radialis Longus

---

- **Origin:** Lateral supracondylar ridge of humerus
- **Insertion:** Second metacarpal
- **Action:** Extends and abducts hand

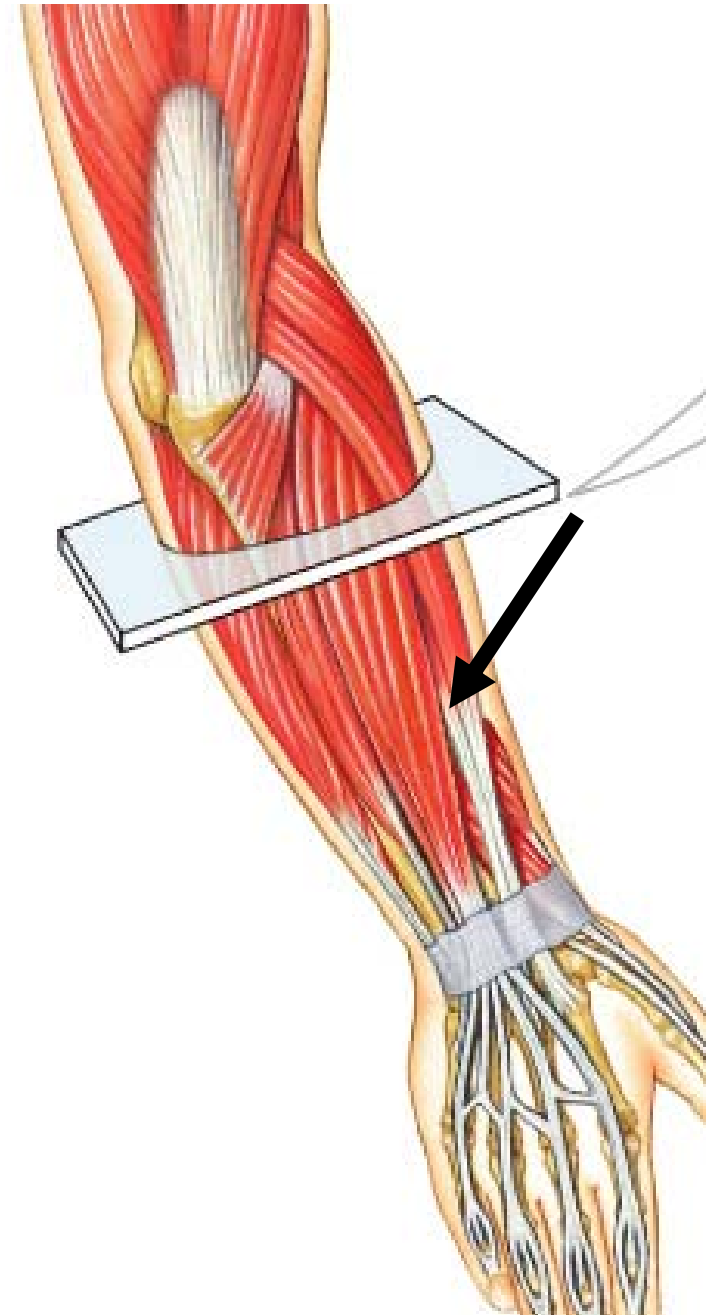


Posterior, Superficial Layer

# Extensor Carpi Radialis Brevis

---

- **Origin:** Lateral epicondyle of humerus
- **Insertion:** Third metacarpal
- **Action:** Extends and abducts hand

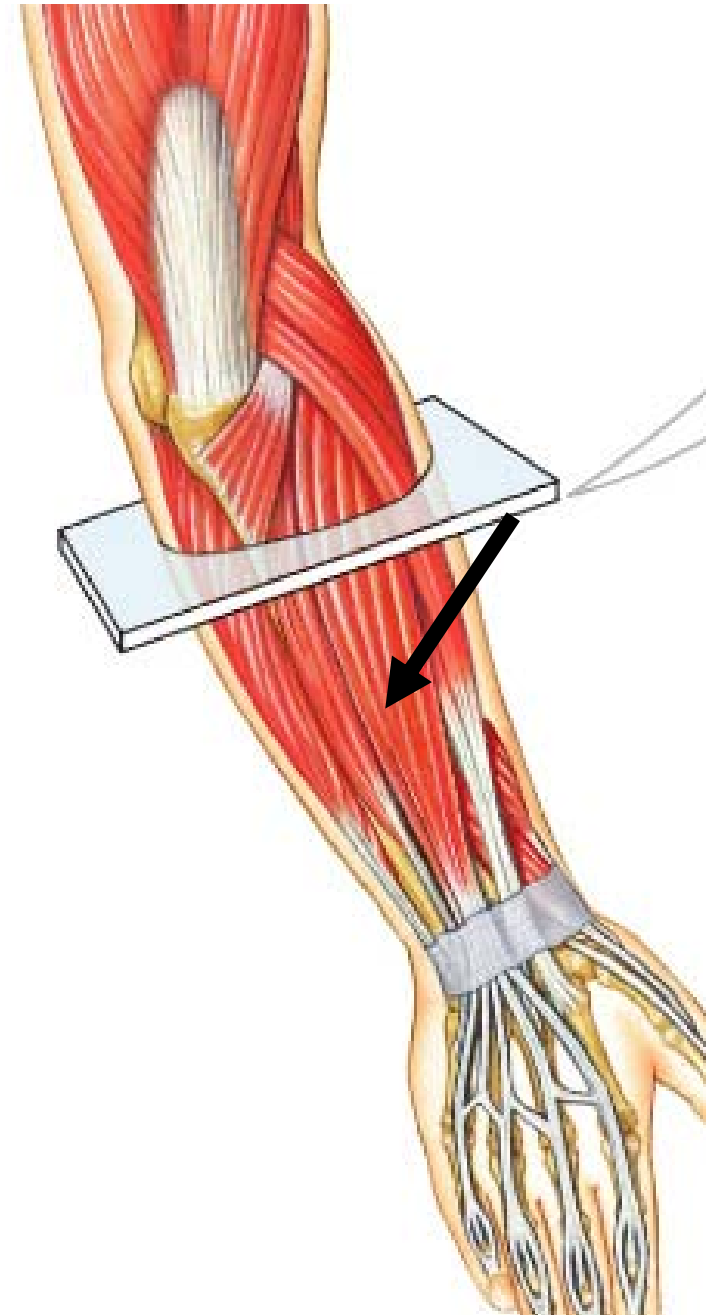


Posterior, Superficial Layer

# Extensor Digitorum

---

- **Origin:** Lateral epicondyle of humerus
- **Insertion:** Into distal phalanx by 4 tendons
- **Action:** Extends fingers and hand

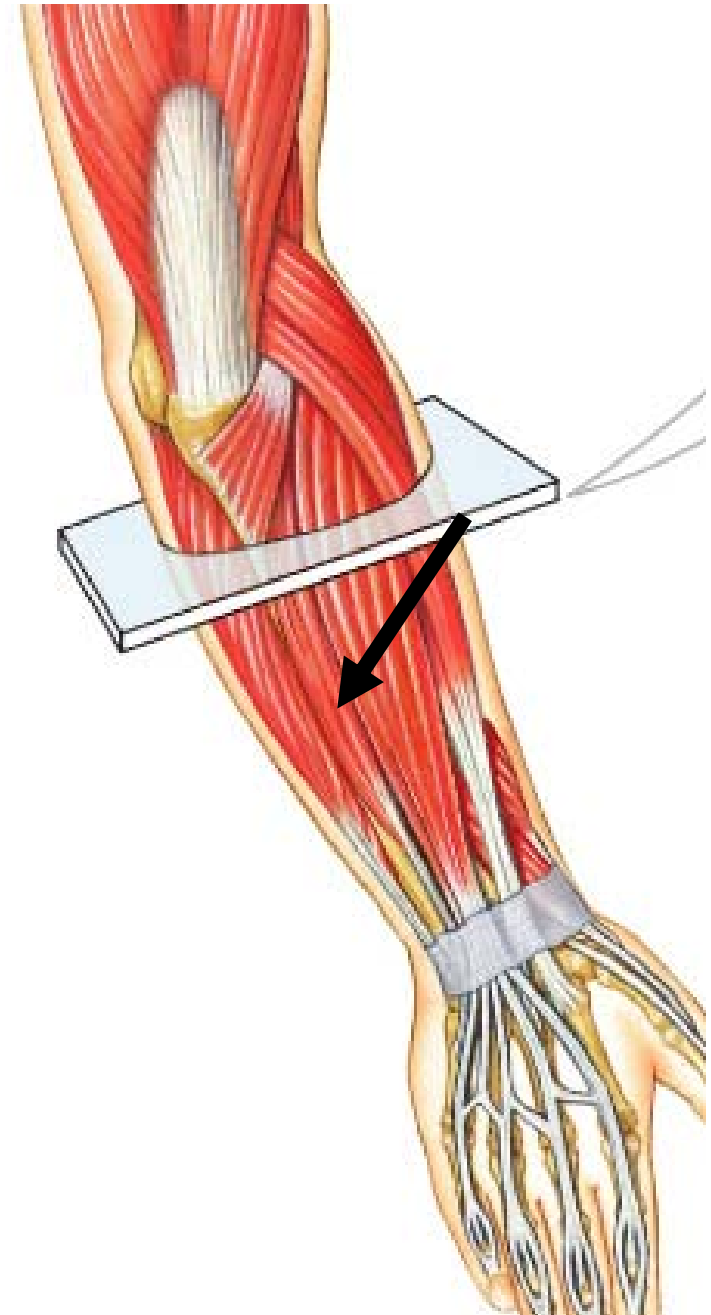


Posterior, Superficial Layer

# Extensor Carpi Ulnaris

---

- **Origin:** Lateral epicondyle of humerus and posterior border of ulna
- **Insertion:** Fifth metacarpal
- **Action:** Extends and adducts hand

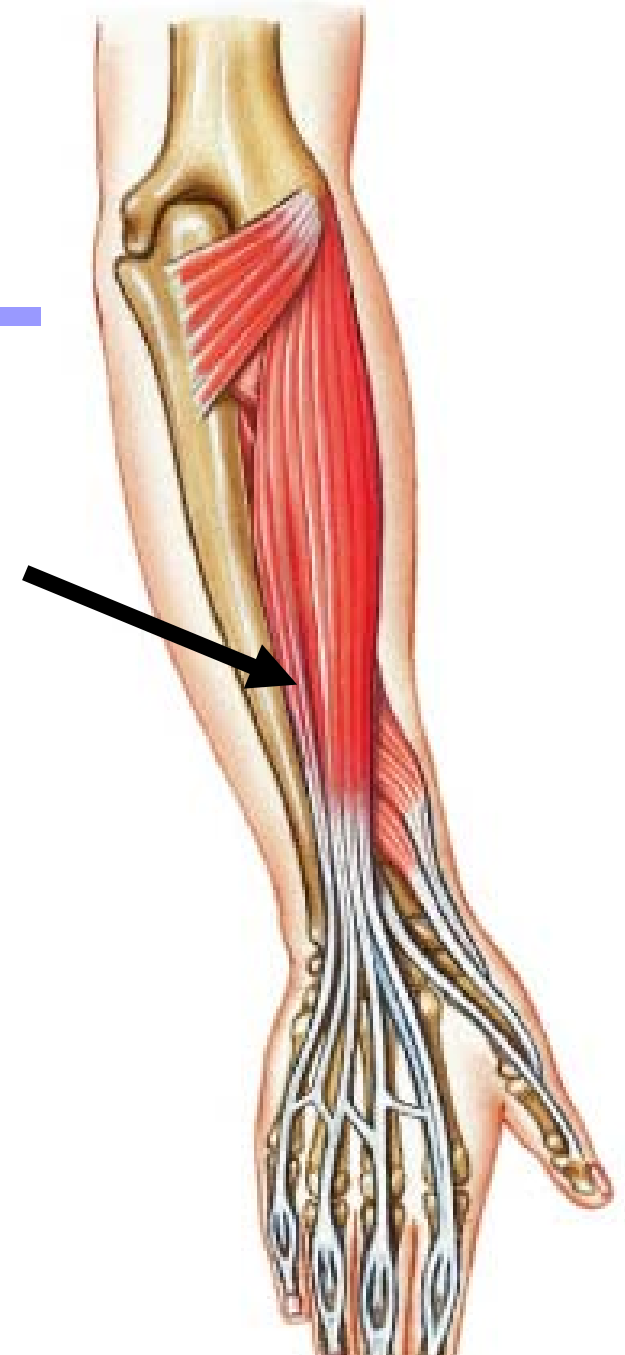


Posterior, Superficial Layer

# Extensor Digiti Minimi

---

- **Origin:** Lateral epicondyle of humerus
- **Insertion:** Extensor expansion of little finger
- **Action:** Extends 5<sup>th</sup> digit and hand

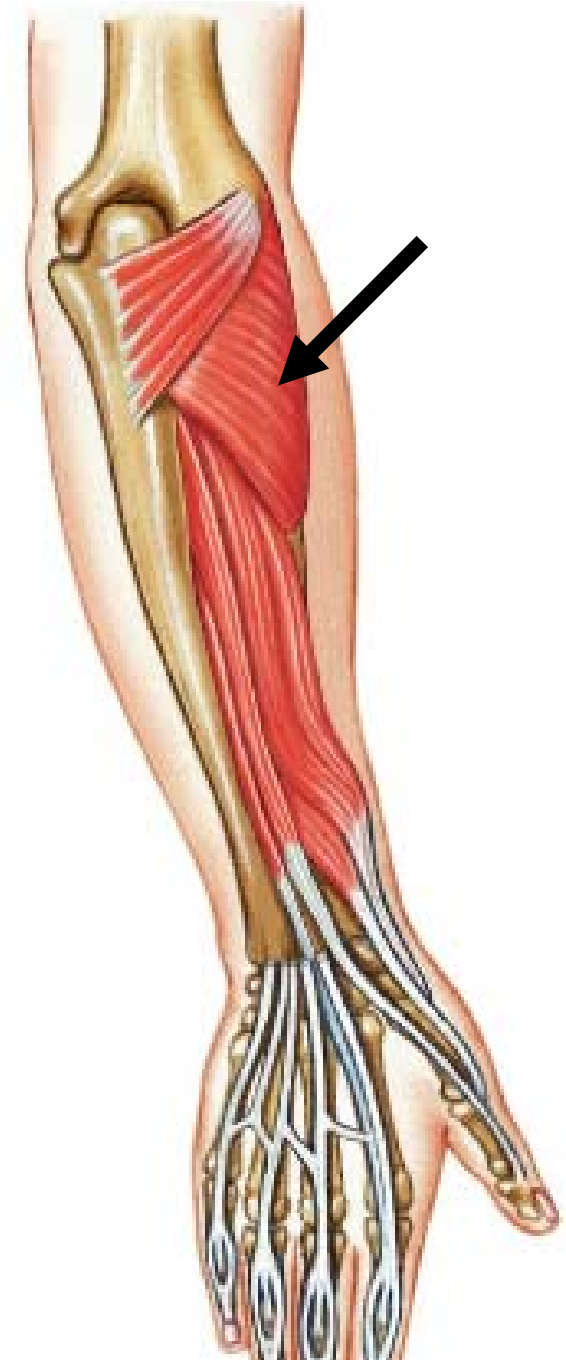

Posterior, Middle Layer

# Supinator

---

- **Origin:** Lateral epicondyle of humerus, supinator crest of ulna
- **Insertion:** Lateral surface and posterior border of radius
- **Action:** Supinates forearm

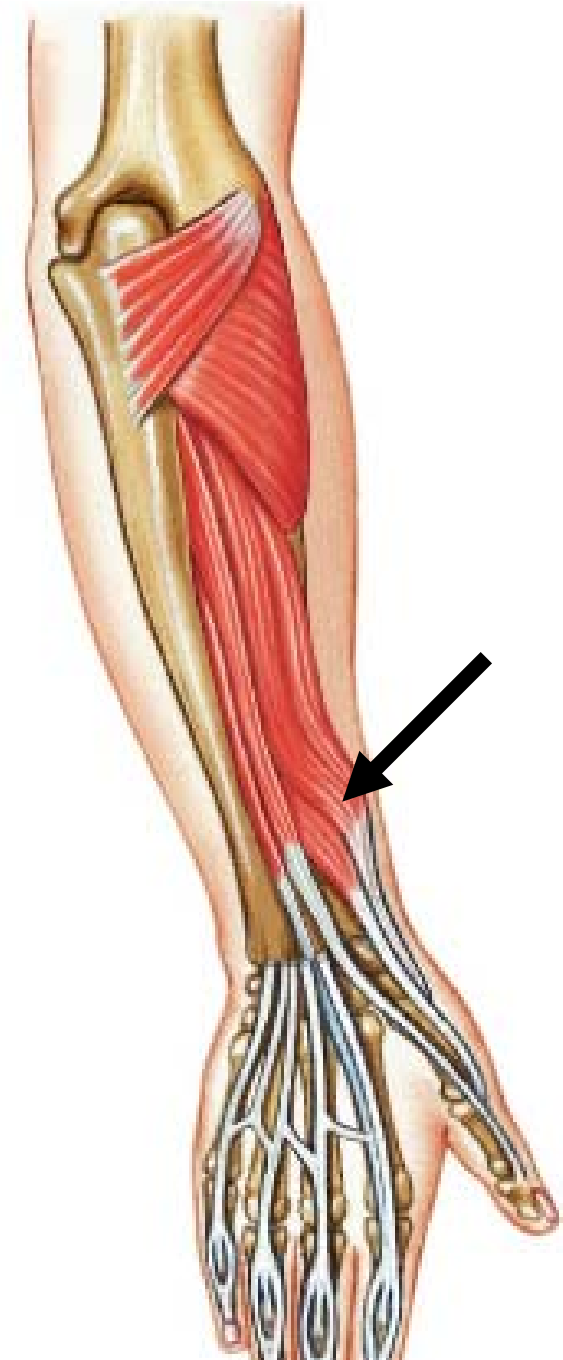


Posterior, Deepest Layer

# Abductor Pollicis Longus

---

- **Origin:** Posterior surface of ulna and radius, and interosseous membrane
- **Insertion:** First metacarpal
- **Action:** Abducts thumb and hand



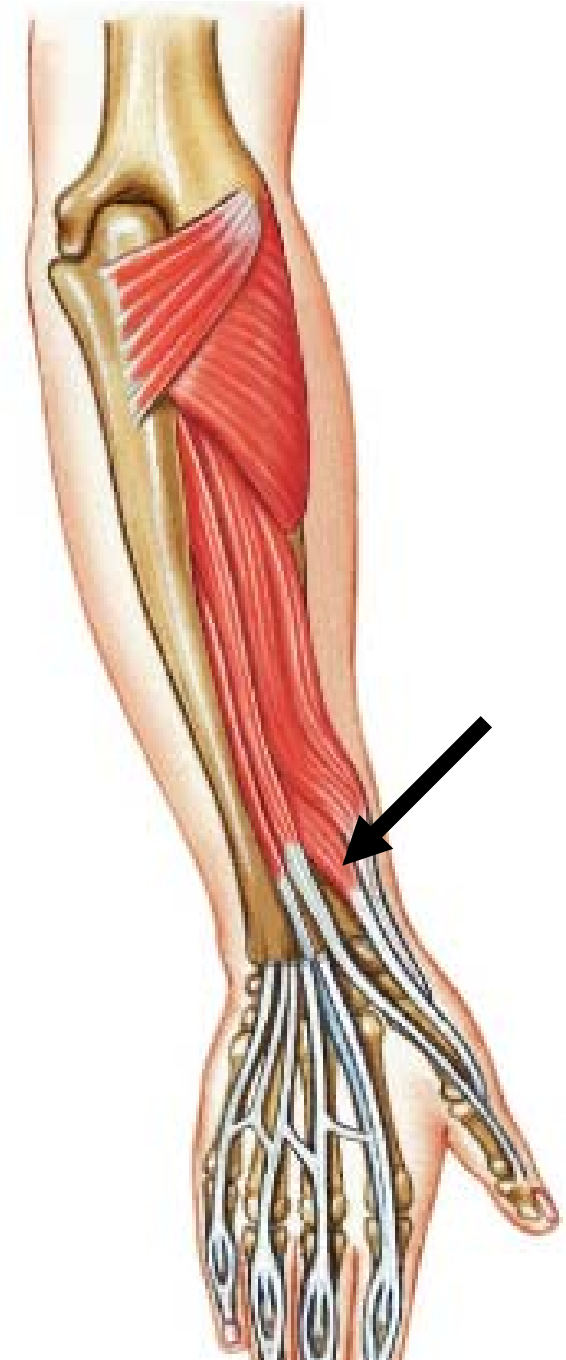Posterior, Deepest Layer



# Extensor Pollicis Brevis

---

- **Origin:** Middle third of radius and interosseous membrane
- **Insertion:** Base of proximal phalanx of thumb
- **Action:** Extends thumb

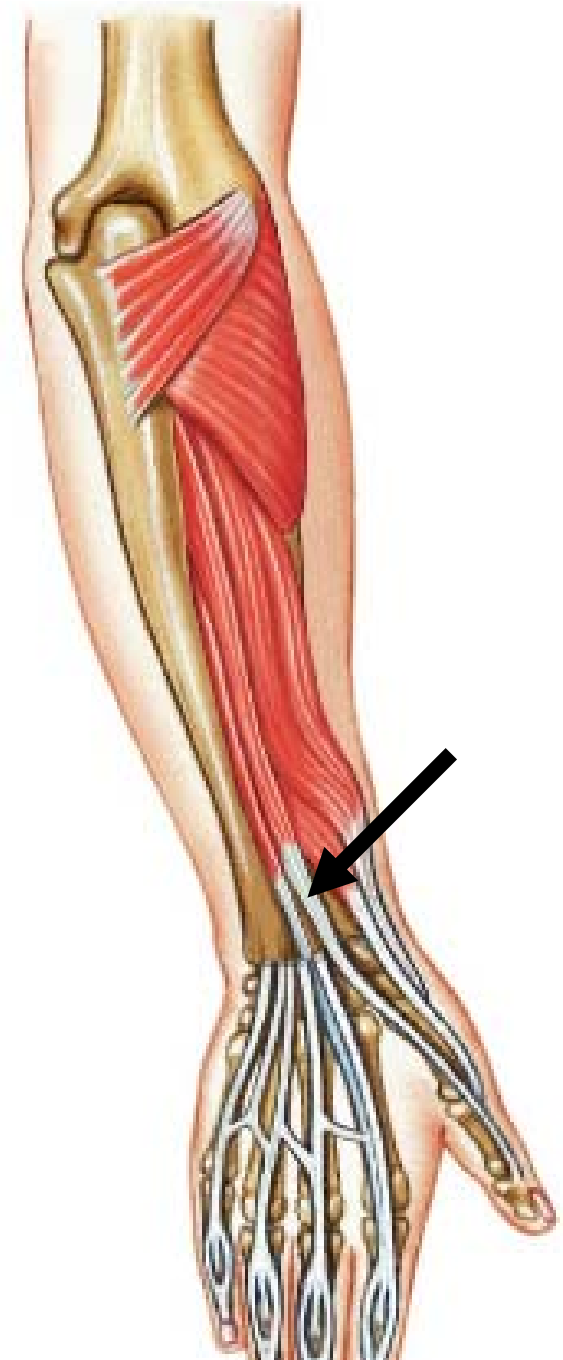

Posterior, Deepest Layer

# Extensor Pollicis Longus

---

- **Origin:** Middle third of ulna and interosseous membrane
- **Insertion:** Base of distal phalanx of thumb
- **Action:** Extends thumb



Posterior, Deepest Layer

# MUSCLES OF DEEP BACK AND GLUTEAL REGION

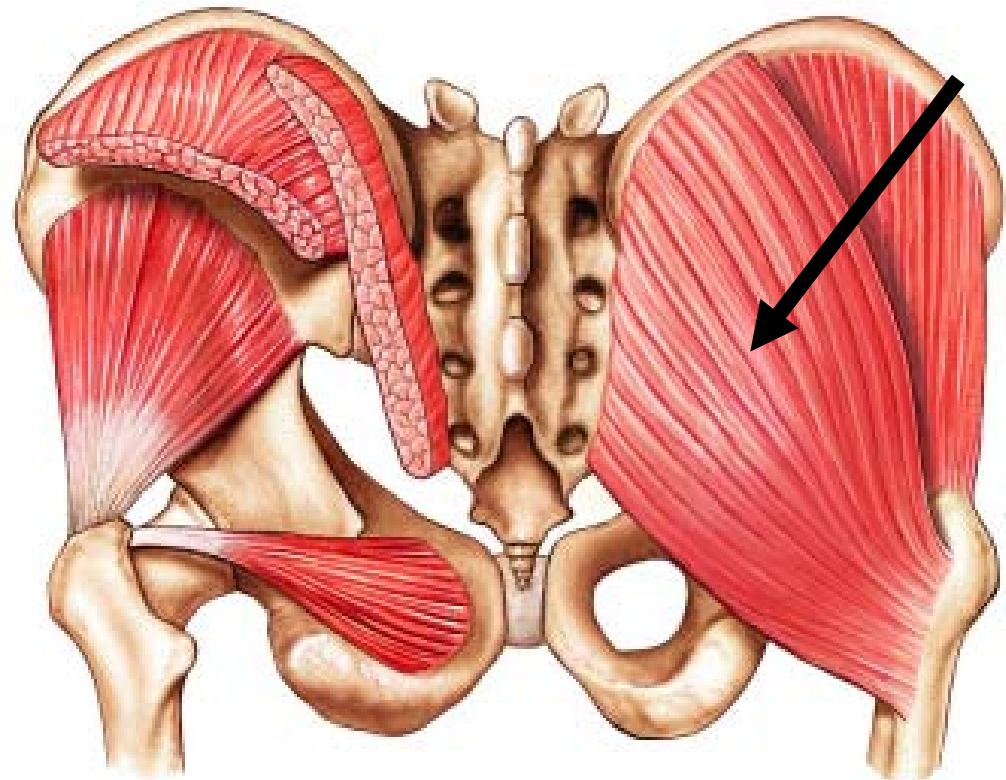
---



# Gluteus Maximus

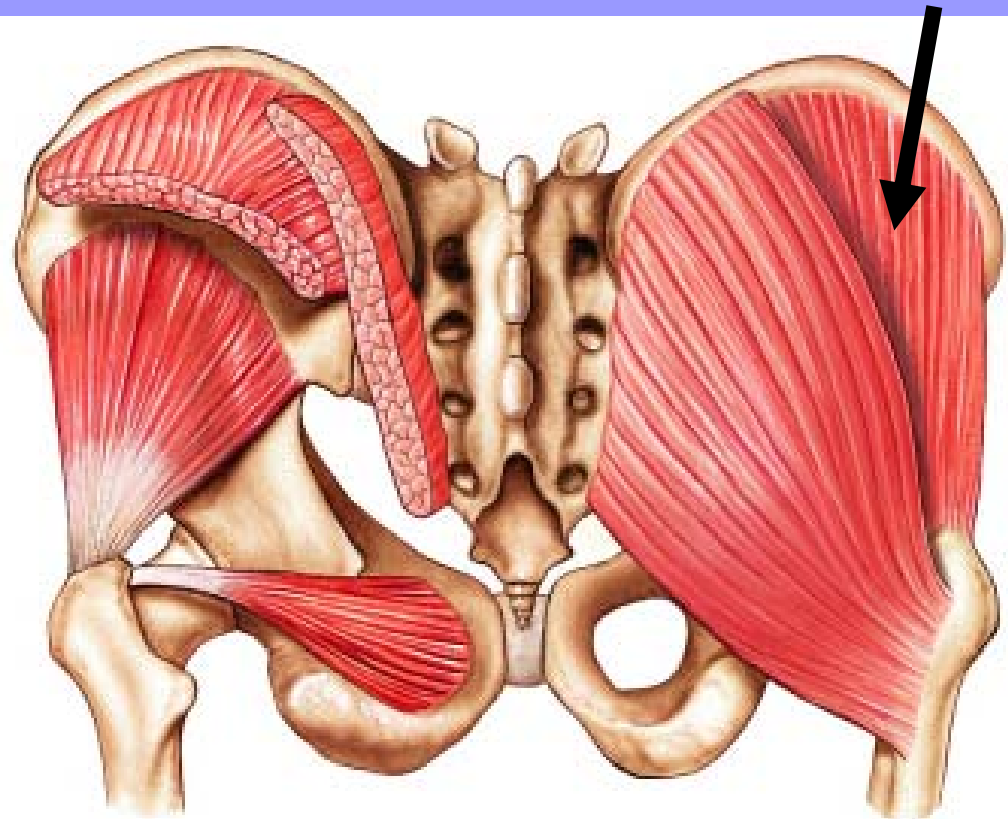
---

- **Origin:** Upper portion of ilium, the sacrum and coccyx
- **Insertion:** Gluteal tuberosity and iliotibial tract
- **Action:** Principal extensor and lateral rotator of femur



# Gluteus Medius

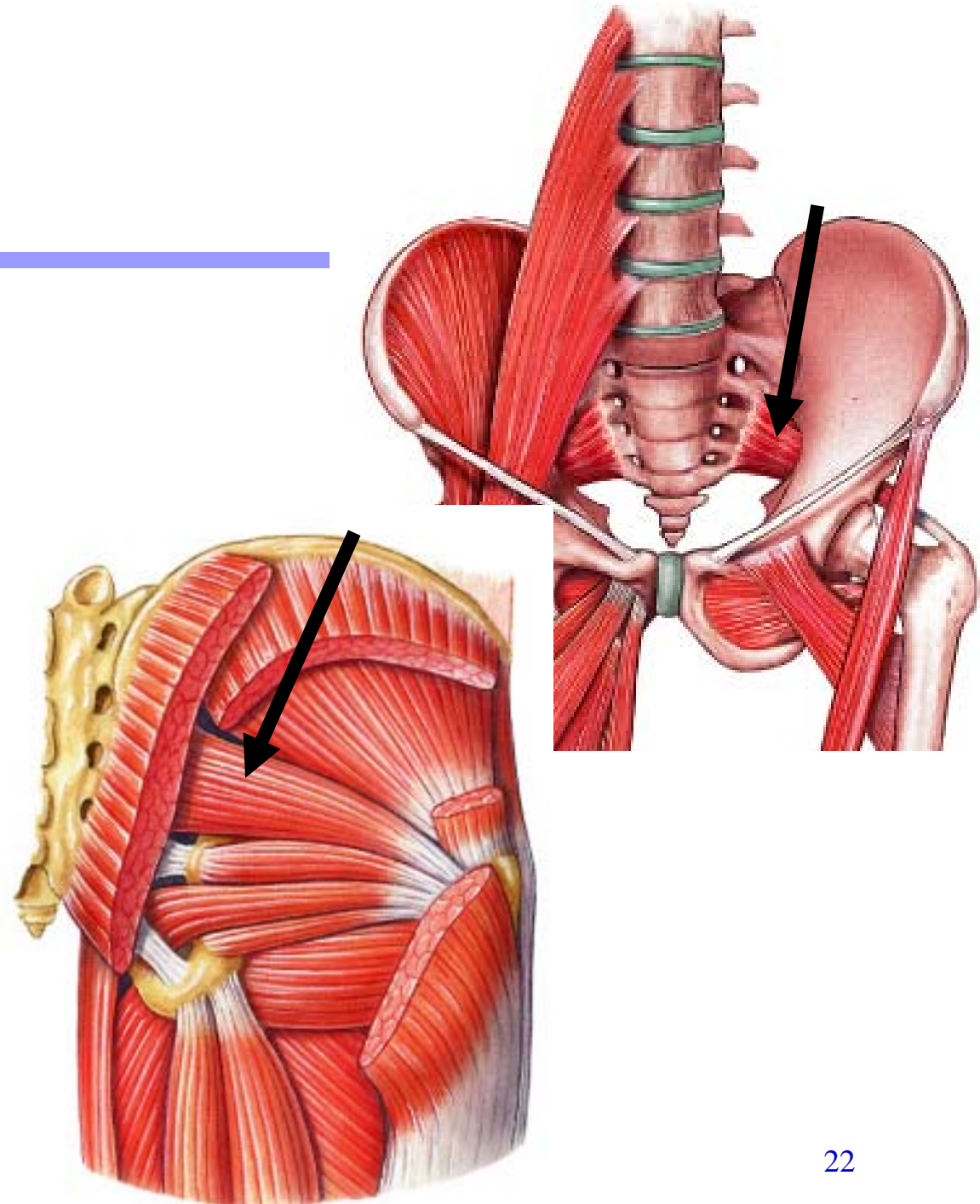
- **Origin:** Middle portion of ilium
- **Insertion:** Oblique ridge on greater trochanter of femur
- **Action:** Abducts femur, stabilizes contralateral hip while standing on one leg



# Piriformis

---

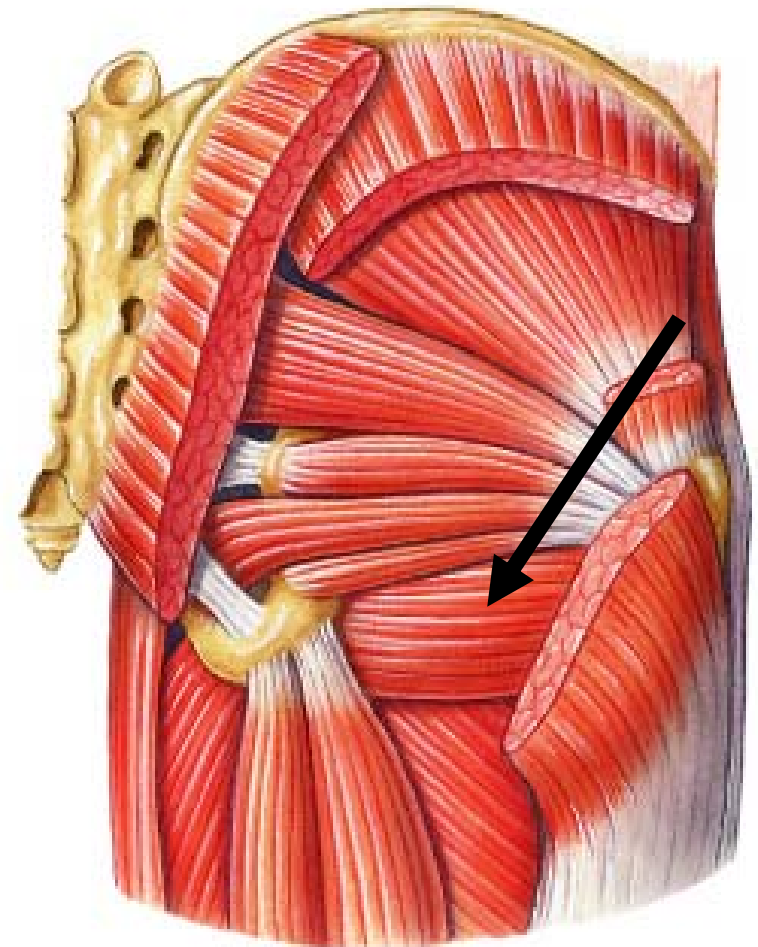
- **Origin:** Pelvic surface of sacrum
- **Insertion:** Greater trochanter of femur
- **Action:** Rotates femur laterally



# Quadratus Femoris

---

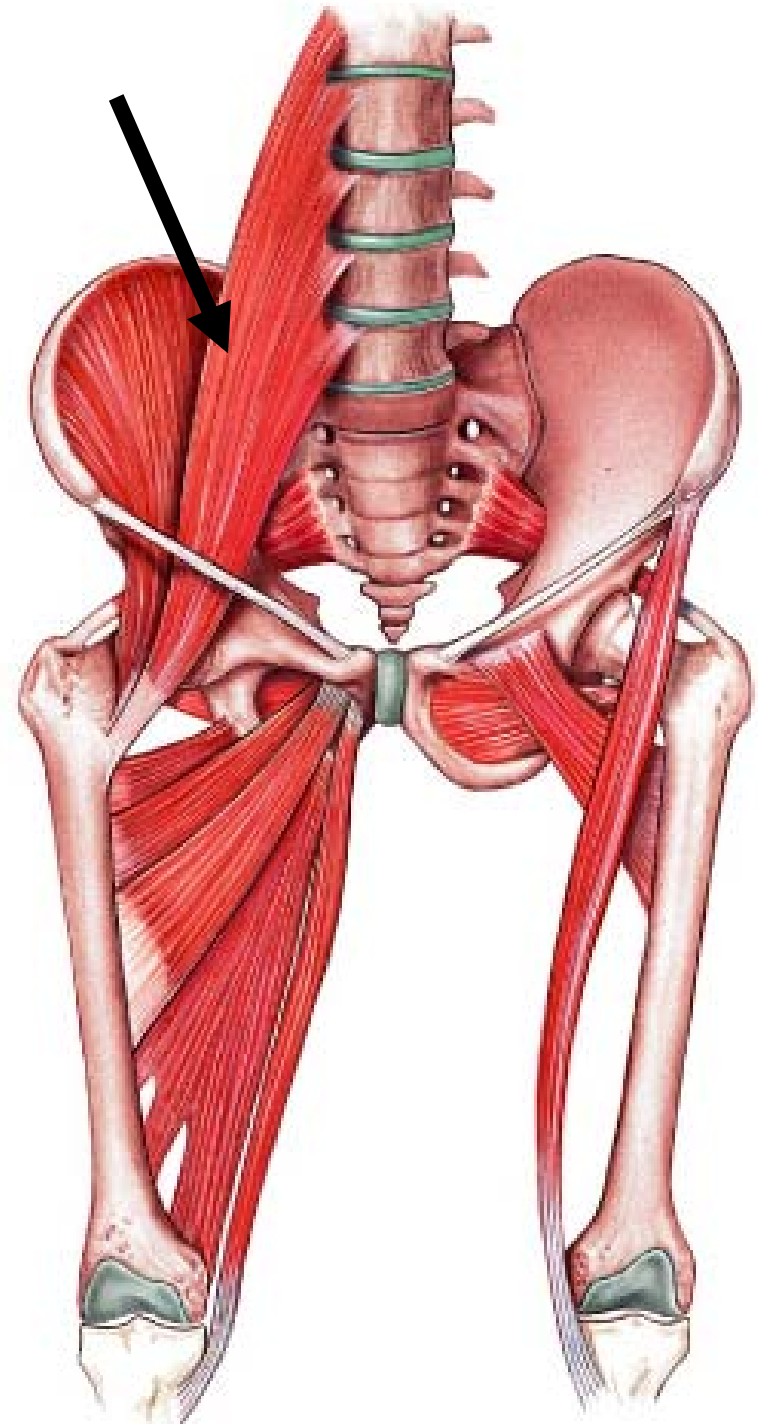
- **Origin:** Ischial tuberosity
- **Insertion:** Greater trochanter and shaft of femur
- **Action:** Rotates thigh laterally



# Psoas Major

---

- **Origin:** Transverse processes of bodies of lumbar vertebrae
- **Insertion:** Lesser trochanter of femur with iliacus
- **Action:** Flexes trunk and flexes and laterally rotates thigh

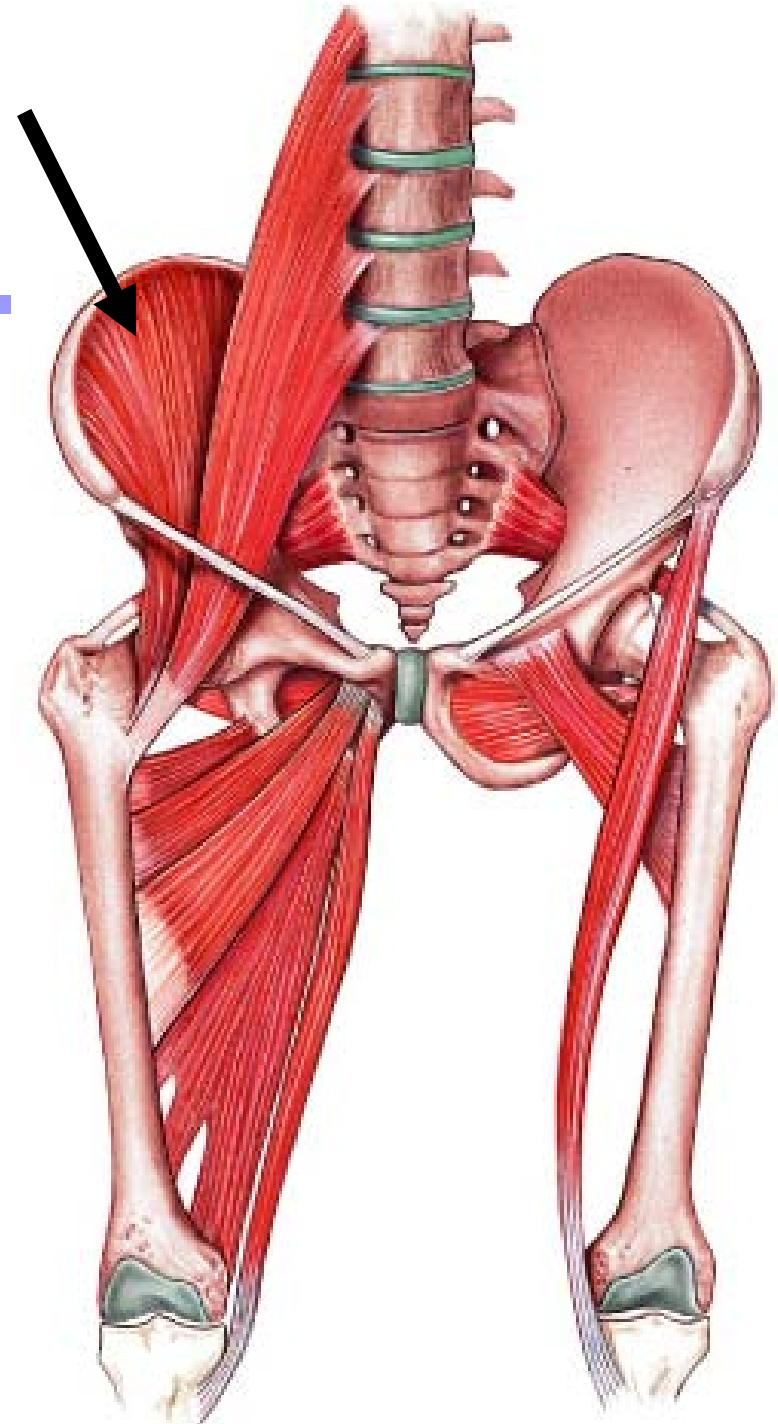




# Iliacus

---

- **Origin:** Iliac fossa and lateral margin of sacrum
- **Insertion:** Lesser trochanter of femur with psoas major
- **Action:** Flexes and laterally rotates femur



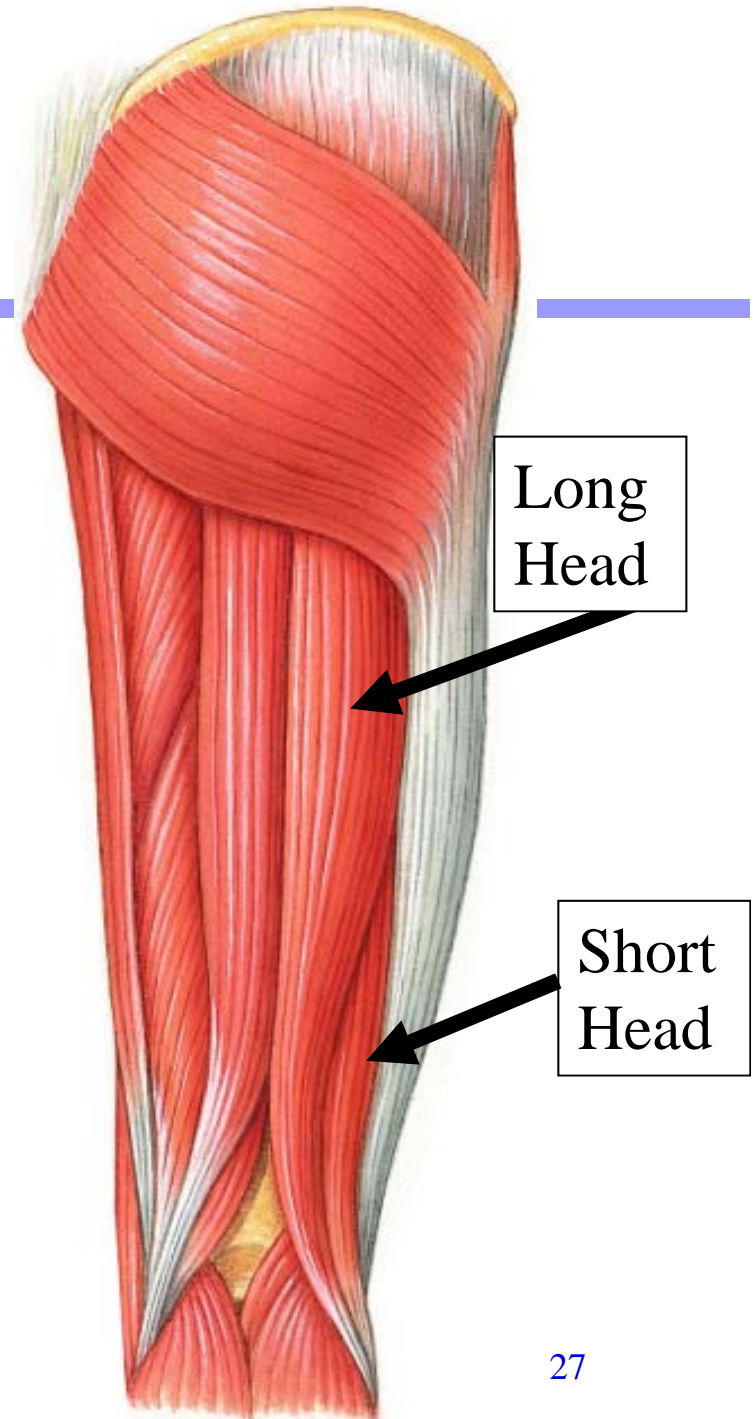
# POSTERIOR COMPARTMENT OF THE THIGH (HAMSTRINGS)

---



# Biceps Femoris

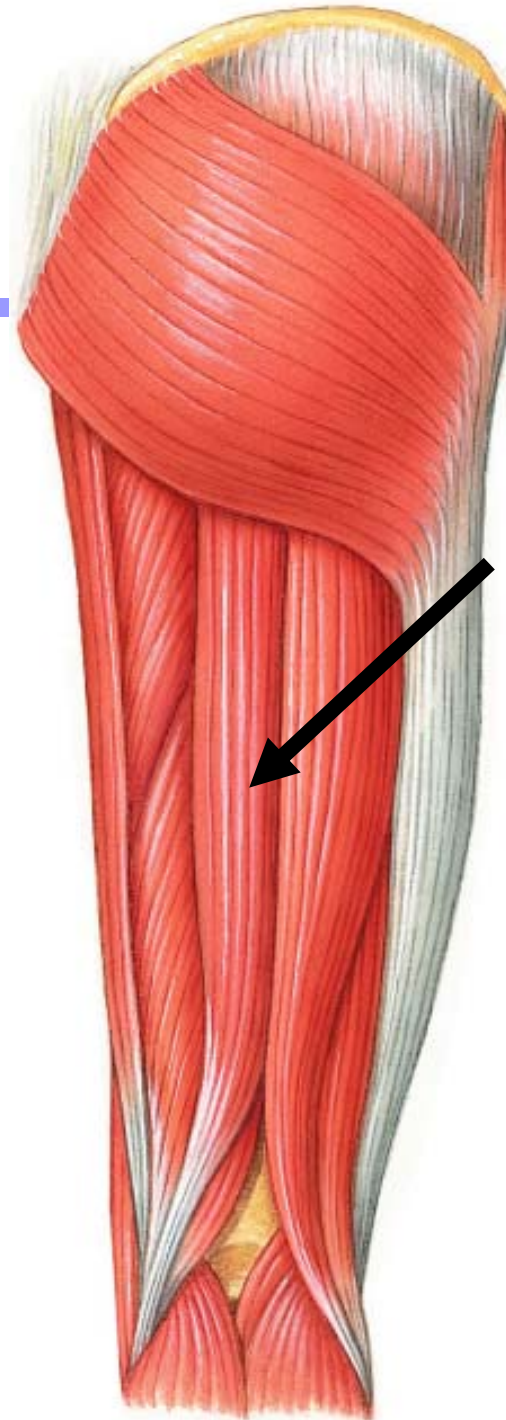
- **Origin:** Long head, ischial tuberosity; Short head, lateral supracondylar ridge of femur
- **Insertion:** Head of fibula and lateral condyle of tibia
- **Action:** Extends femur and flexes leg



# Semitendinosus

---

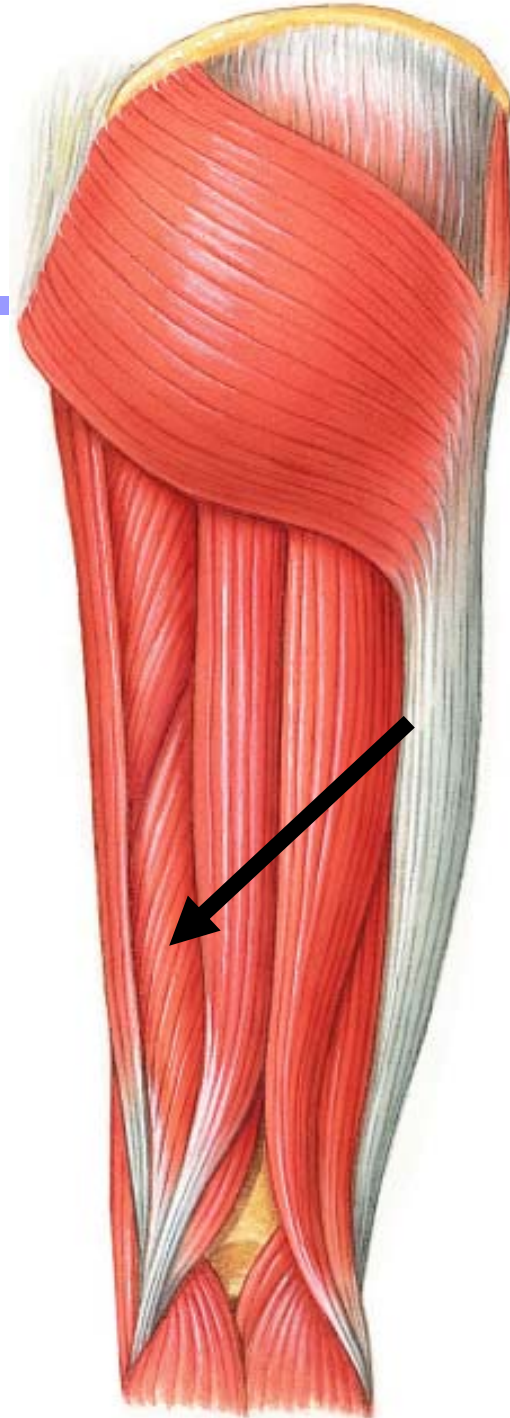
- **Origin:** Ischial tuberosity
- **Insertion:** Medial condyle of tibia
- **Action:** Extends femur and flexes leg



# Semimembranosus

---

- **Origin:** Ischial tuberosity
- **Insertion:** Medial condyle of tibia
- **Action:** Extends femur and flexes leg



# ANTERIOR COMPARTMENT OF THE THIGH

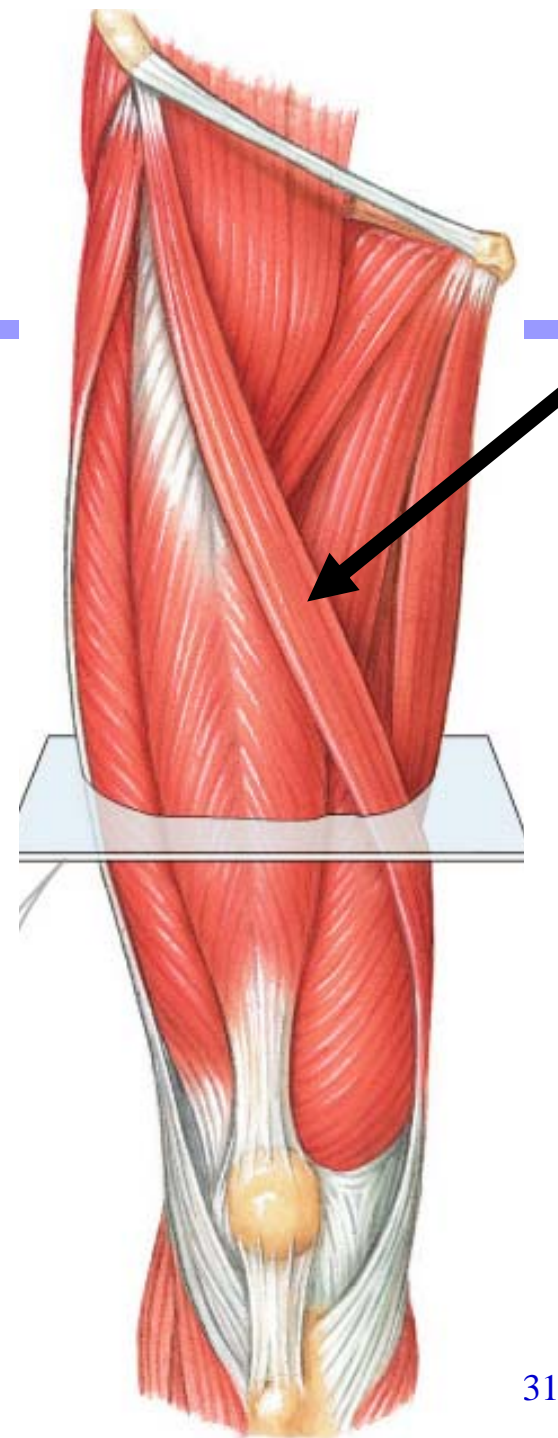
---



# Sartorius

---

- **Origin:** Anterior superior iliac spine
- **Insertion:** Medial margin of tibial tuberosity
- **Action:** Flexes both femur and tibia

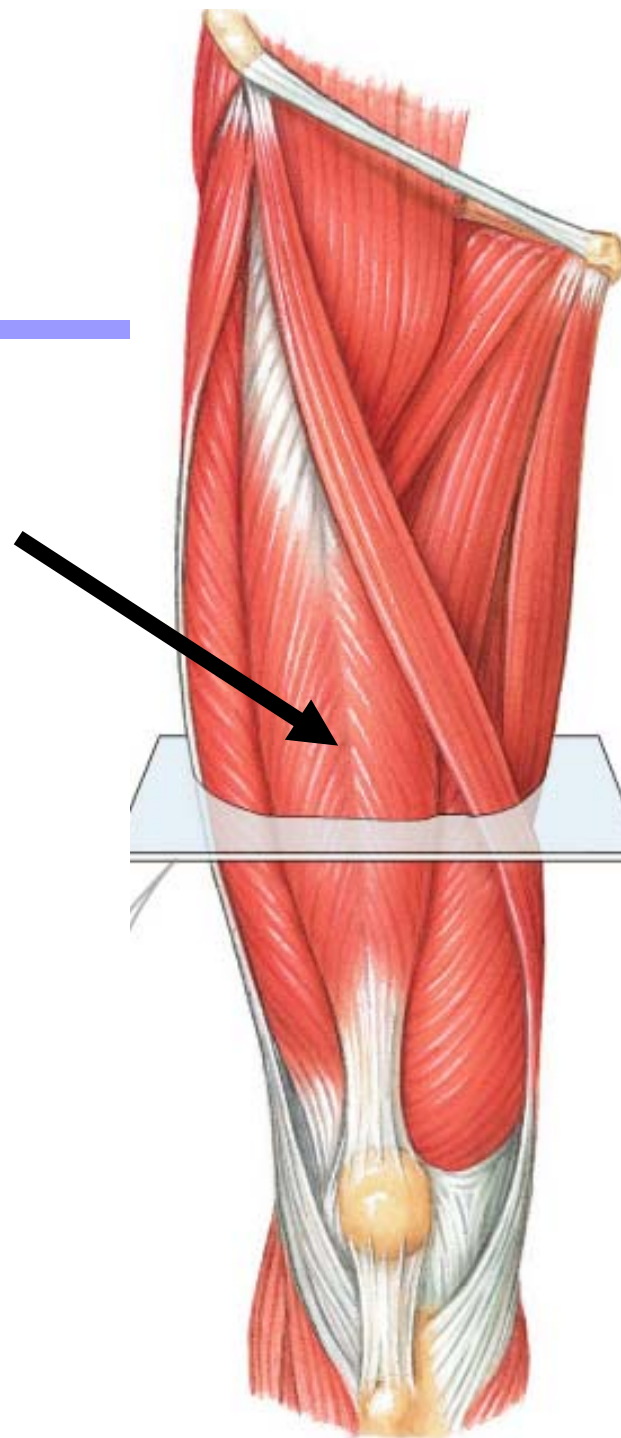




# Rectus Femoris

---

- **Origin:** Anterior inferior iliac spine and upper margin of acetabulum
- **Insertion:** Tibial tuberosity
- **Action:** Extends tibia and flexes femur

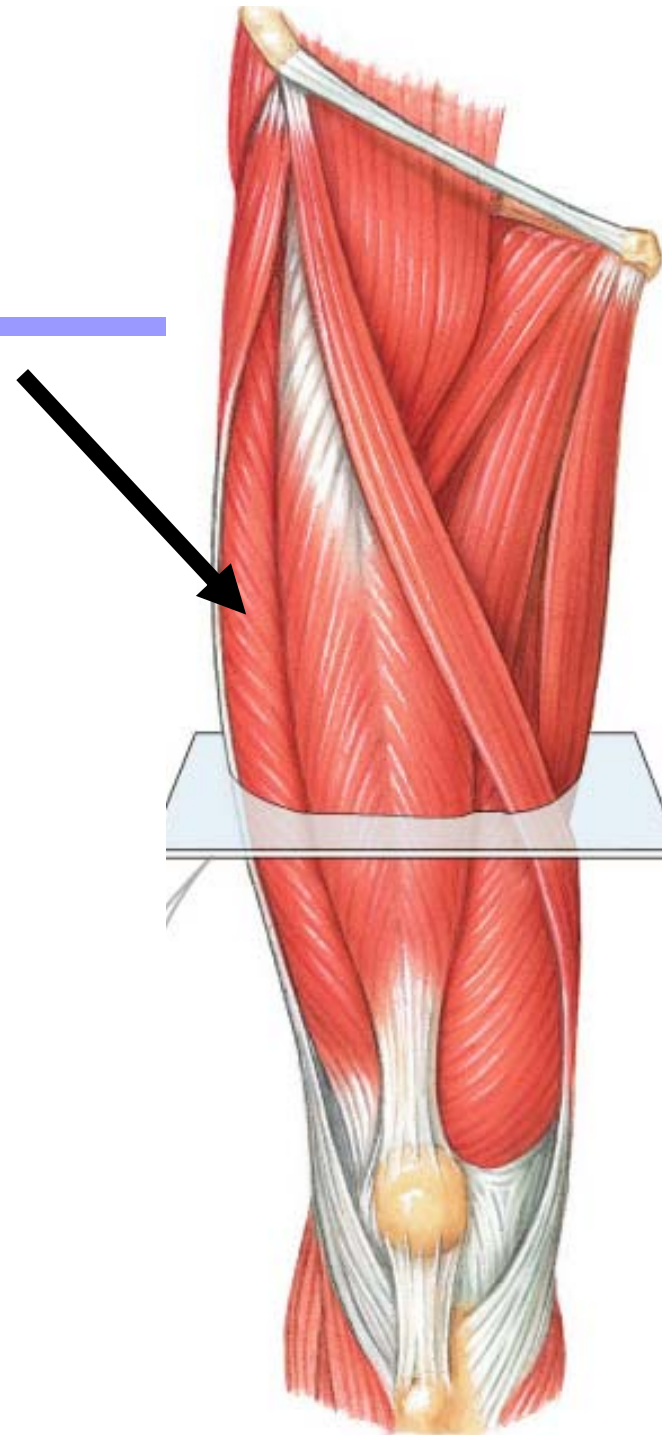




# Vastus Lateralis

---

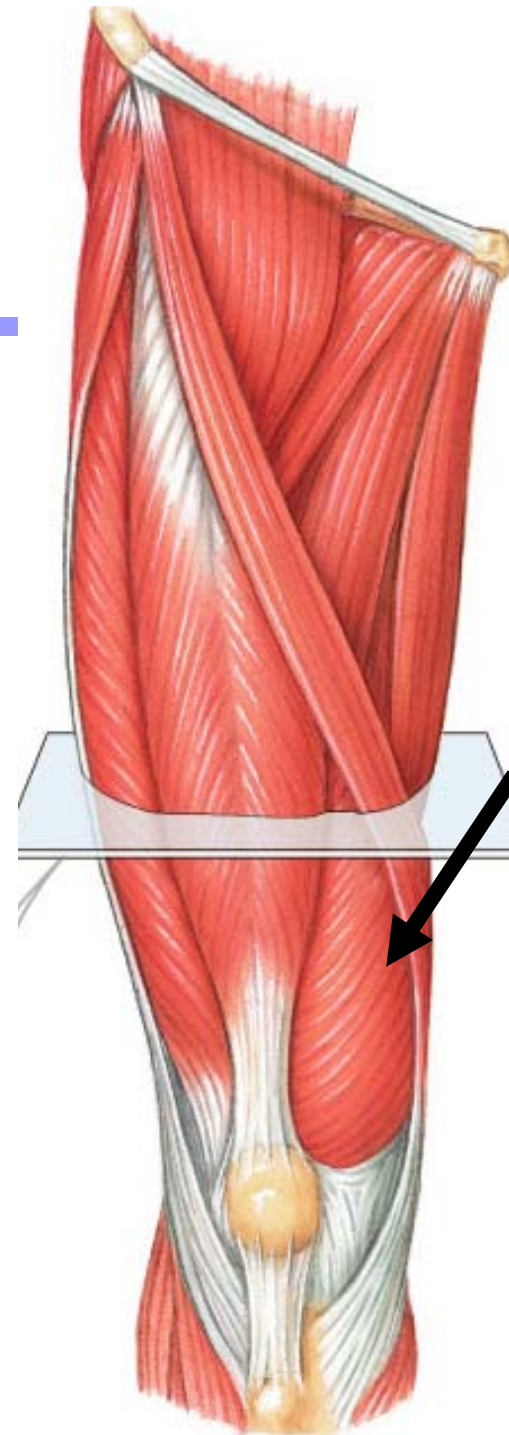
- **Origin:** Intertrochanteric line and linea aspera of femur
- **Insertion:** Tibial tuberosity
- **Action:** Extends tibia



# Vastus Medialis

---

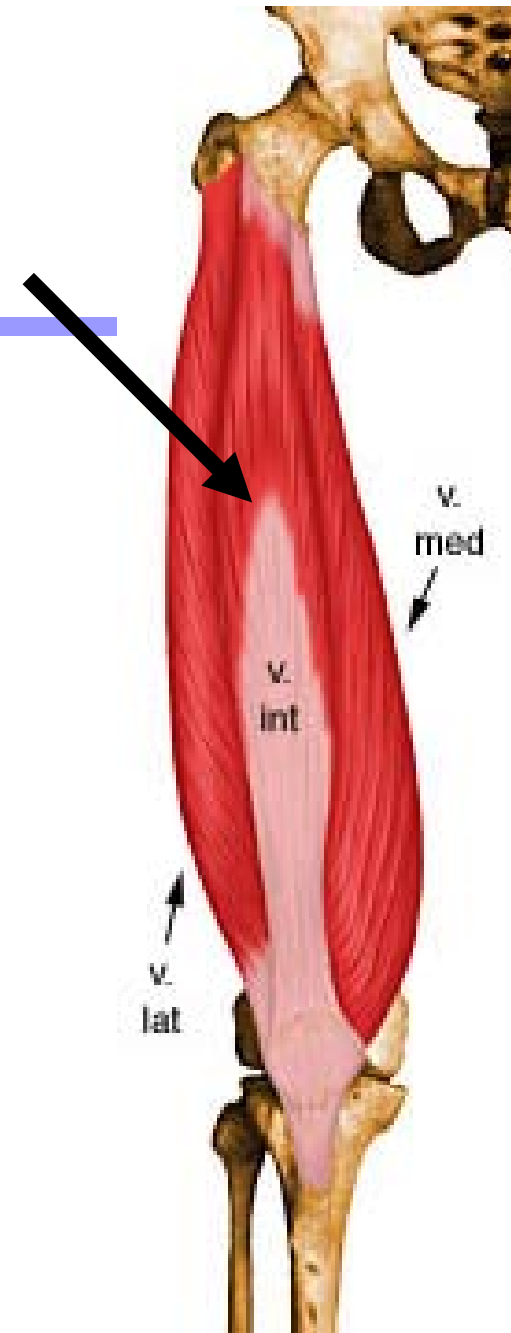
- **Origin:** Intertrochanteric line and linea aspera of femur
- **Insertion:** Tibial tuberosity
- **Action:** Extends tibia



# Vastus Intermedius


---

- **Origin:** Upper shaft of femur
- **Insertion:** Tibial tuberosity
- **Action:** Extends tibia



# POSTERIOR COMPARTMENT OF THE THIGH

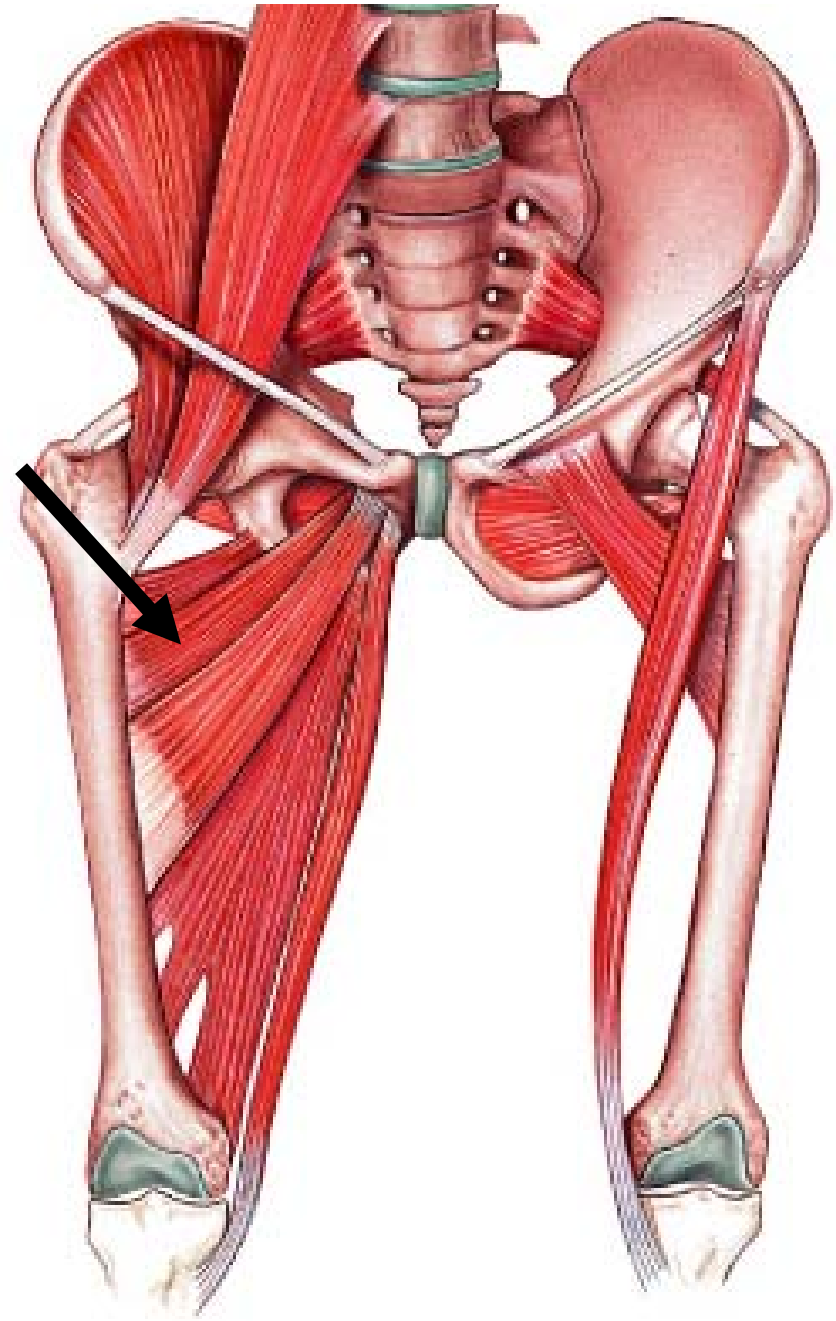
---



# Adductor Brevis

---

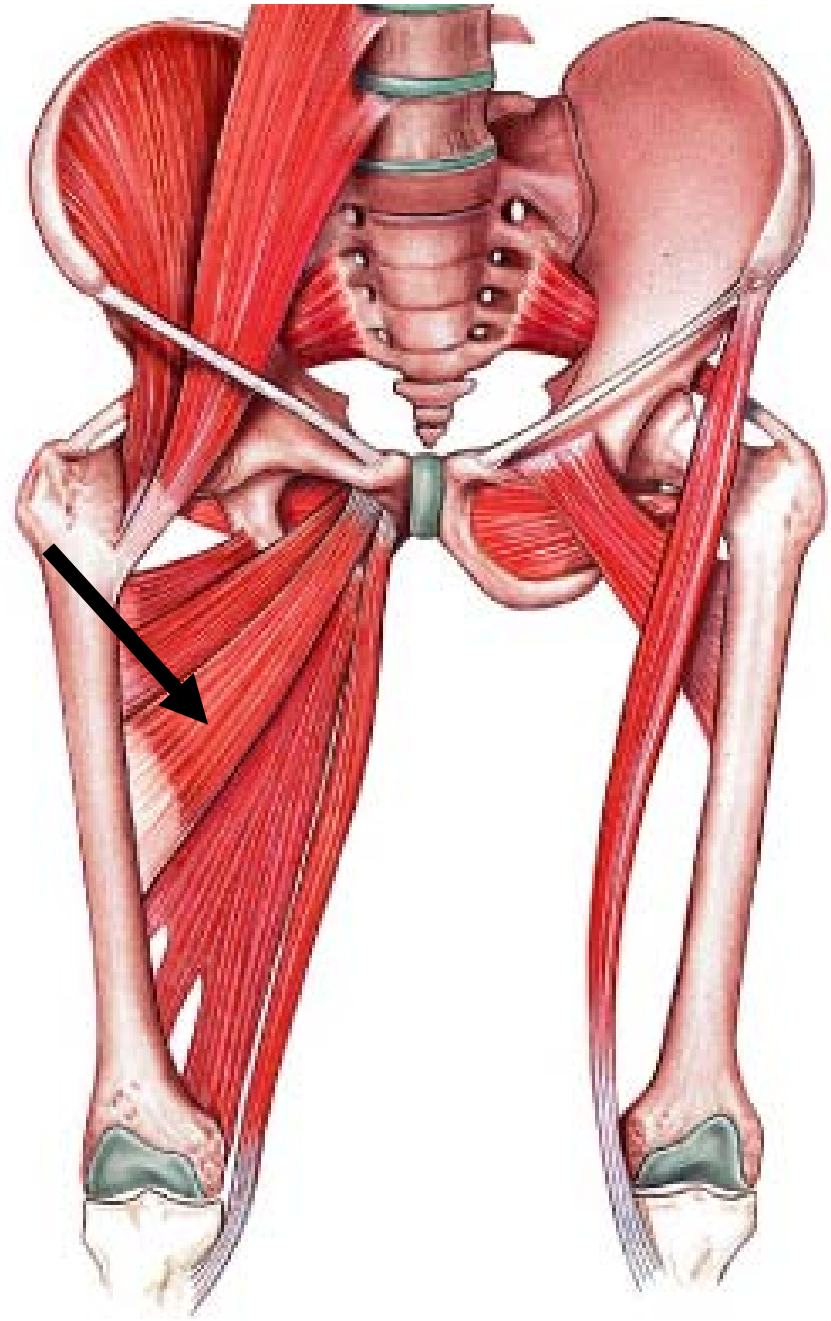
- **Origin:** Inferior pubic ramus
- **Insertion:** Upper part of linea aspera
- **Action:** Adducts, flexes, and medially rotates femur



# Adductor Longus

---

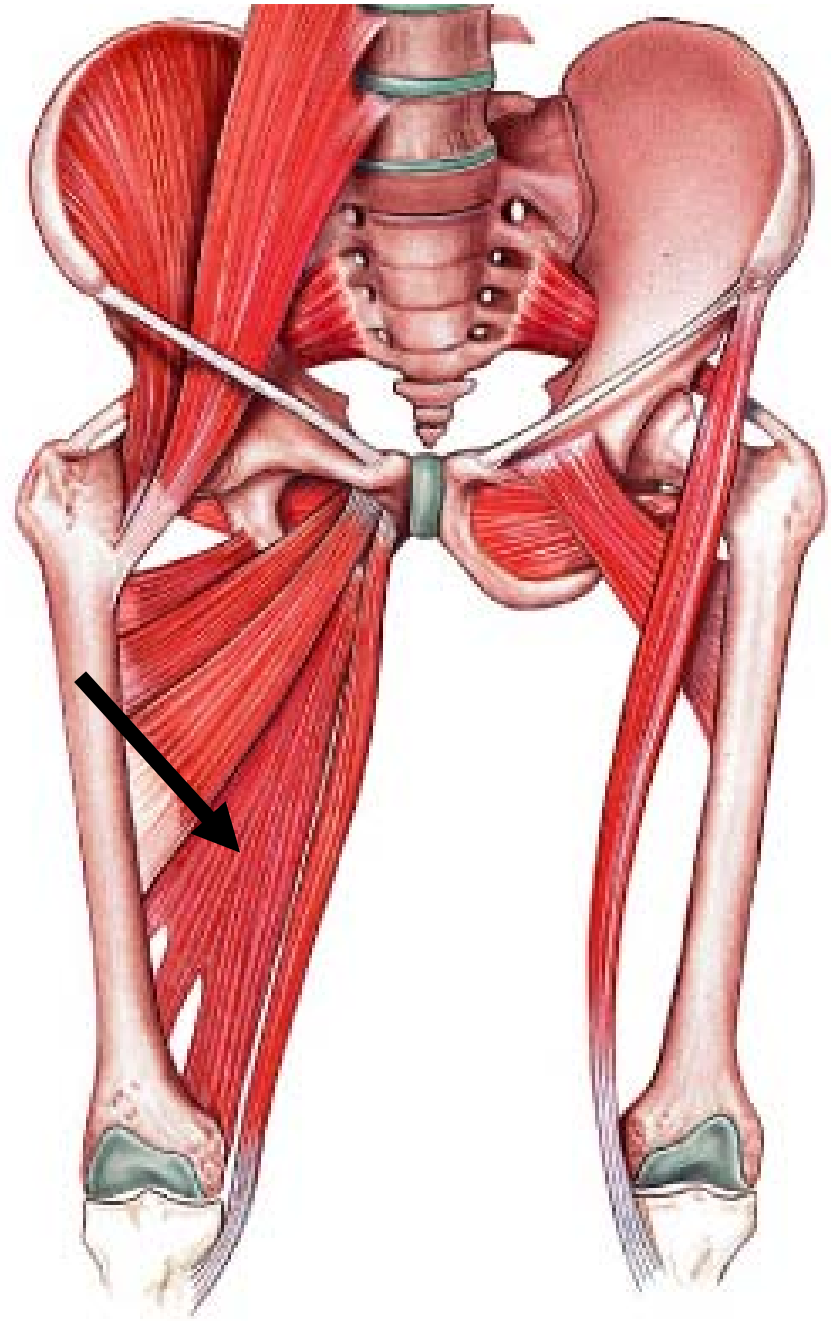
- **Origin:** Between pubic rami near symphysis
- **Insertion:** Middle third of linea aspera
- **Action:** Adducts, flexes & medially rotates femur



# Adductor Magnus

---

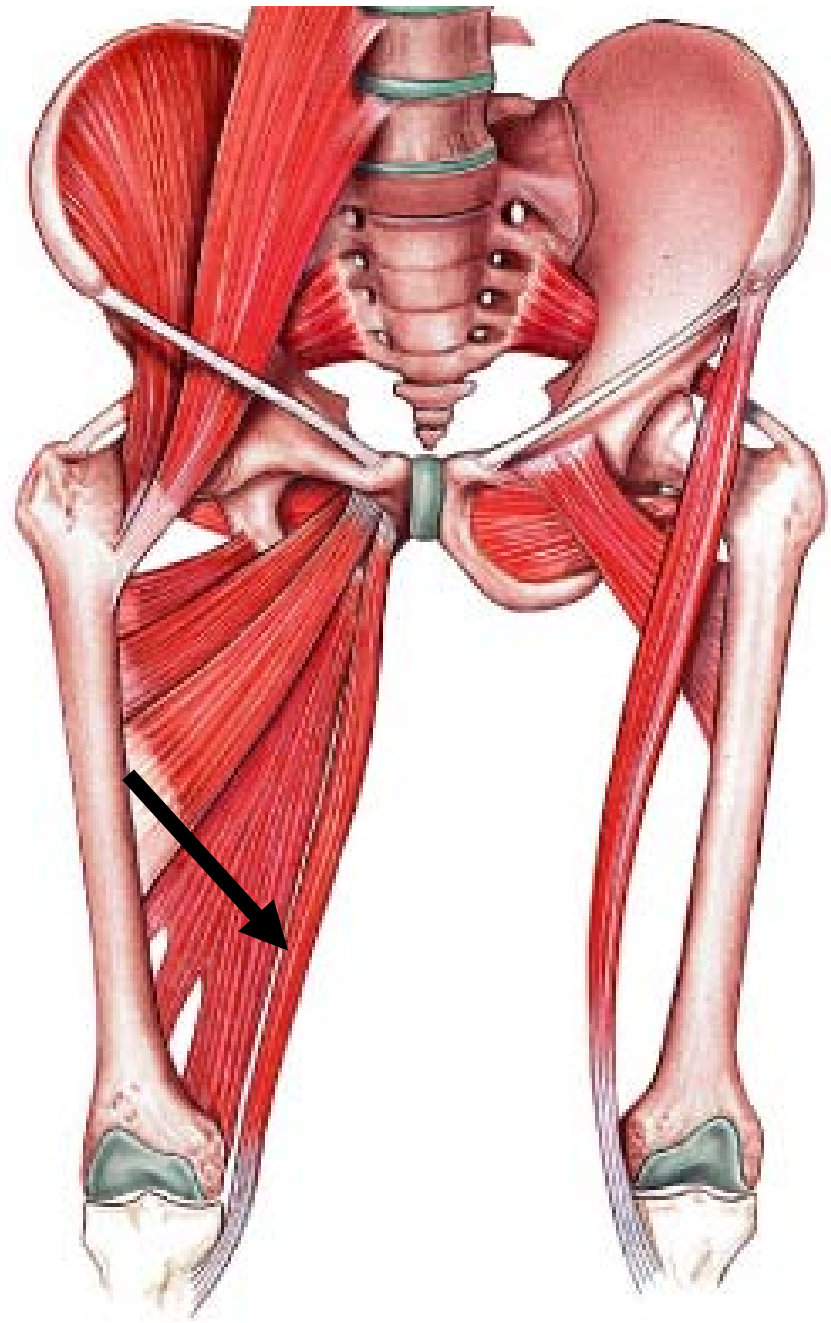
- **Origin:** Pubic arch and ischial tuberosity
- **Insertion:** Linea aspera and adductor tubercle
- **Action:** Adducts, flexes, and laterally and medially rotates femur



# Gracilis

---


- **Origin:** Inferior pubis near symphysis
- **Insertion:** Upper portion of tibia
- **Action:** Adducts, flexes, medially rotates tibia





# ANTERIOR AND MEDIAL THIGH

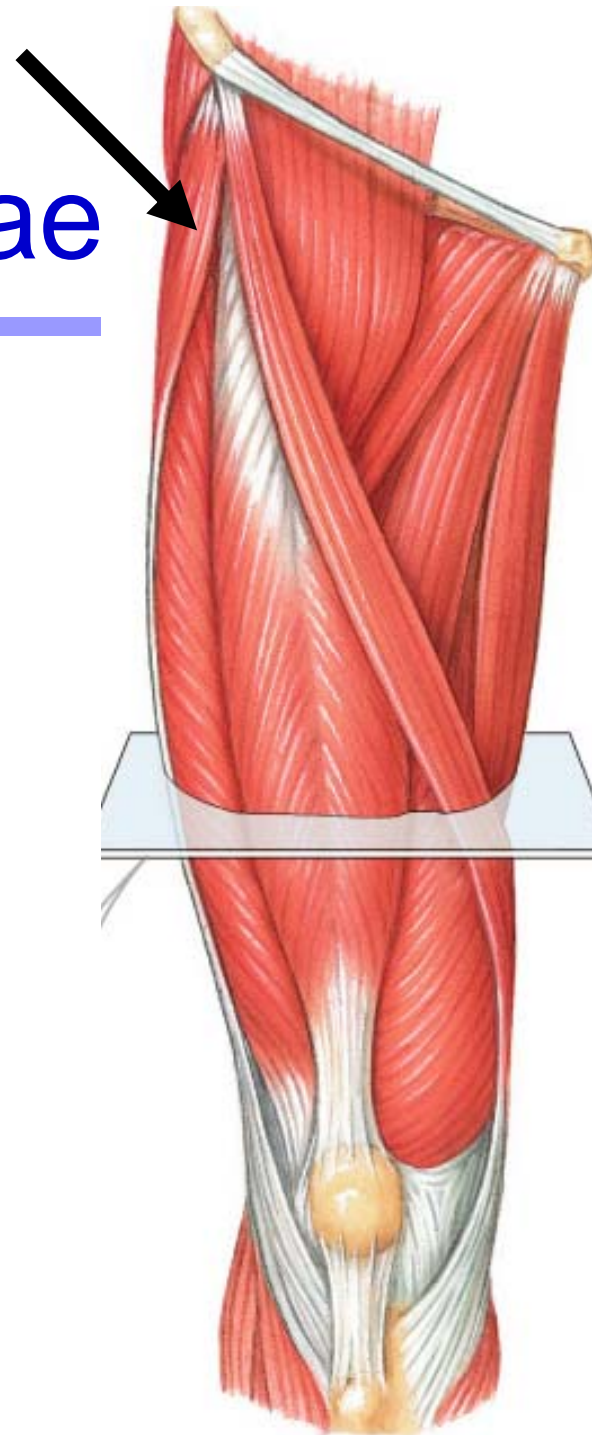
---



# Tensor Fasciae Latae

---

- **Origin:** Iliac crest
- **Insertion:** Iliotibial tract
- **Action:** Flexes thigh, stabilizes knee



# SUPERFICIAL POSTERIOR COMPARTMENT OF THE LEG

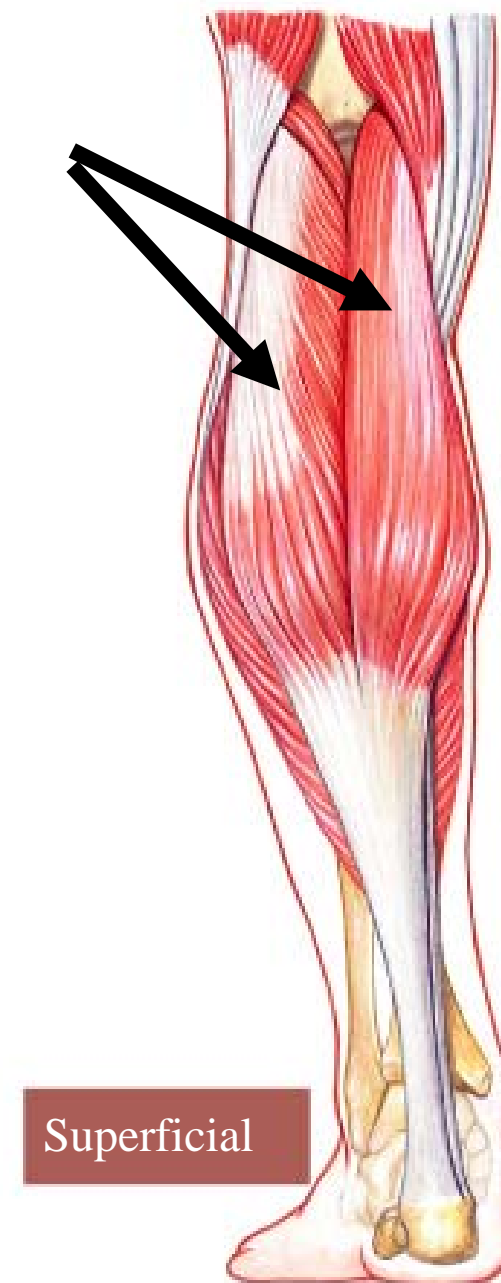---



# Gastrocnemius

---

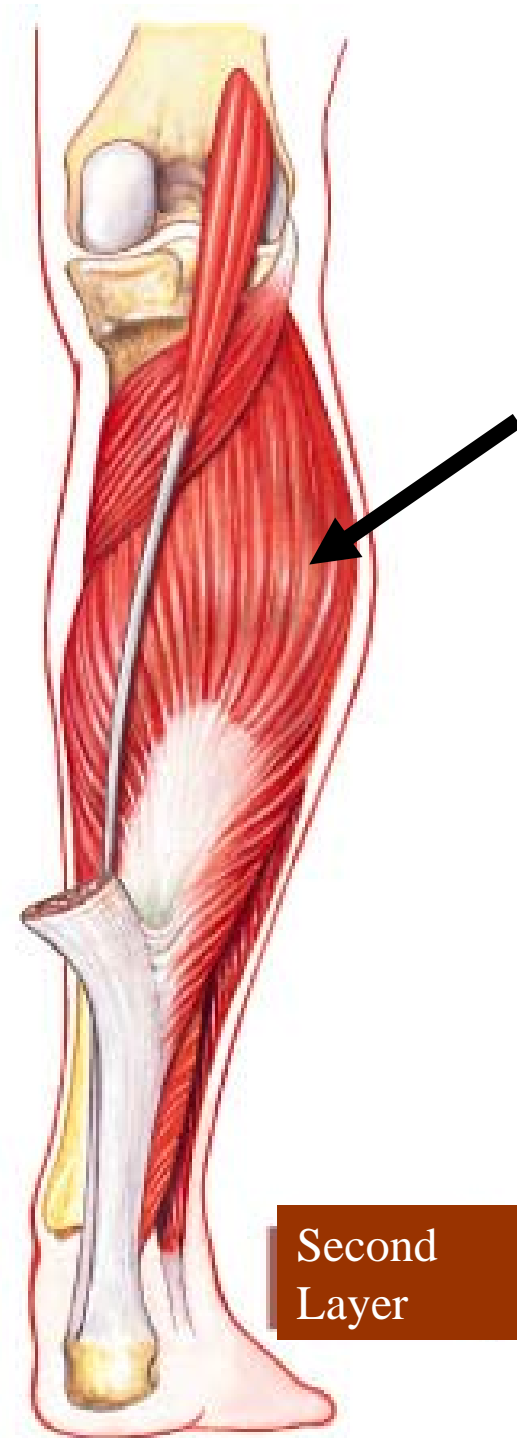
- **Origin:** Medial and lateral condyles of femur
- **Insertion:** With soleus into calcaneus via calcaneal tendon
- **Action:** Flexes tibia and plantar; flexes foot



# Soleus

---

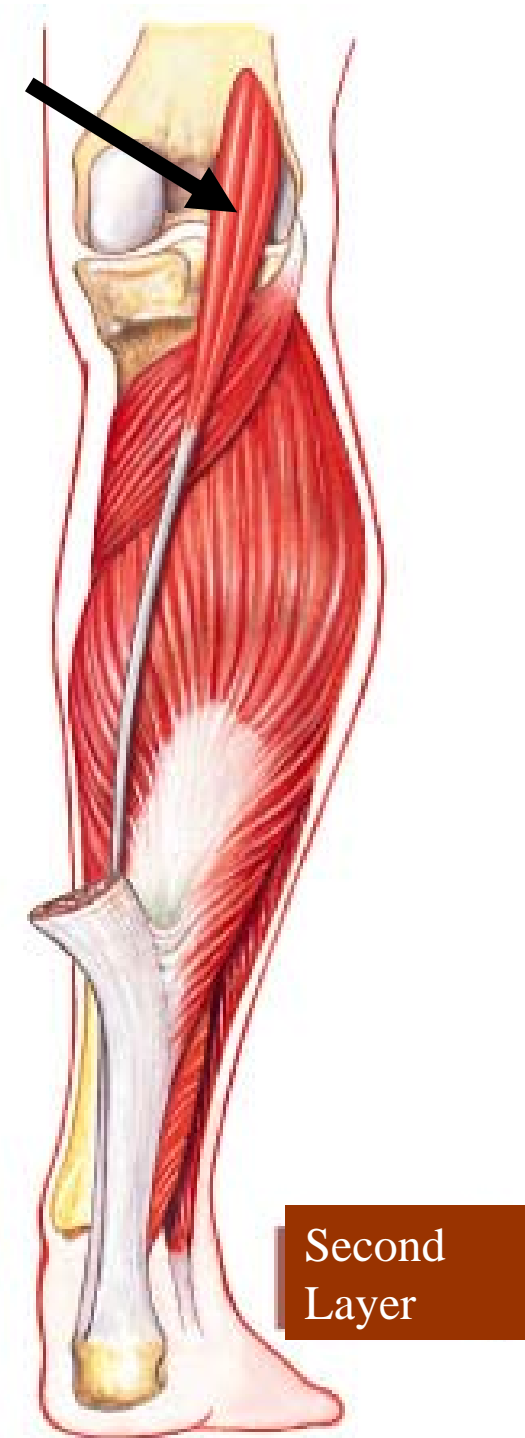
- **Origin:** Upper third of fibula and soleal line of tibia
- **Insertion:** With gastrocnemius into calcaneus via calcaneal tendon
- **Action:** Flexes foot



# Plantaris

---

- **Origin:** Lateral supracondylar ridge of femur
- **Insertion:** Posterior calcaneus via calcaneal tendon
- **Action:** Weakly assists gastroc in plantar flexing ankle and flexing knee



# DEEP POSTERIOR COMPARTMENT OF THE LEG

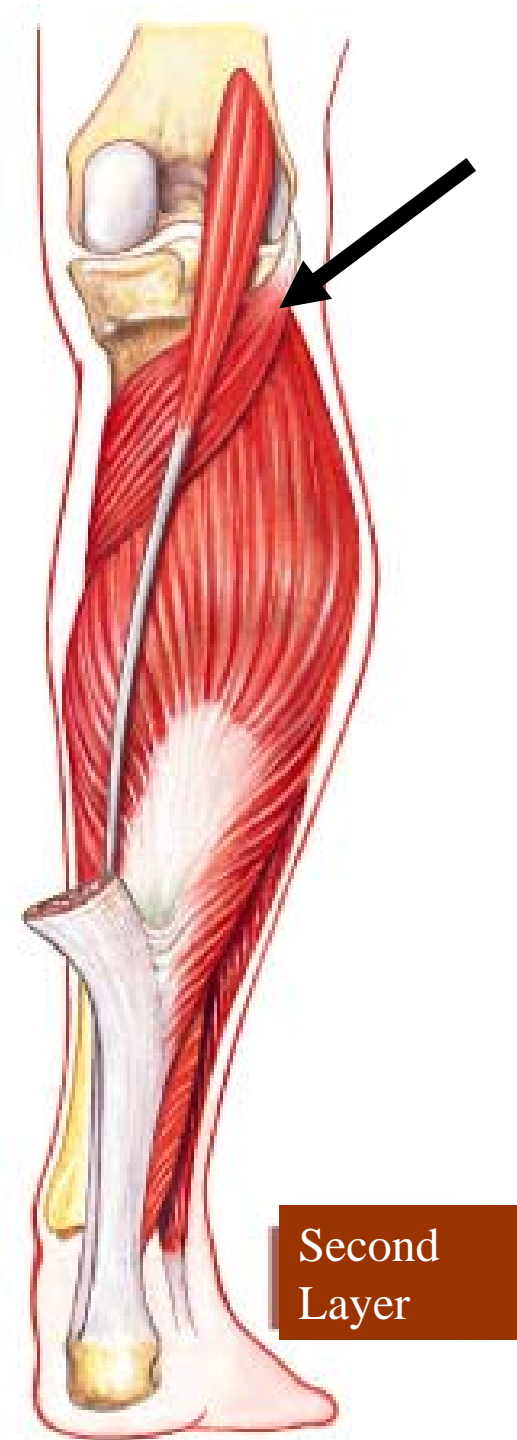
---



# Popliteus

---

- **Origin:** Lateral surface of lateral condyle
- **Insertion:** Posterior surface of tibia just below condyles
- **Action:** Flexes and unlocks knee joint

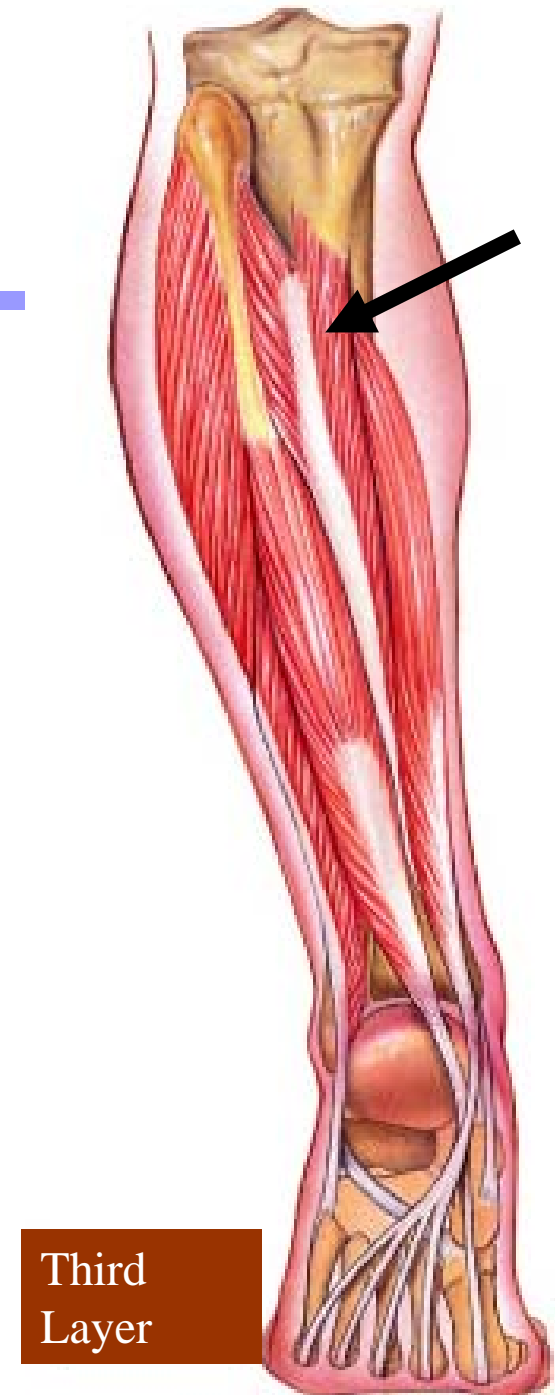



# Tibialis Posterior

---

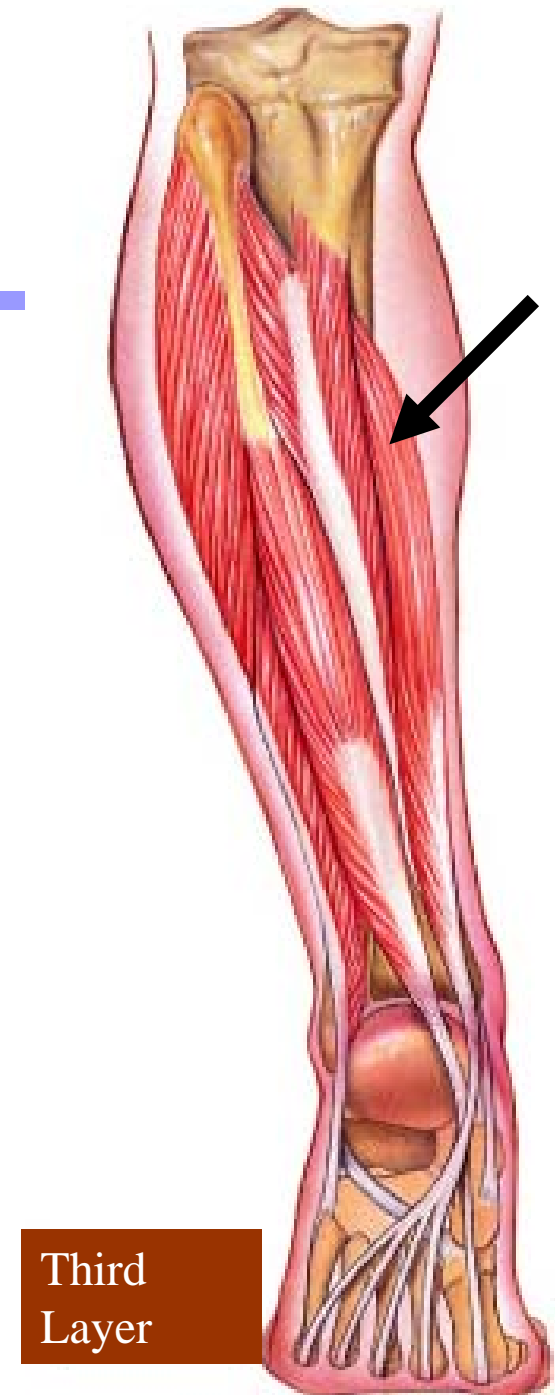- **Origin:** Interosseous membrane and tibia and fibula on either side
- **Insertion:** Navicular, with slips to cuneiform; cuboid; metatarsals 2-4
- **Action:** Adducts and inverts foot and aids in plantar flexion



# Flexor Digitorum Longus

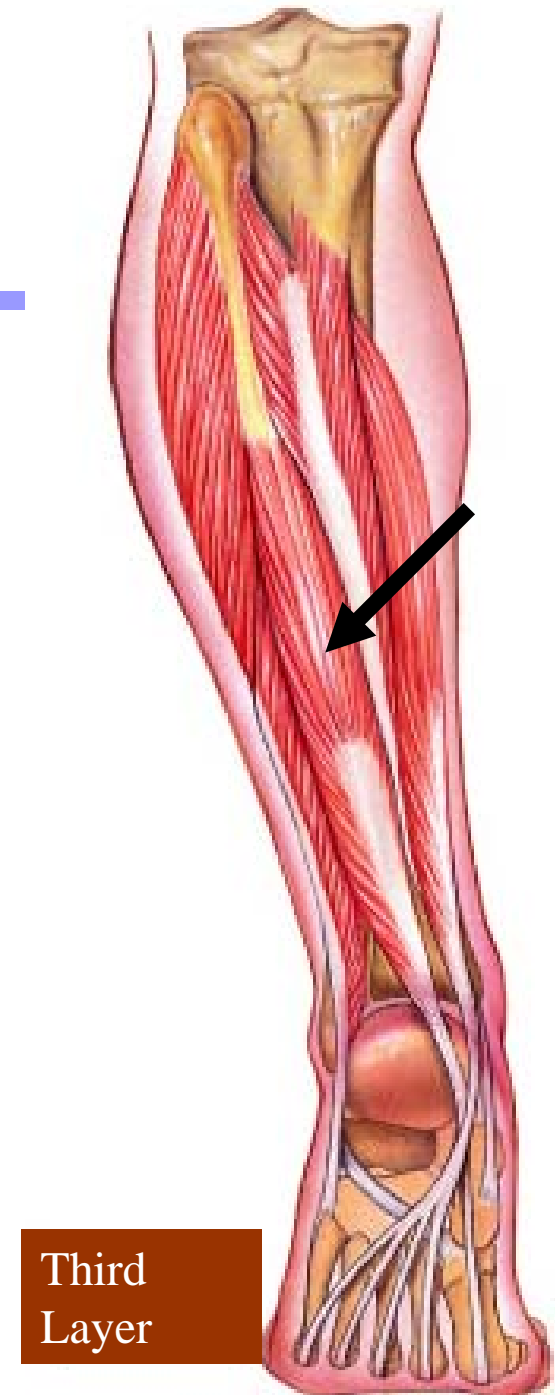---

- **Origin:** Middle half of tibia
- **Insertion:** By four tendons into distal phalanges of lateral four toes
- **Action:** Flexes lateral four toes




# Flexor Hallucis Longus

- **Origin:** Distal two-thirds of fibula
- **Insertion:** Distal phalanx of great toe
- **Action:** Flexes great toe



# ANTERIOR COMPARTMENT OF THE LEG

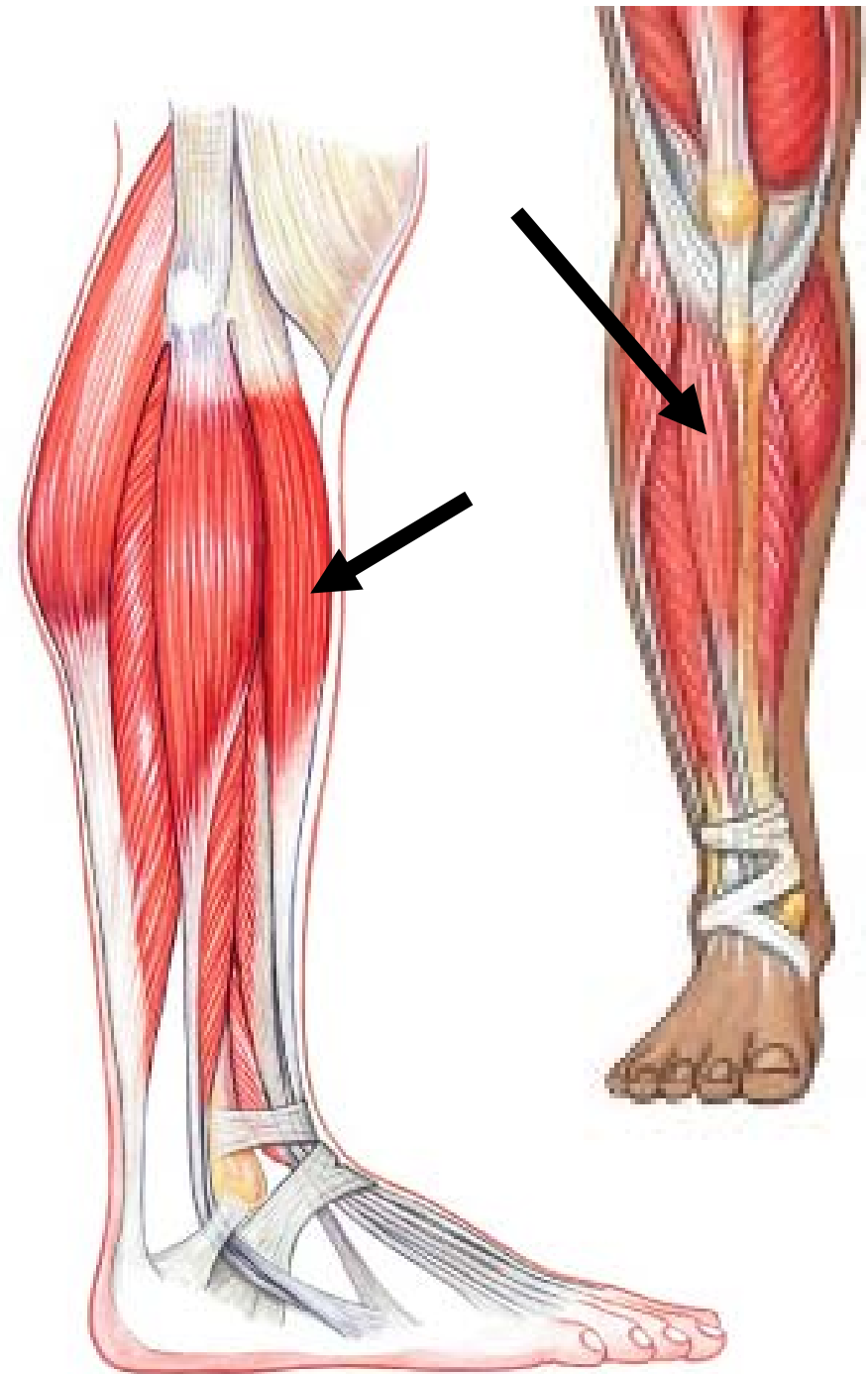
---



# Tibialis Anterior

---

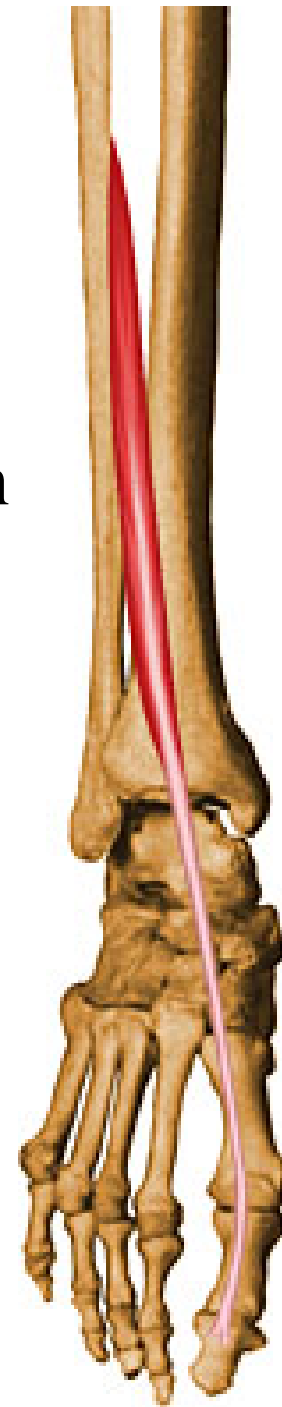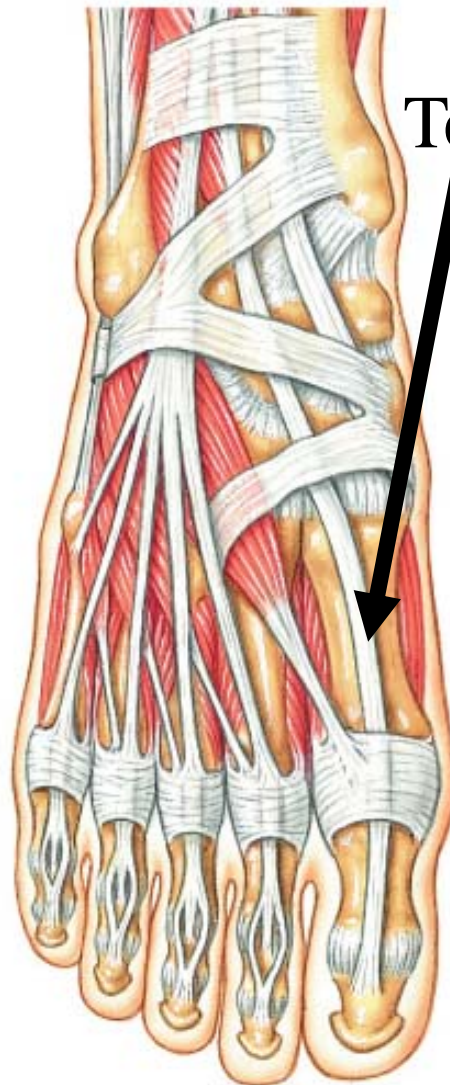
- **Origin:** Upper half of tibia and interosseous membrane
- **Insertion:** Base of first cuneiform and first metatarsal
- **Action:** Dorsiflexes and inverts foot



# Extensor Hallucis Longus

---

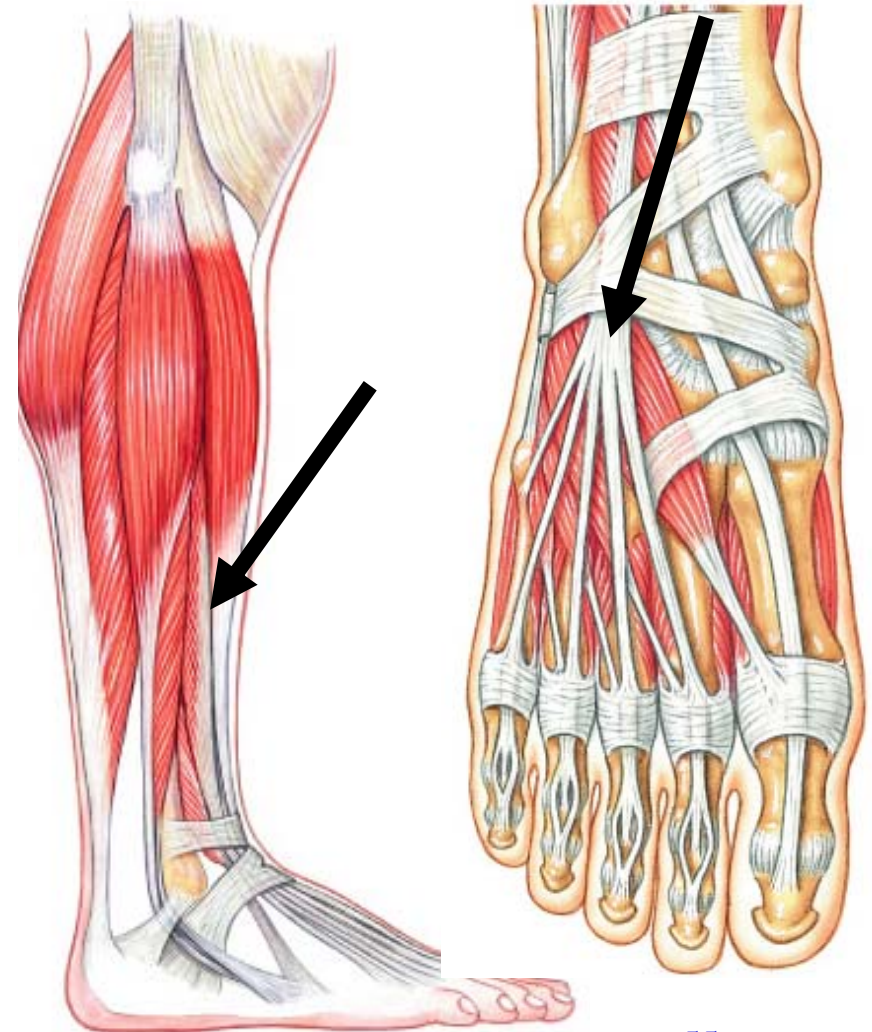
- **Origin:** Middle half of fibula and interosseous membrane
- **Insertion:** Distal phalanx of great toe
- **Action:** Dorsiflexes foot and extends great toe



# Extensor Digitorum Longus

Tendon

- **Origin:** Tibia, proximal three-fourths of fibula, & interosseous membrane
- **Insertion:** Tendons to middle & terminal phalanges of four lateral toes by extensor expansion
- **Action:** Dorsiflexes foot and extends toes



# LATERAL COMPARTMENT OF THE LEG

---

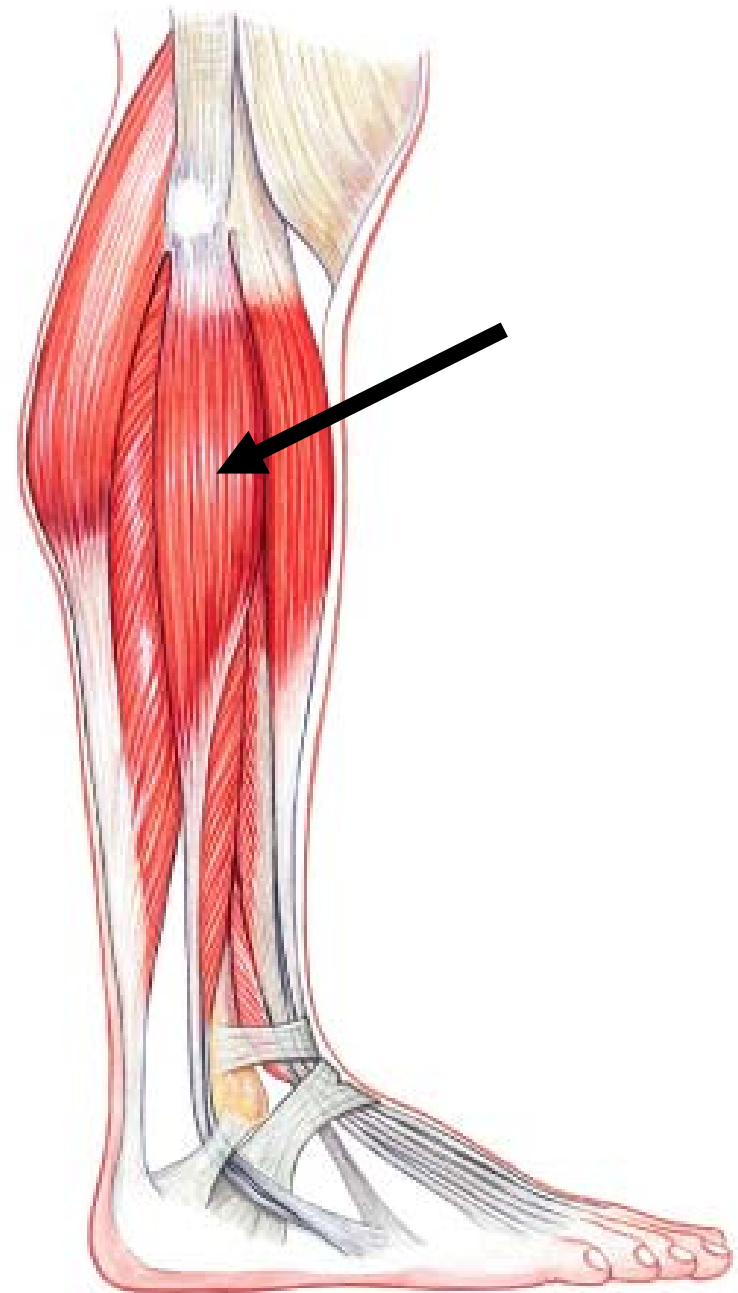




# Fibularis Longus

---

- **Origin:** Upper two-thirds of fibula and intermuscular septa
- **Insertion:** Plantar base of first metatarsal and first cuneiform and
- **Action:** Plantar flexes and everts foot



# Fibularis Brevis

---

- **Origin:** Lower two-thirds of fibula
- **Insertion:** Plantar base of fifth metatarsal
- **Action:** Plantar flexes and everts foot

