LOWER EXTREMITY

OUTLINE

- Hip
- Knee
- Ankle

Trauma

Degeneration

Vascular Injury

Sports Injury

AP HIP

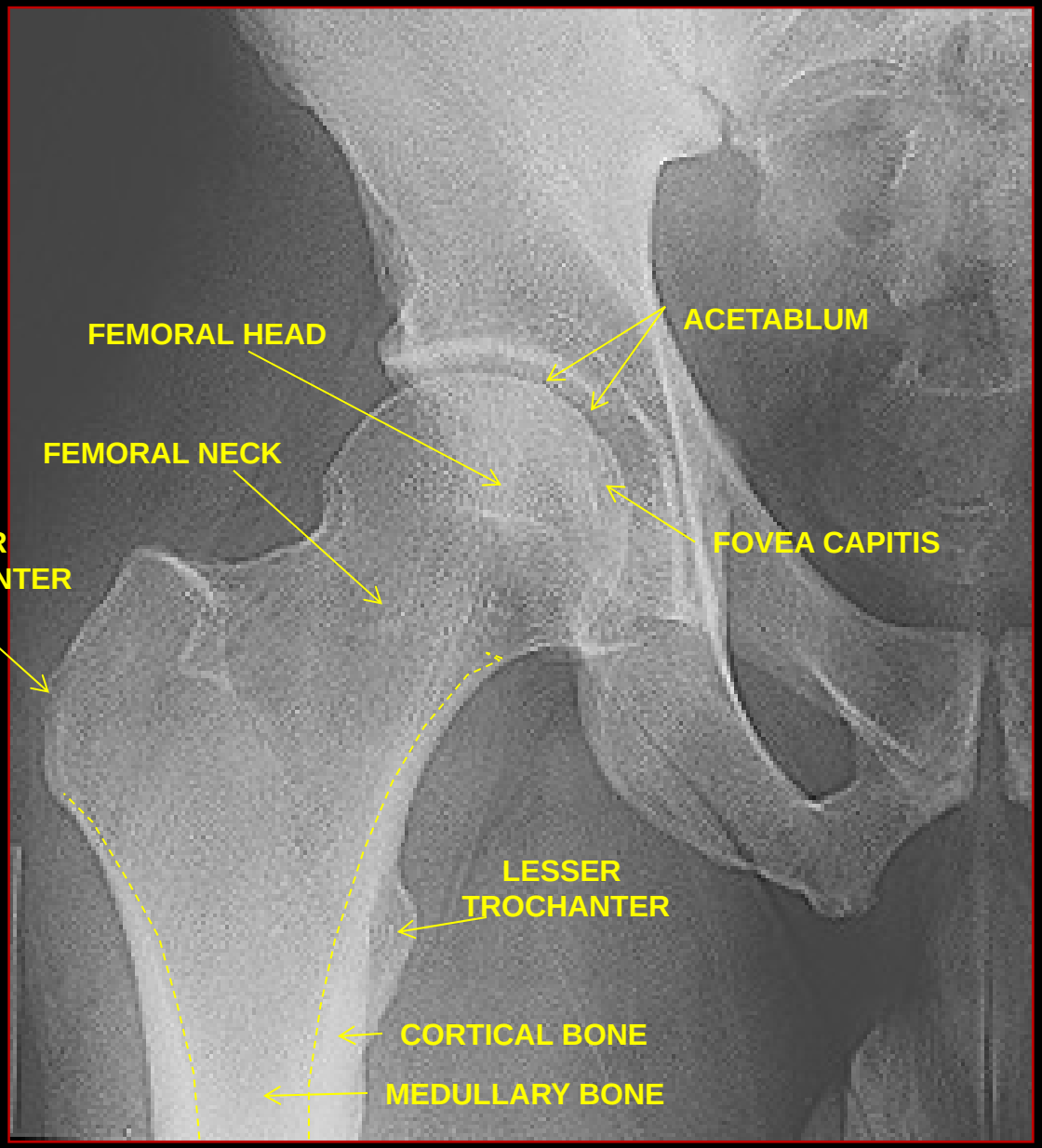
FEMORAL HEAD
ACETABLUM
FEMORAL NECK
FOVEA CAPITIS
GREATER
TROCHANTER
LESSER
TROCHANTER
CORTICAL BONE
MEDULLARY BONE

CORONAL MRI

RT. HIP

INTERTROCHANTERIC FRACTURE

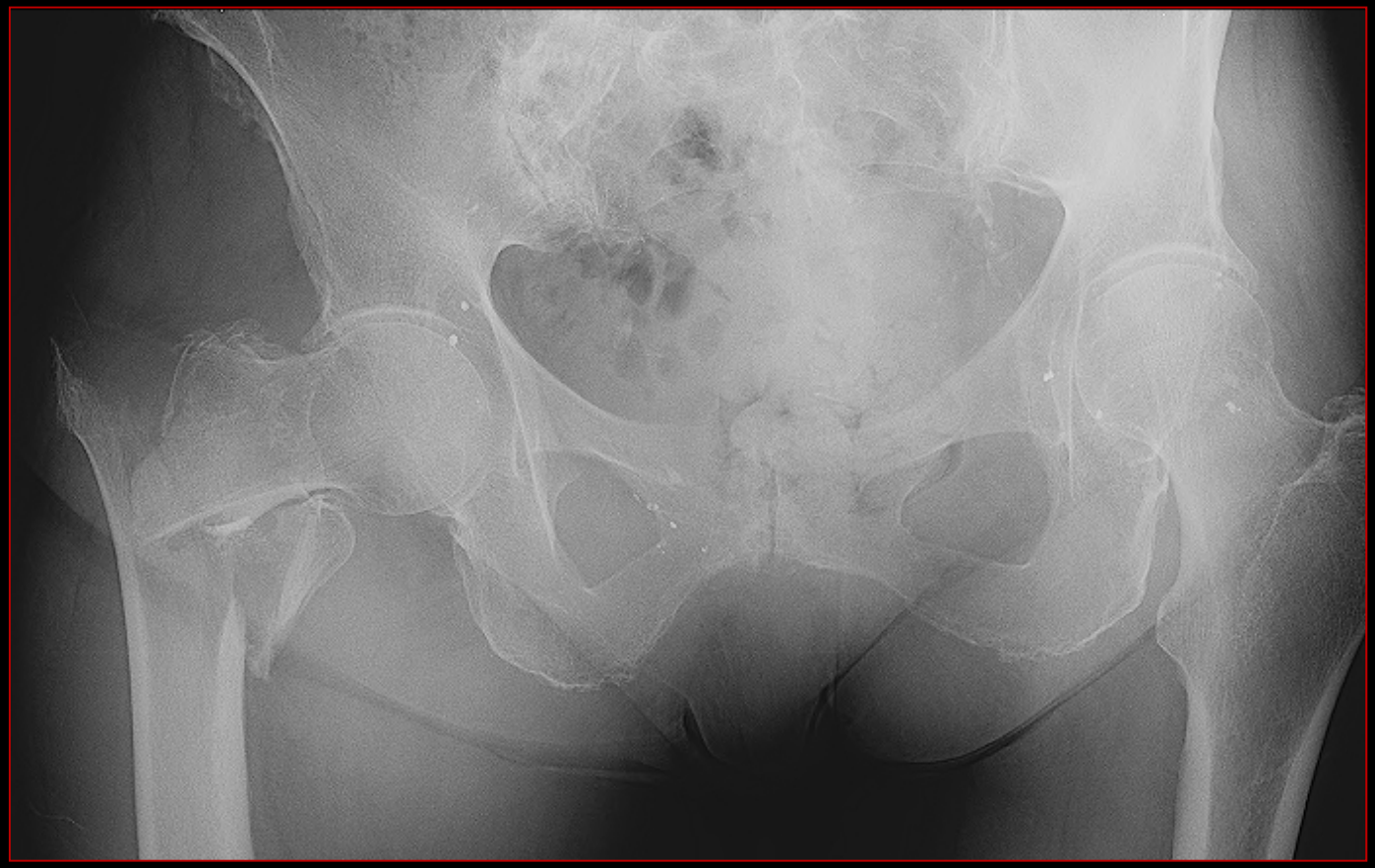

POST OPERATIVE REPAIR

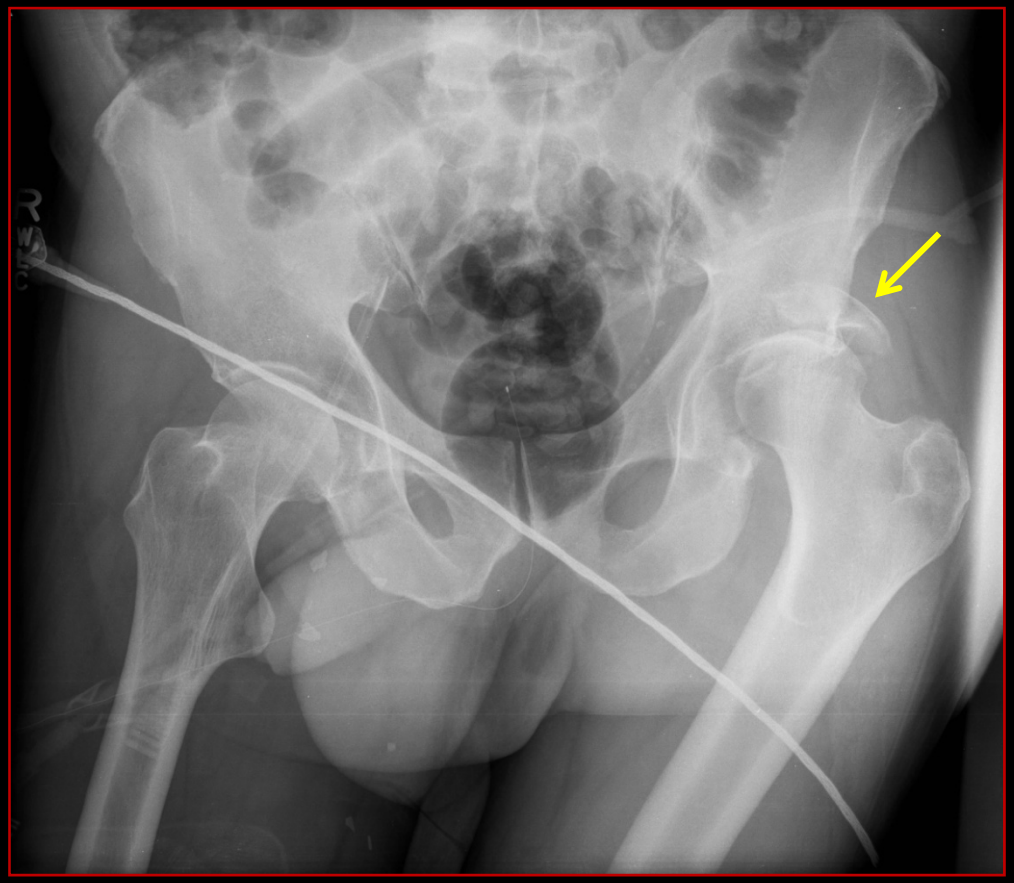

ACETABULAR FRACTURE

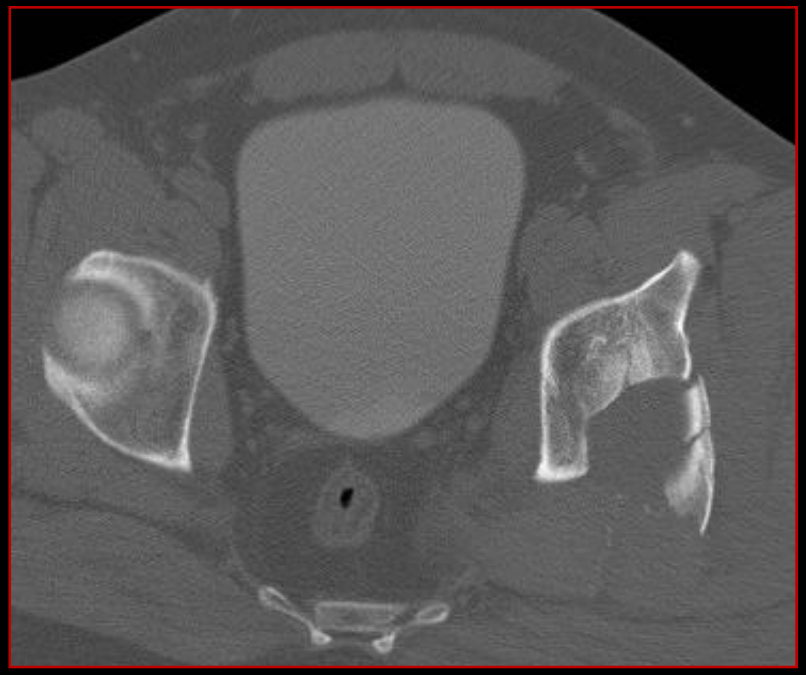

CT SCAN PELVIS

AVASCULAR NECROSIS

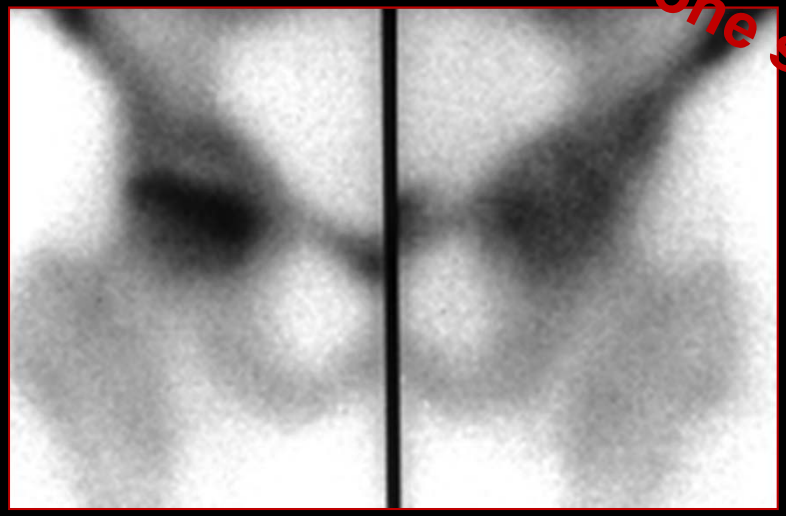

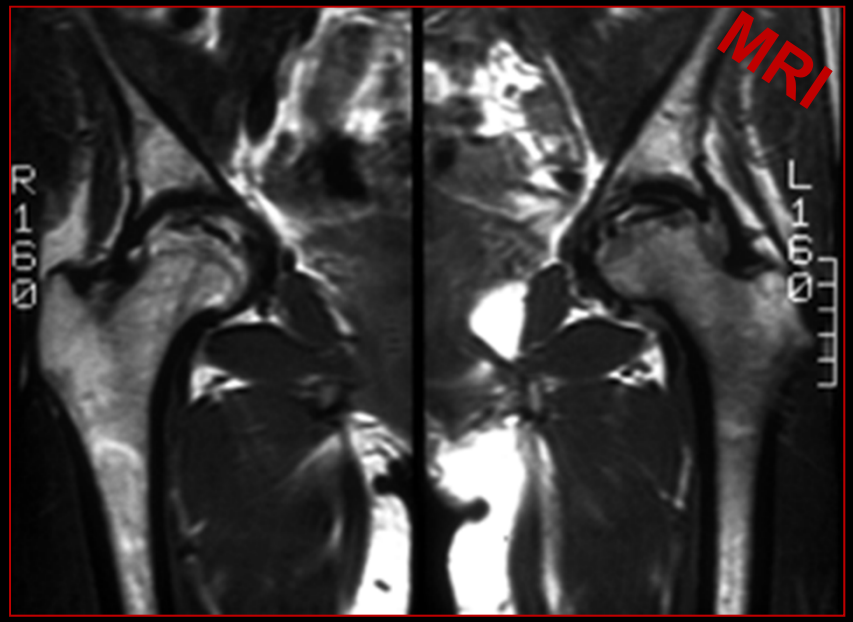

BONE DENSITY MEASUREMENT NUCLEAR MEDICINE

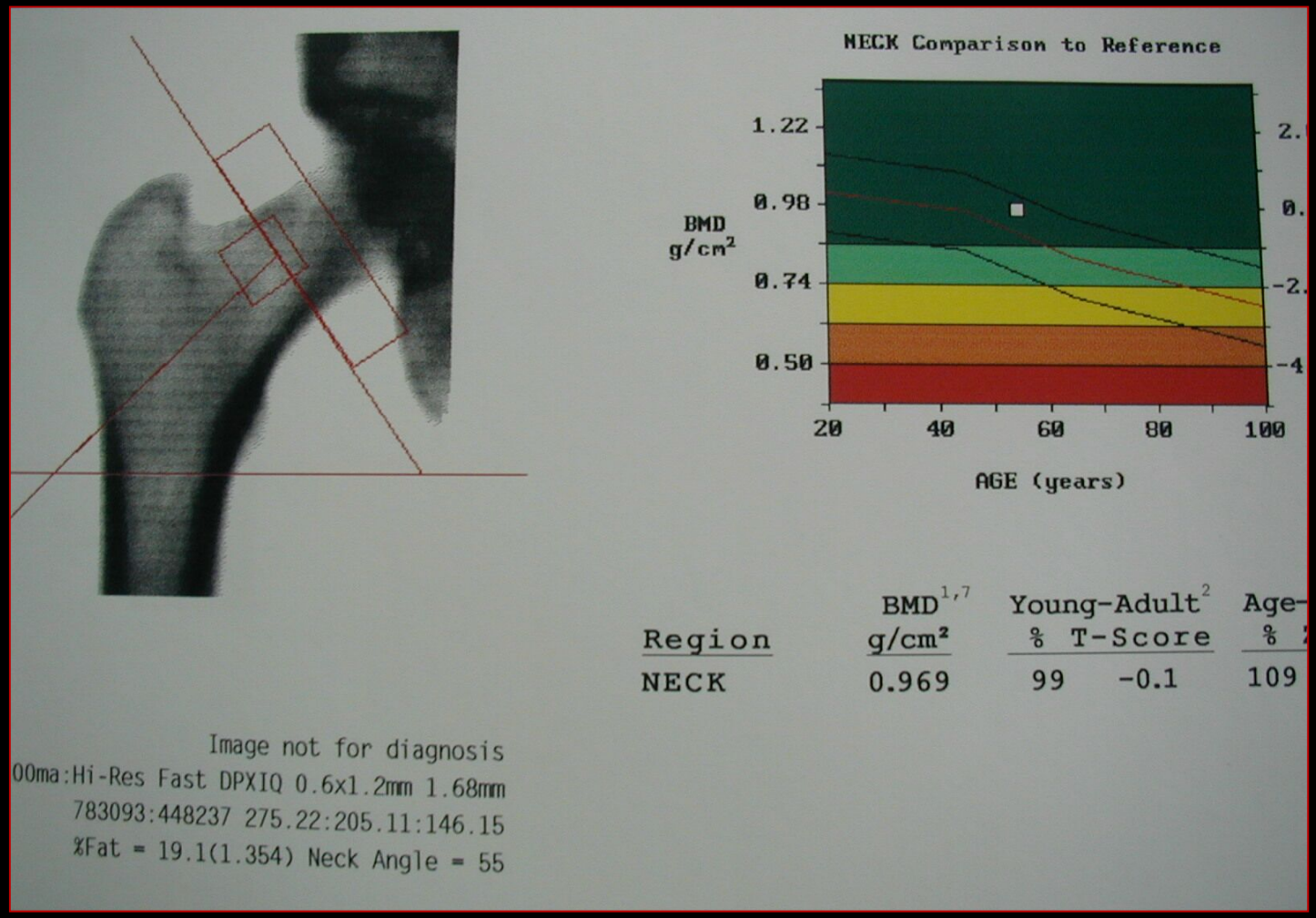

ANGLE OF INCLINATION

Coxa Vara

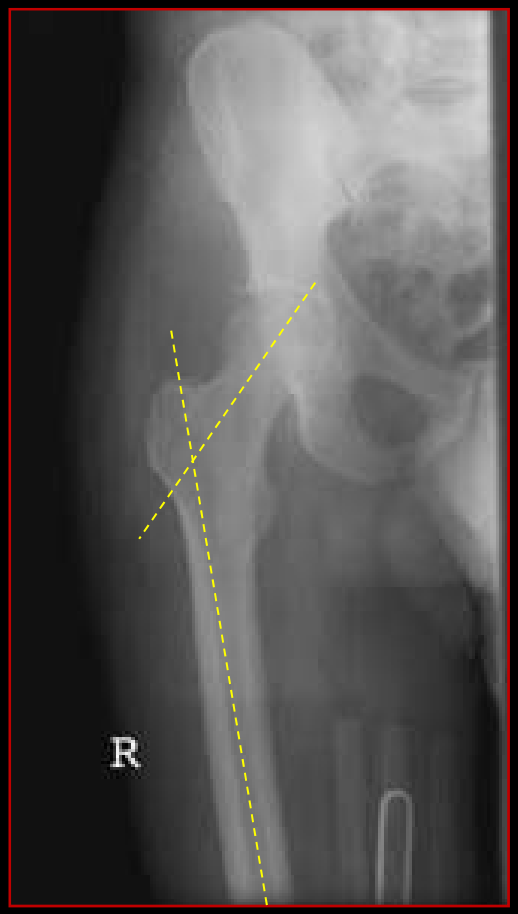

Coxa Valga

TRANSVERSE MRI OF RIGHT THIGH

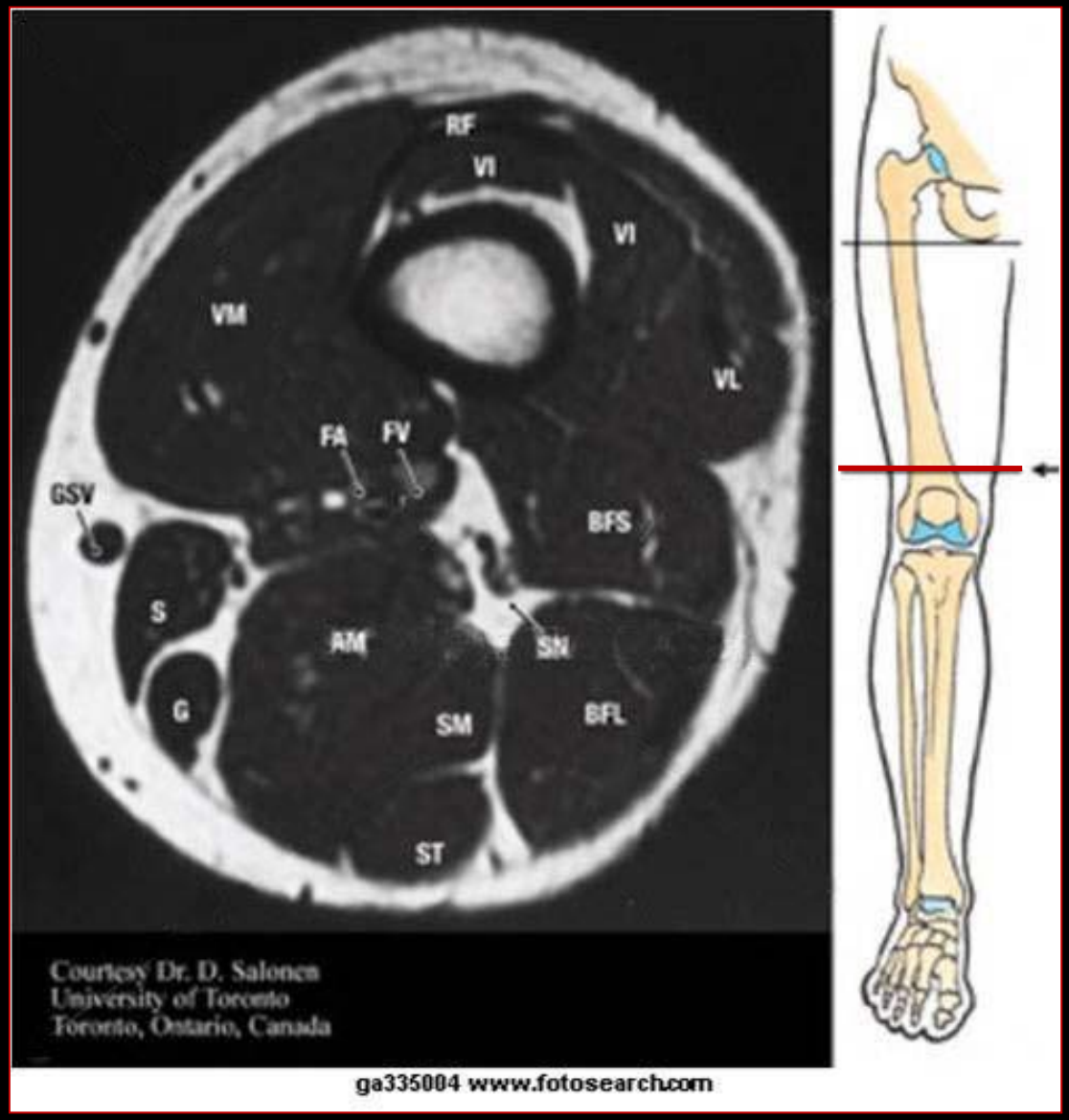

http://www.fotosearch.com/bigcomp.asp?path=LIF/LIF137/GA335004.jpg

DISTAL FEMUR

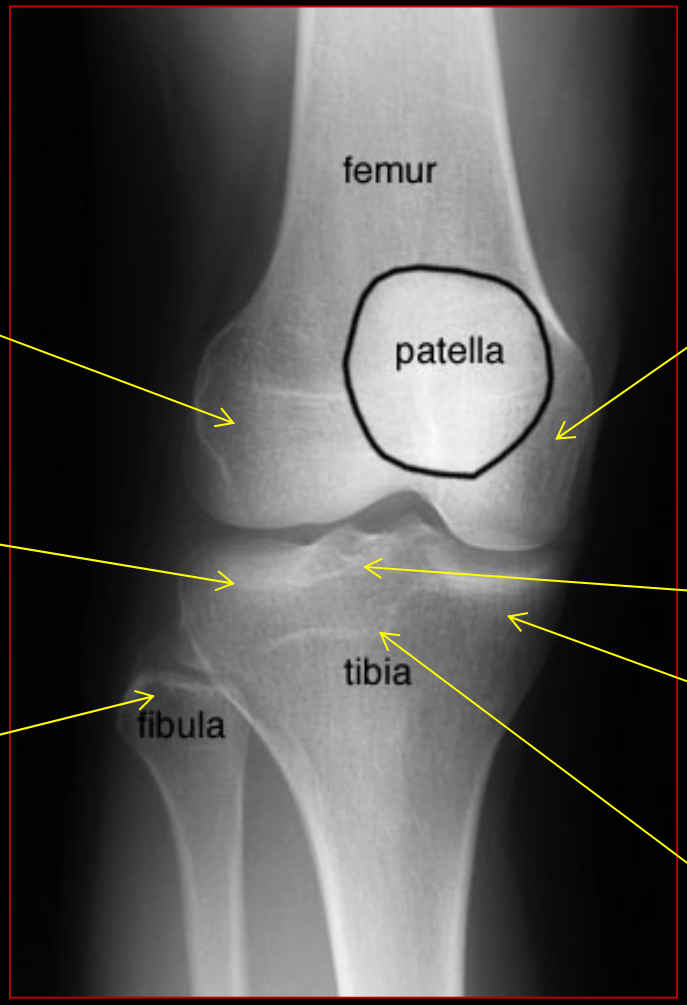

Lateral epicondyle

Medial epicondyle

Lateral tibial condyle

Intercondylar eminence

Medial tibial condyle

Head of fibula

Tibial tuberosity

FRACTURED LT. FEMUR

AP

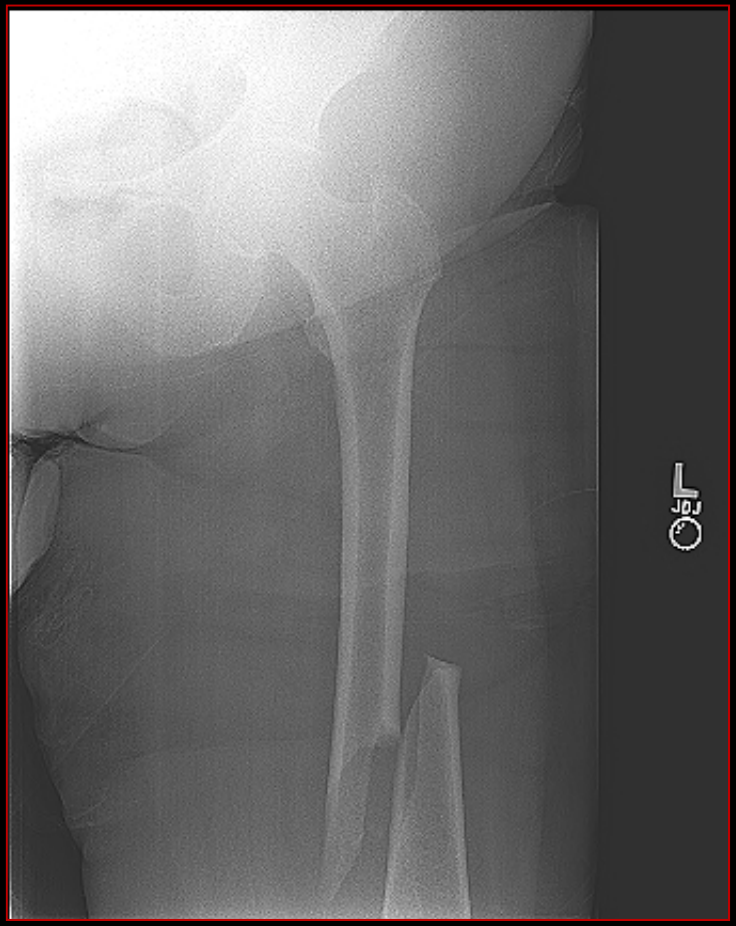

LAT

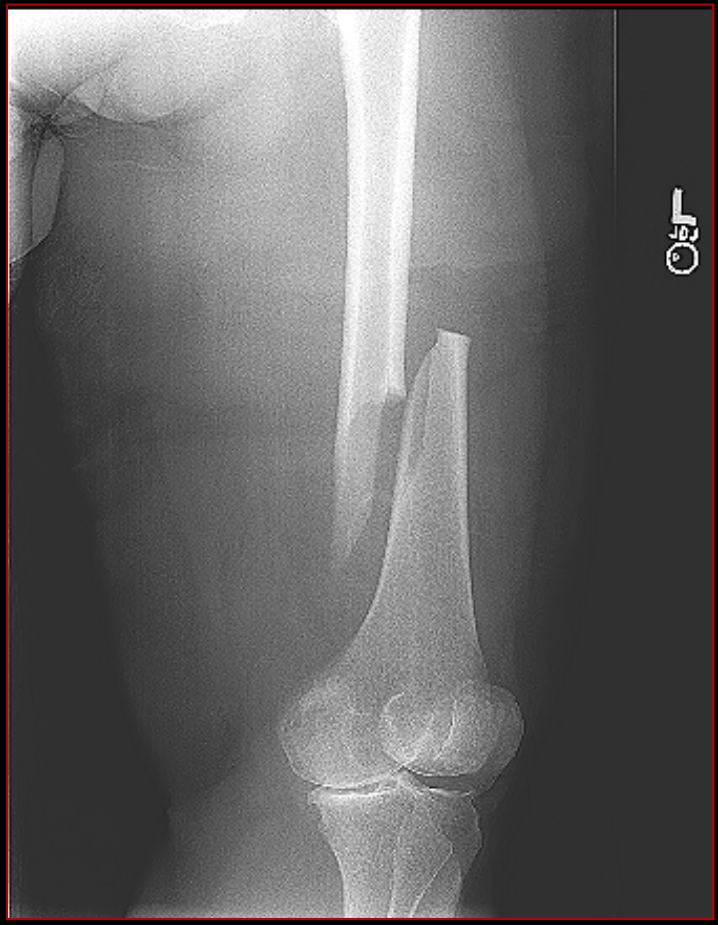

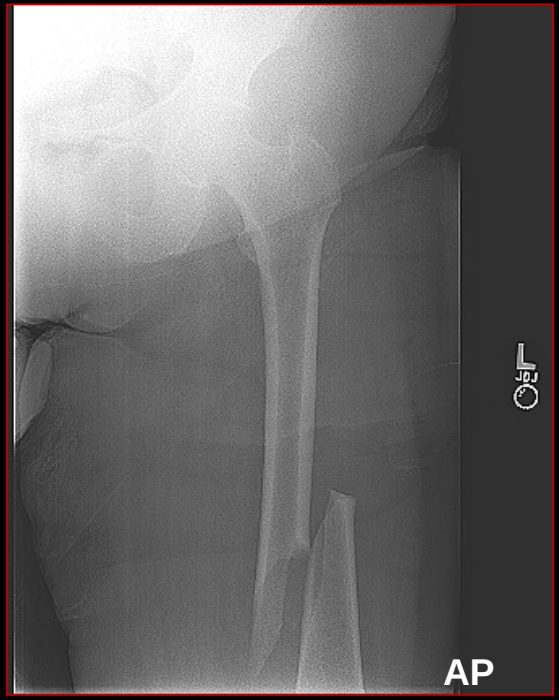

DESCRIBE THE FRACTURE

BONE AND WHICH PART

- FRACTURE ORIENTATION AND PARTS
- DISPLACEMENT AND ANGULATION
- JOINT INVOLVEMENT

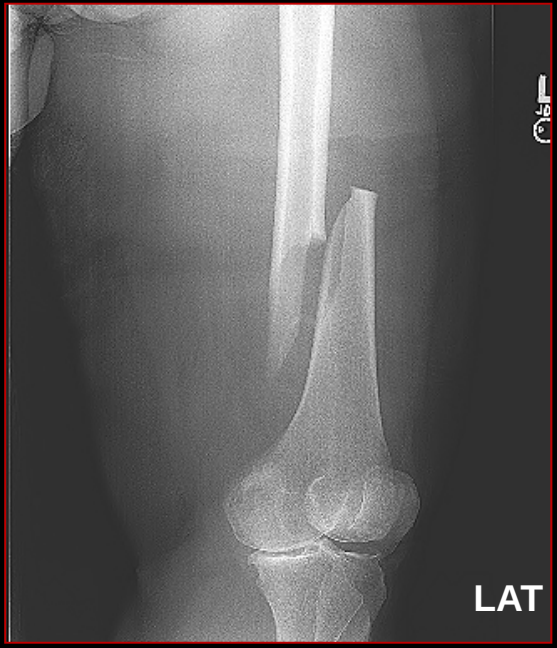

EXAMPLE

There is an <u>oblique</u> fracture through the diaphysis of the femur with approximately 1cm of lateral and anterior <u>displacement</u> of the distil fragments relative to the proximal fragments. There is no <u>angulation</u> at the fracture margin. There is some shortening due to unopposed muscle pull. The fracture does not extend into the <u>joint</u>.

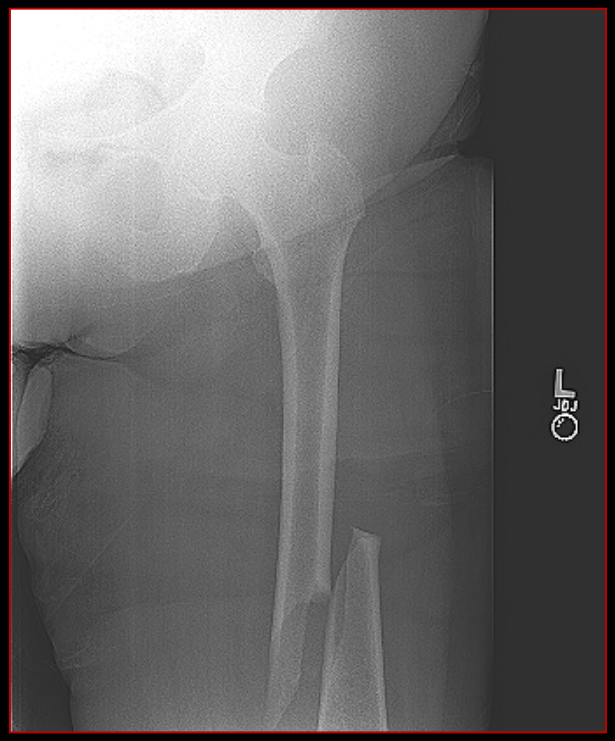

INFERIOR VENA CAVAGRAM

AP PELVIC ARTERIOGRAM

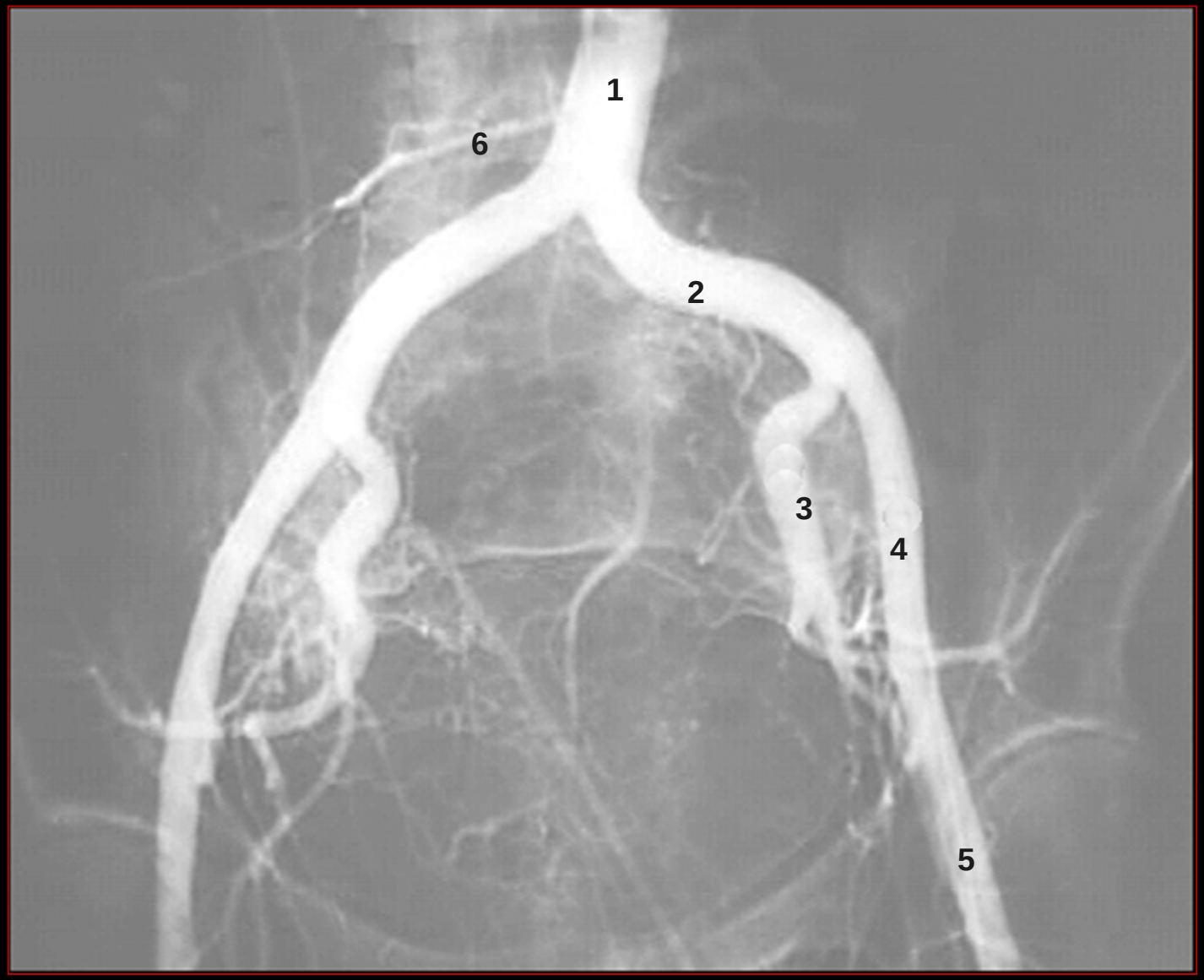

1. ABDOMINAL AORTA
2. COMMON ILLIAC ARTERY
3. INTERNAL ILLIAC ARTERY
4. EXTERNAL ILLIAC ARTERY
5. COMMON FEMORAL ARTERY
6. LUMBAR ARTERY

CONVENTIONAL ANGIOGRAM

1= Common femoral artery

2= Superficial femoral artery

3= Profunda femoral artery (Deep artery of the thigh)

4= Lateral femoral circumflex artery

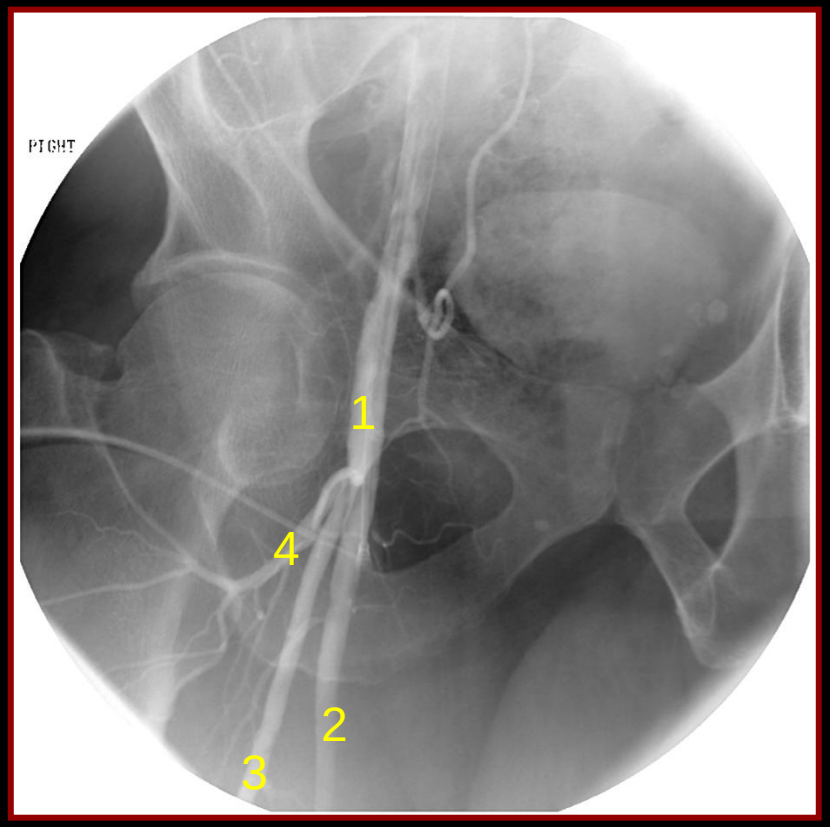

CALCIFICATIONS

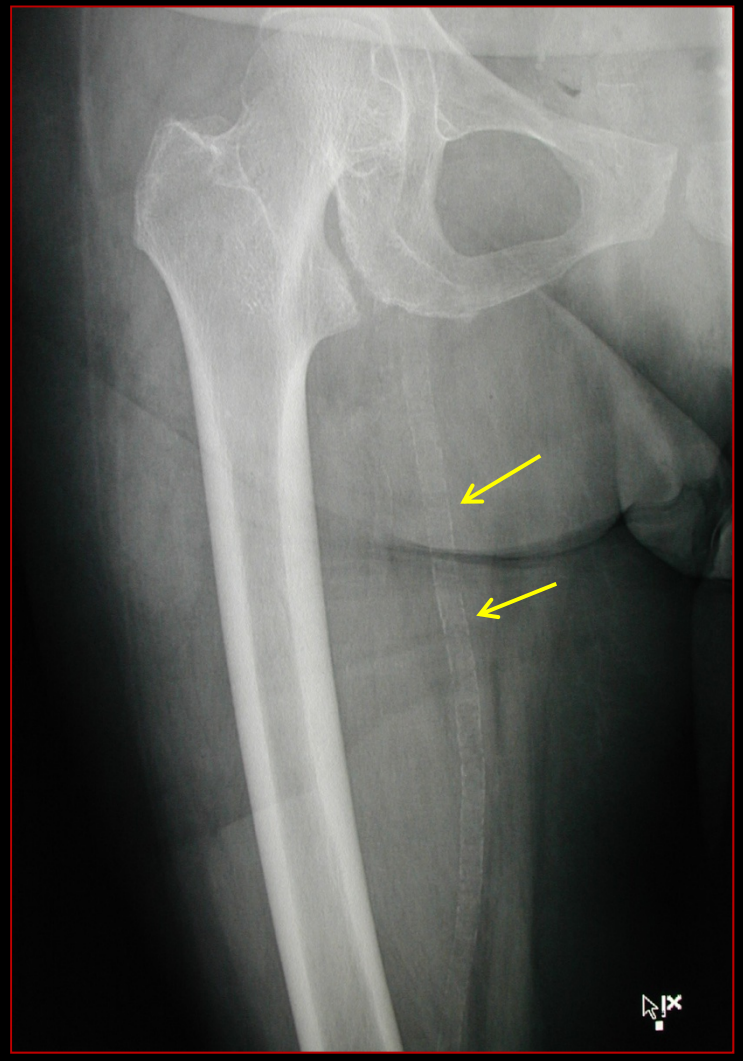

LOWER EXTREMITY ARTERIOGRAM

1. COMMON FEMORAL ARTERY
2. PROFUNDA FEMORIS ARTERY
   (Deep artery of the thigh)
3. SUPERFICIAL FEMORAL ARTERY

LOWER EXTREMITY ARTERIOGRAM

POPLITEAL ARTERY

LOWER EXTREMITY ARTERIOGRAM

4. POPLITEAL ARTERY
5. ANTERIOR TIBIAL ARTERY
6. POSTERIOR TIBIAL ARTERY
7. FIBULAR ARTERY

SUPERFICIAL FEMORAL ARTERY ARTERIOGRAM

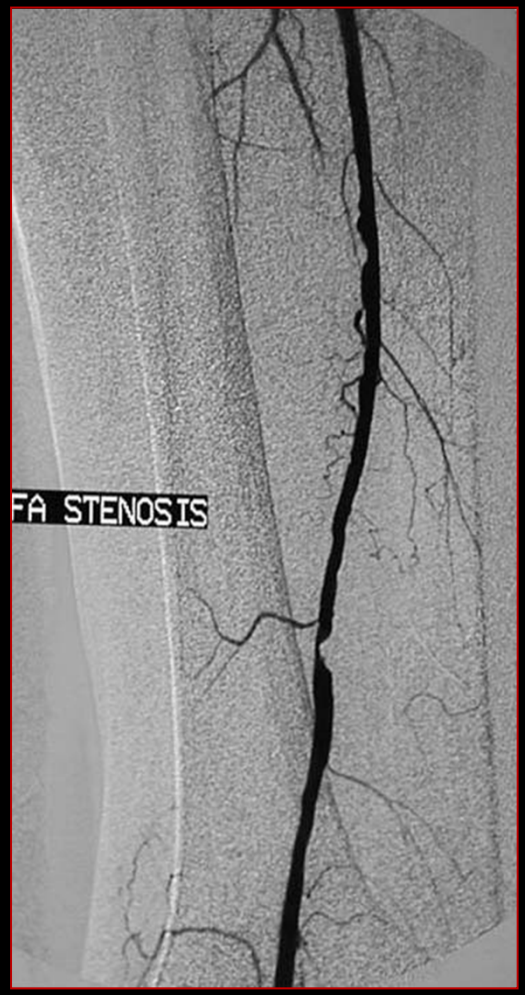

BALLOON ANGIOPLASTY OF SMA

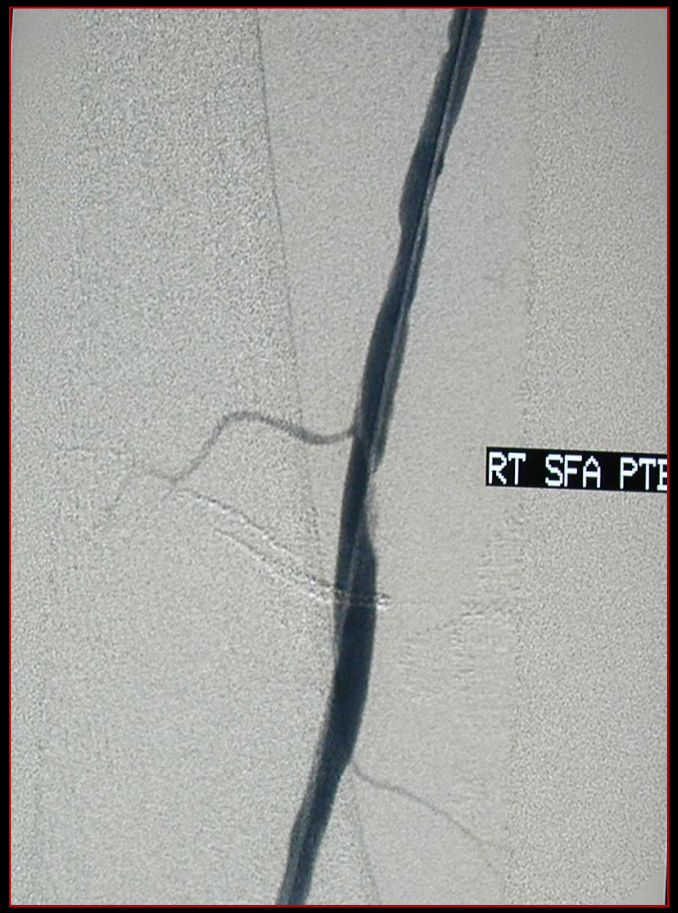

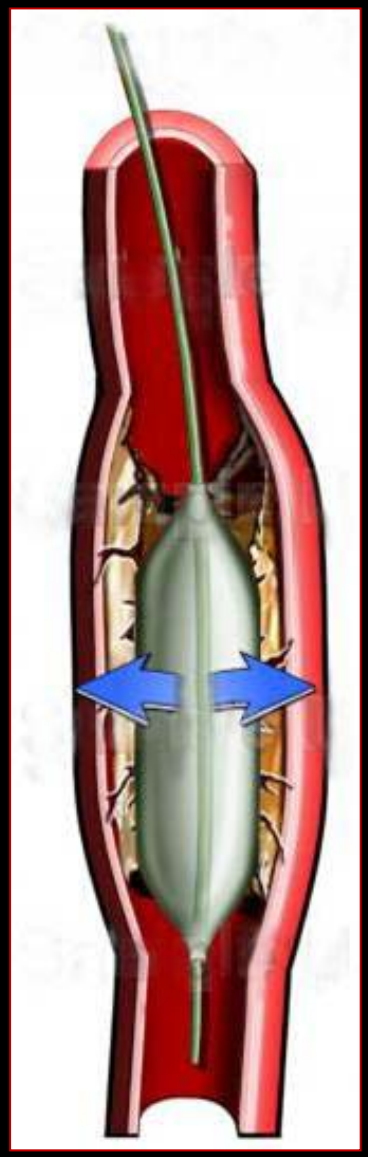

Occluded SFA fills by collateal vessels from the Profunda circulation.

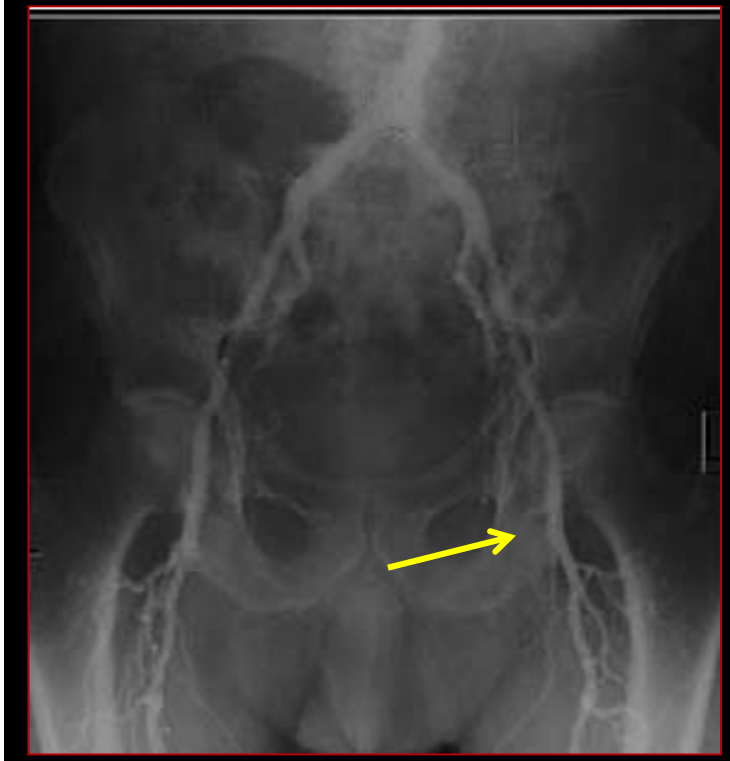

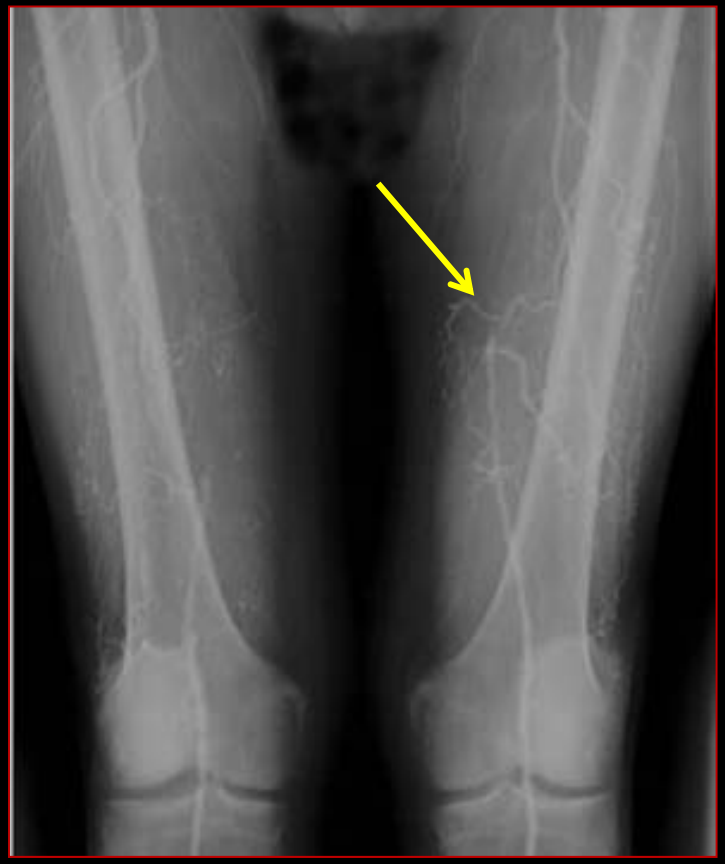

ARTERIAL CALCIFICATION

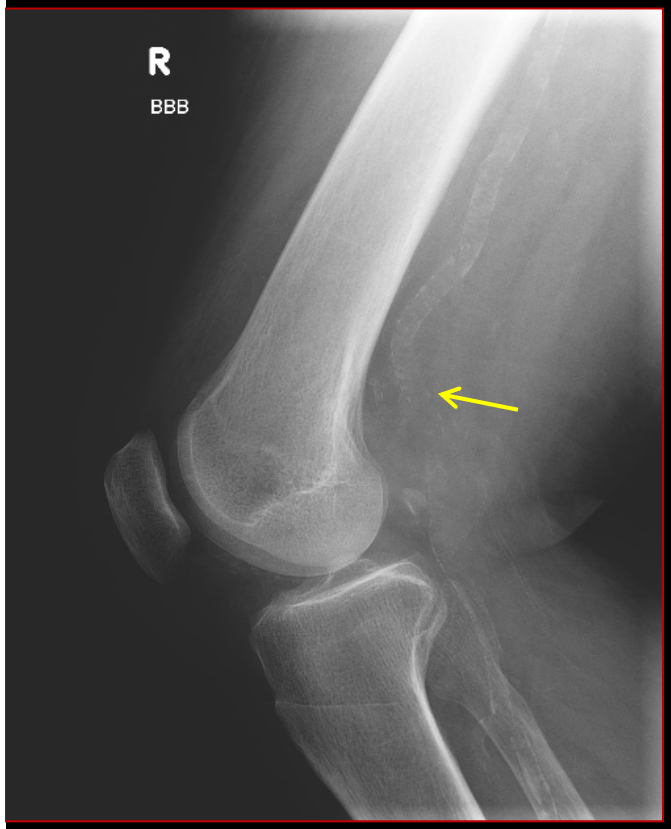

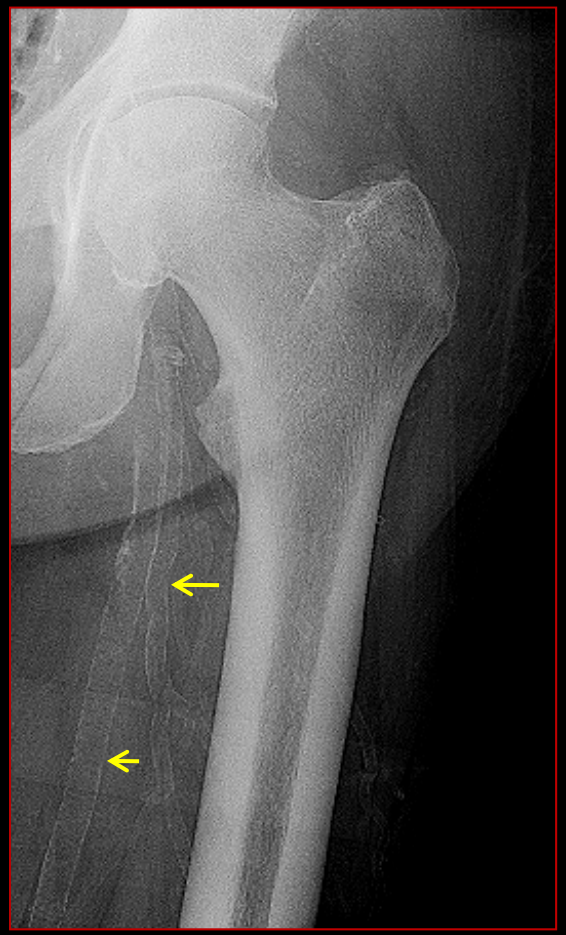

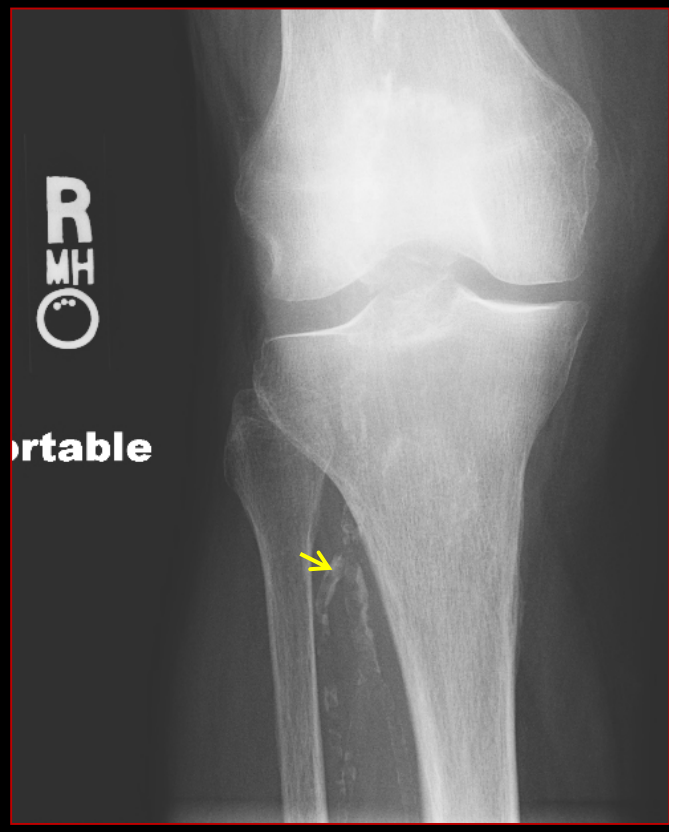

LEFT LOWER LEG VENOGRAM

1. POPLITEAL VEIN
2. FEMORAL VEIN
3. PROFUNDA FEMORAL VEIN
4. GREAT SAPHENOUS VEIN

VENOGRAM

AP projection

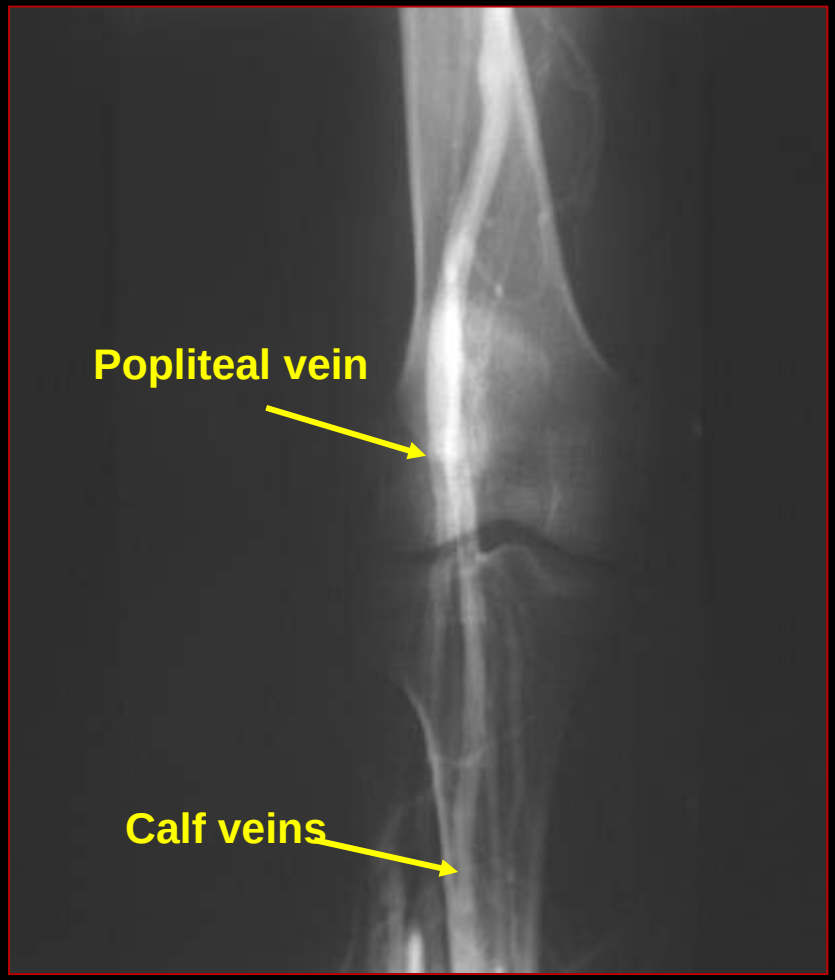

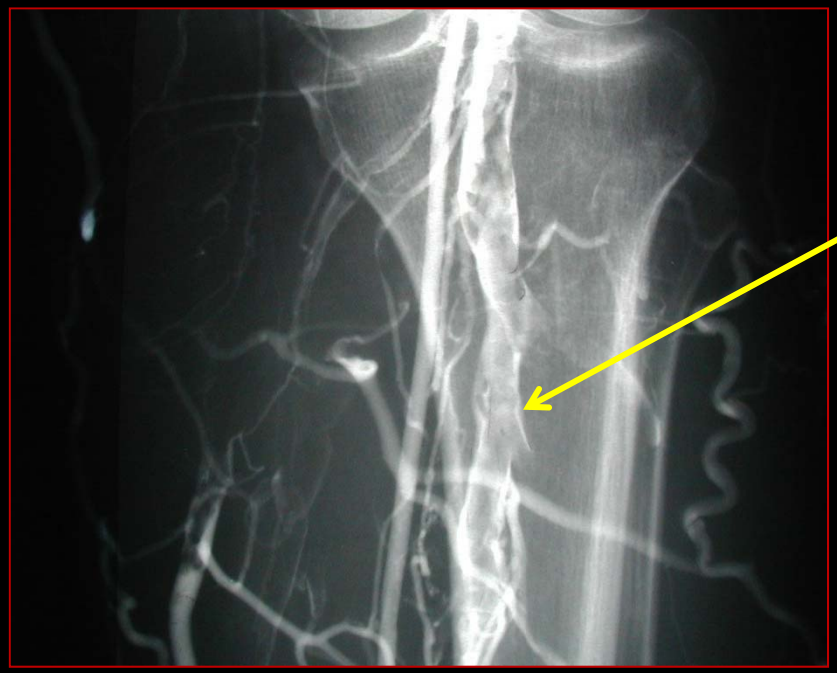

CALF VEIN THROMBUS

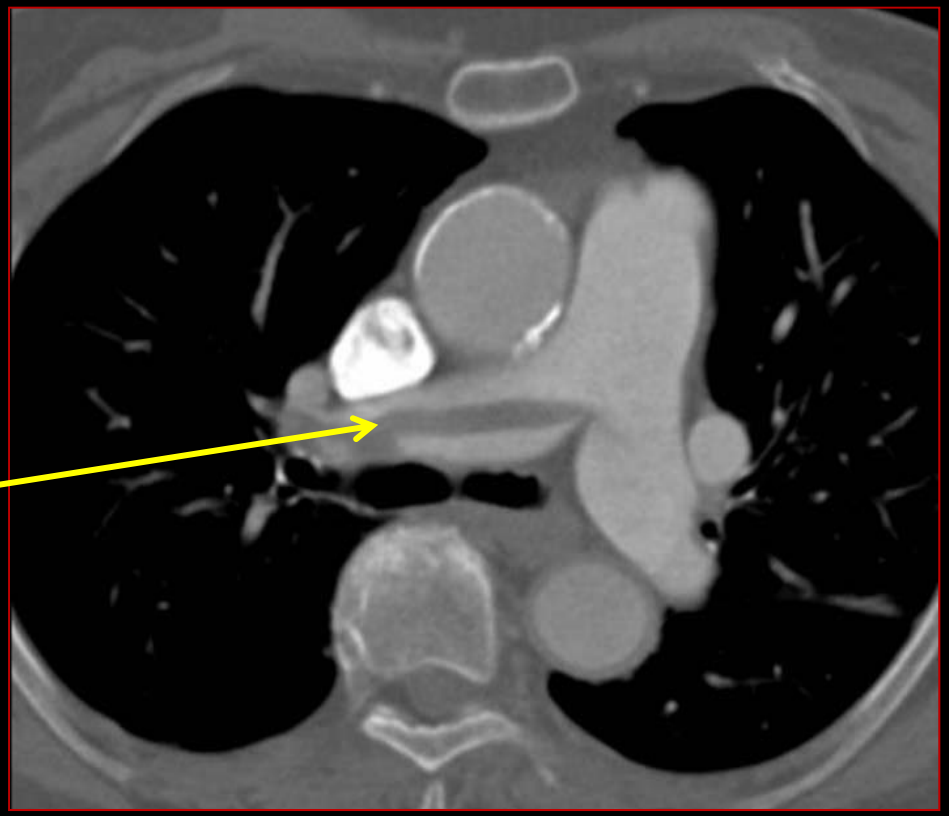

PULMONARY EMBOLUS

KNEE

AP

LATERAL

Tendon Rupture
Which One?

MRI RIGHT KNEE CORONAL

Scan level

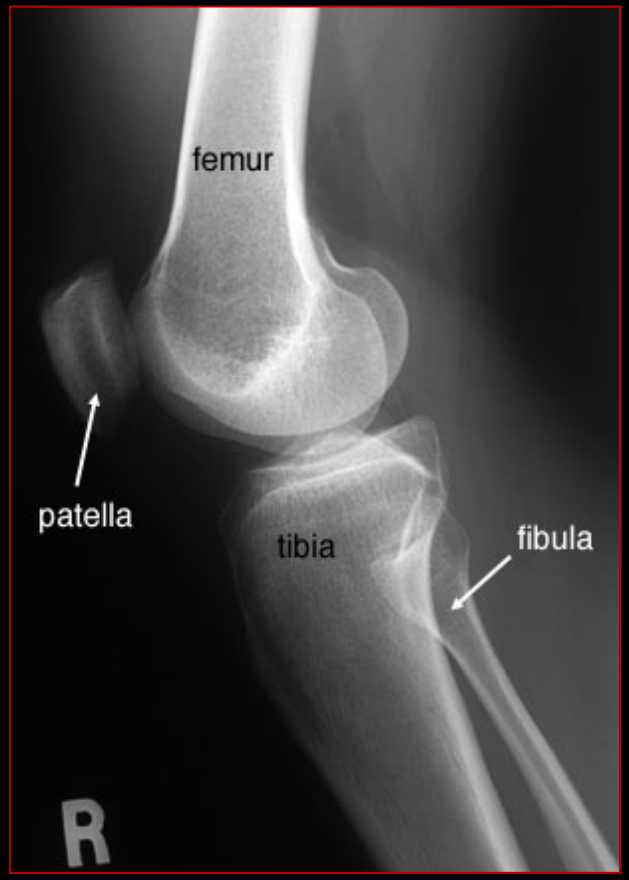

MEDIAL

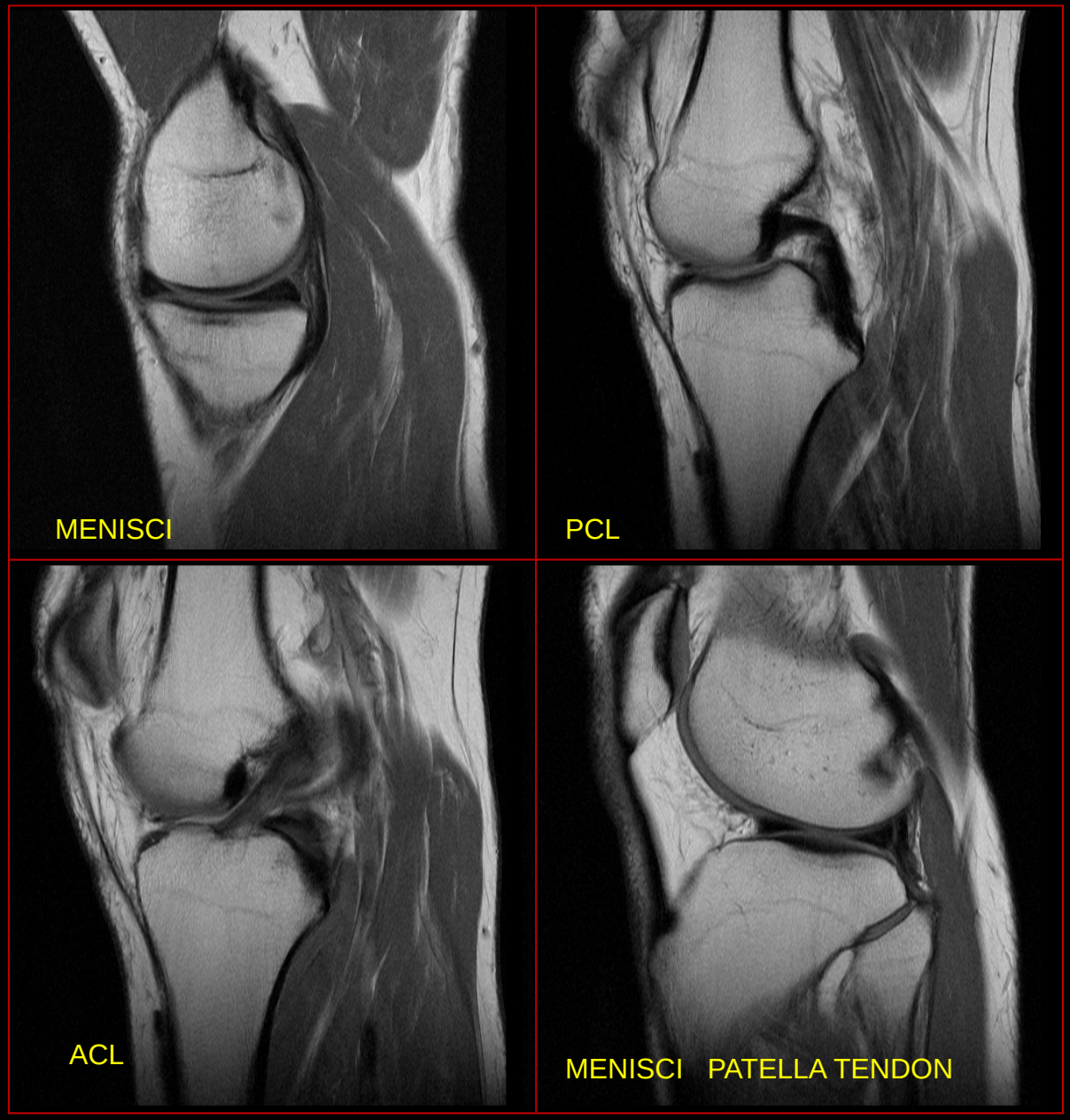

LATERAL

SAGITAL MR KNEE (MID JOINT)

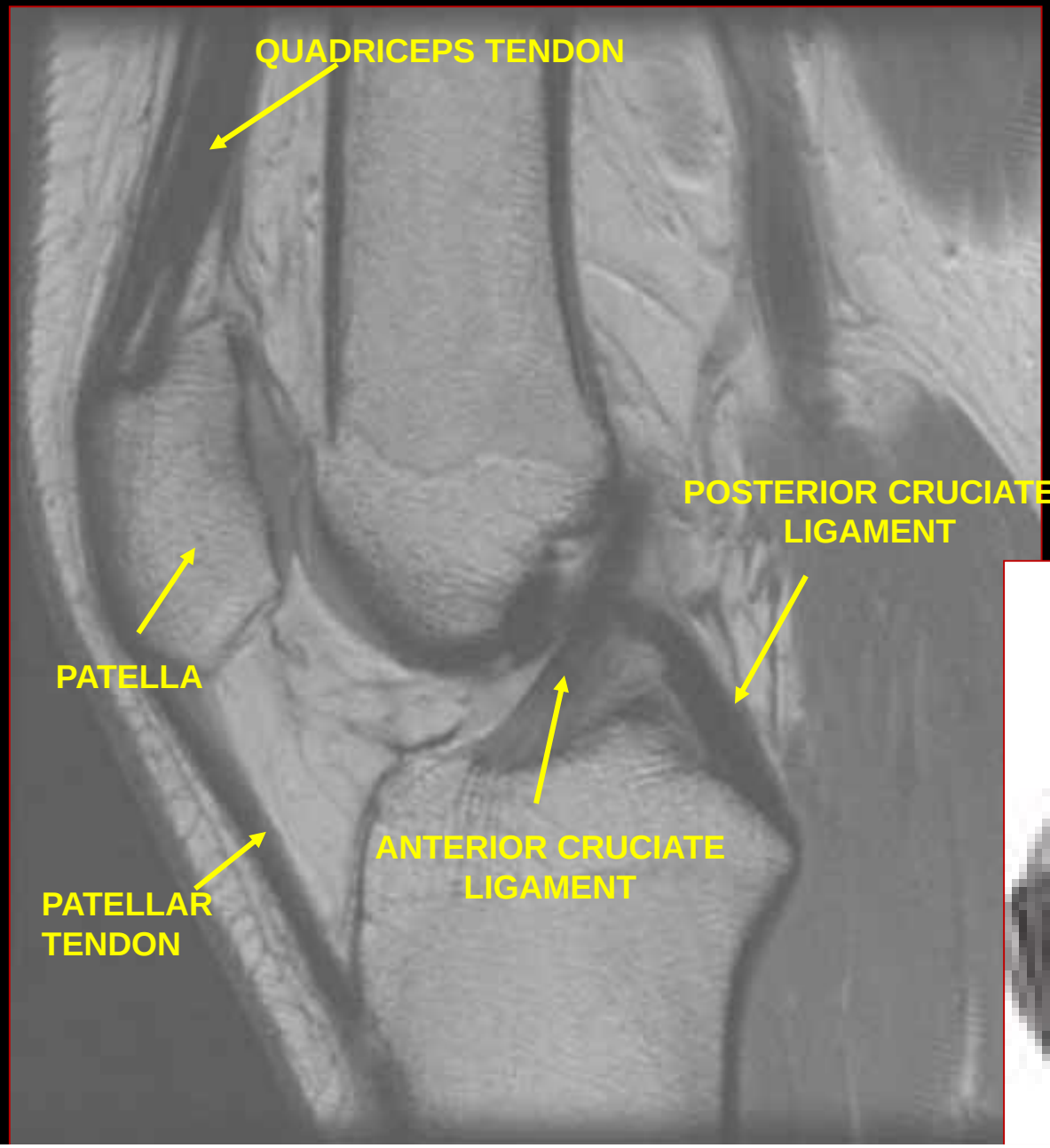

Scan level

PATELLA FRACTURE

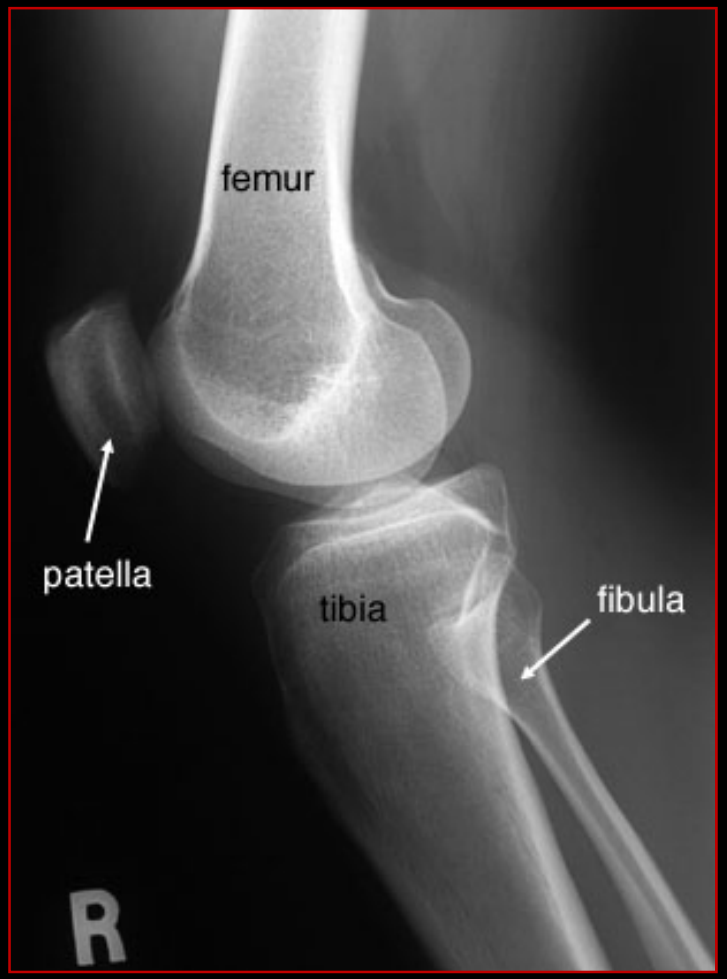

NORMAL

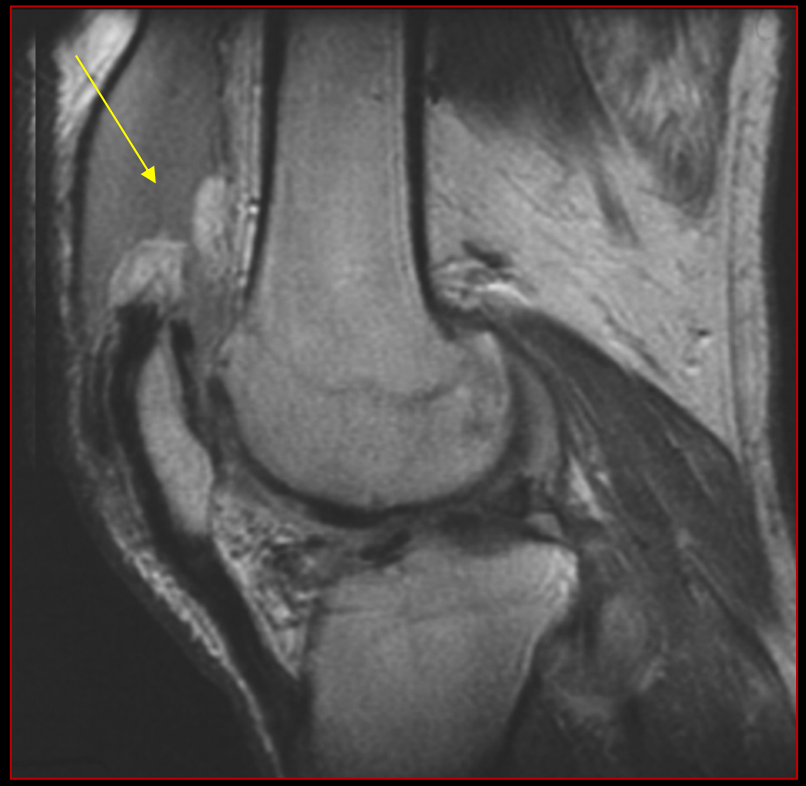

QUADRACEPS TENDON INJURY

NORMAL

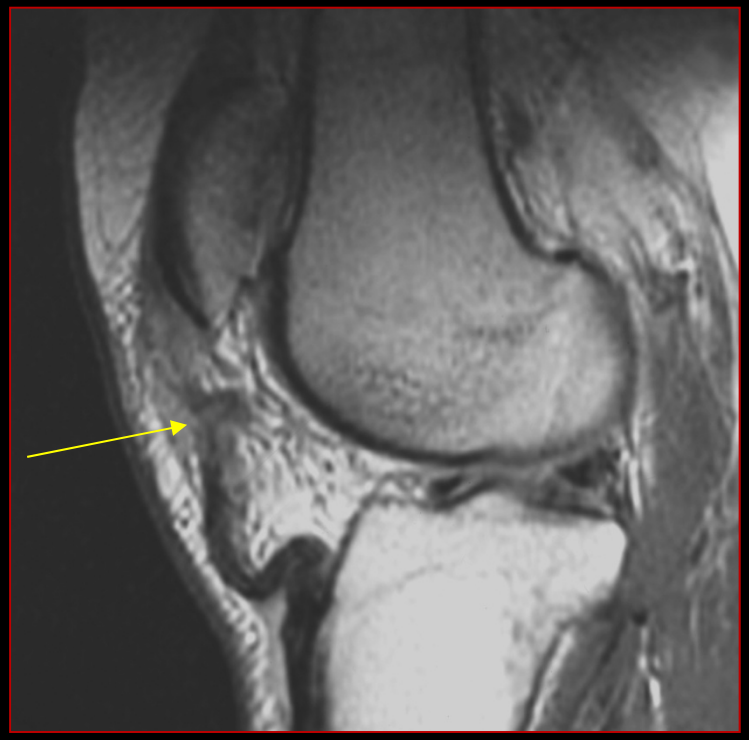

Patella tendon injury

ANTERIOR CRUCIATE LIGAMENT INJURY

Normal

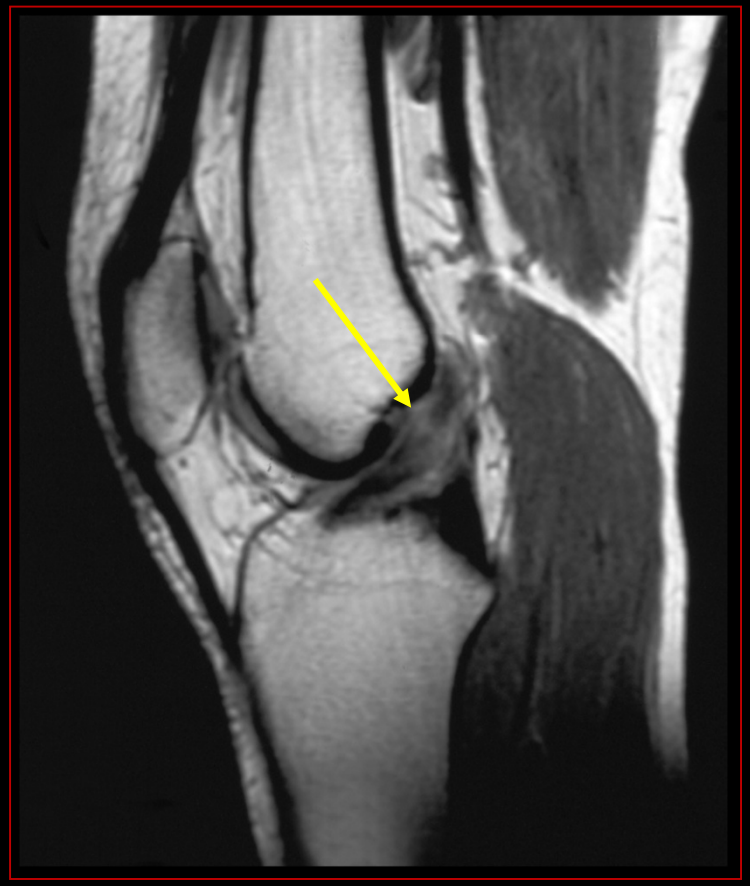

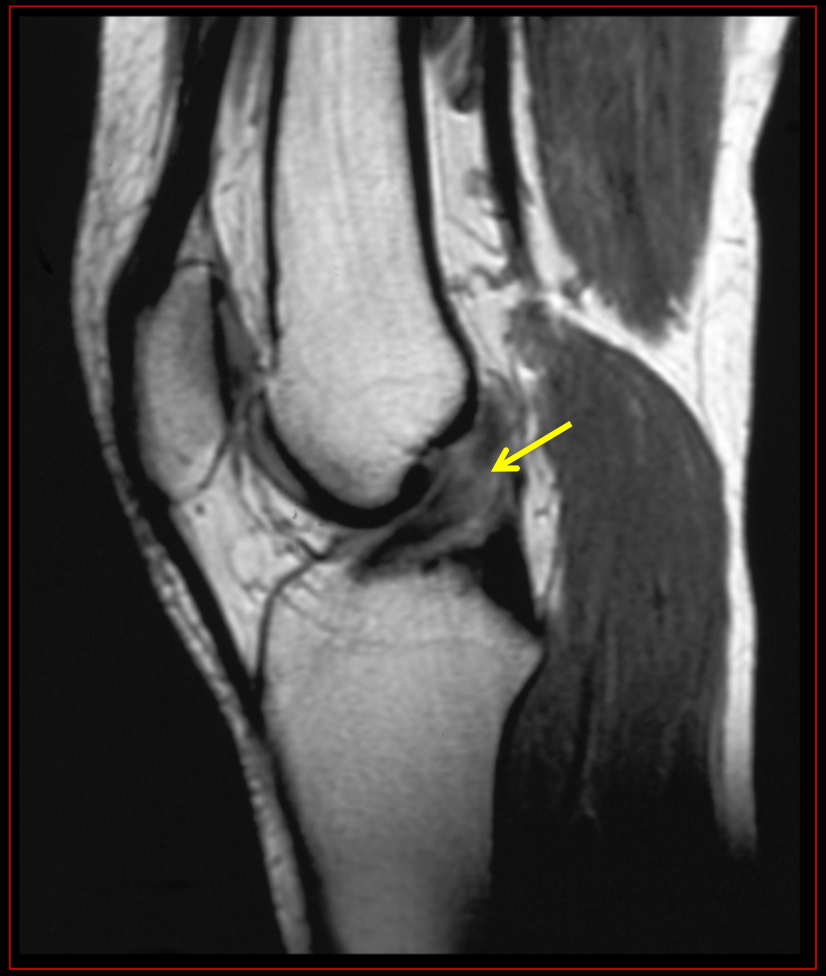

POST OPERATIVE LIGAMENT REPAIR

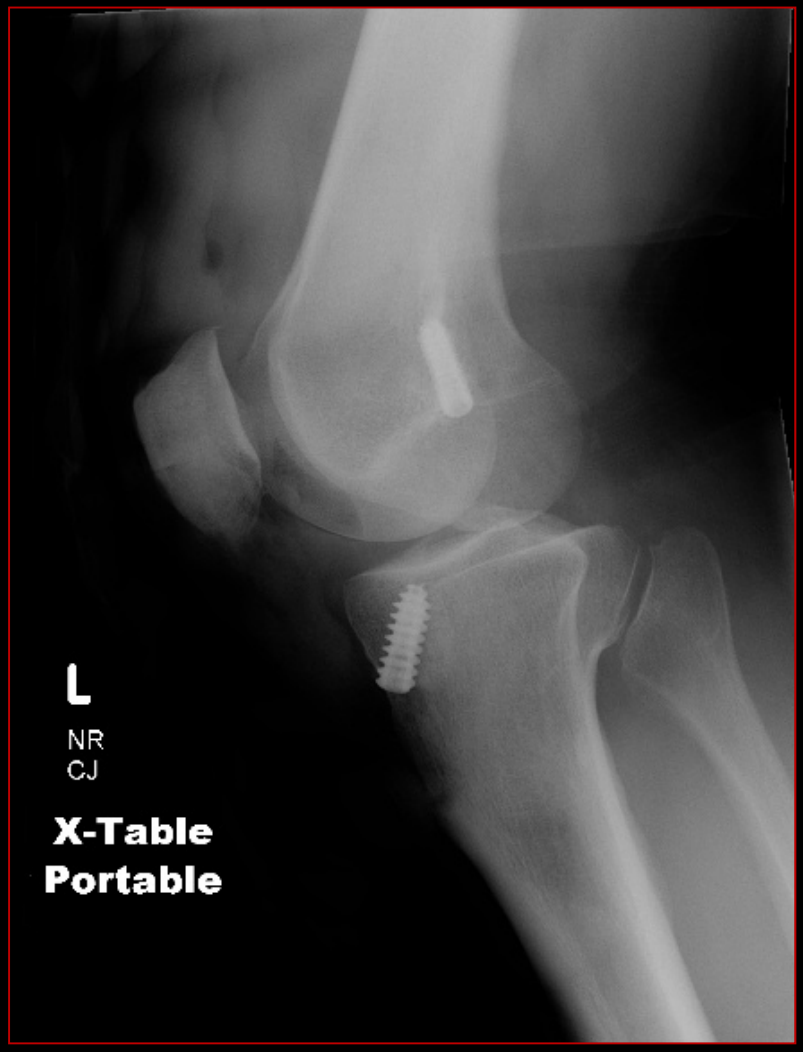

POSTERIOR CRUCIATE LIGAMENT INJURY

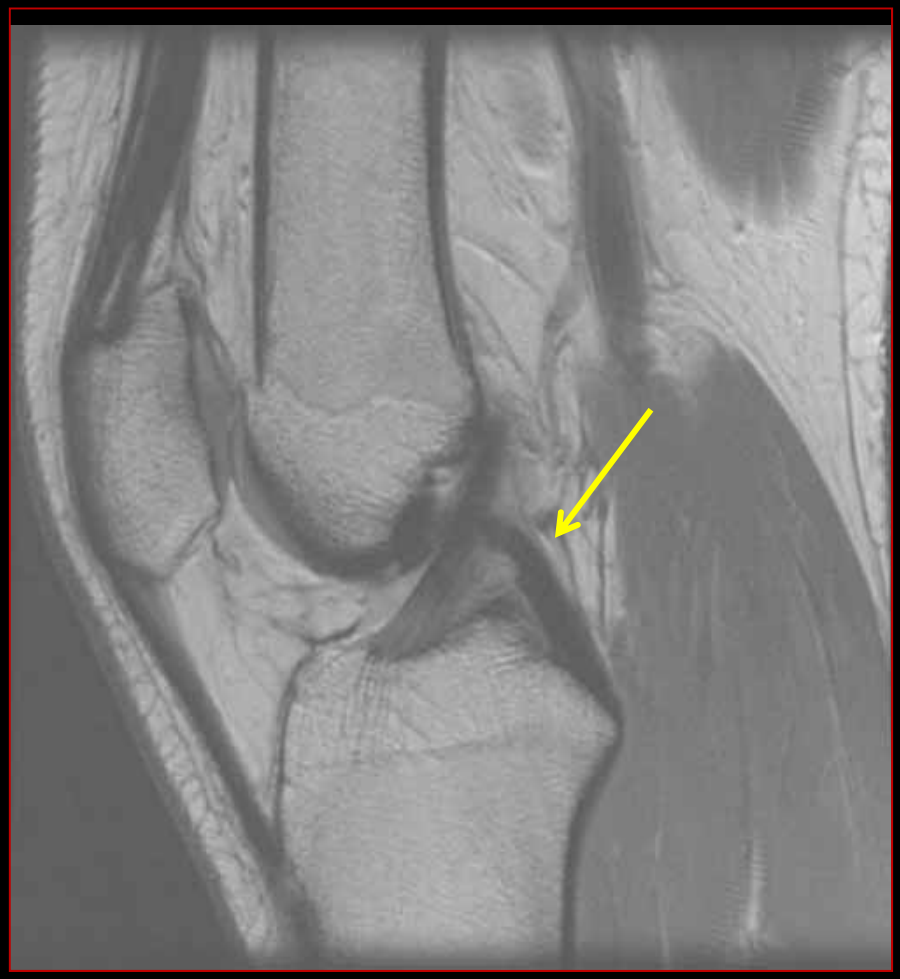

normal

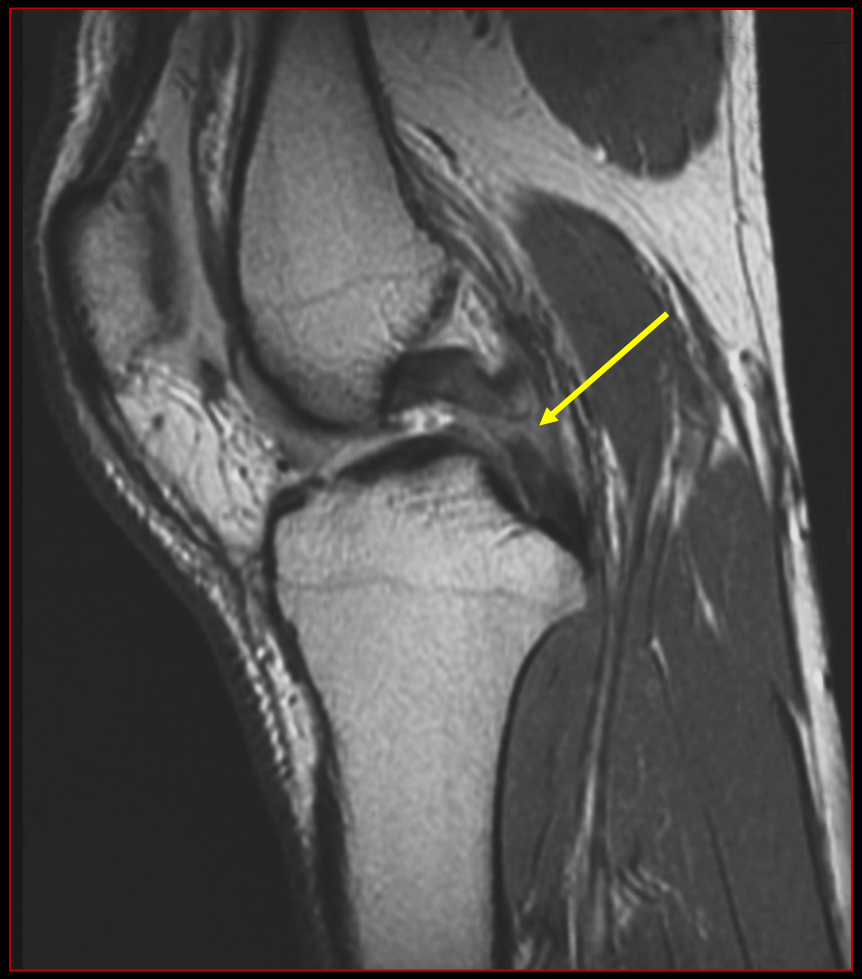

MENISCUS

NORMAL

TORN

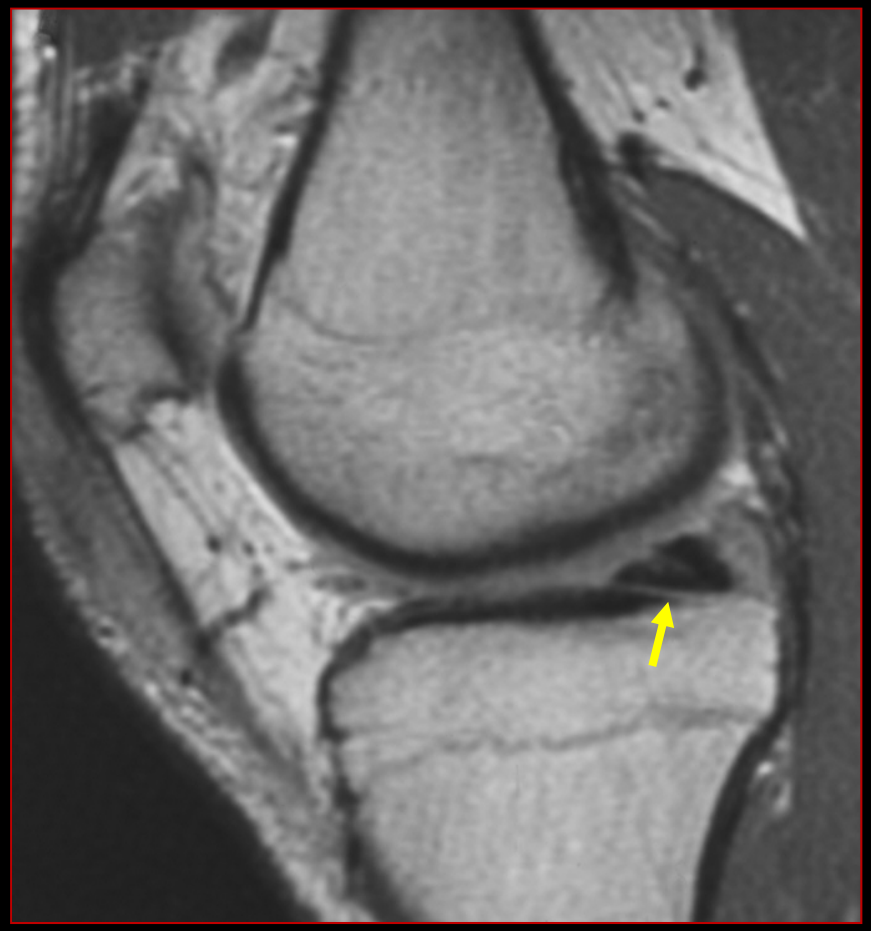

WHAT IS MY AGE?

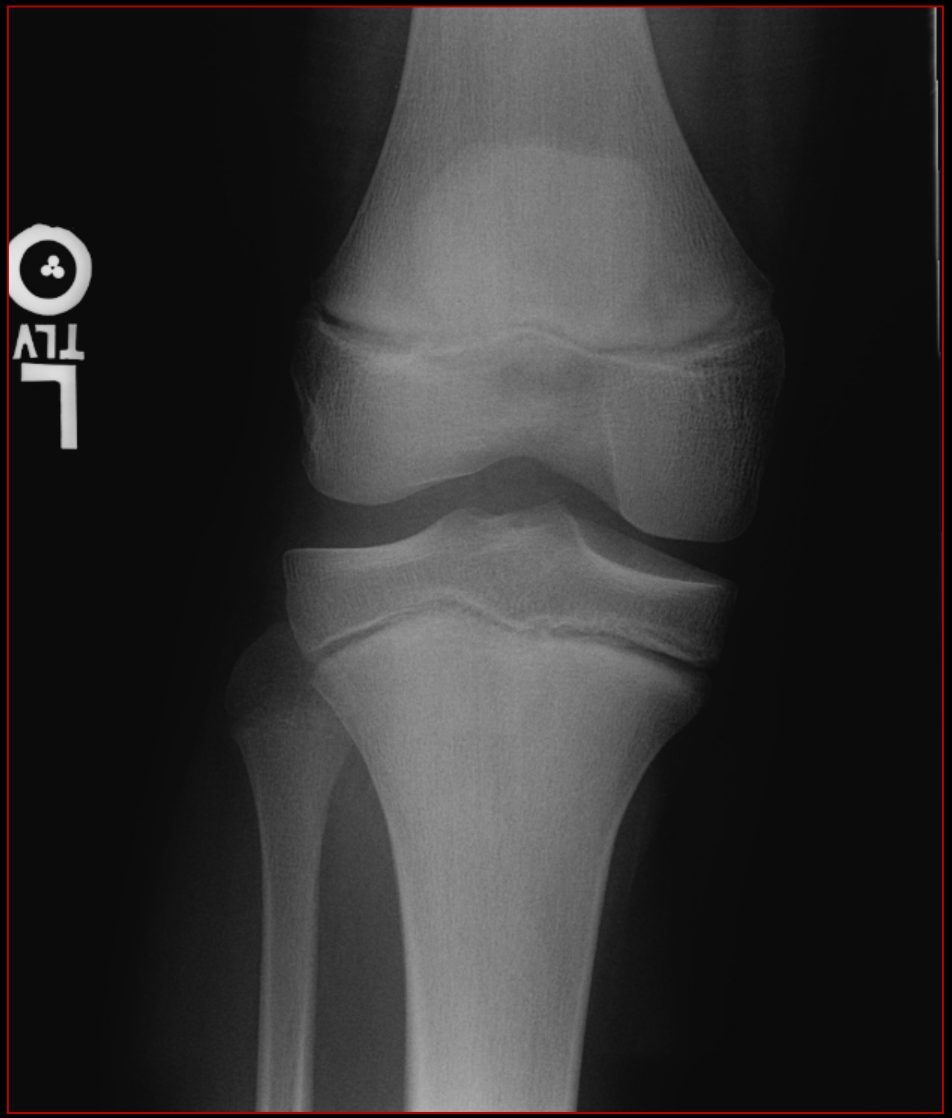

POST OP TOTAL KNEE

BEFORE

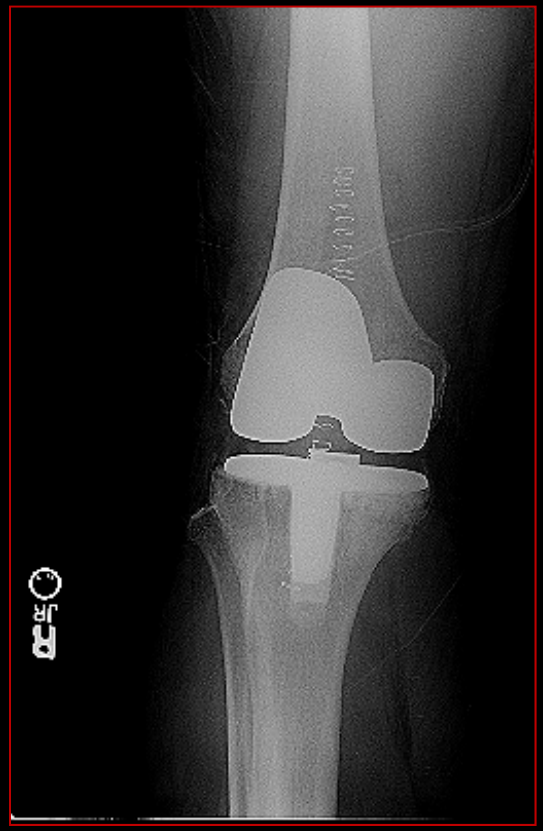

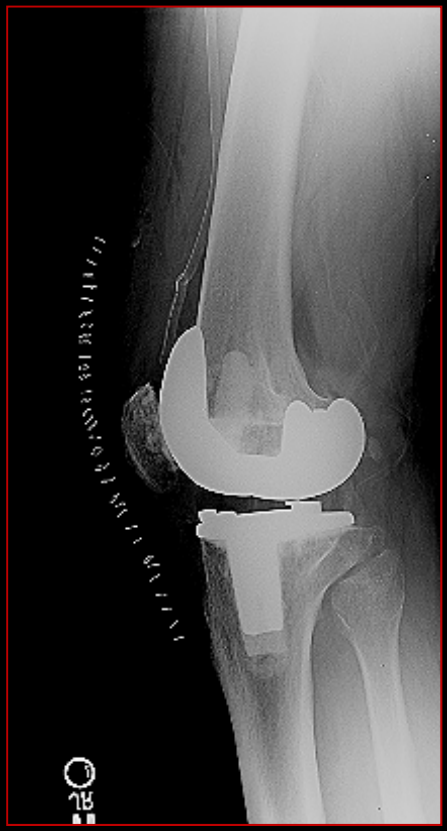

POST -OP

AP TIBIA & FIBULA

(LOWER LEG)

AP ANKLE

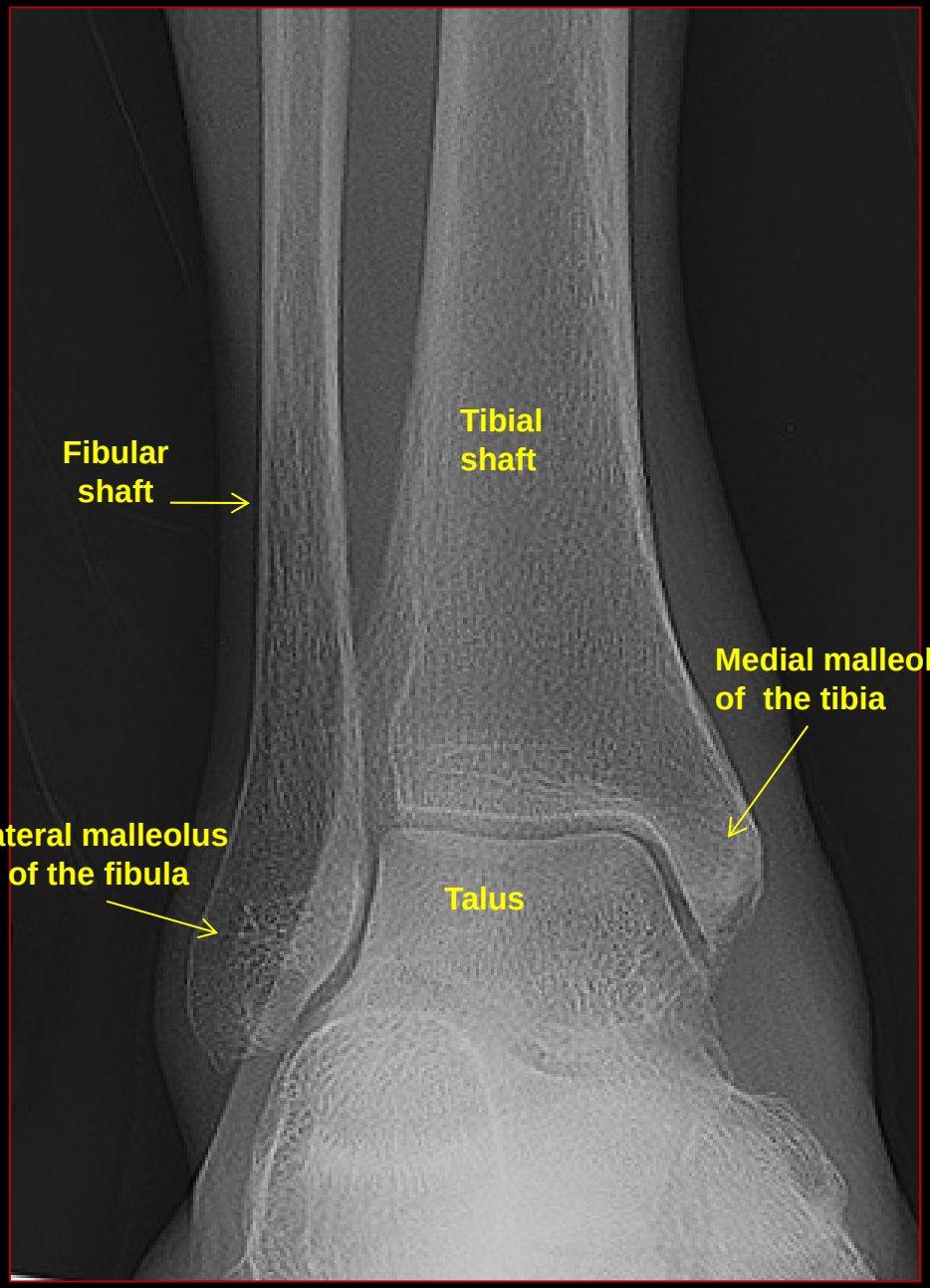
Fibular
shaft
Tibial
shaft
Medial malleolus
of the tibia
Lateral malleolus
of the fibula
Talus

LATERAL ANKLE

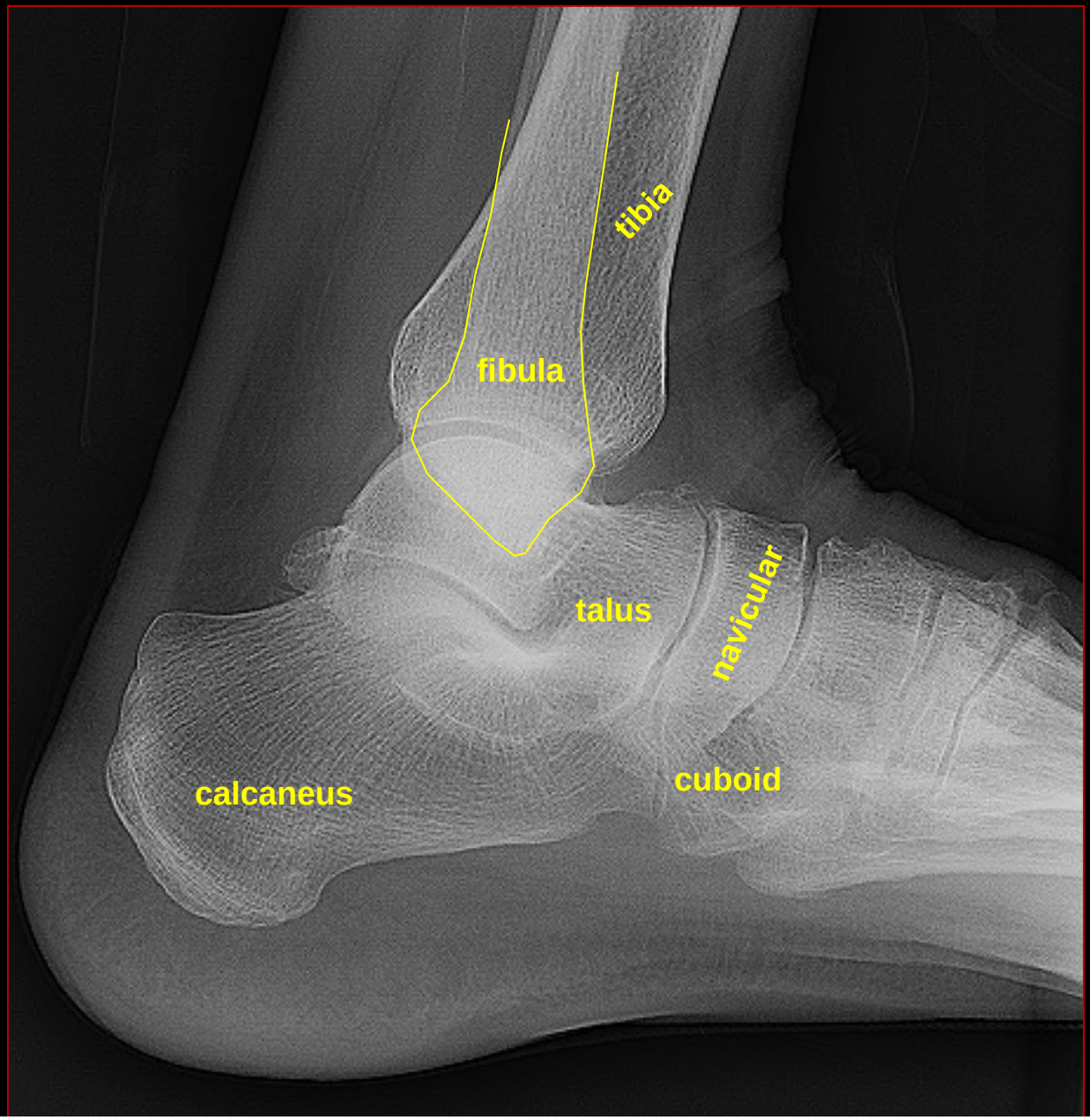

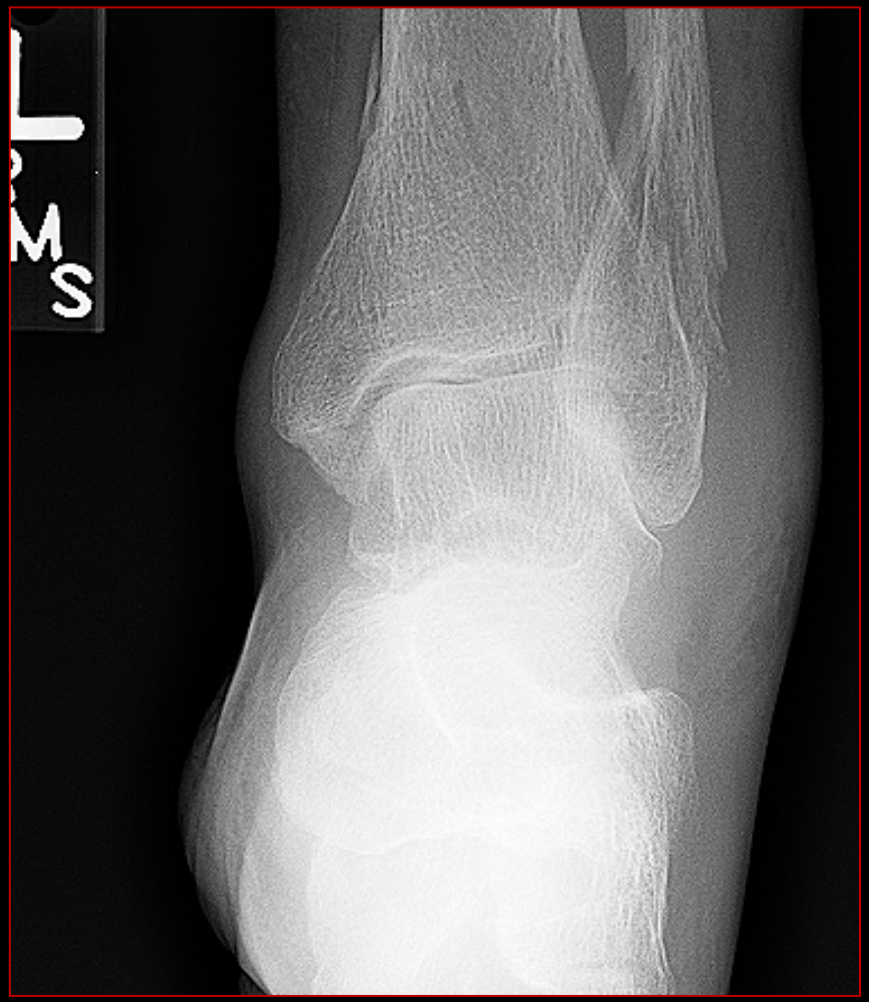

Fractures through the medial and lateral malleoli.

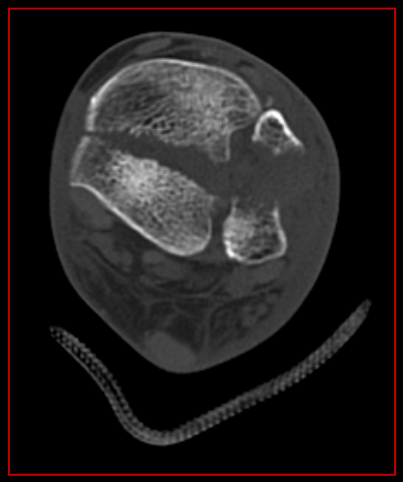

AP FOOT


PP = proximal phalanx
MP = middle phalanx
DP = distal phalanx
MT = metatarsal
cun = cuneiform
1st DP
2 DP
2 MP
3 DP
4 DP
3 MP
5 DP
4 MP
5 MP
1st PP
2 PP
3 PP
4 PP
5 PP
sesamoids
1st MT
2nd MT
3rd MT
4th MT
5th MT
1st cun
2nd cun
3rd cun
navicular
cuboid
talus
calcaneus

LATERAL FOOT

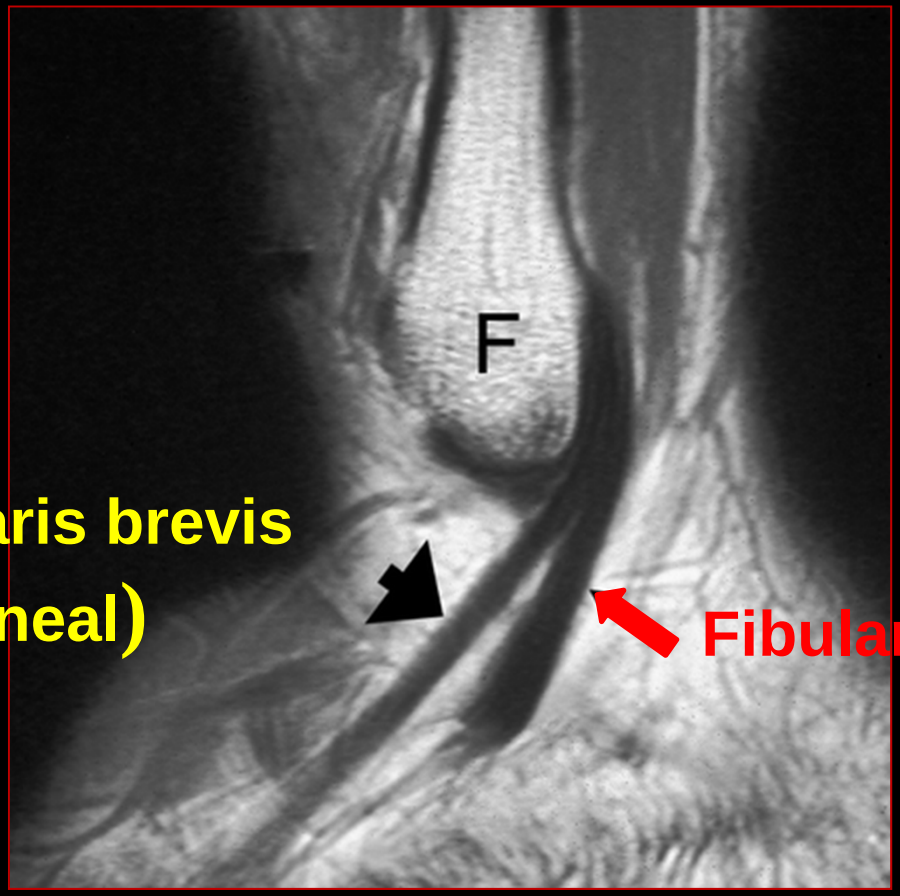

Fibularis brevis
(Peroneal)

Fibularis longus

CALCANEAL FRACTURE

PATIENT FELL OFF OF A LADDER

DIABETIC OSTEOMYLITIS

BONE SCAN

OSTEOMYELITIS

GOUT