THE KNEE JOINT

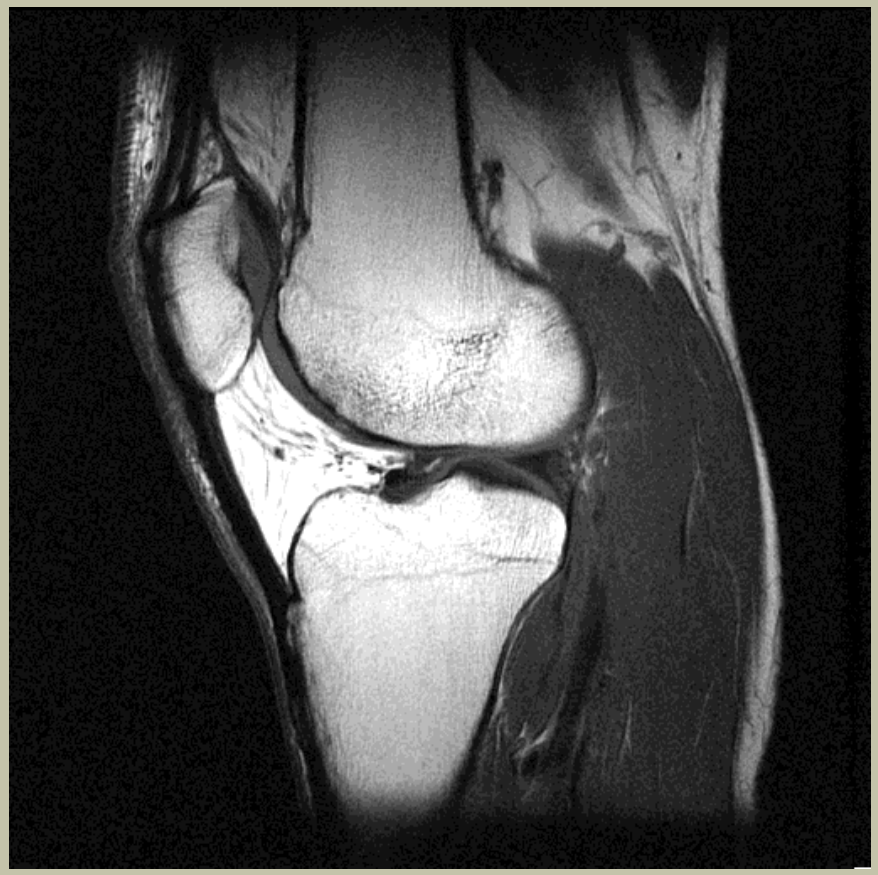

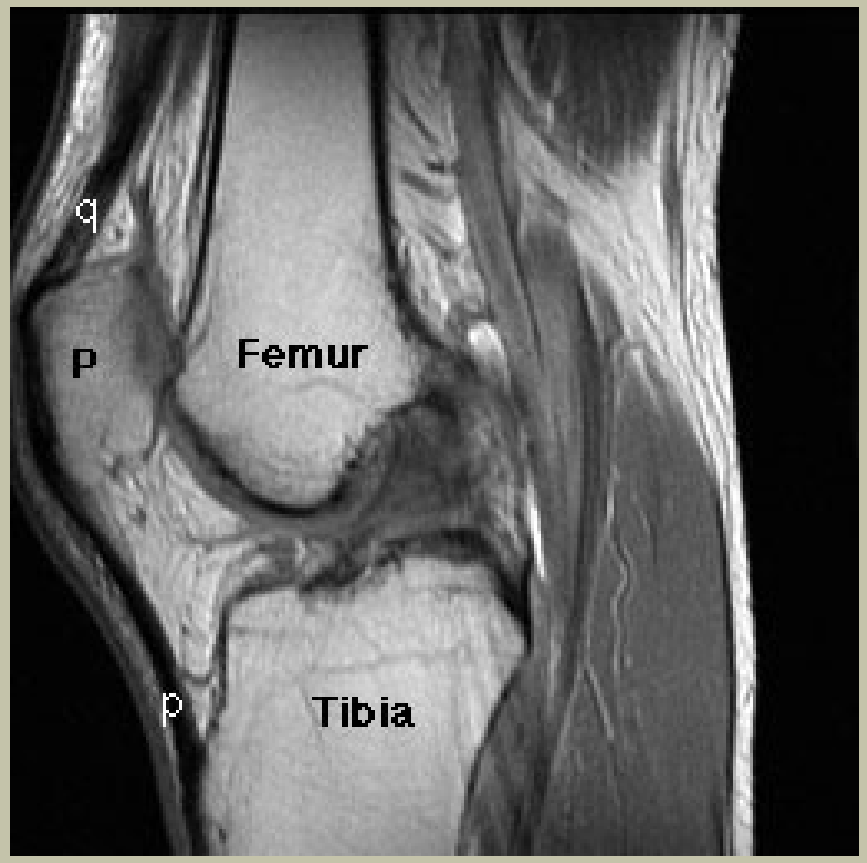

www.fisiokinesiterapia.biz

BONES OF THE KNEE

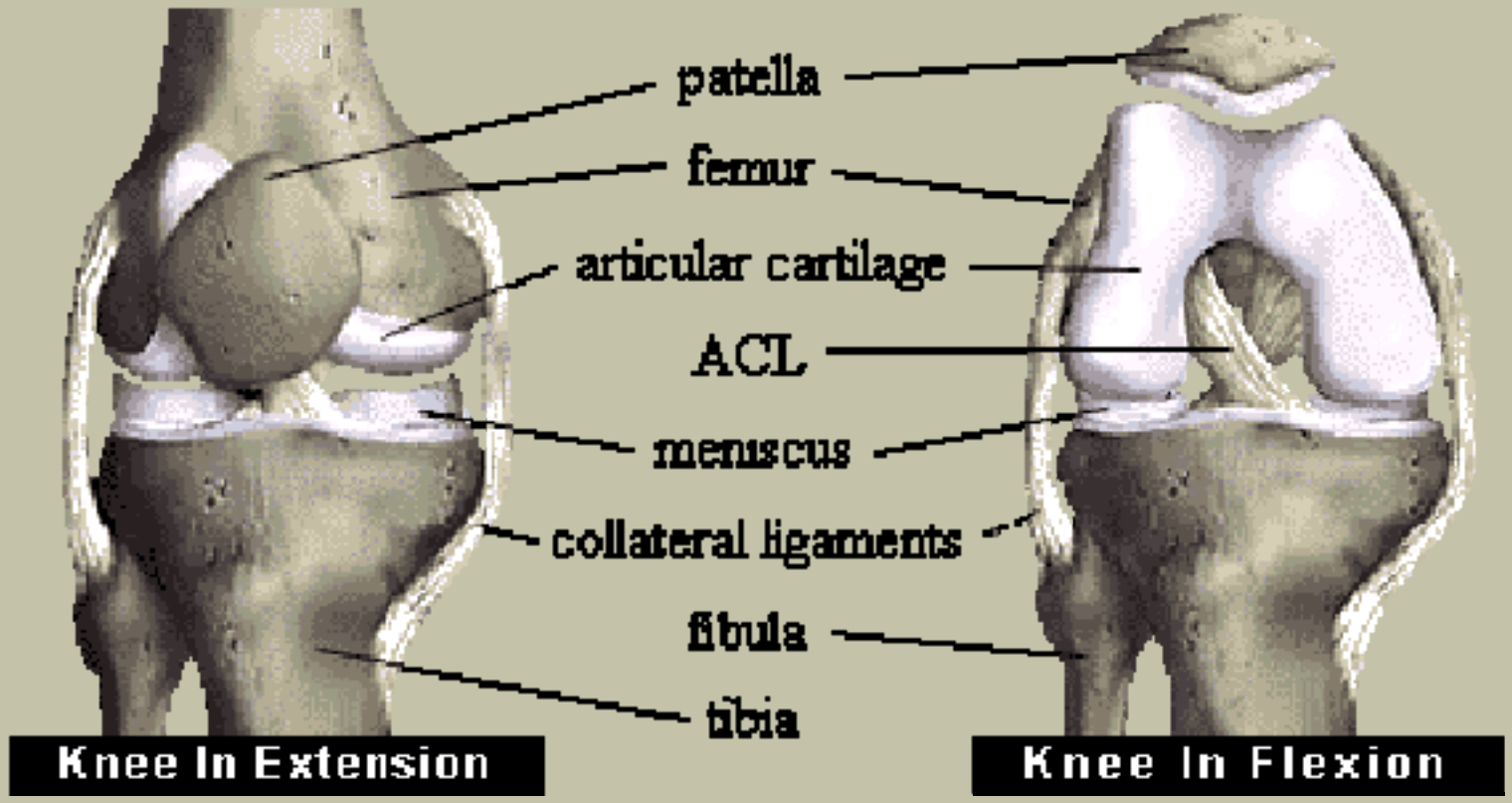

FEMUR

- Lateral condyle (6 left)
- Medial condyle (8 left)

- Intercondylar fossa (7 left)
-

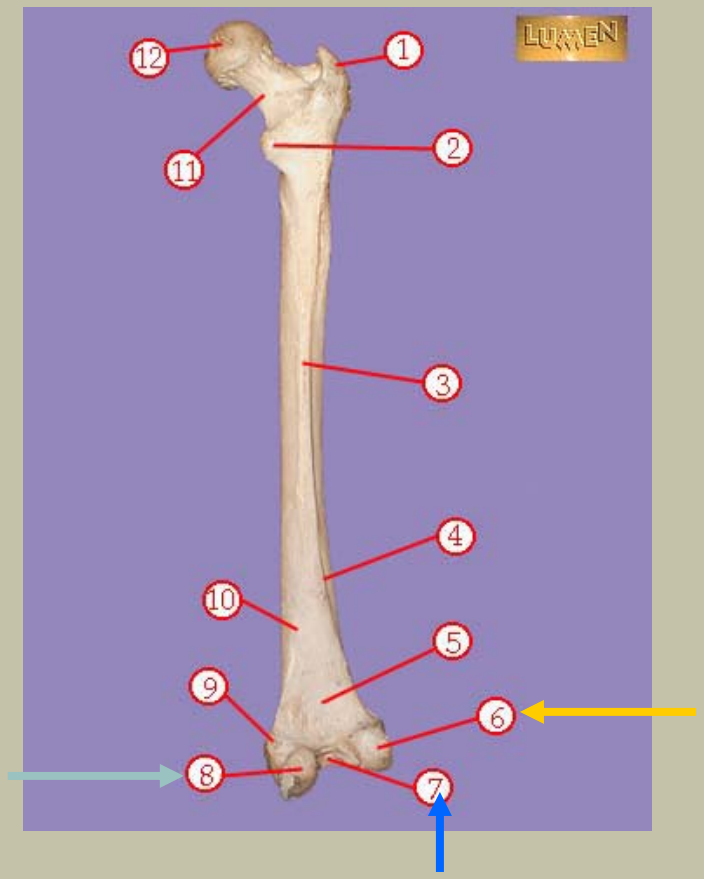

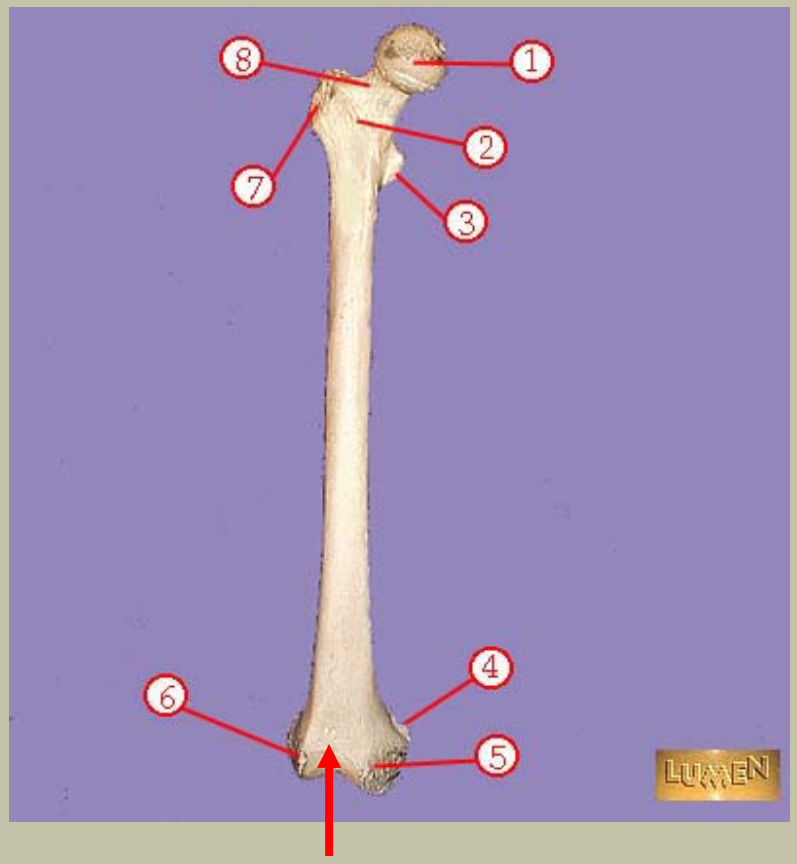

FEMUR

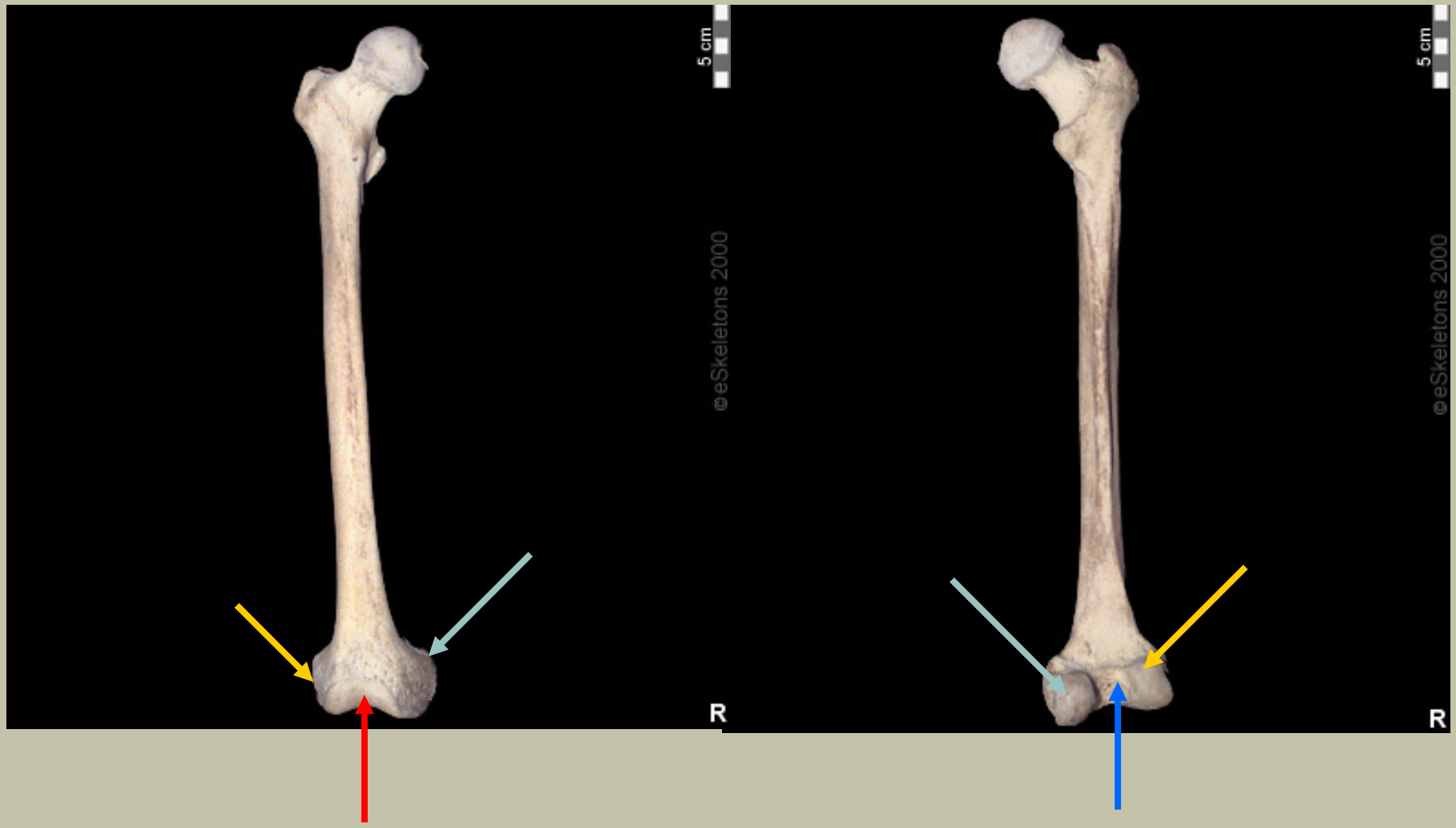

FEMUR

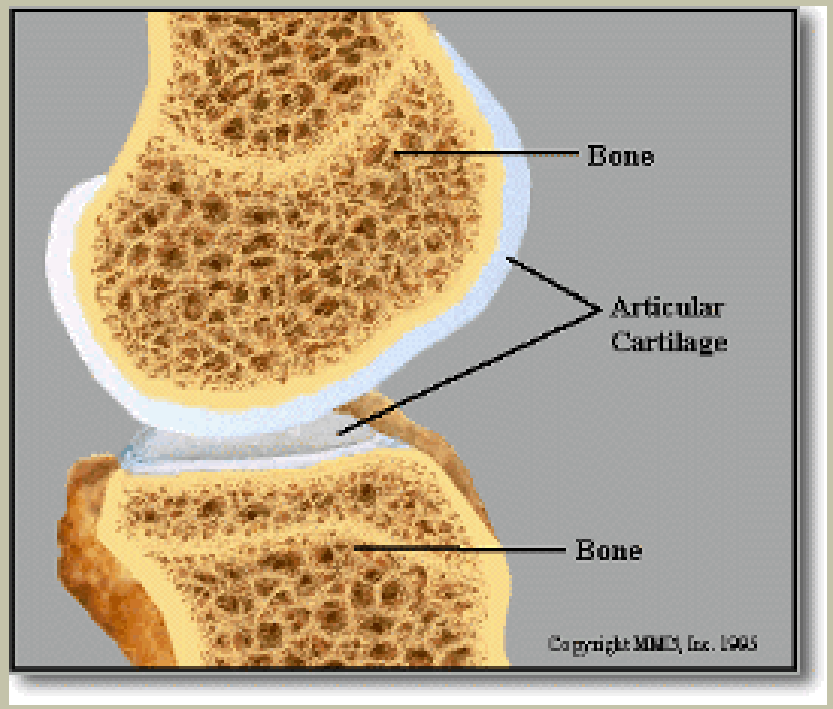
Bone
Articular
Cartilage
Bone
Copyright MMS, Inc. 1995

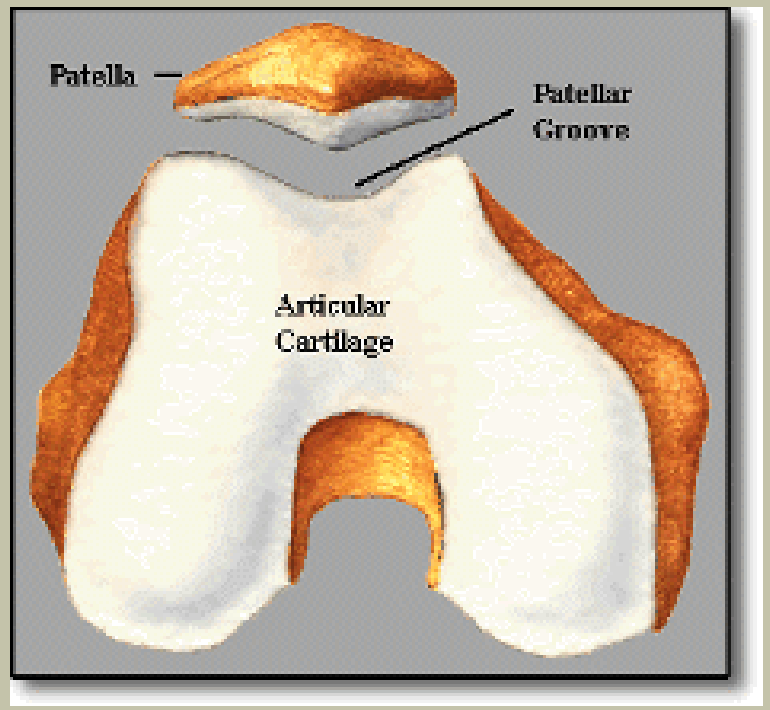
Patella
Patellar
Groove
Articular
Cartilage

TIBIA

- Medial condyle
- Lateral condyle

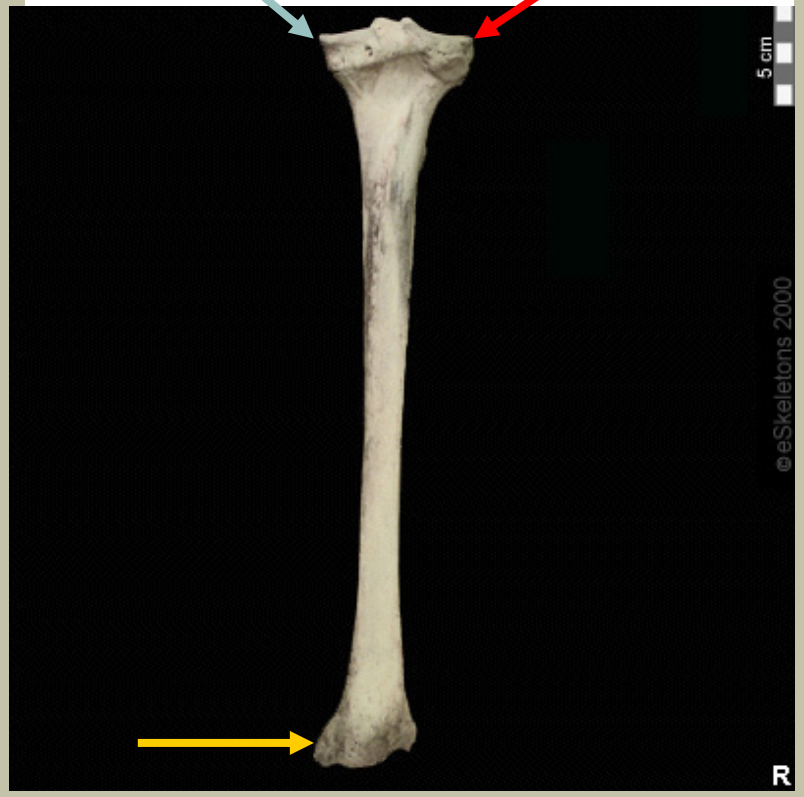

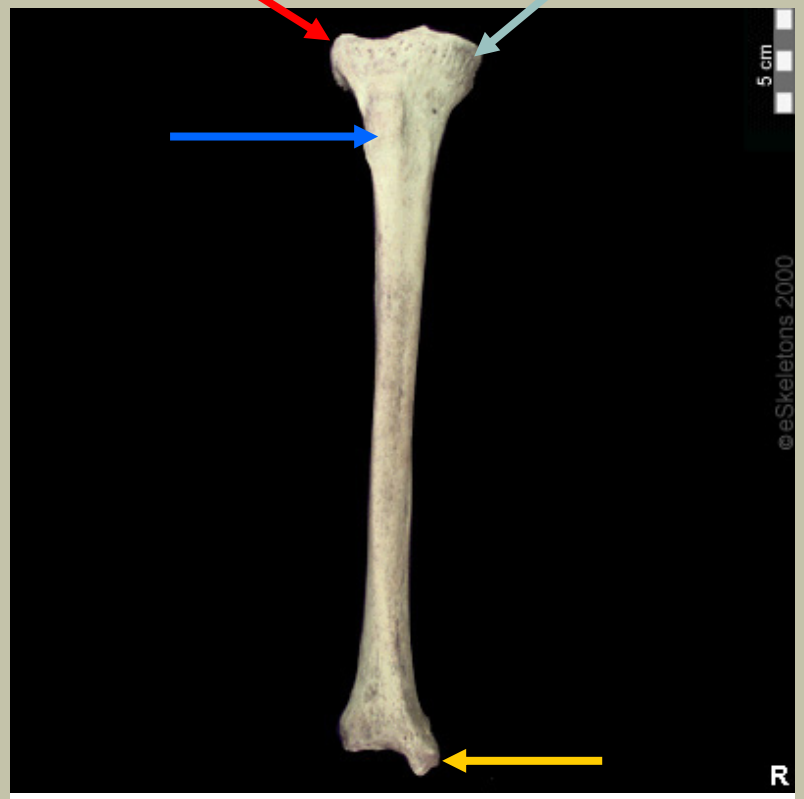

- Tibial Tuberosicty
- Medial Malleolus

TIBIA



TIBIA

- Anterior medial surface
  - Insertion for semitedonosis, semimembranosis, gracilis and sartorius

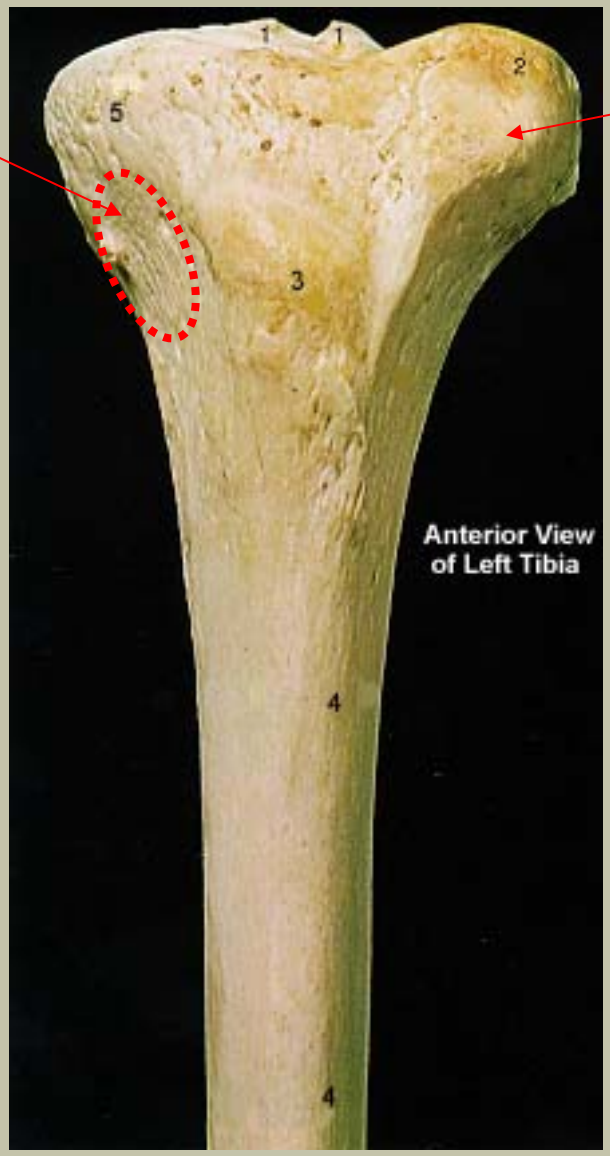

- Gerdy's tubercle
  - IT band insertion

FIBULA

- No connection with the femur
- Head
- Lateral malleolus

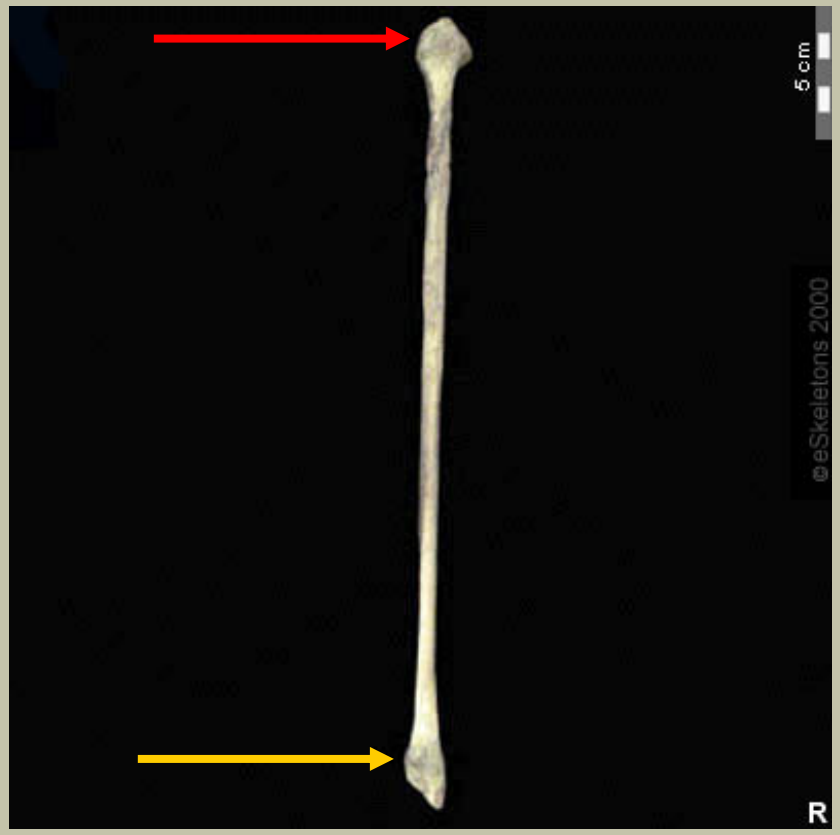

PATELLA

- A ‘sesamoid’ (floating) bone
- Protection
- Mechanical advantage to quads.
- Without the patella, 30% more force would be required by the quads

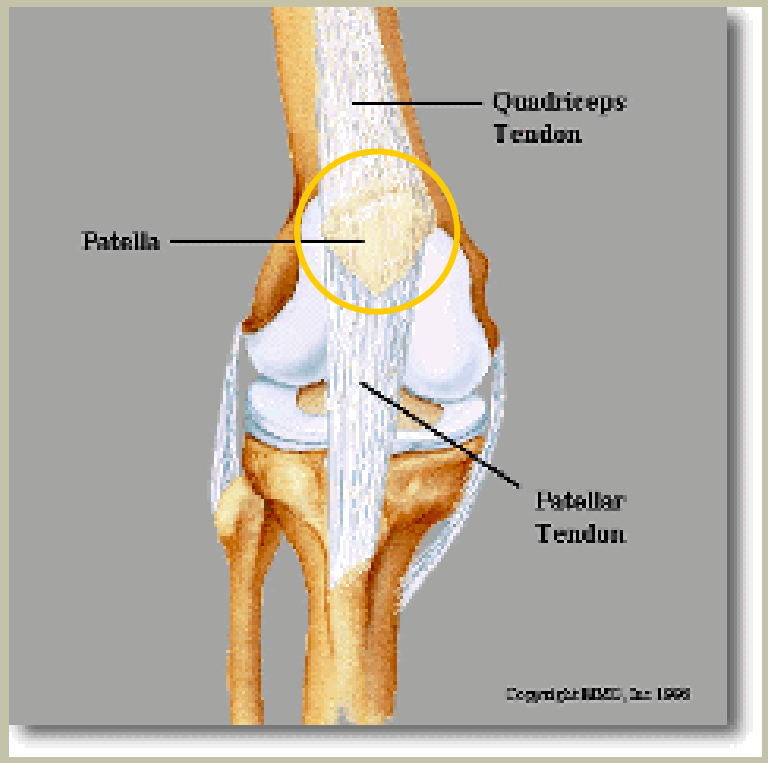

www.fisiokinesiterapia.biz

PATELLA

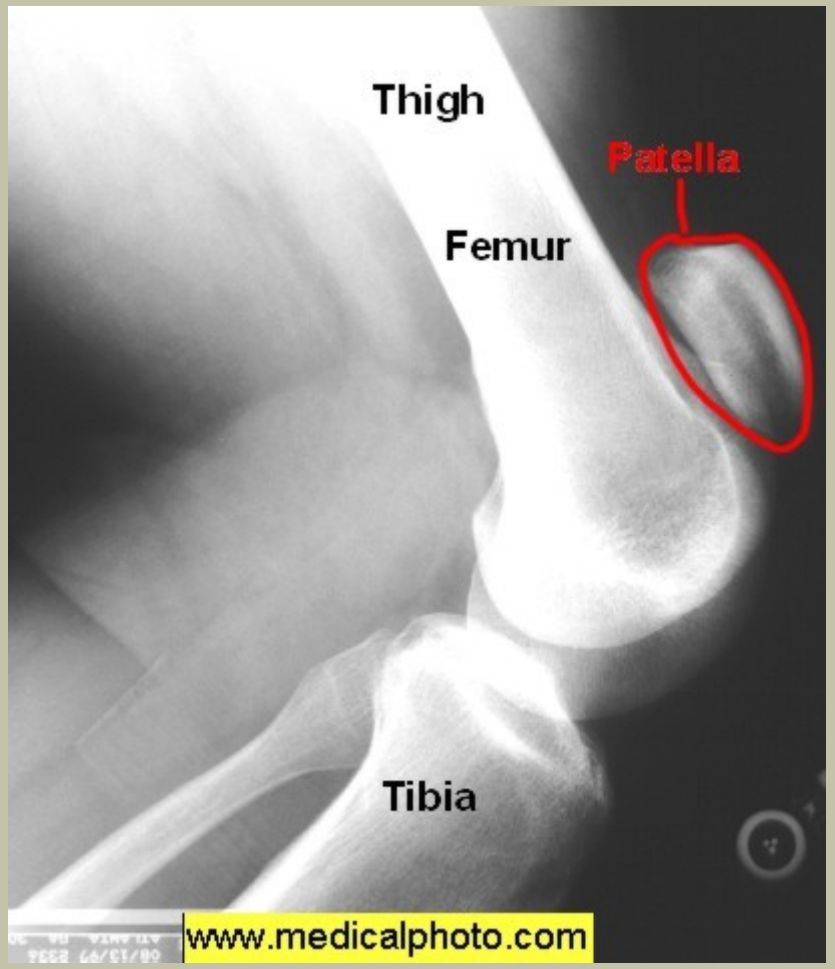
Thigh
Patella
Femur
Tibia
www.medicalphoto.com


Patella

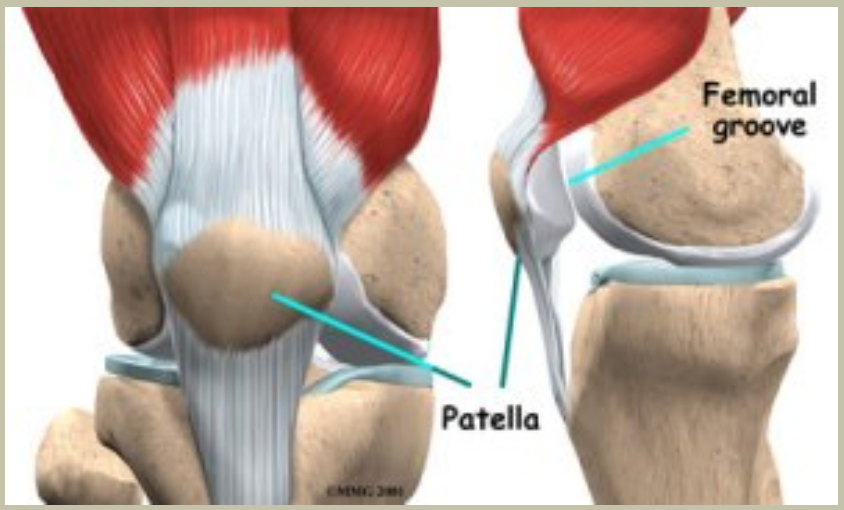
Femoral groove
Patella

THE KNEE

1. Femur - medial condyle
2. Femur - lateral condyle
3. Tibia - medial condyle
4. Tibia - lateral condyle
5. Anterior medial surface
6. Tibial tuberoscity
7. Gerdy's tubercle (IT band insertion)
8. Head of fibula
9. Patella

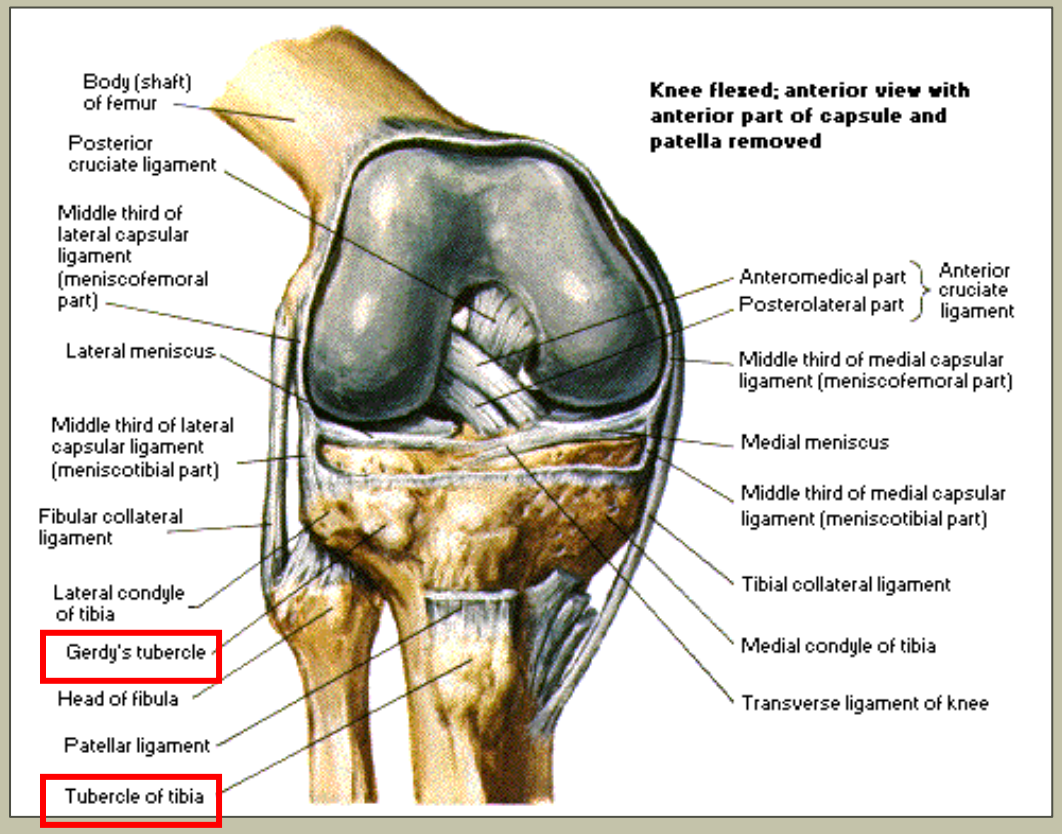

KNEE LIGAMENTS AND CARTILAGE

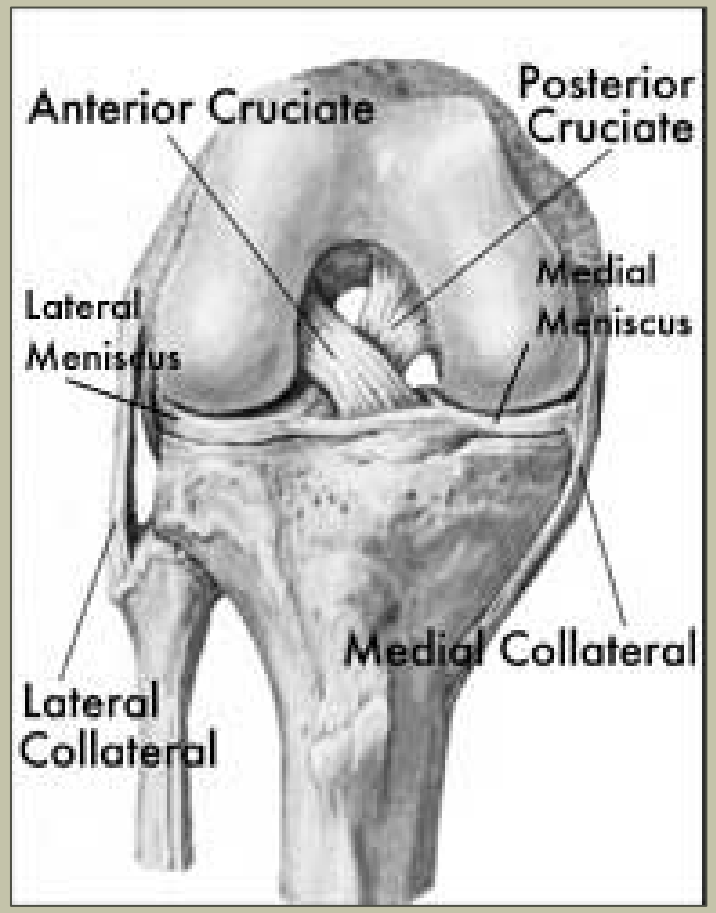

COLLATERAL LIGAMENTS

- They are important in controlling…
  - Tibial rotation
  - Anterior and posterior tibial displacement.
  - Valgus (knocked kneed)
  - Varus (blow legged)

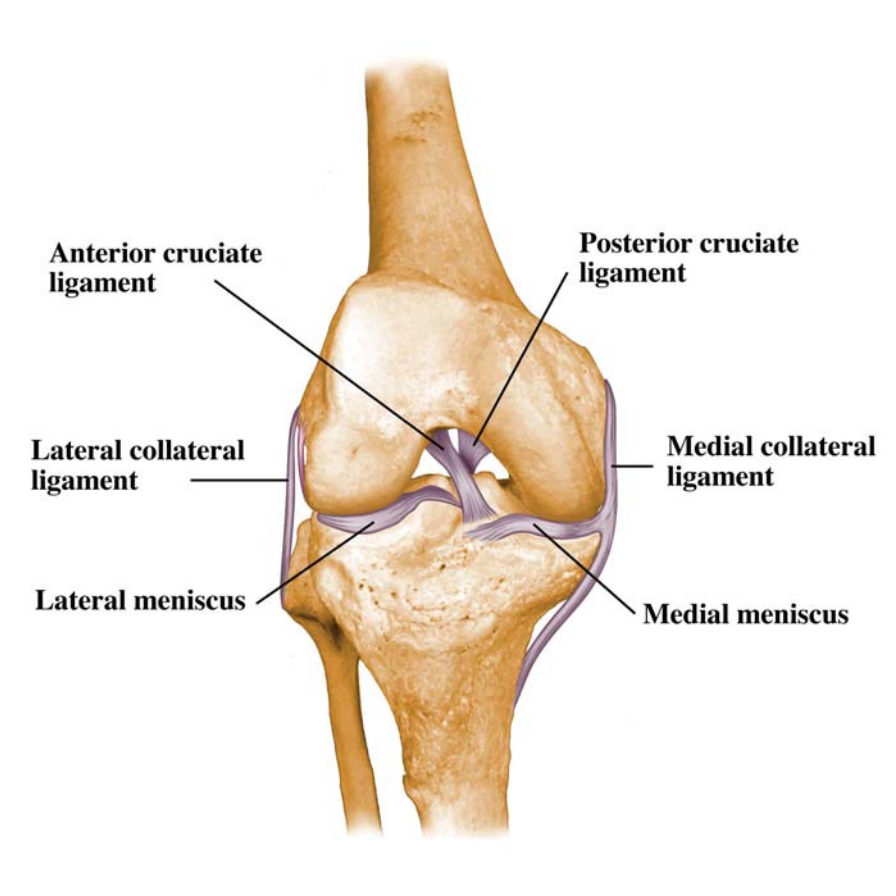

MEDIAL COLLATERAL

- Medial aspect of the knee
- Attached to medial meniscus,

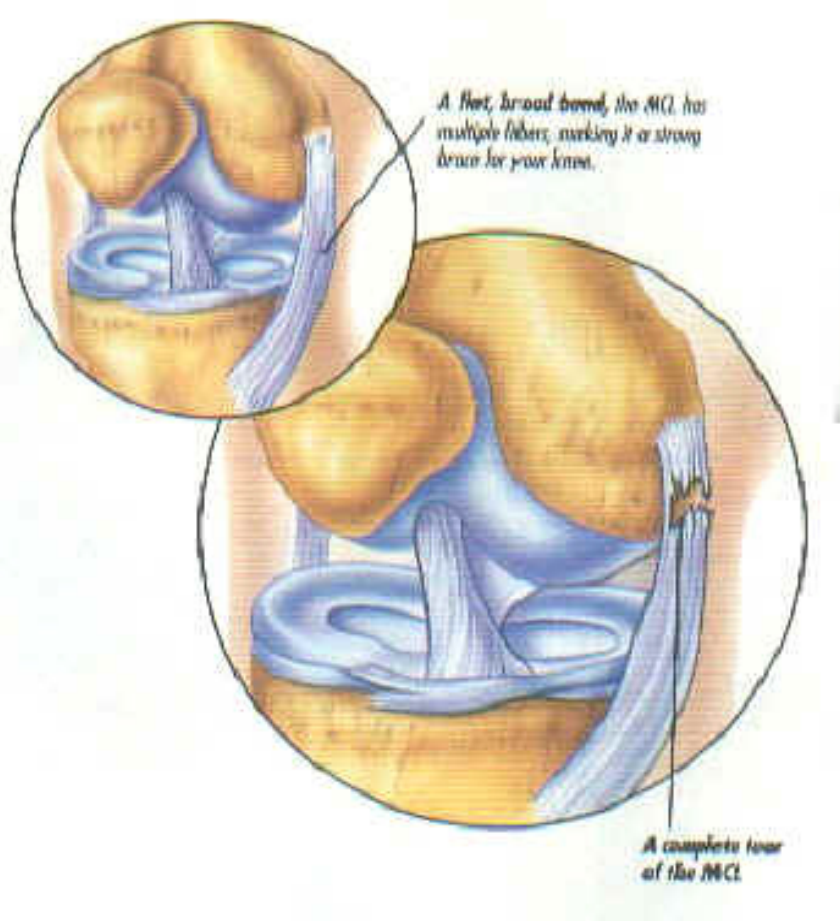

LATERAL COLLATERAL

- Lateral aspect of the knee
- Is not attached to lateral meniscus.

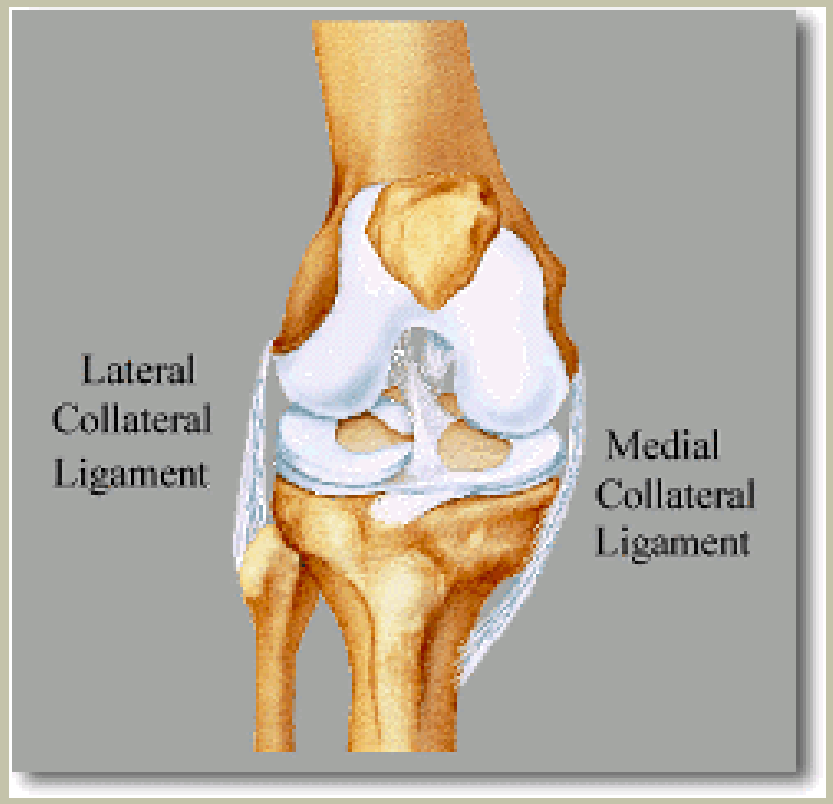

VALGUS AND VARUS

Valgus – lateral force;
Stress to the medial collateral ligament

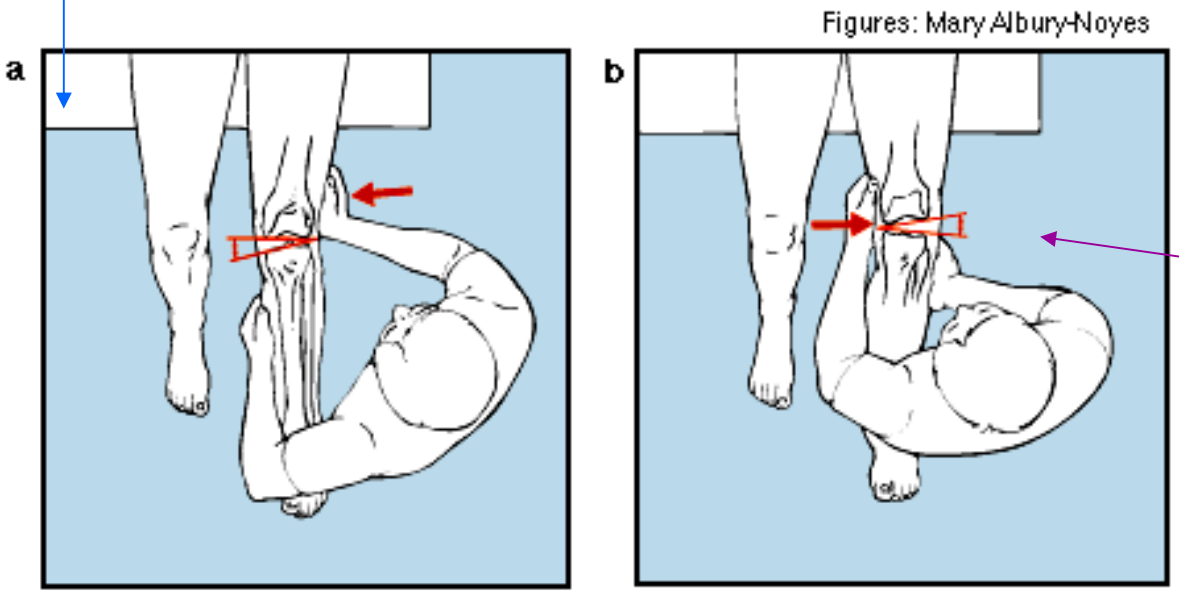

Figure 3. To examine a patient with a suspected medial collateral ligament (MCL) injury for instability (a) the physician supports the seated patient's leg with one hand, tucking the patient's foot under the examiner's arm. Valgus stress is then applied (arrows). To test for lateral collateral ligament (LCL) instability (b), the physician switches the position of the hands and applies varus stress (arrows). Both tests are performed at full extension and 25° flexion. MCL and LCL injuries are graded by the degree of joint space opening.

Varus – Medial force; Stress to the lateral collateral ligament

VALGUS AND VARUS

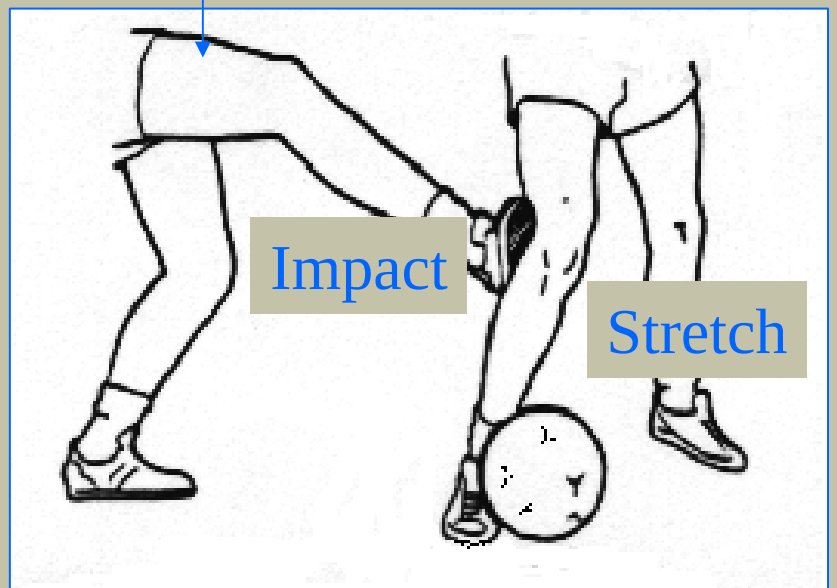

Flexion-Valgus-Rotation externe

(pied bloqué au sol)

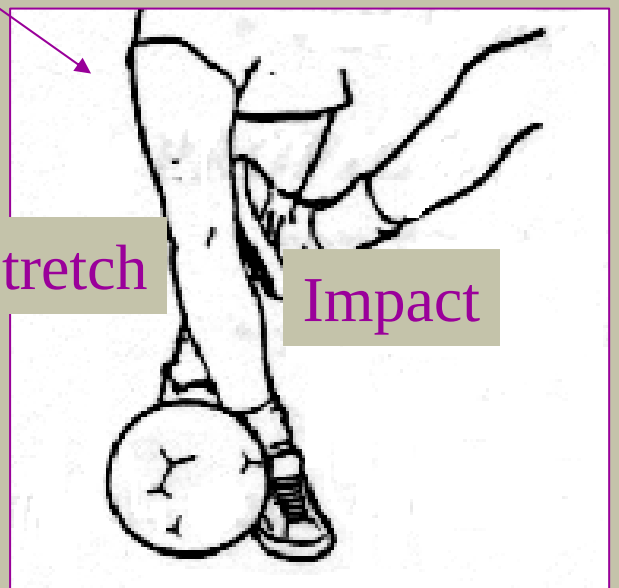

Flexio-Varus-Rotation interne

(Le pied bloqué au sol)

CRUCIATE LIGAMENTS

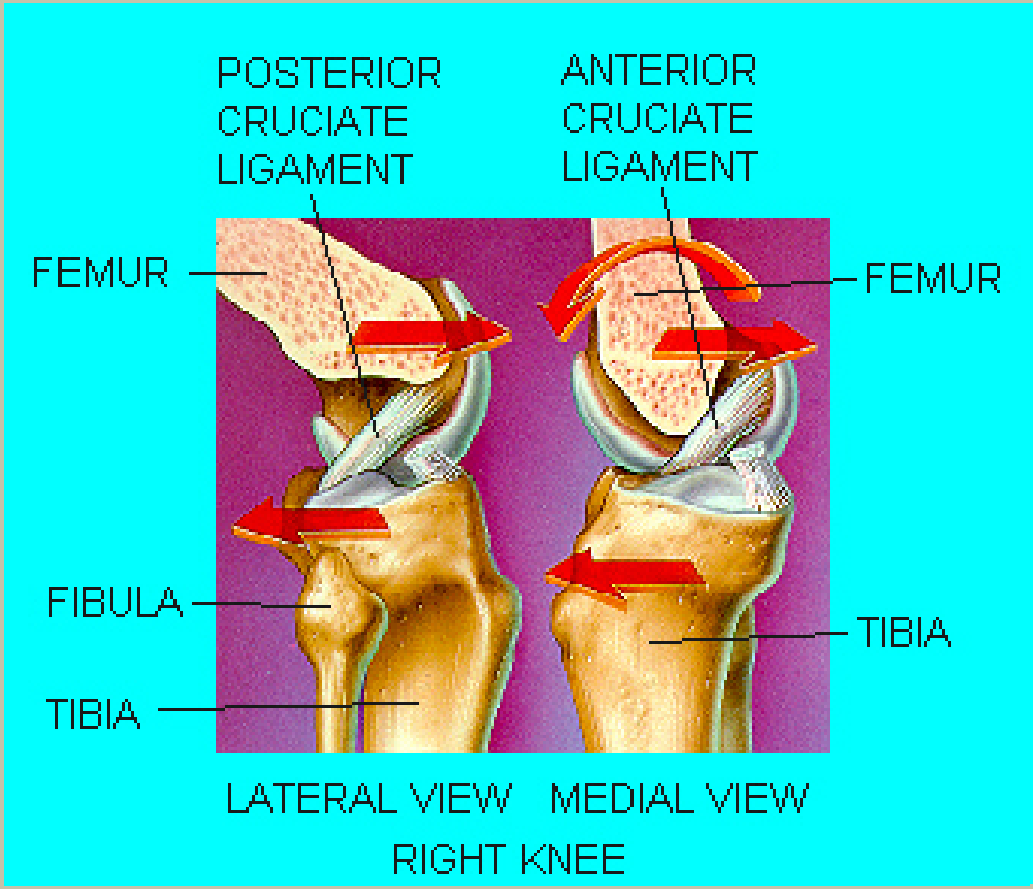

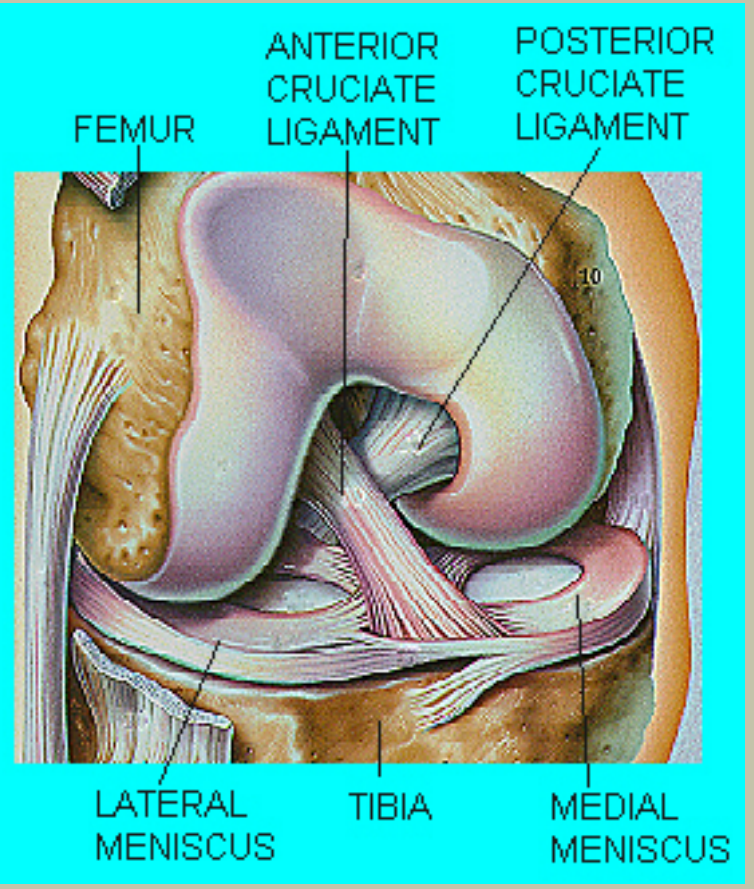

ANTERIOR CRUCIATE LIGAMENT

- Inferior end: proximal, anterior tibia
- Superior end: distal posterior femur
- Prevents excess *anterior motion* of the tibia and posterior motion of the femur

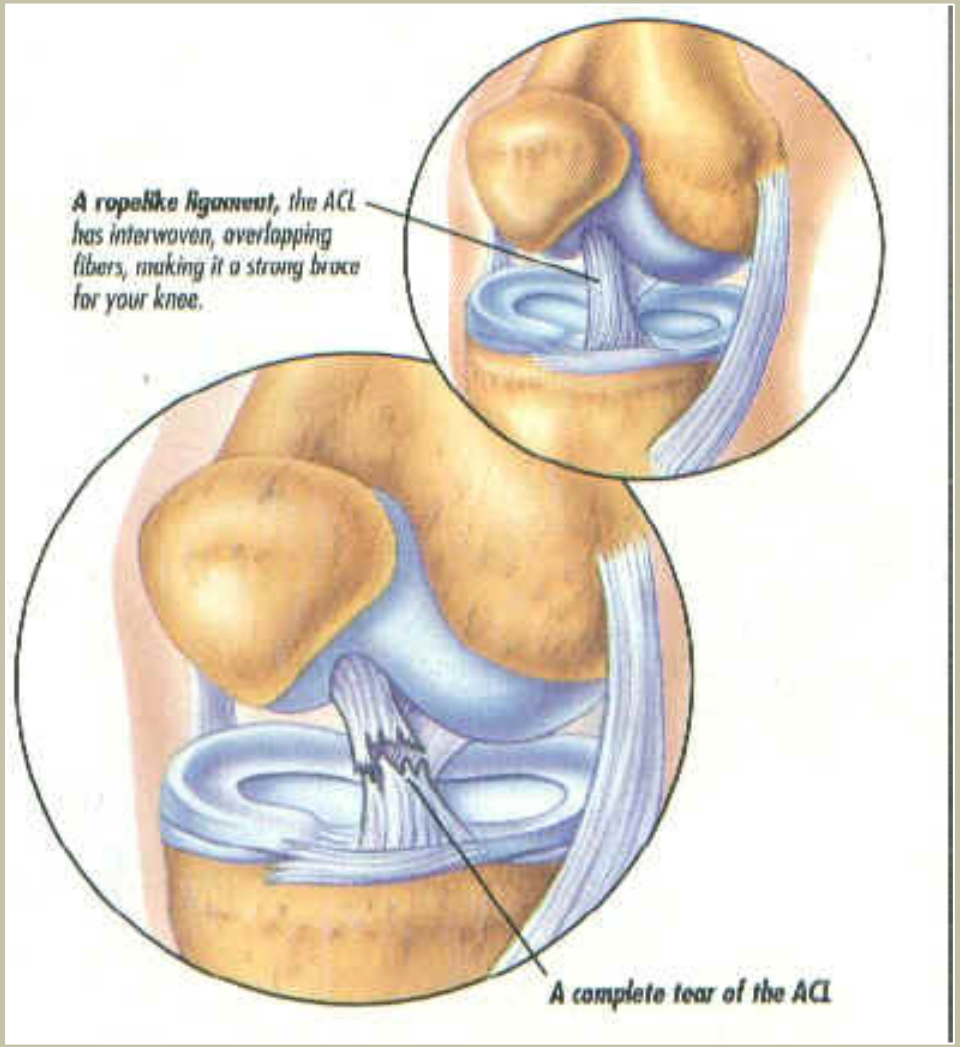

ACL

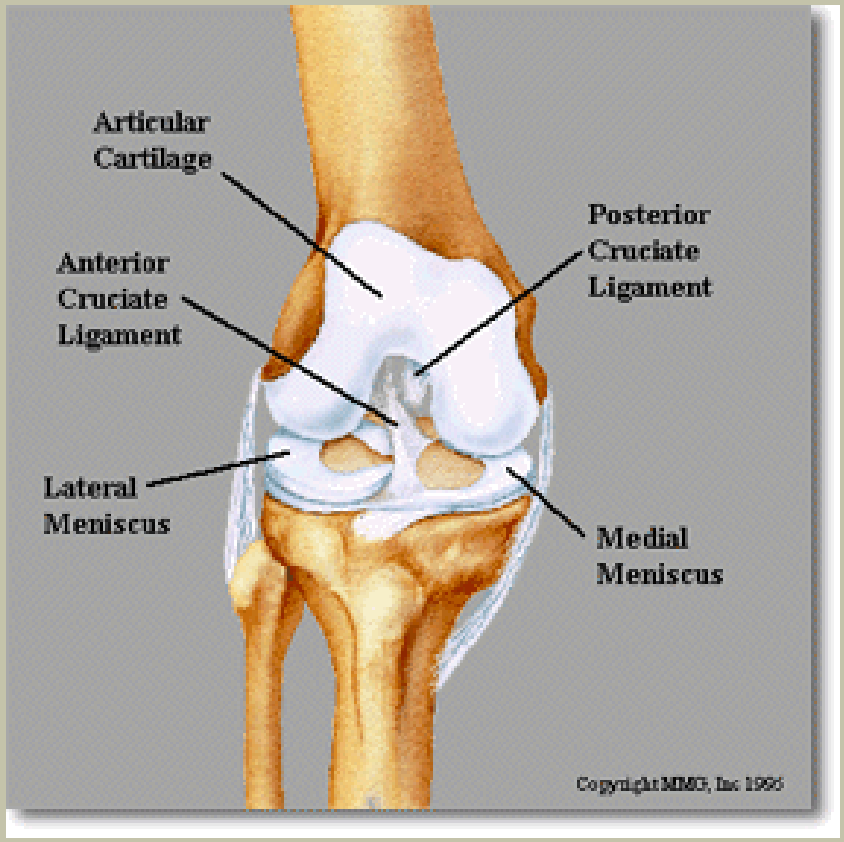

www.fisiokinesiterapia.biz

ACL

Anterior Posterior

Anterior Posterior

POSTERIOR CURCIATE LIGAMENT

- Inferior end: proximal posterior tibia
- Superior end: distal posterior to middle femur
- Prevents excessive posterior movement of the tibia and anterior movement of the femur

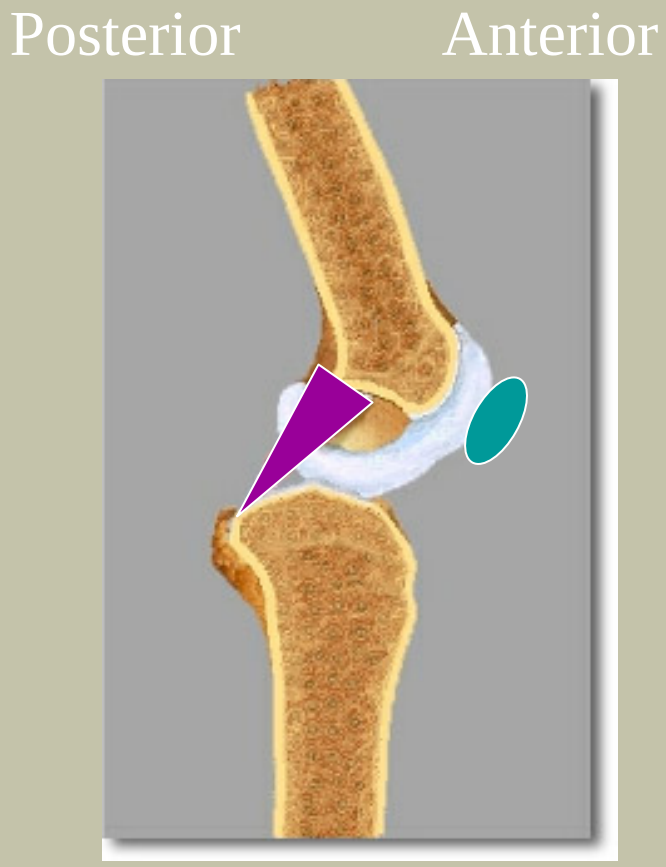

PCL

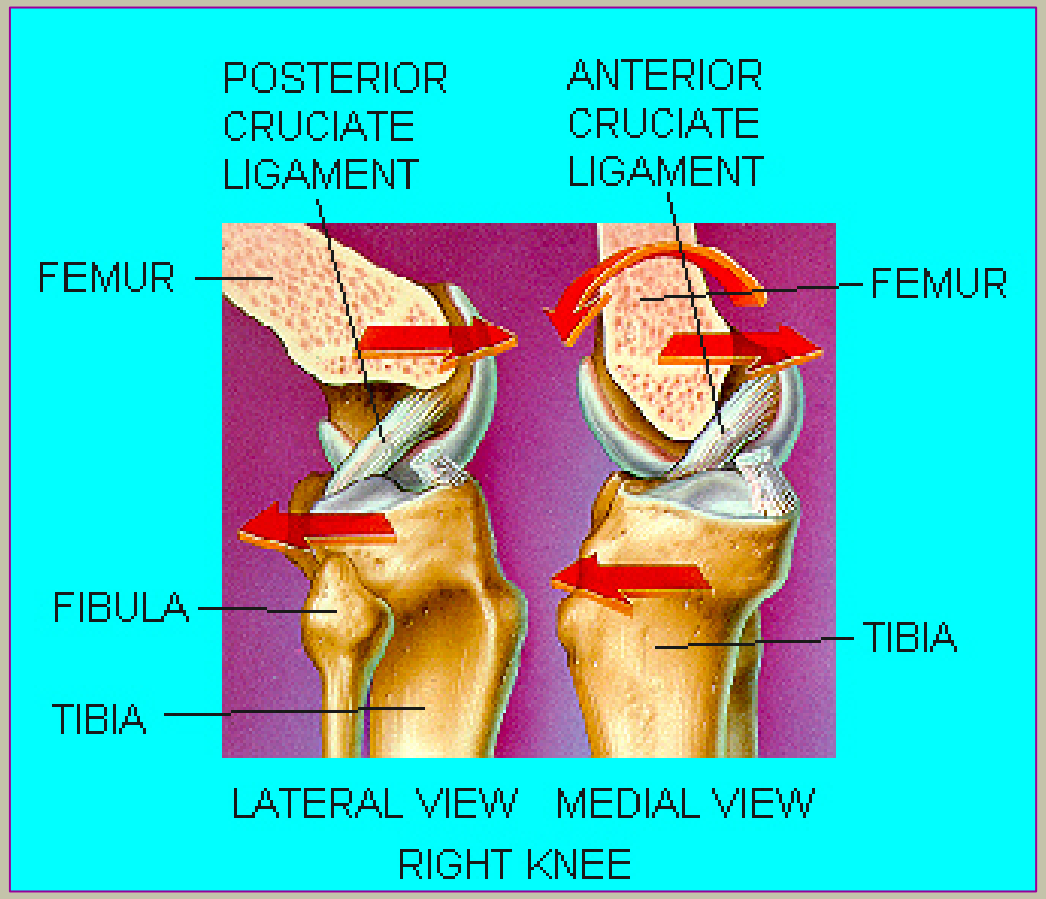
POSTERIOR CRUCIATE LIGAMENT
ANTERIOR CRUCIATE LIGAMENT
FEMUR
FEMUR
FIBULA
TIBIA
TIBIA
LATERAL VIEW
MEDIAL VIEW
RIGHT KNEE

PCL

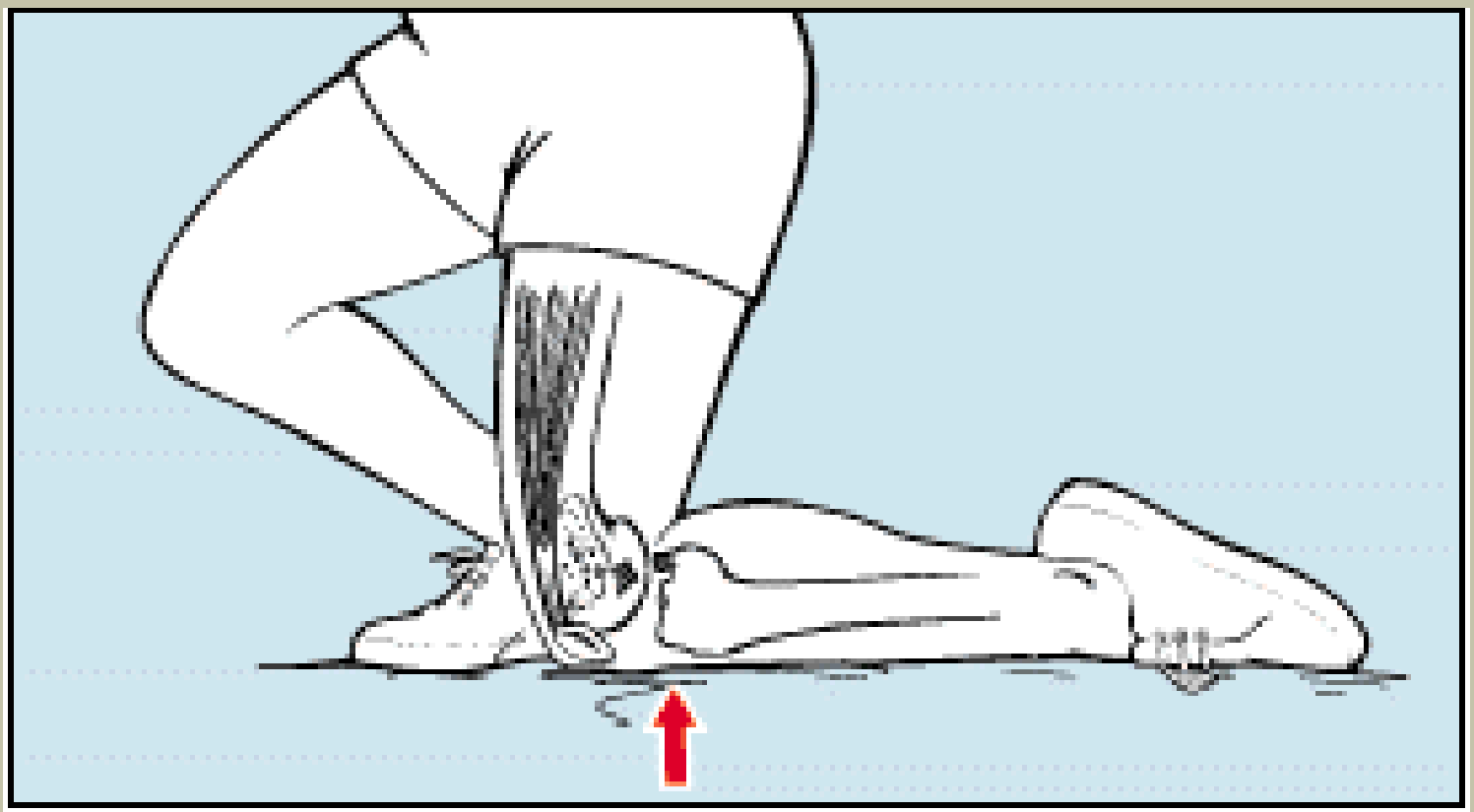

Figure 1. One of the mechanisms of injury for a posterior cruciate ligament (PCL) tear is a fall onto a flexed knee with the foot plantar flexed, which applies posterior force to the proximal tibia.

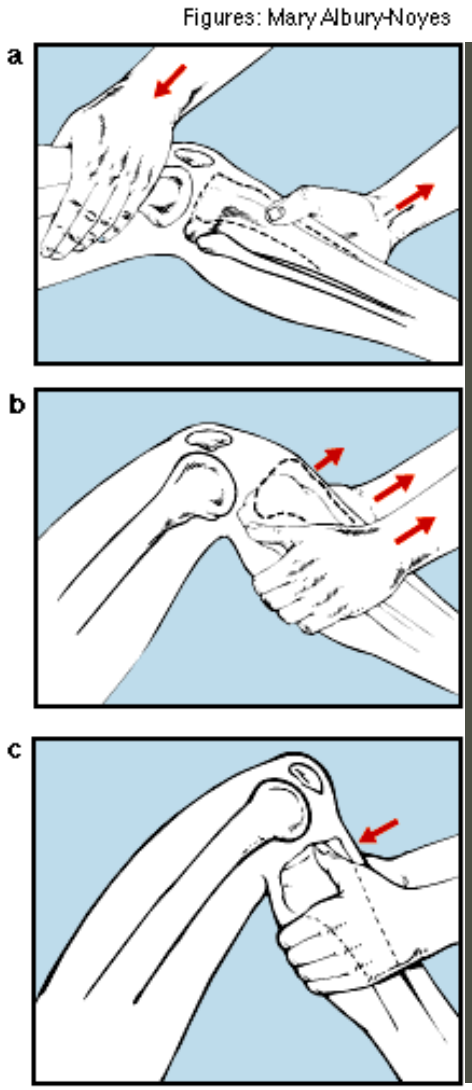

Sliding of the tibia with respect to the femur, a condition refered to as the *drawer sign*, is an indication of the integrity of the cruciate ligaments.

The anterior drawer sign is tibial displacement beneath the femur in an anterior direction and reflects the integrity of the **anterior cruciate**.

The posterior drawer sign is posterior displacement and reflects the integrity of the **posterior cruciate**.

The PCL is shorter and stronger than the ACL

MENISCI

- Two on each of the tibia, loosely attached, thicker to the outside.
- Functions:
  1. Stabilization
  2. Shock absorption
  3. Lubrication

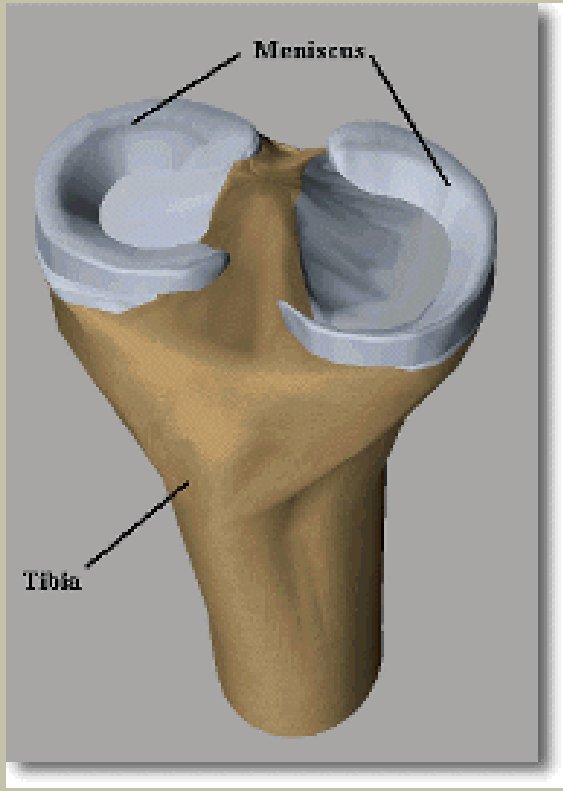

MEDIAL MENISCUS

- Broader in front, most frequently injured
- The medial meniscus is “C” shaped.
- Attached to the medial collateral ligament.

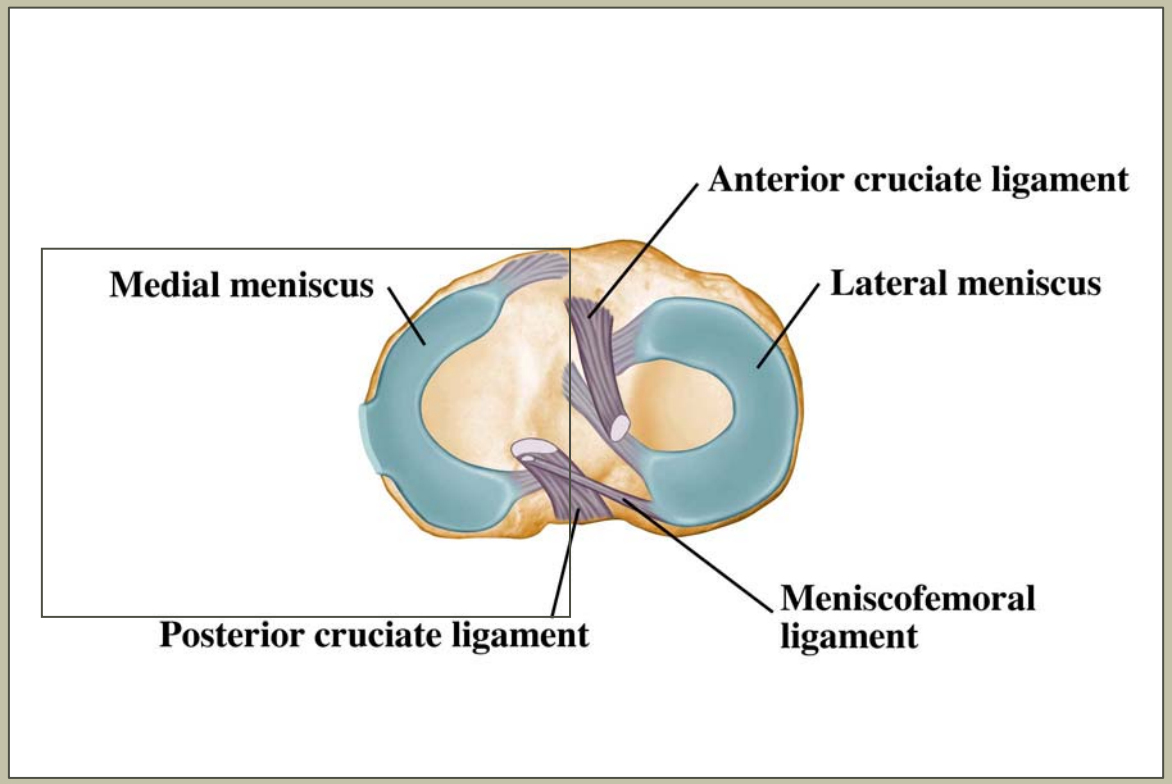

MEDIAL MENISCUS

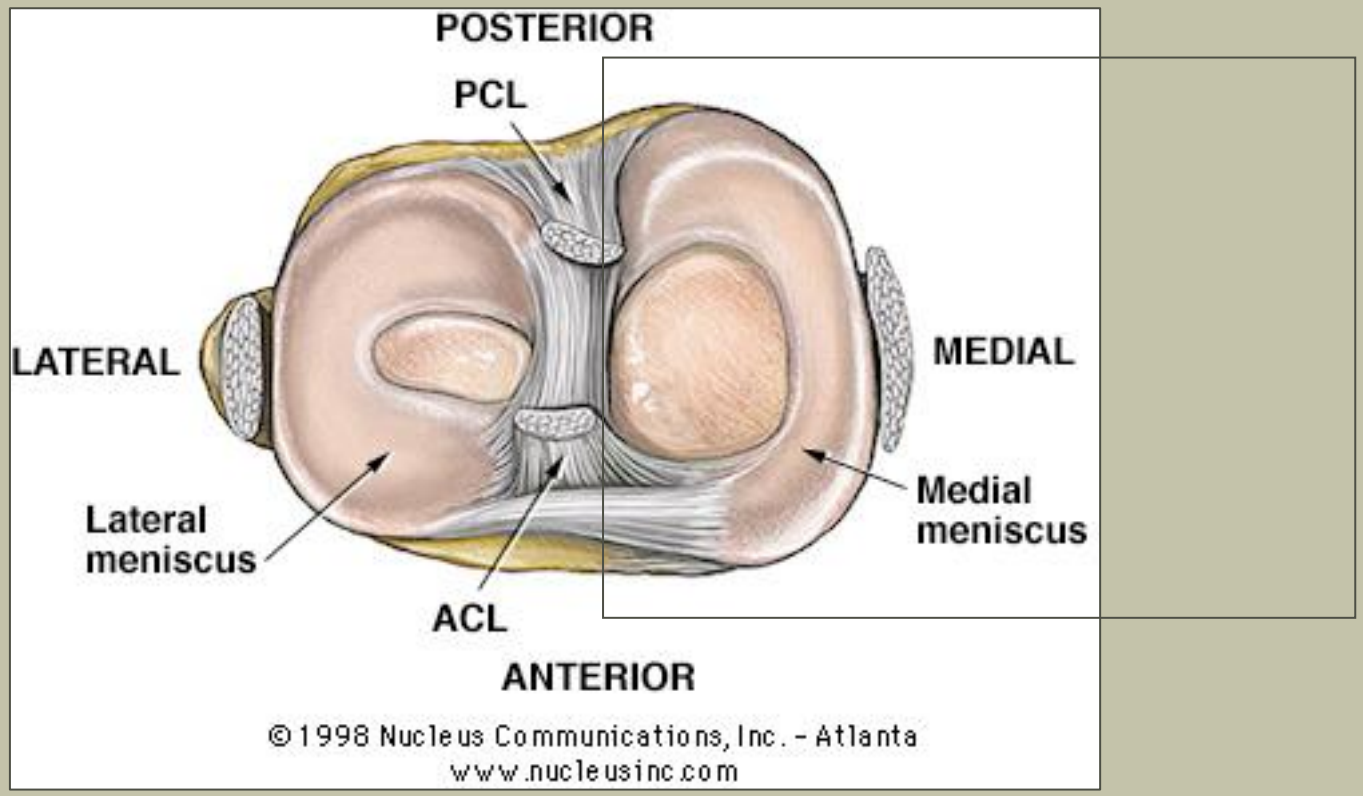

www.fisiokinesiterapia.biz

LATERAL MENISCUS

- The lateral meniscus is “O” shaped.
- Not attached to the lateral collateral ligament.

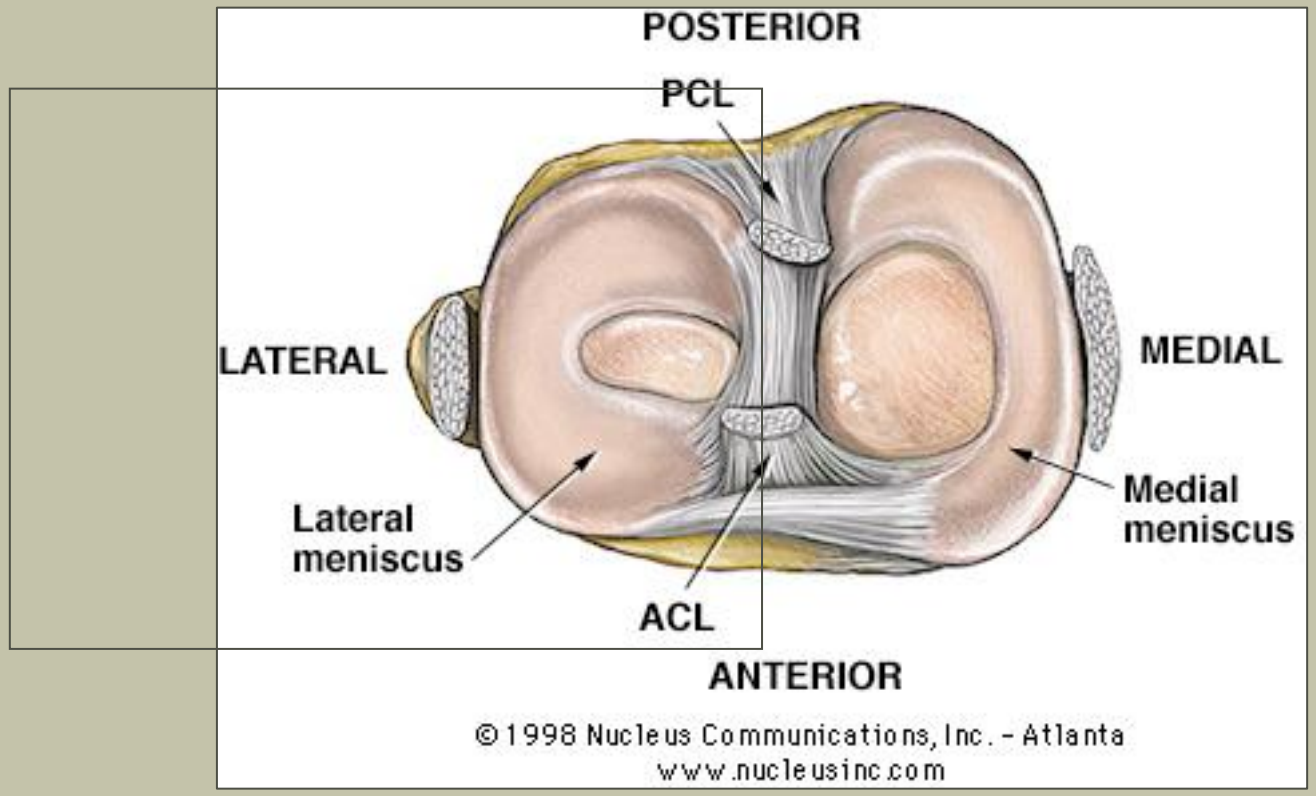

LATERAL MENISCUS

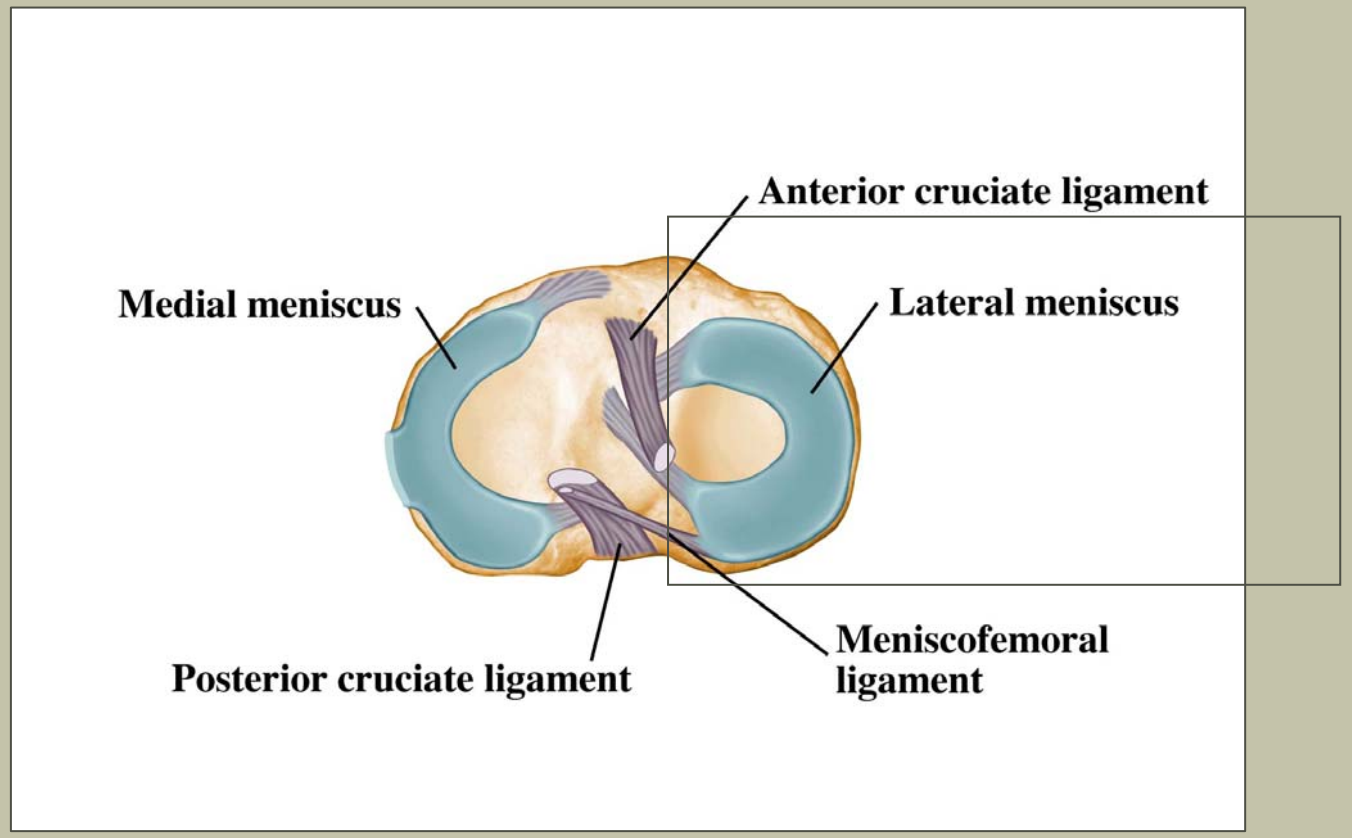

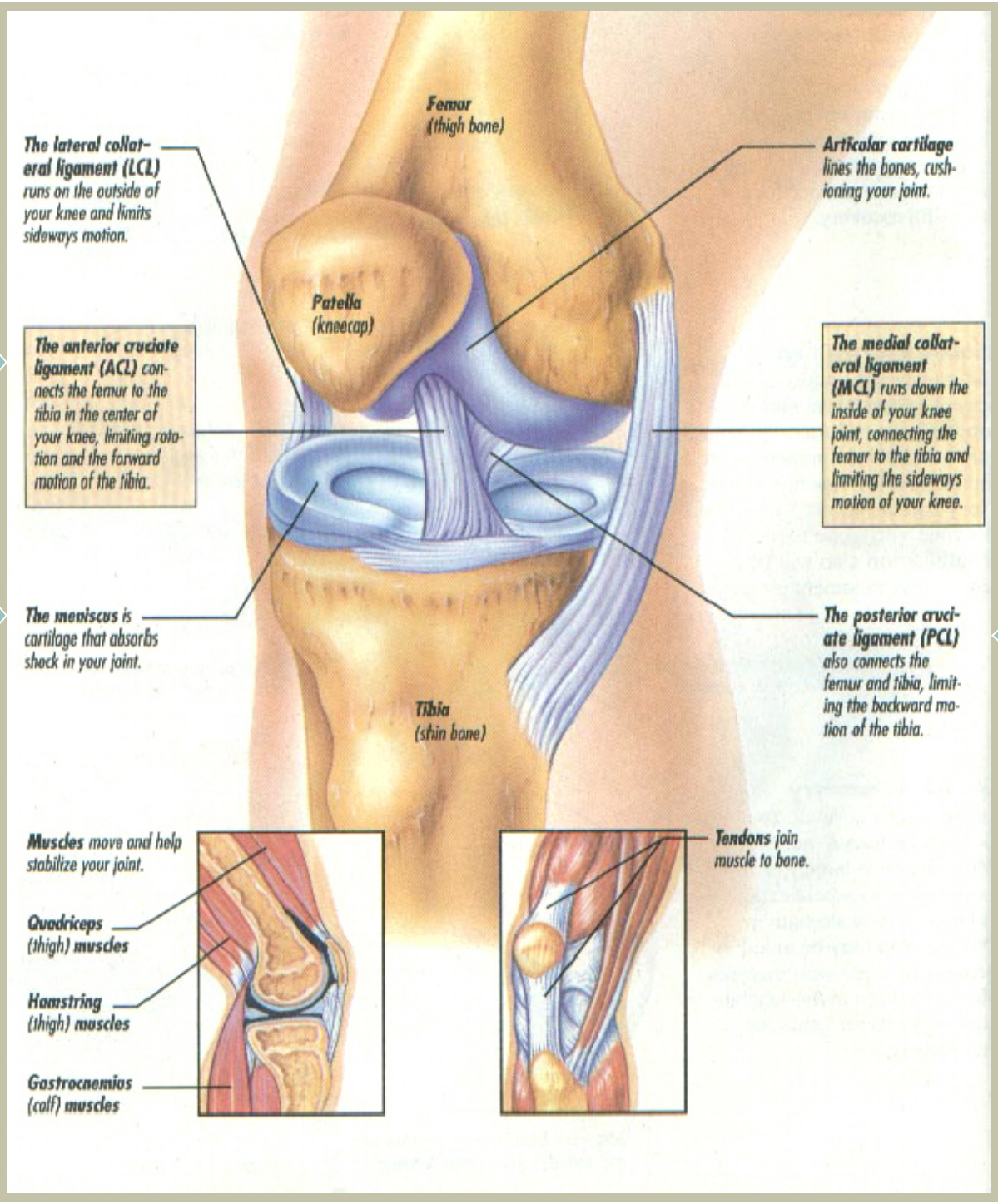
Femur
(thigh bone)
The lateral collateral ligament (LCL) runs on the outside of your knee and limits sideways motion.
Articular cartilage lines the bones, cushioning your joint.
Patella
(kneecap)
The anterior cruciate ligament (ACL) connects the femur to the tibia in the center of your knee, limiting rotation and the forward motion of the tibia.
The medial collateral ligament (MCL) runs down the inside of your knee joint, connecting the femur to the tibia and limiting the sideways motion of your knee.
The meniscus is cartilage that absorbs shock in your joint.
The posterior cruciate ligament (PCL) also connects the femur and tibia, limiting the backward motion of the tibia.
Tibia
(shin bone)
Muscles move and help stabilize your joint.
Quadriceps (thigh) muscles
Hamstring (thigh) muscles
Gastrocnemius (calf) muscles
Tendons join muscle to bone.

Movements of the Knee

Flexion



Extension

Actions of the Knee

- Function of the knee
- Flexion
- Extension

MECHANICAL APPLICATIONS TO THE KNEE

Mechanical Advantage from the Patella

- The patella moves the insertion of the quadriceps muscles further down the tibia.
- This increases the folcrum of the quads
- A longer folcrum increases the leverage of the quads making them a strong muscle group

- No patella: Folcrum ^—F————R.
- Patella: Folcrum ^——F——R.

Patellar ligament

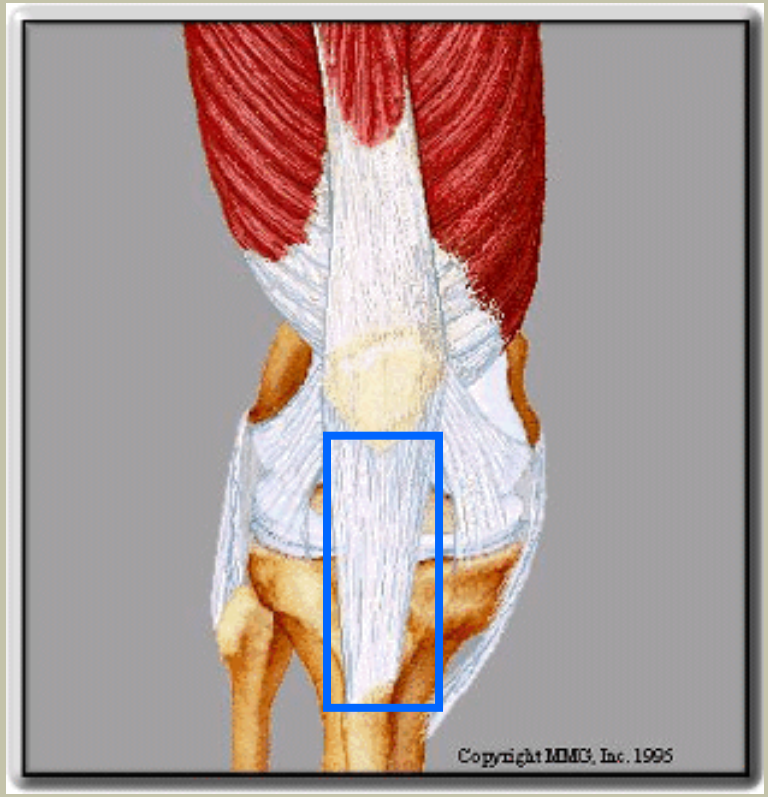

What landmark of the tibia does the patella tendon insert on?

Q-Angle.

- The deviation between the line of pull of the rectus femoris and the patellar ligament.
- It is usually measured from the anterior superior iliac spine and the center of the patella.
- A Q-angle of 10° is considered normal.
- Angles greater than this can result in lateral patellar dislocations when contractions of the quadriceps reduces the angle.

Figure: Mary Albury-Noyes

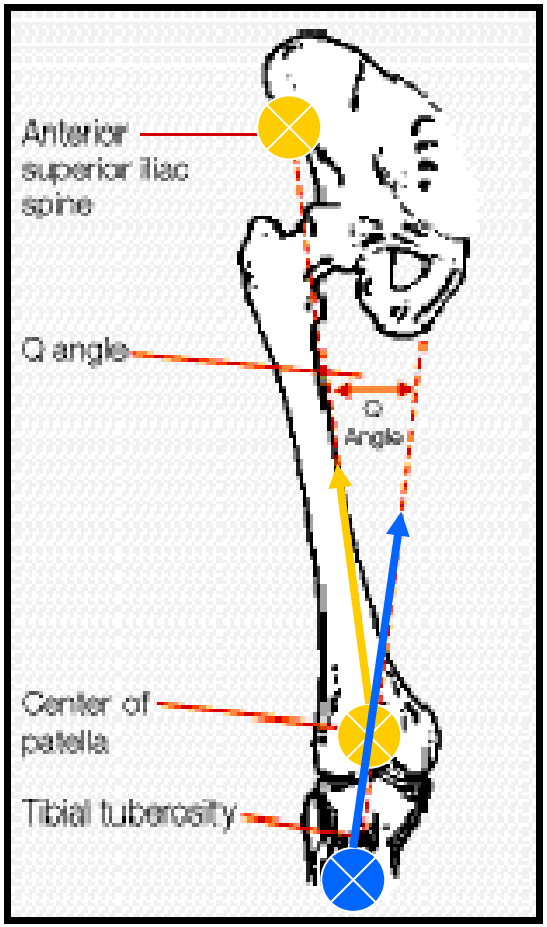

Figure 2. Anatomic landmarks for establishing the quadriceps angle (Q angle). There is no apparent relationship between Q-angle and ACL injury.

Q Angle

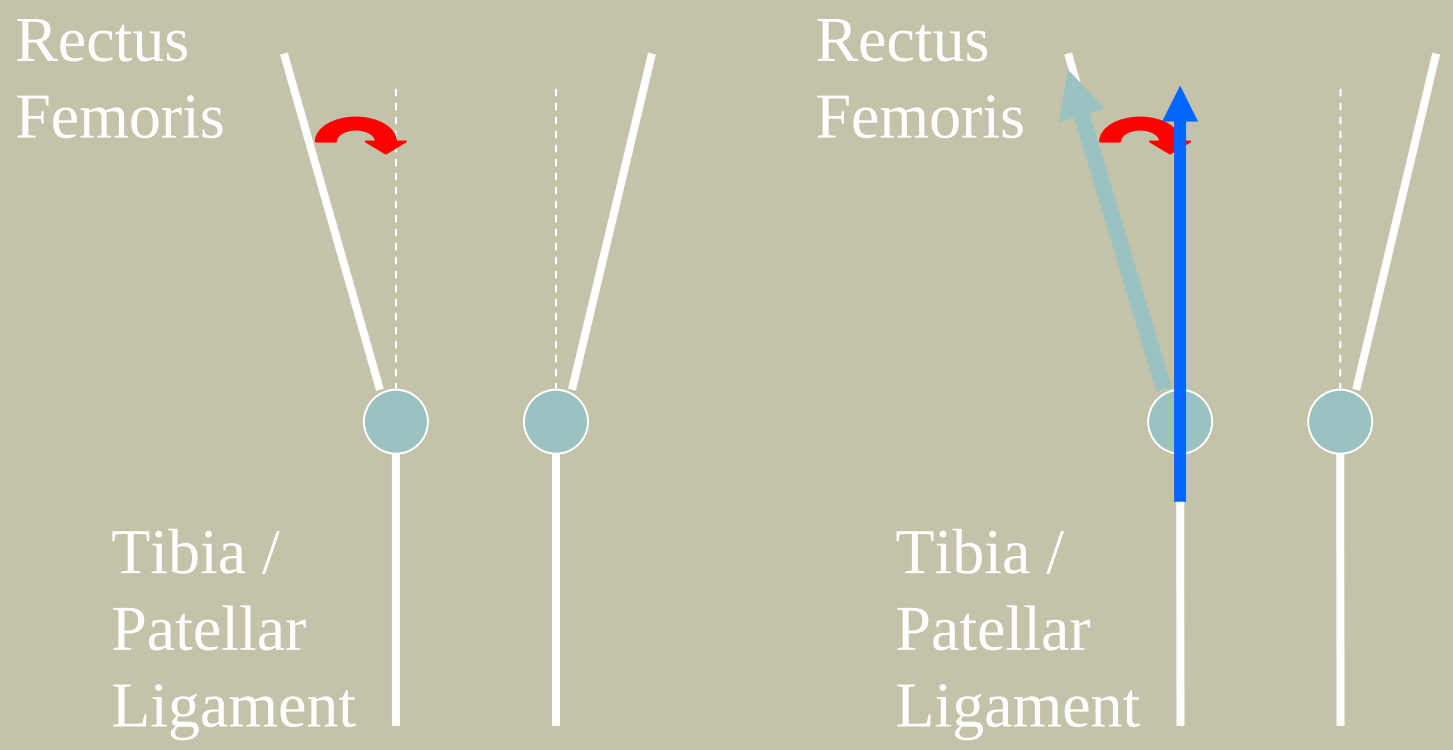

www.fisiokinesiterapia.biz