Human Anatomy

Brain and Cranial Nerves

Brain and Cranial Nerves

- An adult brain weighs between 1.35 and 1.4 kilograms (kg) (around 3 pounds) and has a volume of about 1200 cubic centimeters (cc).
- Brain size is not directly correlated with intelligence
- It is not the physical size of the brain that determines intelligence—it is the number of active synapses.

The Brain's 4 Major Regions

- Cerebrum, the diencephalon, the brainstem, and the cerebellum.
- The cerebrum is divided into two halves, called the left and right cerebral hemispheres.
- Each hemisphere is subdivided into five functional areas called lobes.
- Outer surface of an adult brain exhibits folds called gyri (gyrus) and shallow depressions between those folds called sulci (sulcus).
- The brain is associated with 12 pairs of cranial nerves.

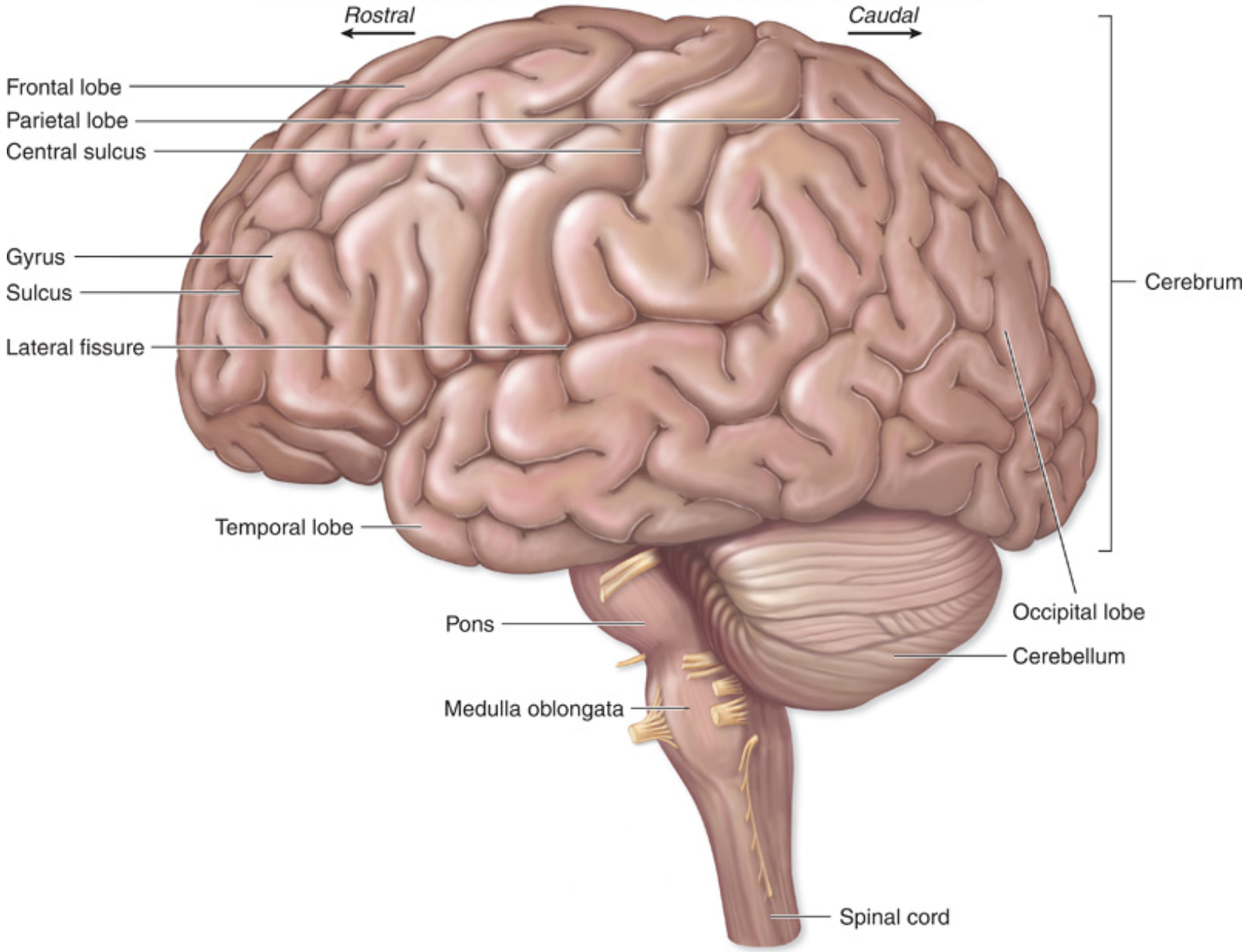

(a) Left lateral view

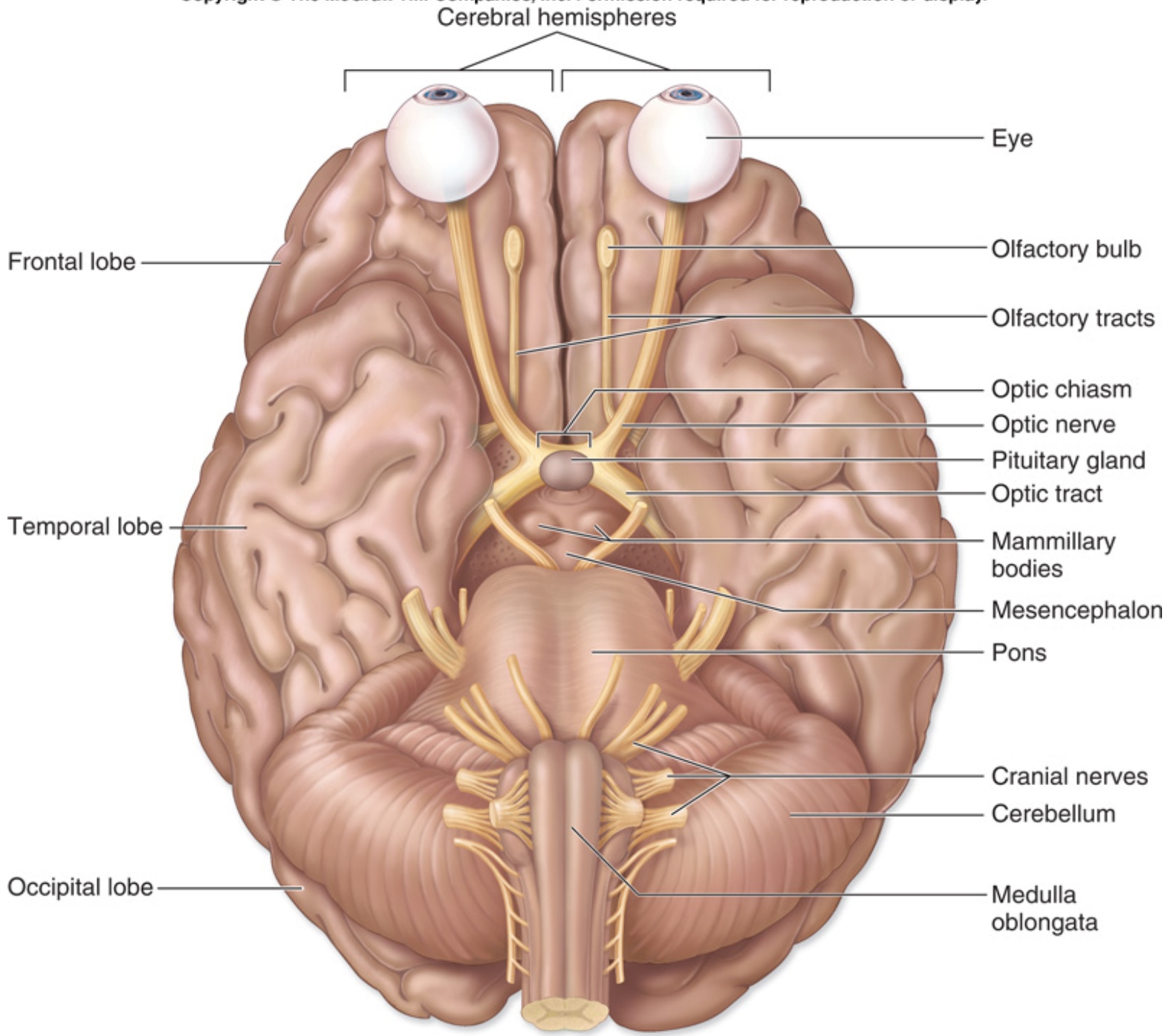

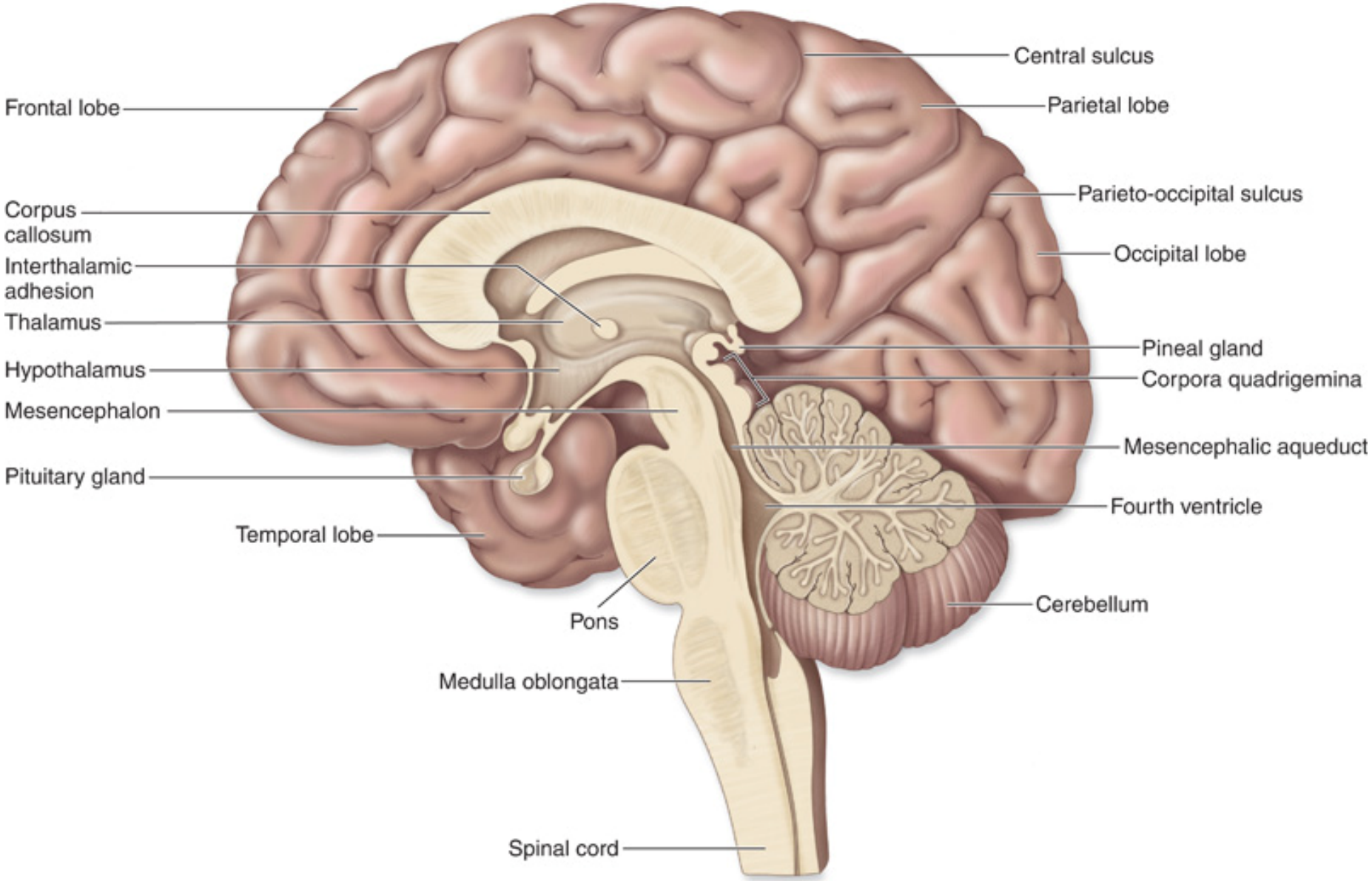

The Brain's 4 Major Regions

- Prosencephalon (forebrain)
  - Telencephalon: cerebrum
  - Diencephalon: epithalamus, thalamus,hypothalamus
- Mesencephalon (midbrain)
  - Mesencephalon: cerebral peduncles, colliculi
- Rhombencephalon (hindbrain)
  - Metencephalon: pons, cerebellum
  - Myelencephalon: medulla oblongata

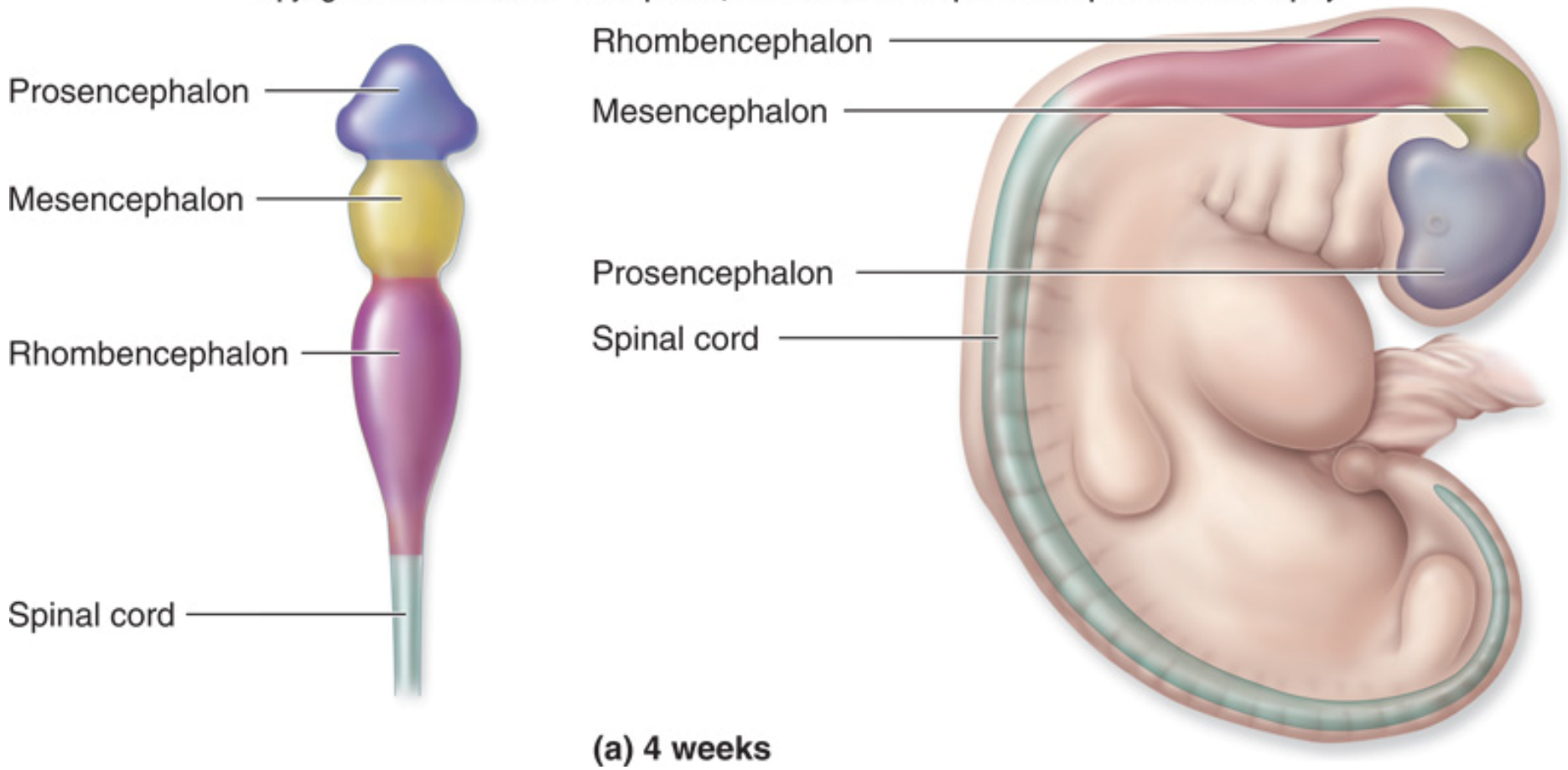

(a) 4 weeks

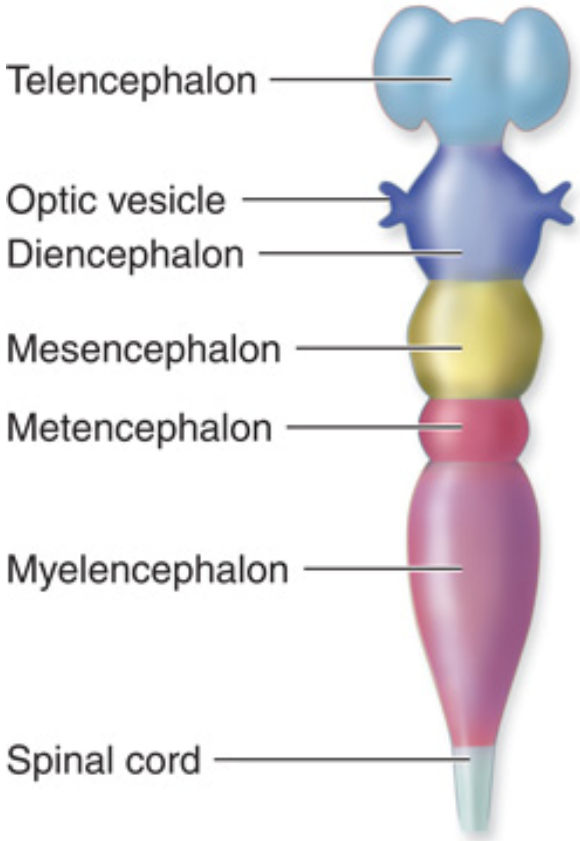

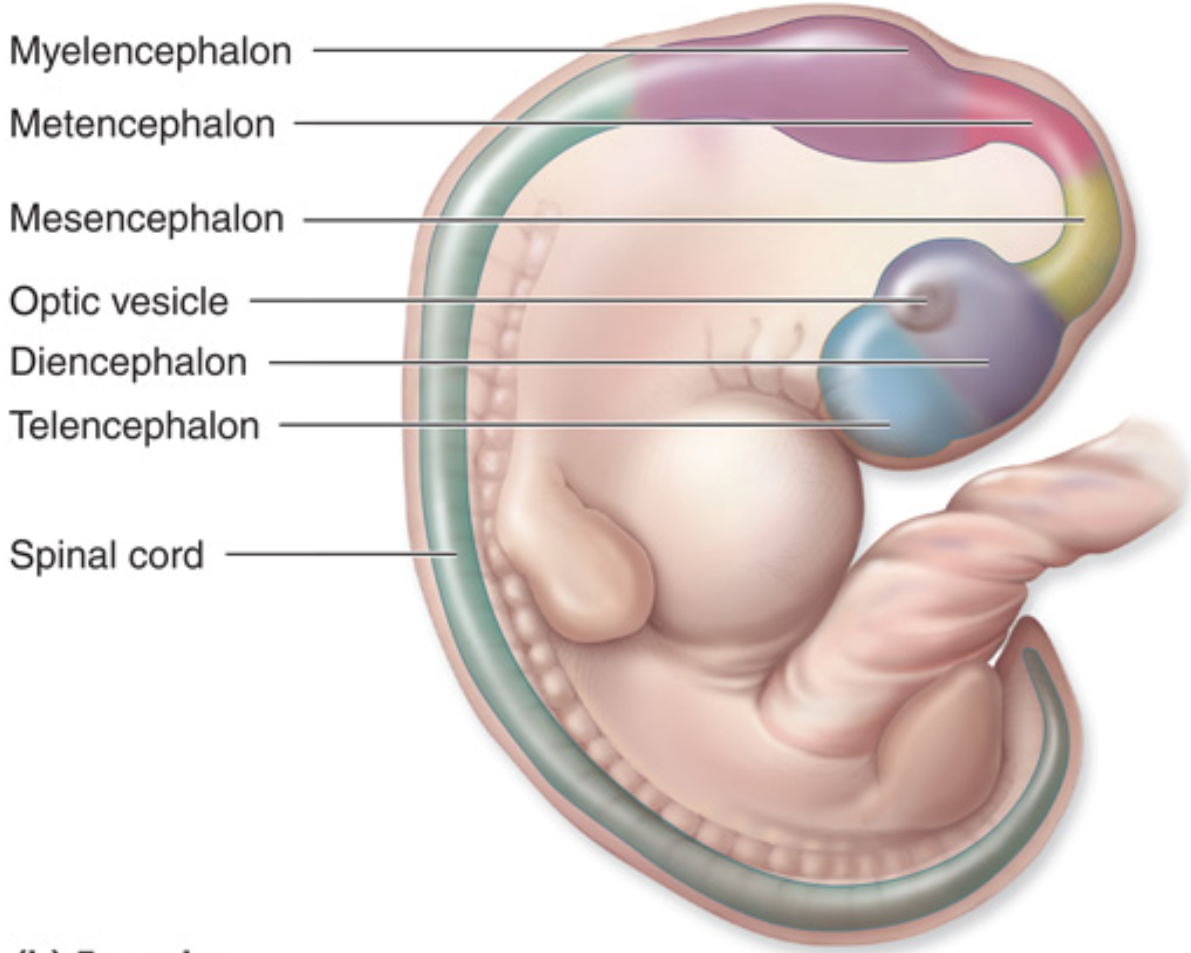

(b) 5 weeks

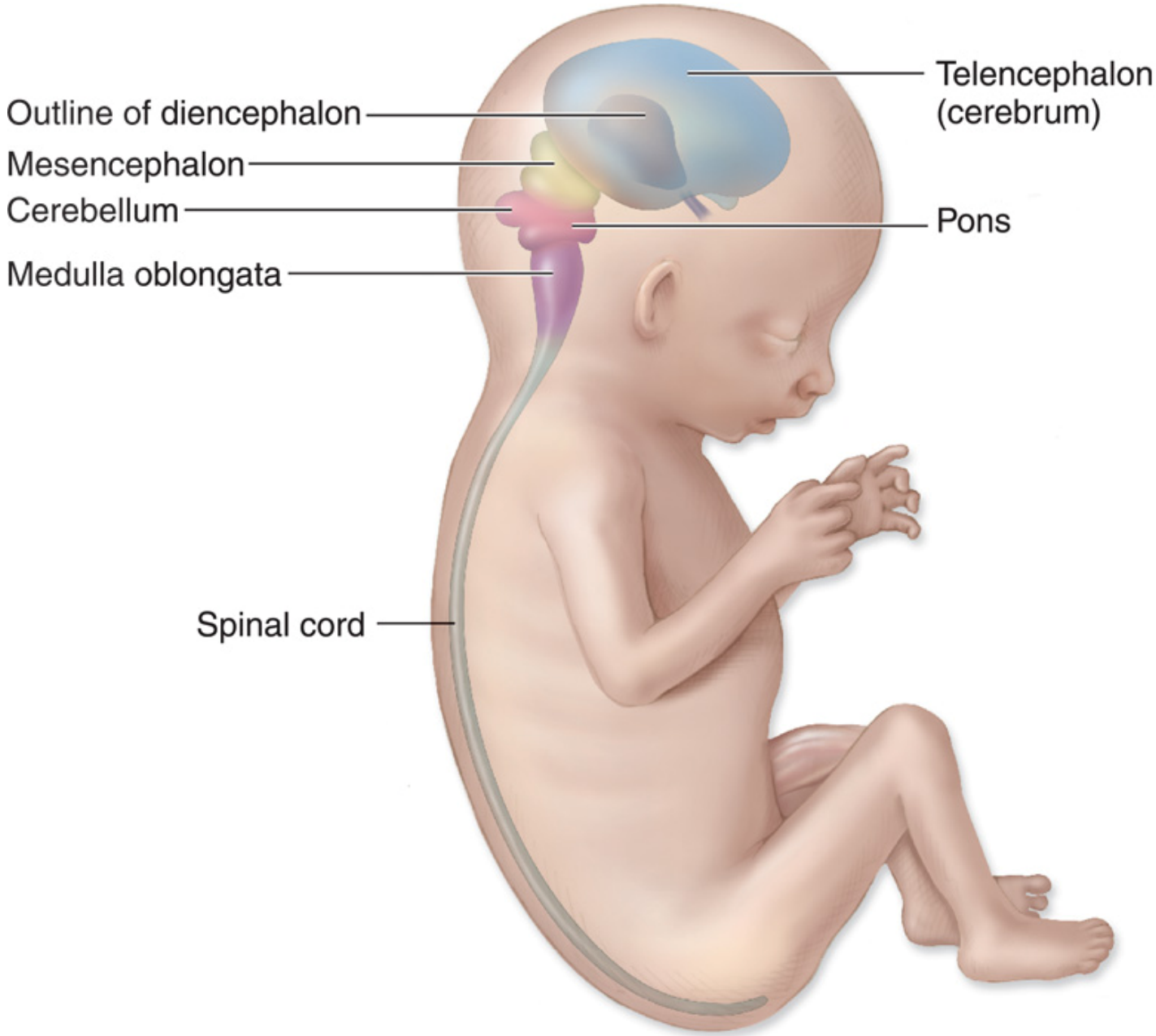

(c) 13 weeks

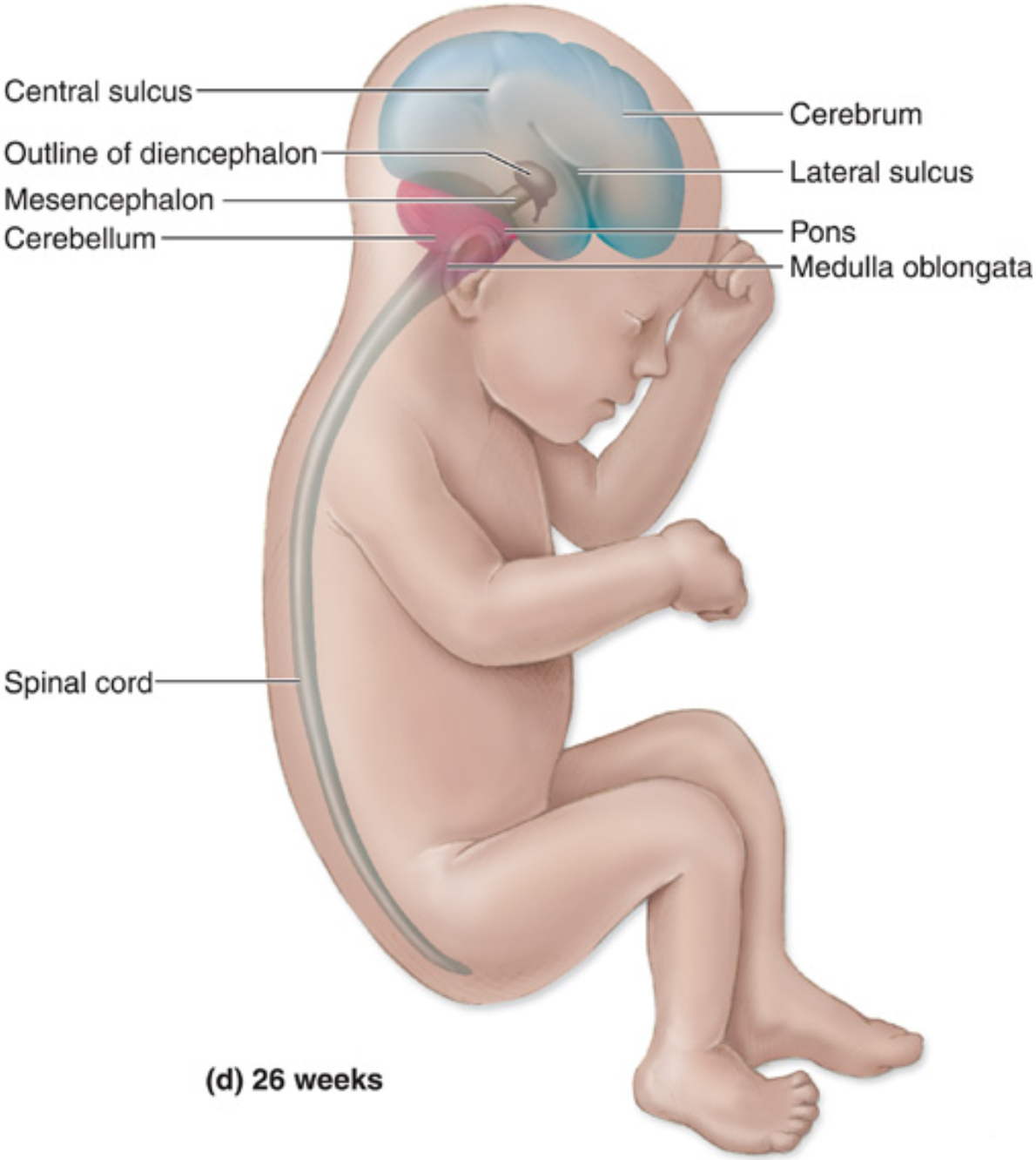

(d) 26 weeks

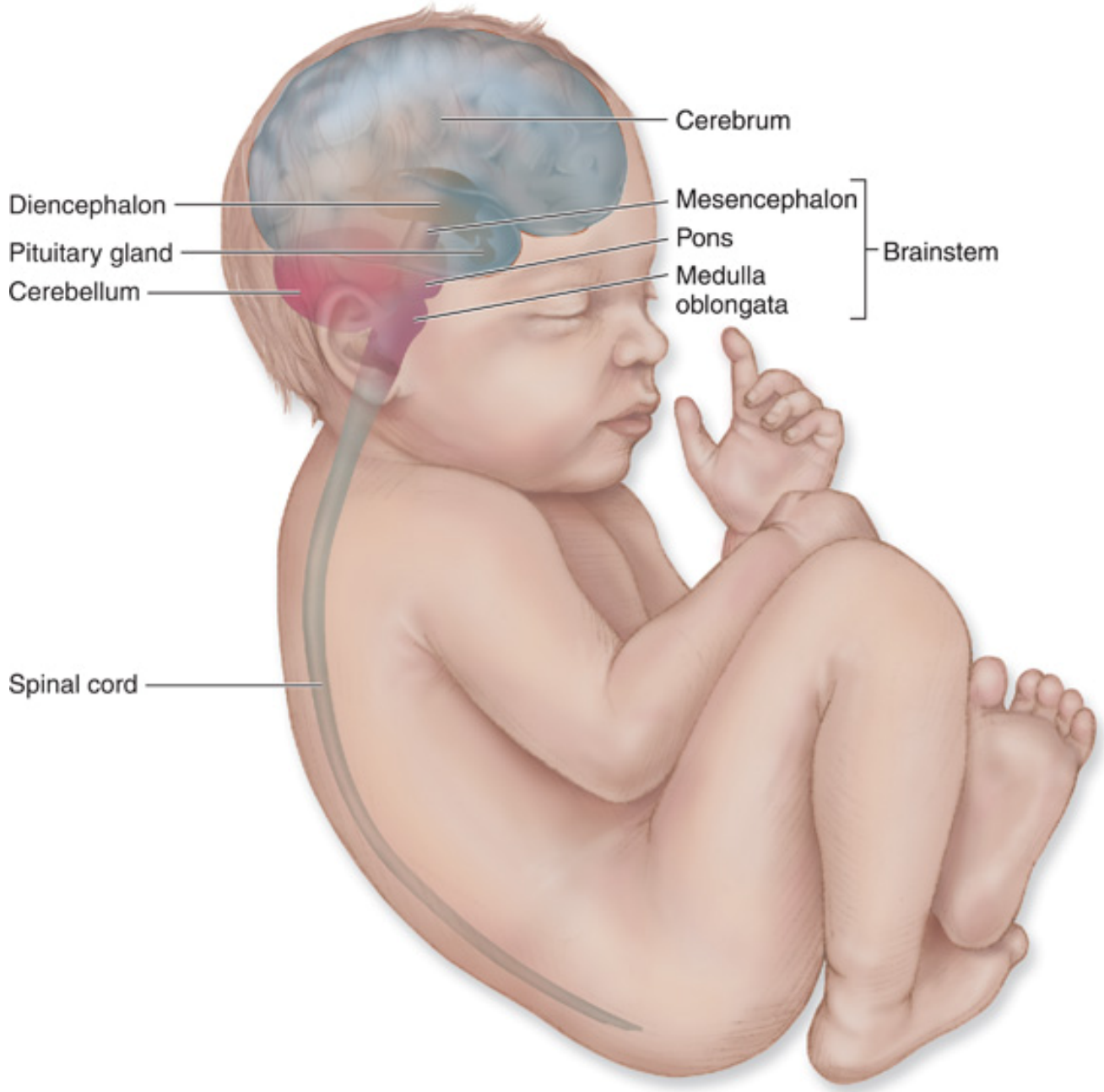

(e) Birth

Organization of Brain Tissue

- Gray matter:
  - motor neuron and interneuron cell bodies, dendrites, axon terminals
  - unmyelinated axons.
- White matter:
  - composed primarily of myelinated axons.
- During brain development, an outer, superficial region of gray matter forms from migrating peripheral neurons.
- External sheets of gray matter, called the cortex, cover the surface of most of the adult brain (the cerebrum and the cerebellum).

Organization of Brain Tissue

- White matter lies deep to the gray matter of the cortex.
- Within the masses of white matter:
  - discrete innermost clusters of gray matter called cerebral nuclei (or basal nuclei).
  - are oval, spherical, or sometimes irregularly shaped clusters of neuron cell bodies.

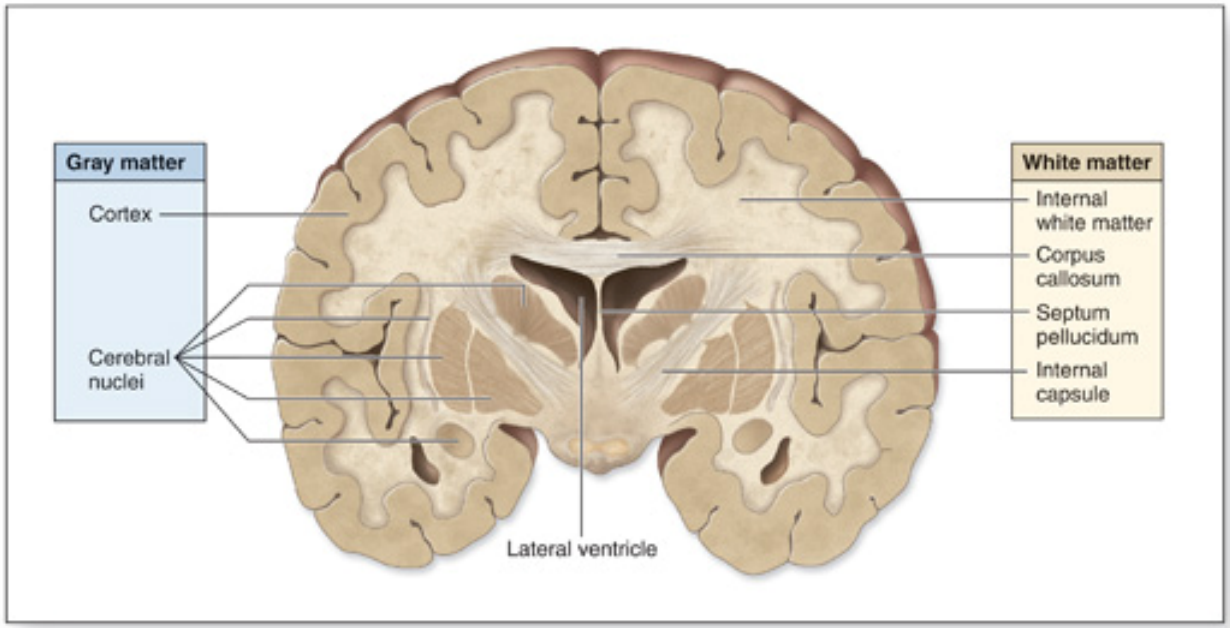

(a) Frontal section of cerebrum

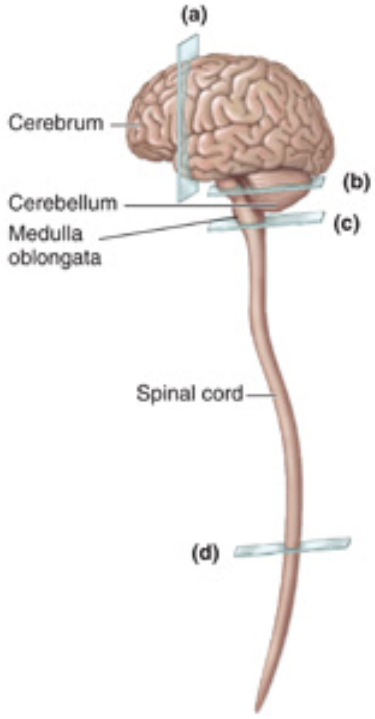

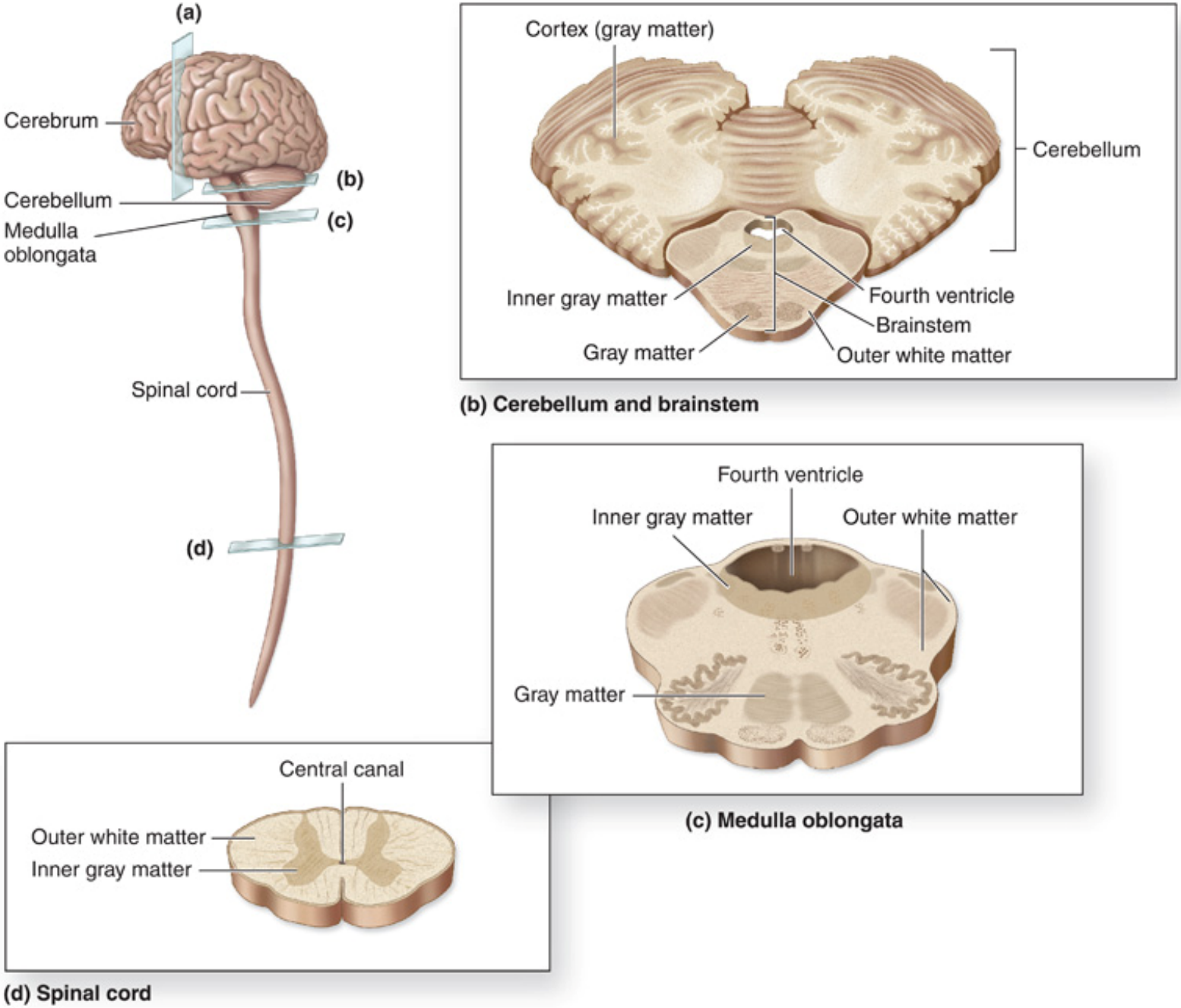

(b) Cerebellum and brainstem

(c) Medulla oblongata

(d) Spinal cord

Support and Protection of the Brain

- The brain is protected and isolated by multiple structures:
  - bony cranium
  - Meninges:
    - Protective connective tissue membranes
    - surround and partition portions of the brain.
  - Cerebrospinal fluid (CSF)
    - acts as a cushioning fluid.
  - Blood-brain barrier:
    - prevents entry of harmful materials from the bloodstream.

Cranial Meninges

- Three dense regular connective tissue layers:
  - separate the soft tissue of the brain from the bones of the cranium.
  - Enclose and protect blood vessels that supply the brain.
  - Contain and circulate cerebrospinal fluid.
  - Parts of the cranial meninges form some of the veins that drain blood from the brain.
- From superficial to deep, the cranial meninges are the dura mater, the arachnoid, and the pia mater.

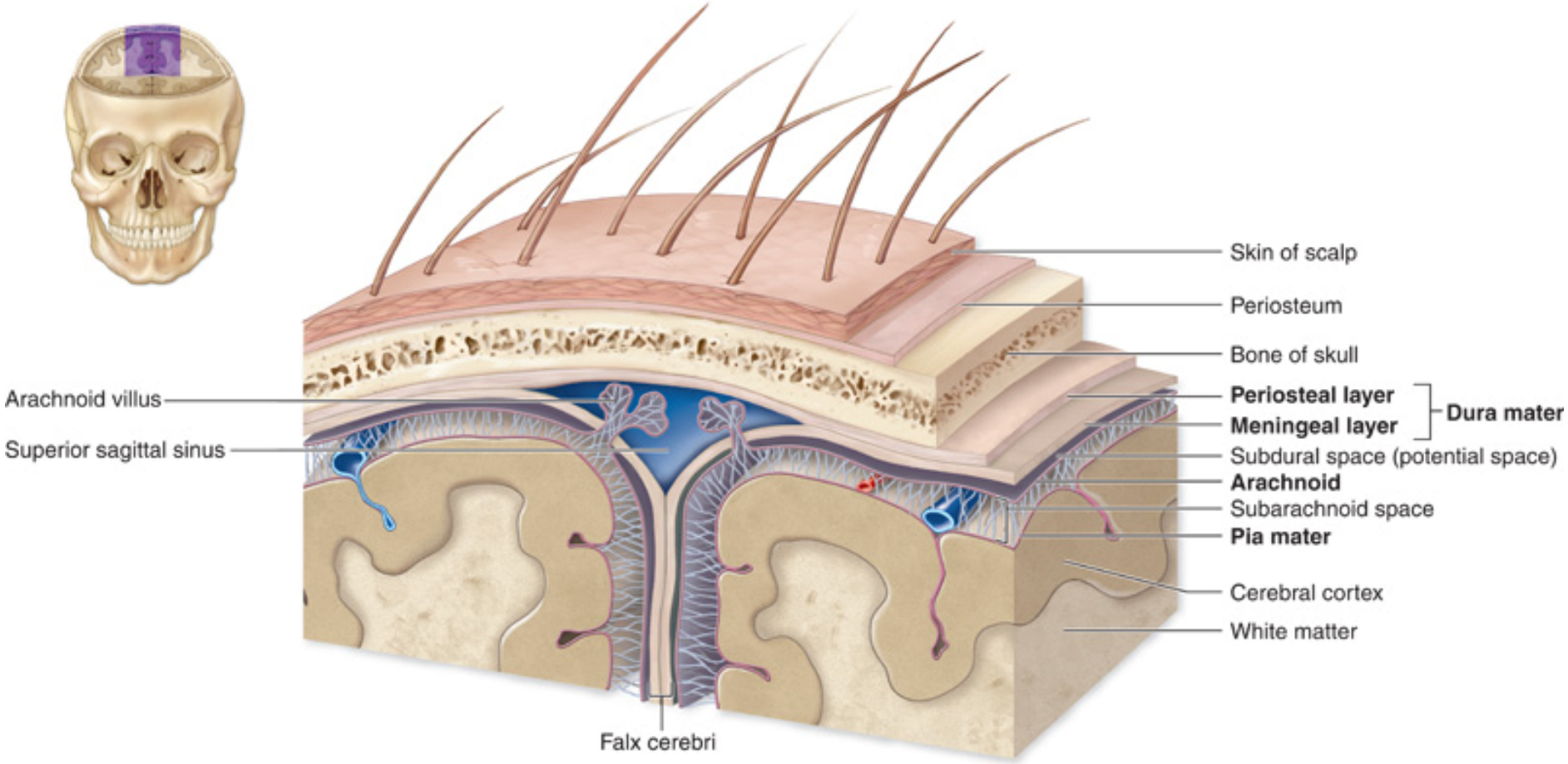

Dura Mater

- Tough membrane composed of two fibrous layers.
- Strongest of the meninges.
- Dura mater is composed of two layers.
  - periosteal layer, the more superficial layer, attaches to the periosteum of the cranial bones
  - meningeal layer lies deep to the periosteal layer
- The meningeal layer is usually fused to the periosteal layer
  - Exception: in specific areas where the two layers separate to form large, blood-filled spaces called dural venous sinuses.

Arachnoid

- Also called the arachnoid mater or the arachnoid membrane.
- Lies immediately internal to the dura mater.
- Partially composed of a delicate web of collagen and elastic fibers, termed the arachnoid trabeculae.
- Between the arachnoid and the overlying dura mater is the subdural space.
- Immediately deep to the arachnoid is the subarachnoid space.

Pia Mater

- The innermost of the cranial meninges.
- Thin layer of delicate connective tissue that tightly adheres to the brain and follows every contour of the brain surface.

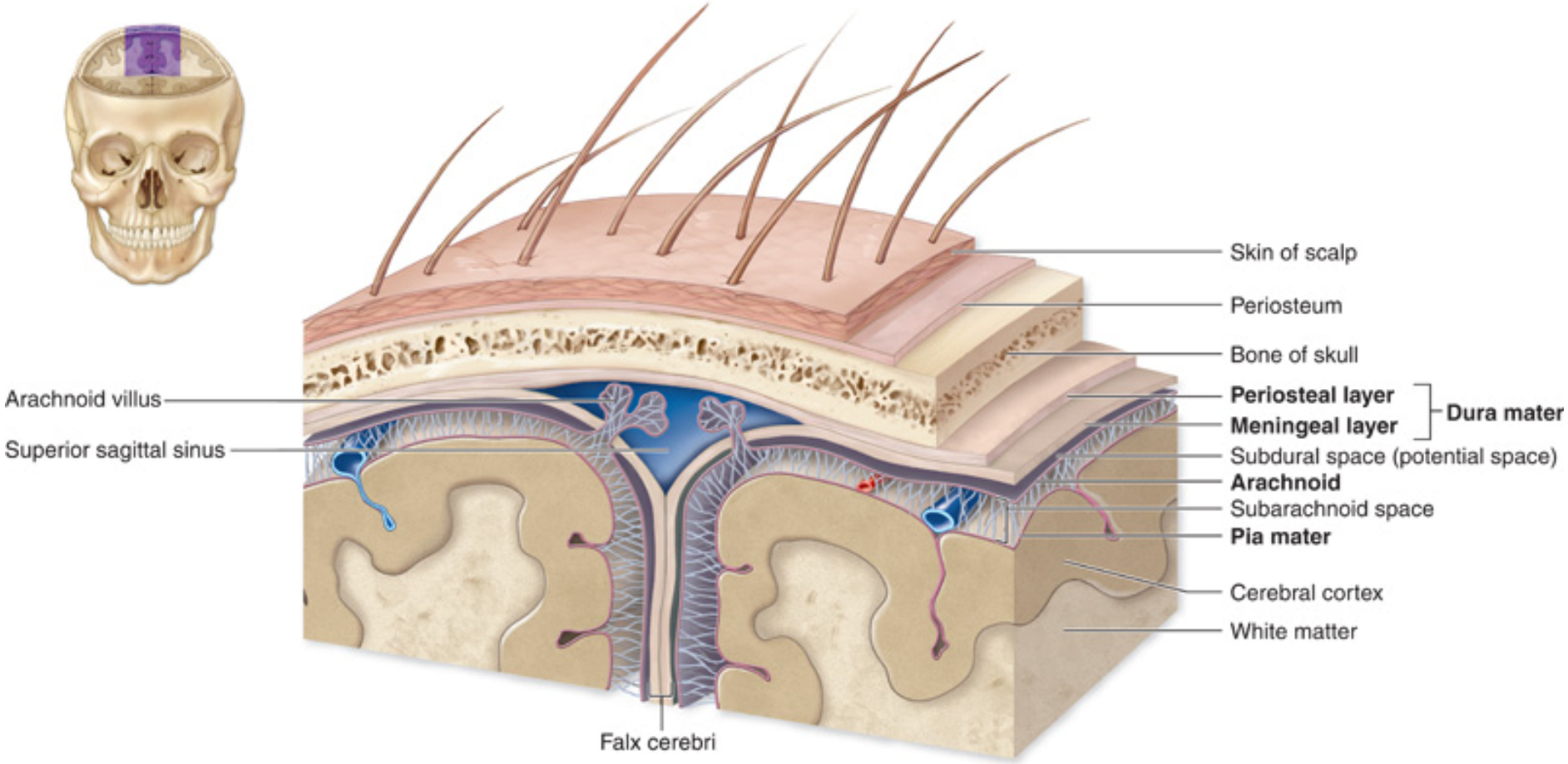

Cranial Dural Septa

- The meningeal layer of the dura mater extends as flat partitions (septa) deep into the cranial cavity;
  - at four locations
  - called cranial dural septa.
- Membranous partitions separate specific parts of the brain and provide additional stabilization and support to the entire brain.
  - falx cerebri
  - tentorium cerebelli
  - falx cerebelli
  - diaphragma sellae

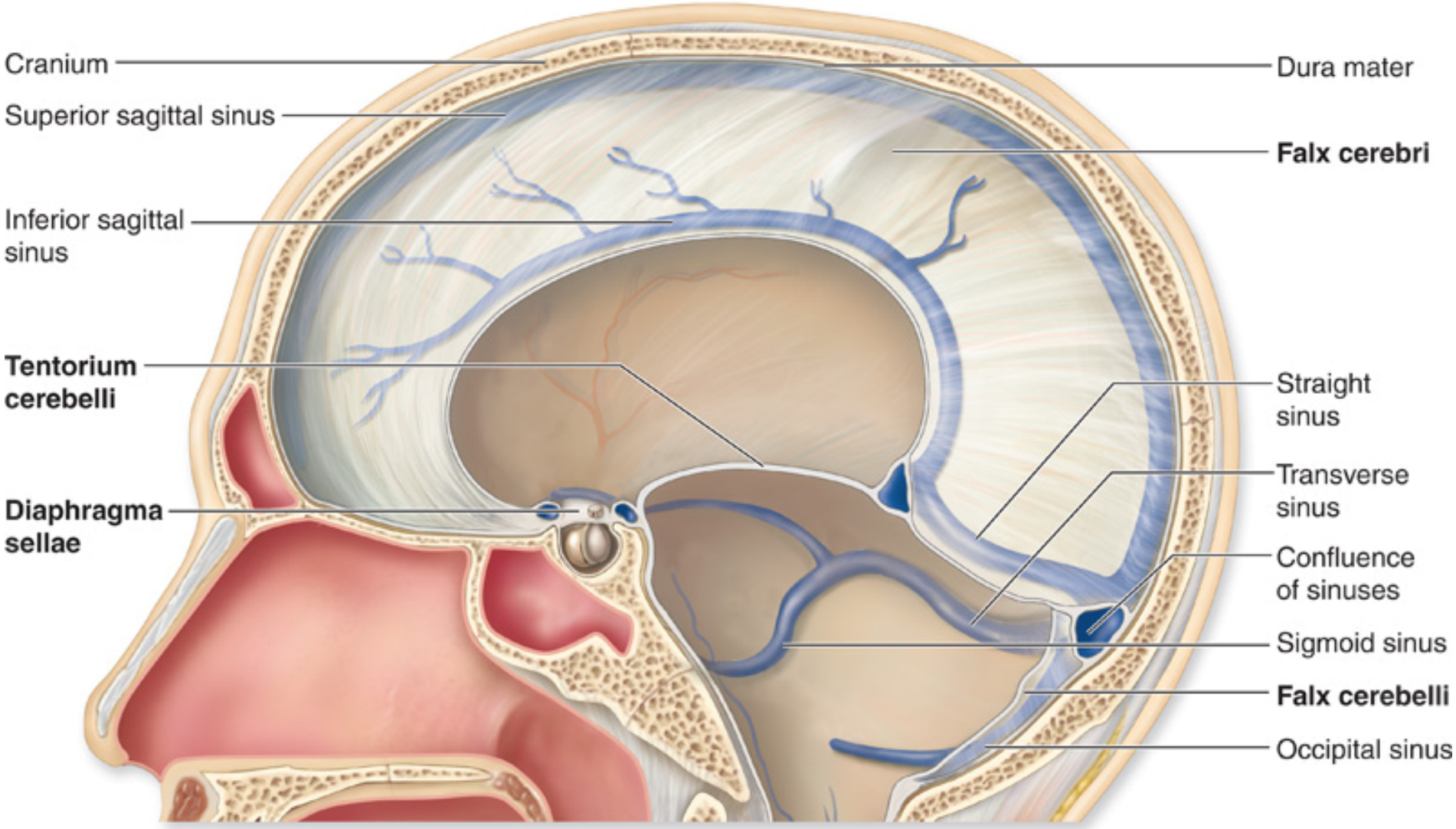

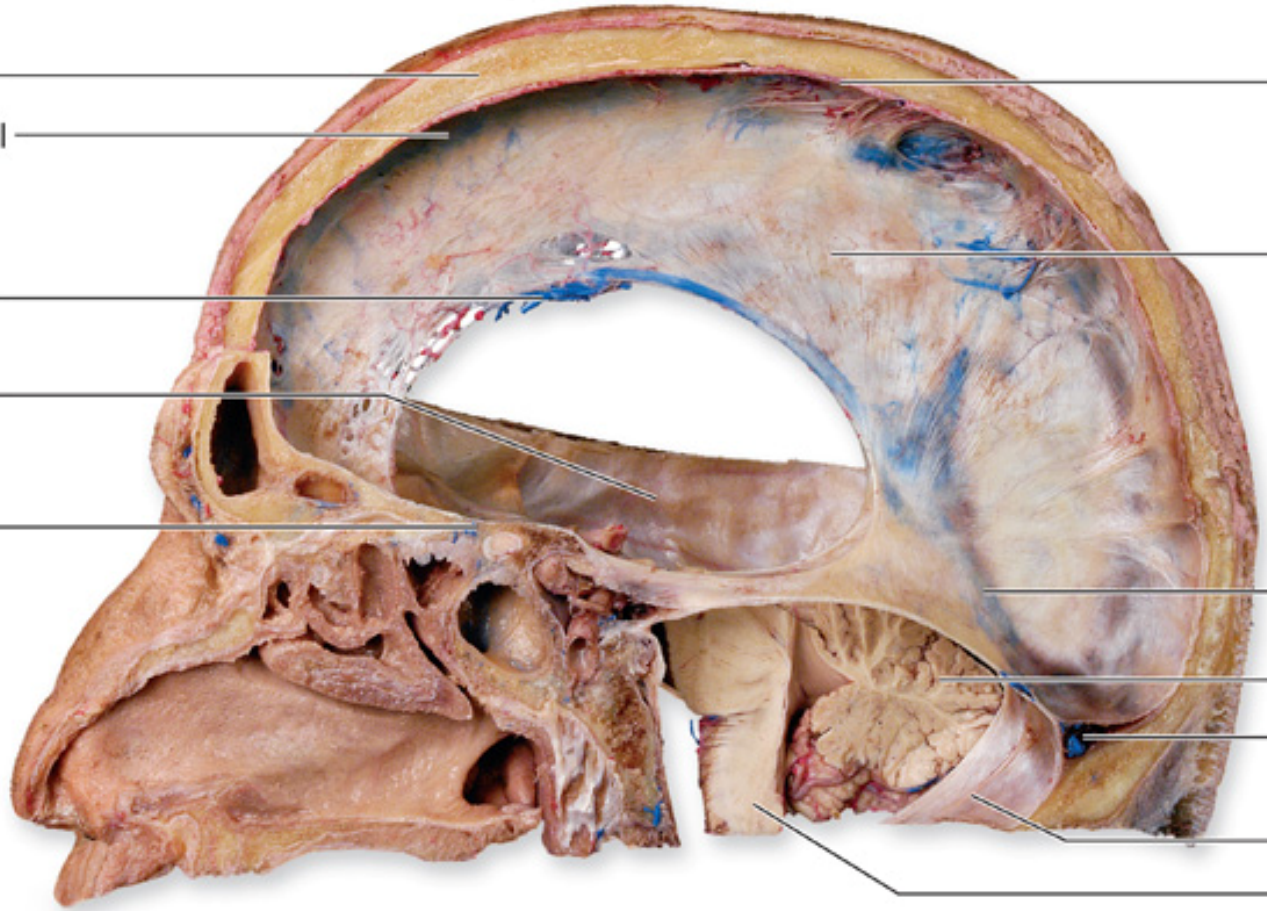

Midsagittal section

Brain Ventricles

- Cavities or expansions within the brain that are derived from the lumen (opening) of the embryonic neural tube.
- Continuous with one another as well as with the central canal of the spinal cord.
- Four ventricles in the brain.
  - two lateral ventricles are in the cerebrum, separated by a thin medial partition called the septum pellucidum
  - within the diencephalon is a smaller ventricle called the third ventricle
    - each lateral ventricle communicates with the third ventricle through an opening called the interventricular foramen
- The fourth ventricle is located within the pons and cerebellum.

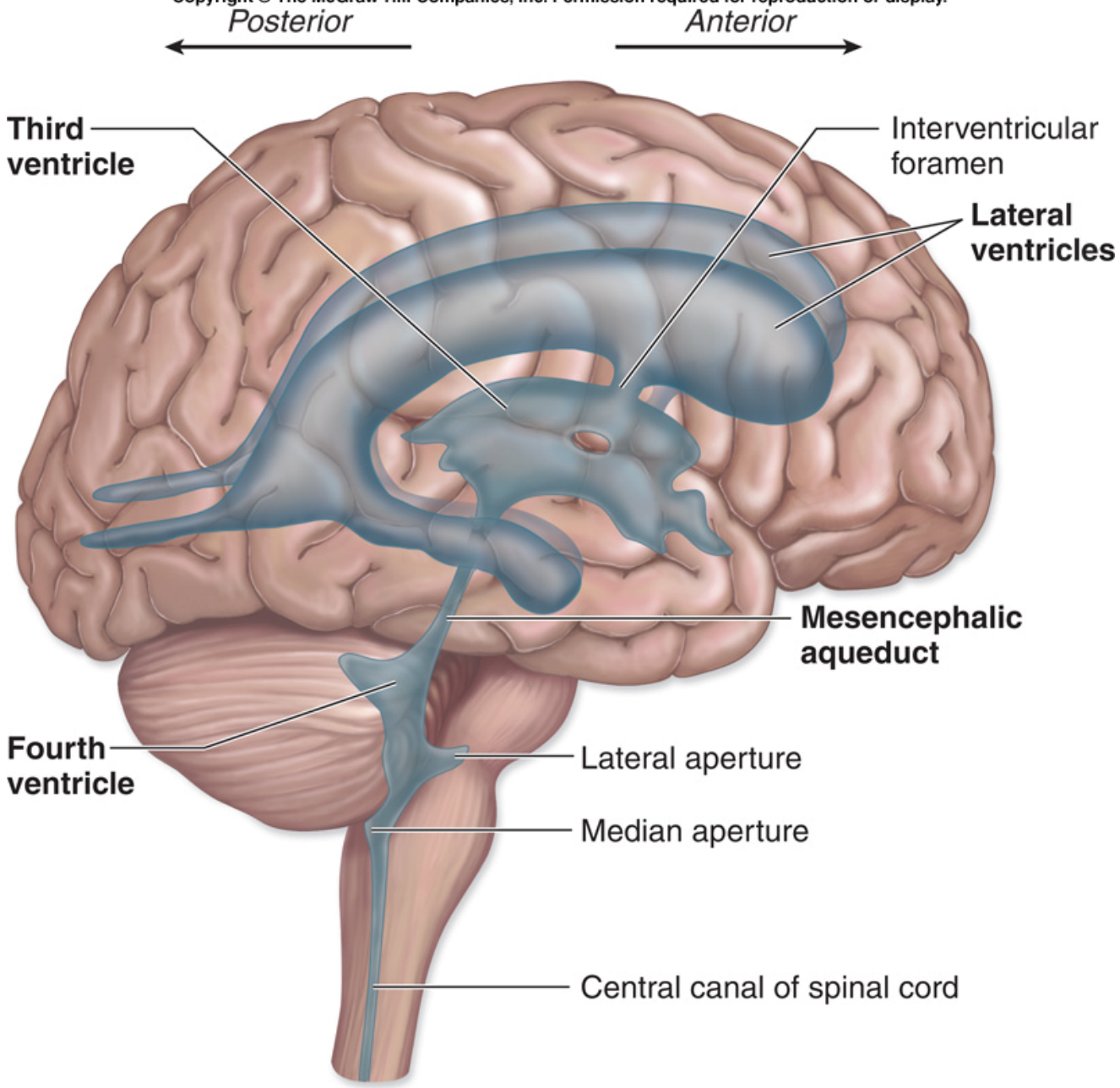

(a) Lateral view

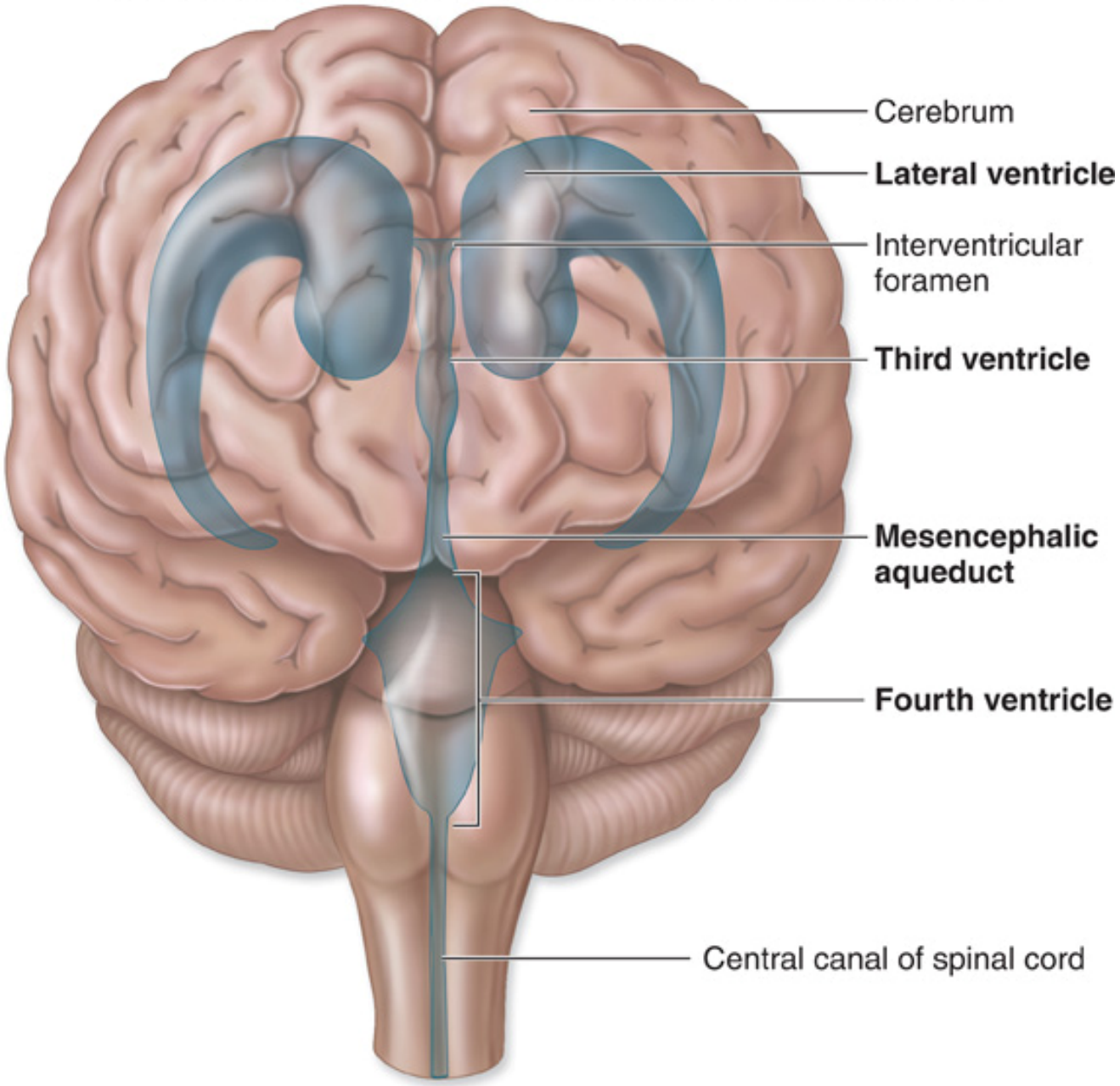

(b) Anterior view

Cerebrospinal Fluid

- A clear, colorless liquid that circulates in the ventricles and subarachnoid space.
- Bathes the exposed surfaces of the central nervous system and completely surrounds it.
- Performs several important functions.
  - buoyancy
  - protection
  - environmental stability
- Formed by the choroid plexus in each ventricle.
- Produced by secretion of a fluid from the ependymal cells that originate from the blood plasma.
- Is similar to blood plasma.

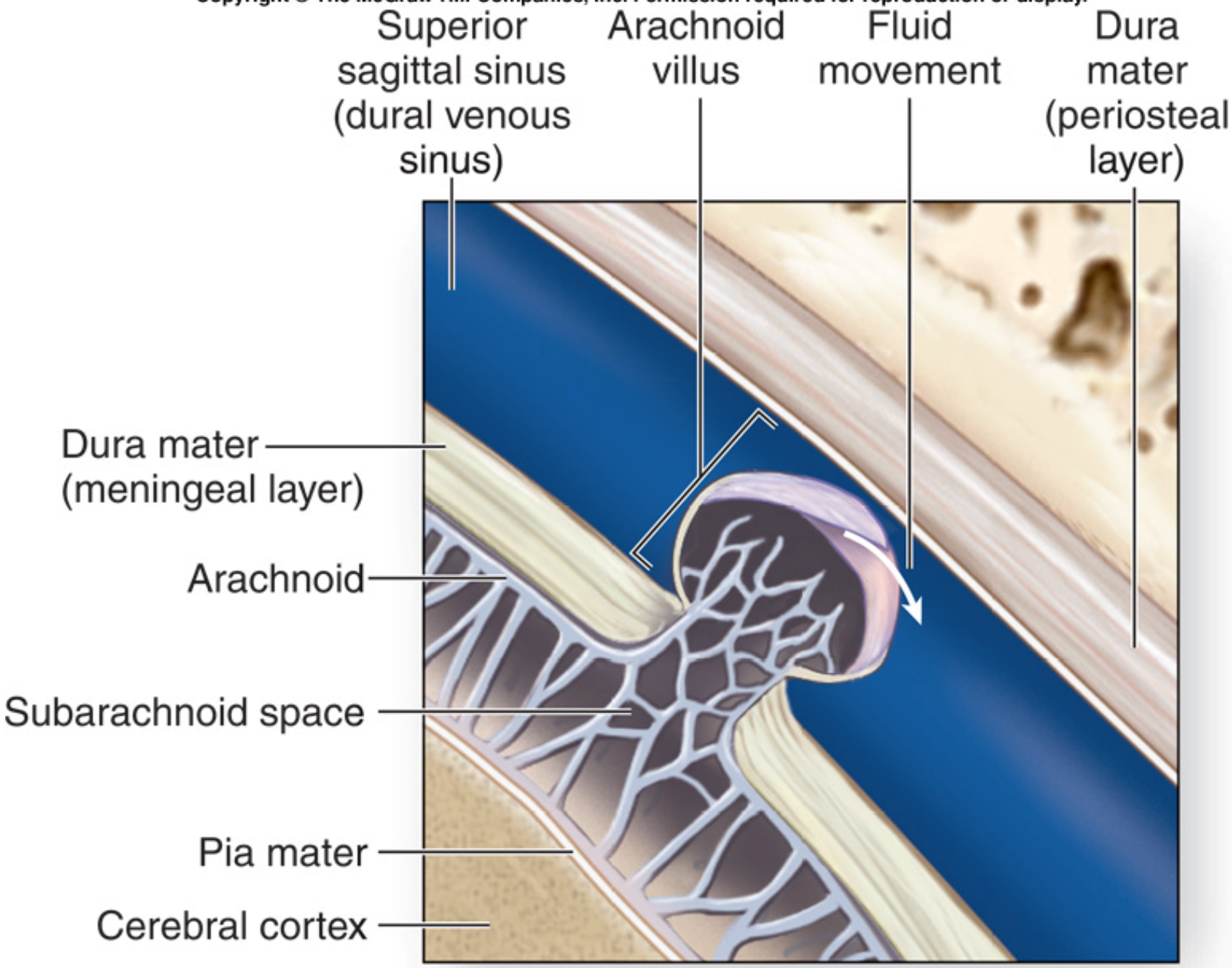

(b) Arachnoid villus

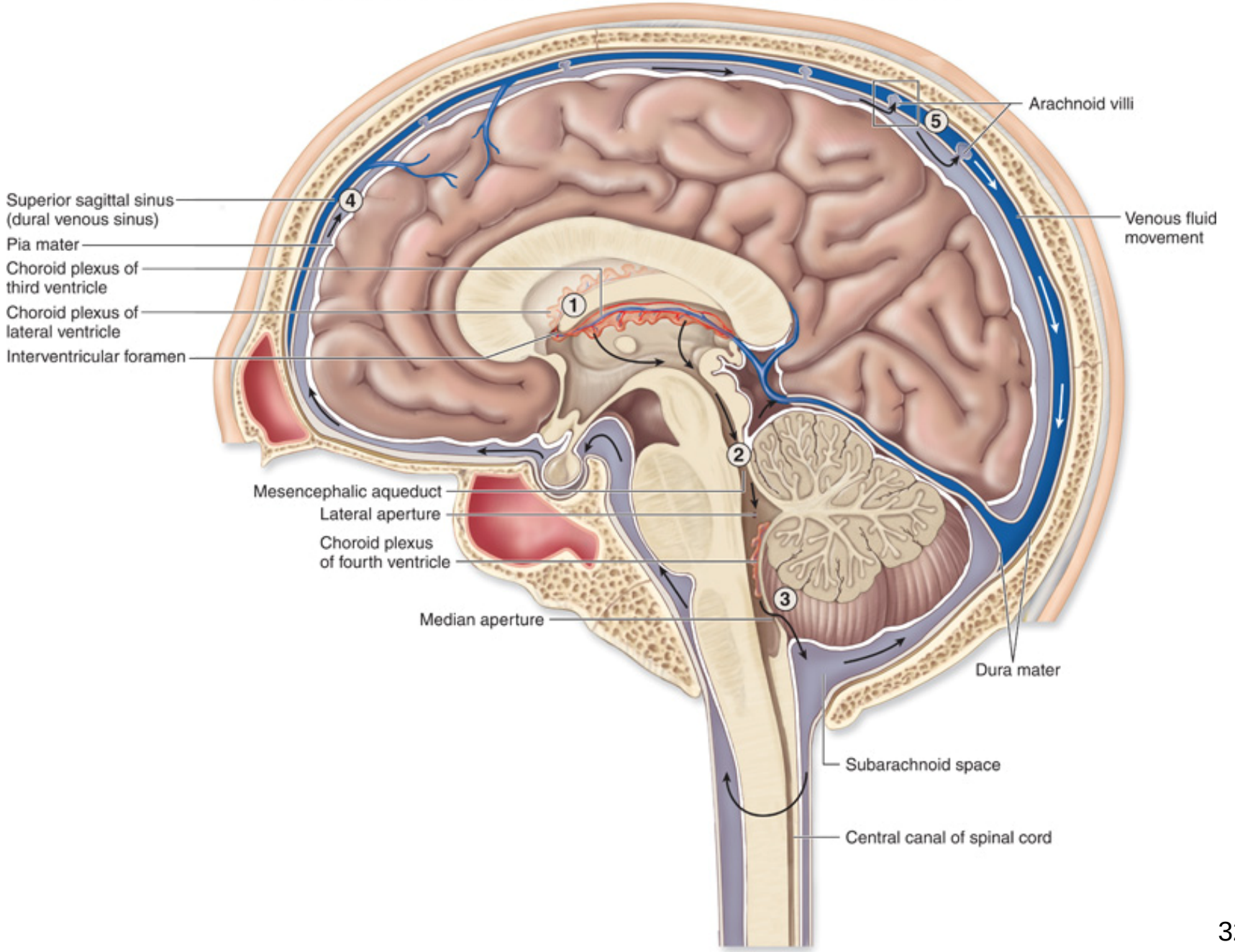

(a) Midsagittal section

Blood-Brain Barrier

- Nervous tissue is protected from the general circulation by the blood-brain barrier.
- Strictly regulates what substances can enter the interstitial fluid of the brain.
- Prevents exposure of neurons in the brain to drugs, waste products in the blood, and variations in levels of normal substances (ions, hormones) that could adversely affect brain function.

Blood-Brain Barrier

- Tight junctions prevent materials from diffusing across the capillary wall.
- Astrocytes act as “gatekeepers” that permit materials to pass to the neurons after leaving the capillaries.
- Is markedly reduced or missing in three distinct locations in the CNS: the choroid plexus, hypothalamus, and pineal gland.

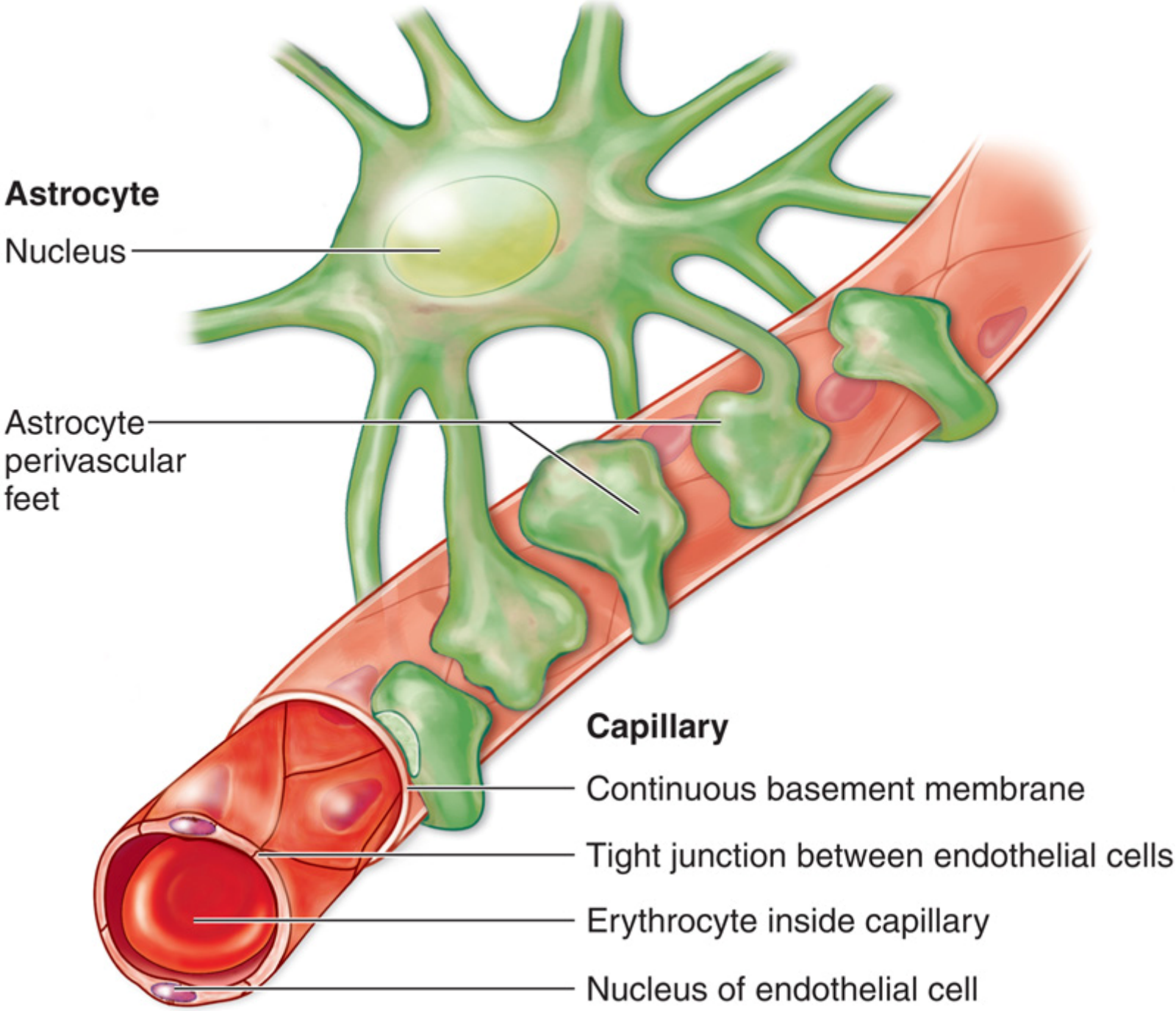

Cerebrum

- Account for 83% of brain mass
- Fissures – deep grooves – separate major regions of the brain
  - Transverse fissure – separates cerebrum and cerebellum
  - Longitudinal fissure – separates cerebral hemispheres
- Sulci – grooves on the surface of the cerebral hemispheres
- Gyri – twisted ridges between sulci
- Prominent gyri and sulci are similar in all people

Cerebrum

- Deeper sulci divide cerebrum into lobes
- Lobes are named for the skull bones overlying them
- Central sulcus separates frontal and parietal lobes
  - Bordered by two gyri
    - Precentral gyrus
    - Postcentral gyrus
- Parieto-occipital sulcus
  - Separates the occipital from the parietal lobe
- Lateral sulcus
  - Separates temporal lobe from parietal and frontal lobes
- Insula – deep within the lateral sulcus

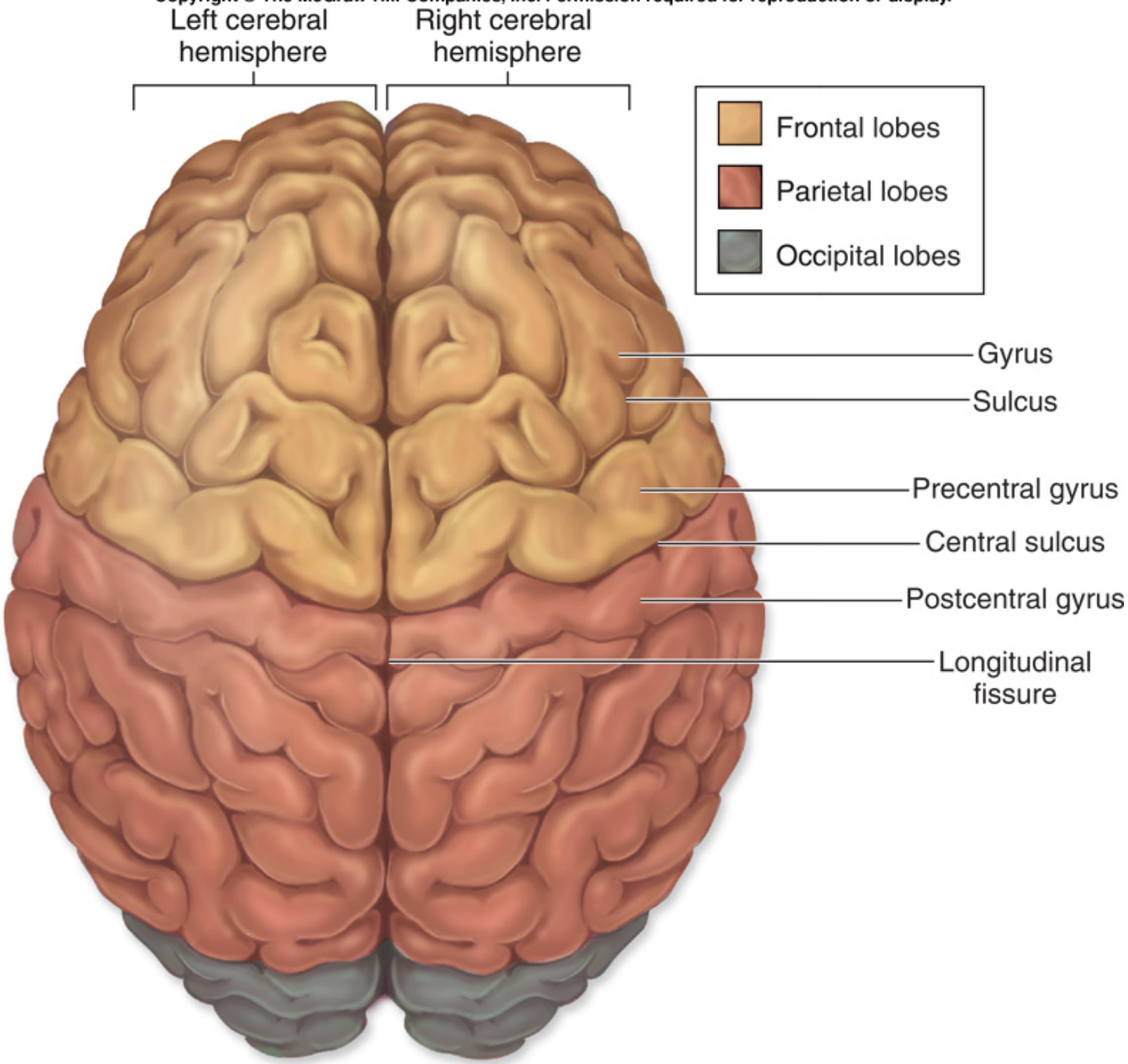

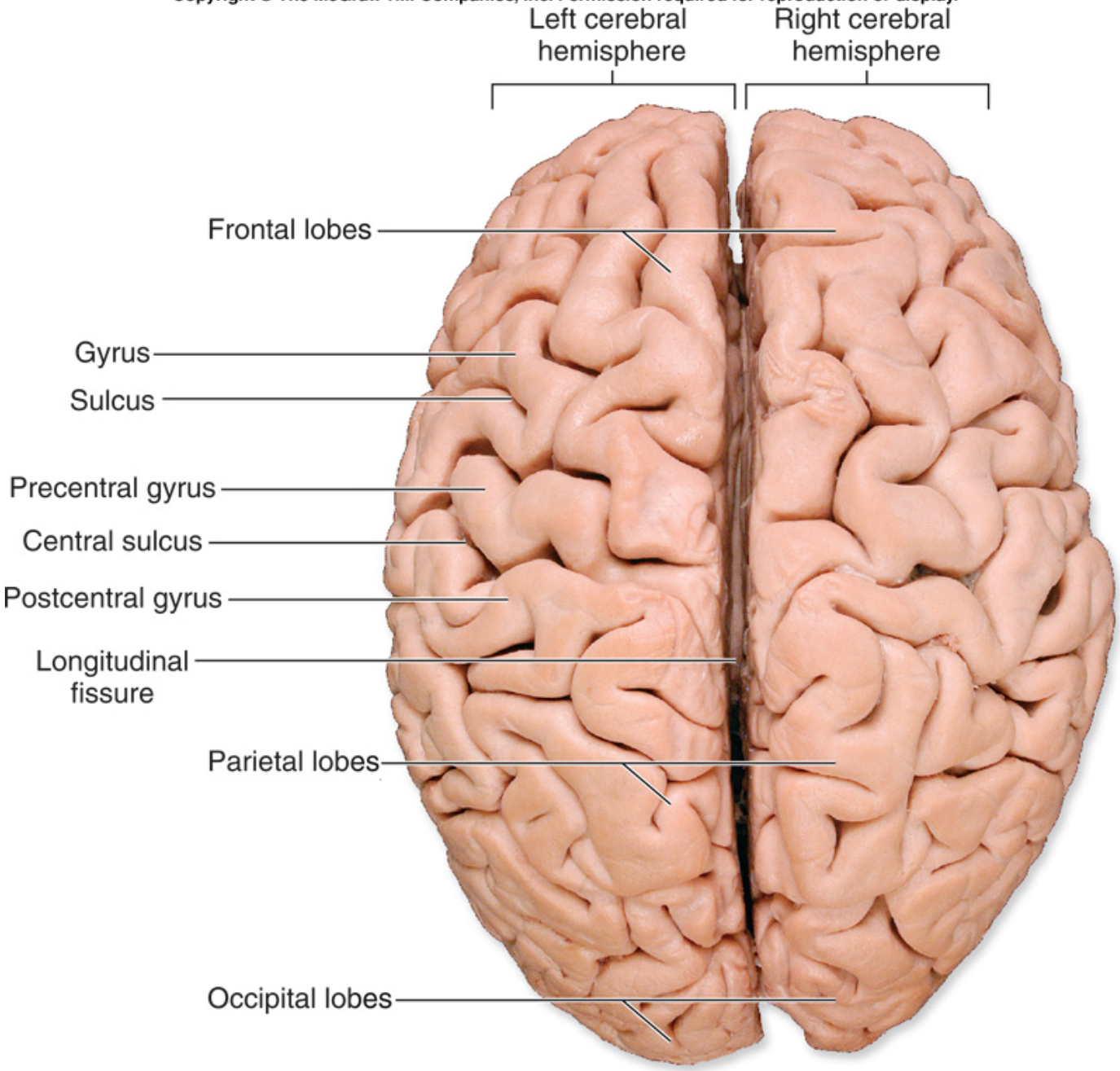

Superior view

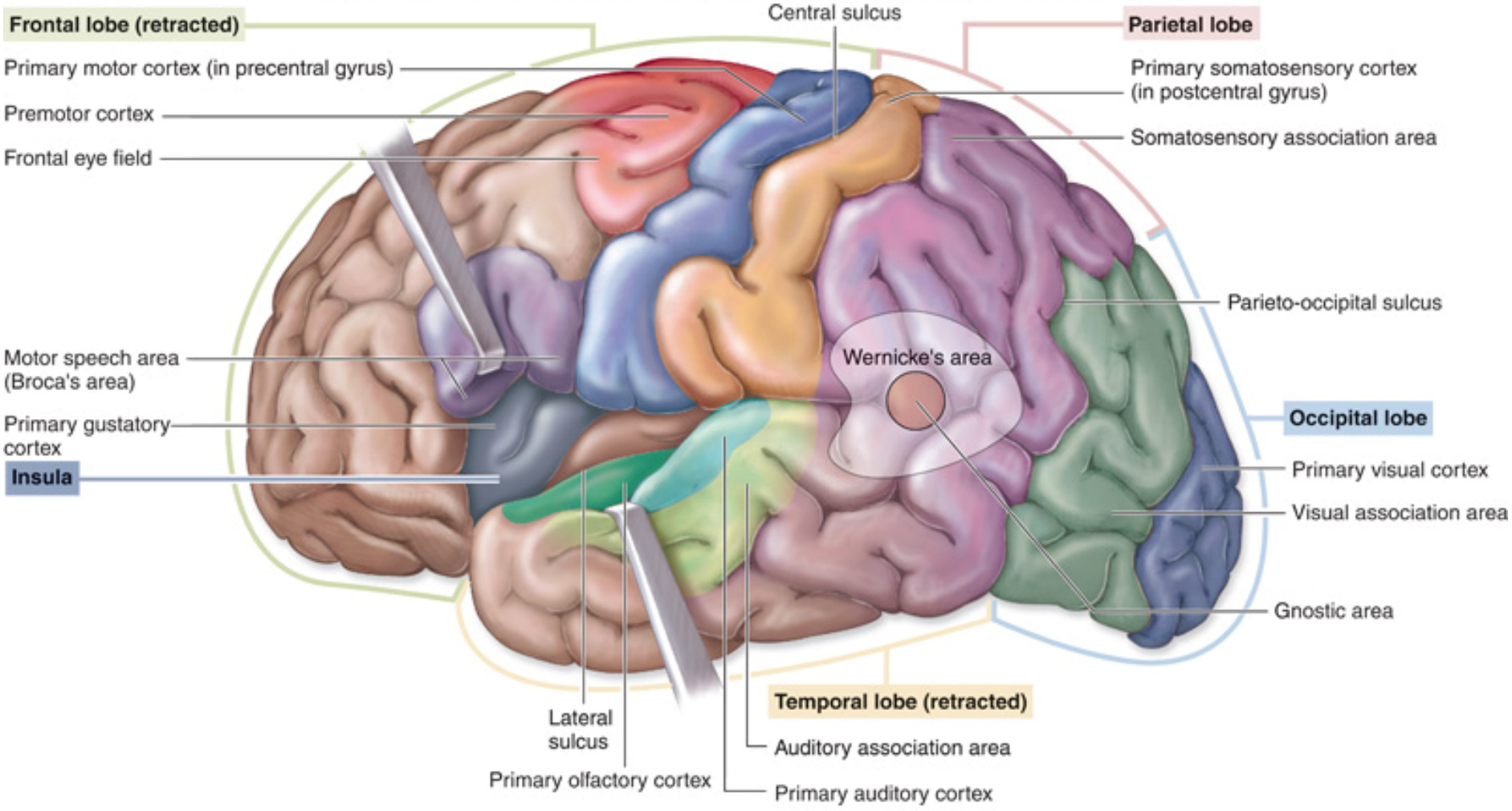

Left lateral view

Cerebrum: functional areas

- Home of our conscious mind
- Enables us to:
  - Be aware of ourselves and our sensations
  - Initiate and control voluntary movements
  - Communicate, remember, and understand

Cerebral cortex

- Composed of gray matter
  - Neuronal cell bodies, dendrites, and short axons
- Folds in cortex – triples its size
- Approximately 40% of brain's mass
- Brodmann areas – 52 structurally distinct areas

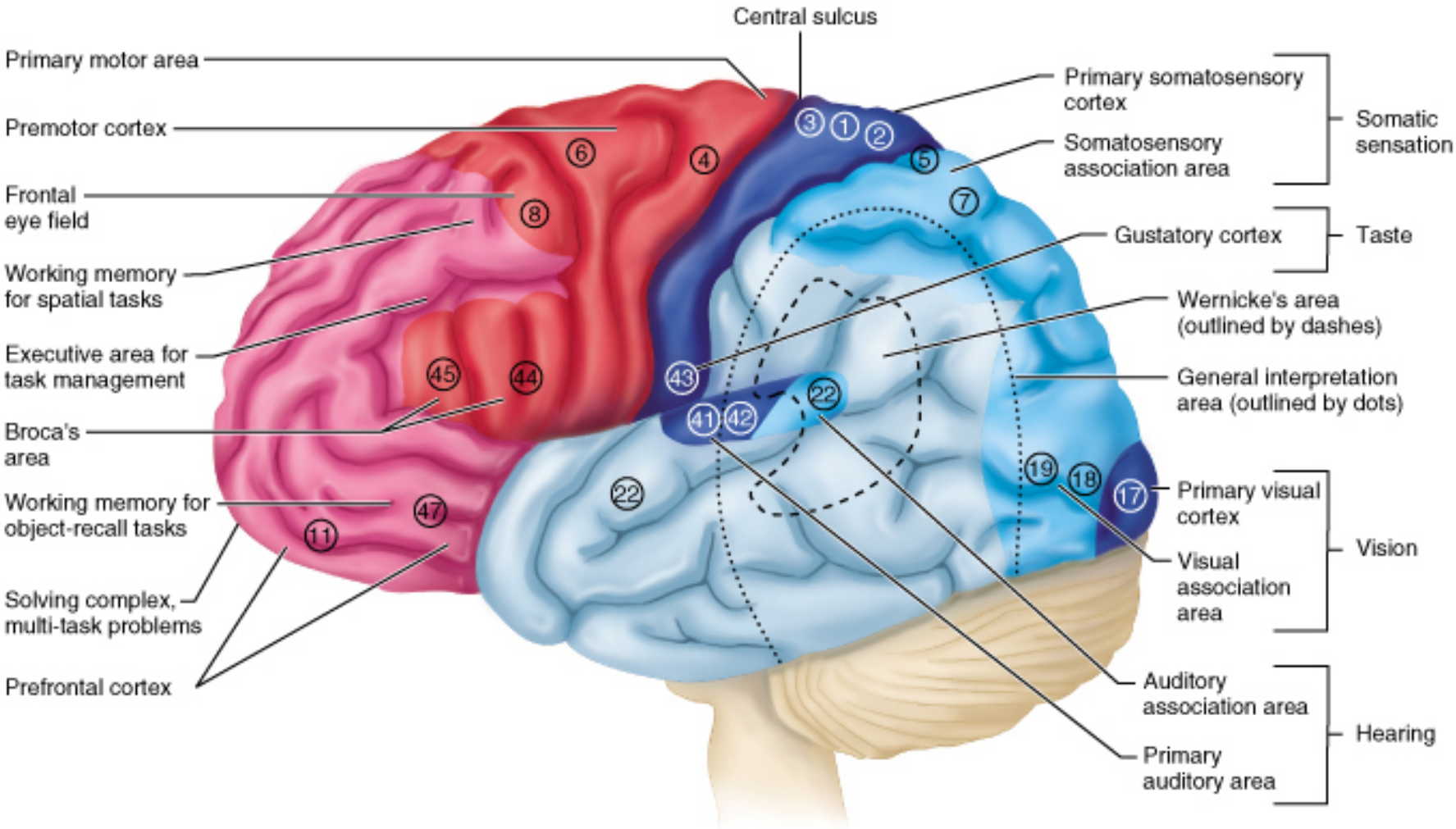
Central sulcus
Primary motor area
Premotor cortex
Frontal eye field
Working memory for spatial tasks
Executive area for task management
Broca's area
Working memory for object-recall tasks
Solving complex, multi-task problems
Prefrontal cortex
Primary somatosensory cortex
Somatosensory association area
Somatic sensation
Gustatory cortex
Taste
Wernicke's area (outlined by dashes)
General interpretation area (outlined by dots)
Primary visual cortex
Visual association area
Vision
Auditory association area
Primary auditory area
Hearing
3
1
2
5
7
6
4
8
45
44
43
41
42
22
22
19
18
17
11
47

Functional areas of the cortex

- Three kinds of functional areas
  - Motor areas
  - Sensory areas
  - Association areas

Motor areas

- Controls motor functions
  - Primary motor cortex (somatic motor area)
  - Located in precentral gyrus (Brodmann area 4)
- Pyramidal cells – large neurons of primary motor cortex

Motor areas

- Corticospinal tracts descend through brainstem and spinal cord
  - Axons signal motor neurons to control skilled movements
  - **Contralateral** – pyramidal axons cross over to opposite side of the brain

Motor areas

- Specific pyramidal cells control specific areas of the body
- Face and hand muscles – controlled by many pyramidal cells
- Motor homunculus – body map of the motor cortex

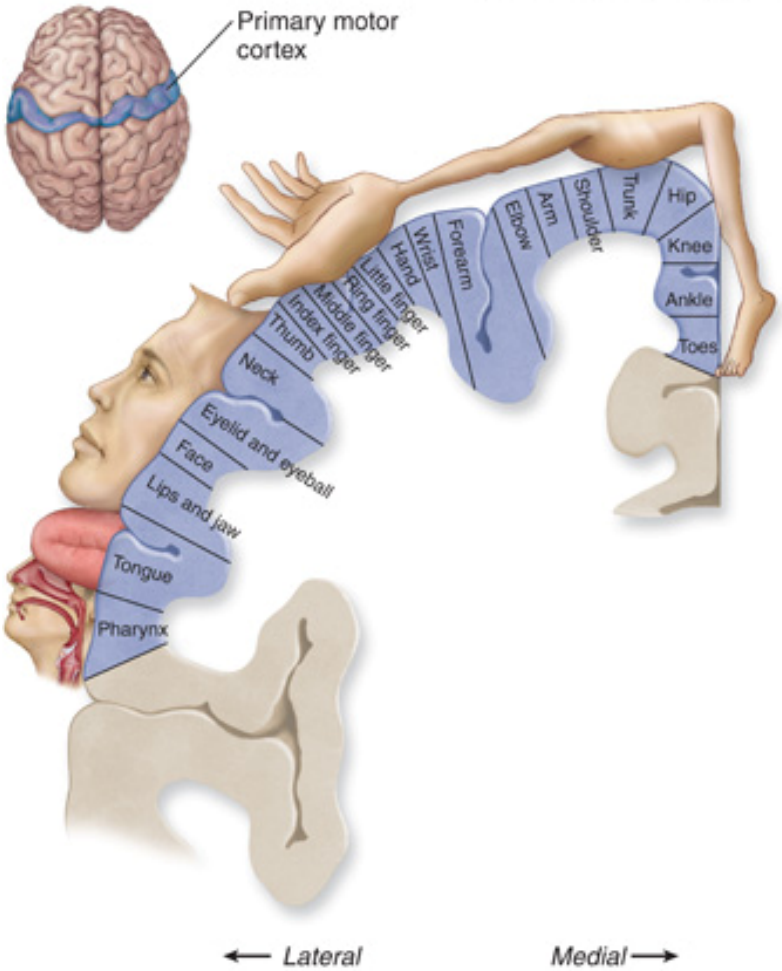

Primary motor cortex

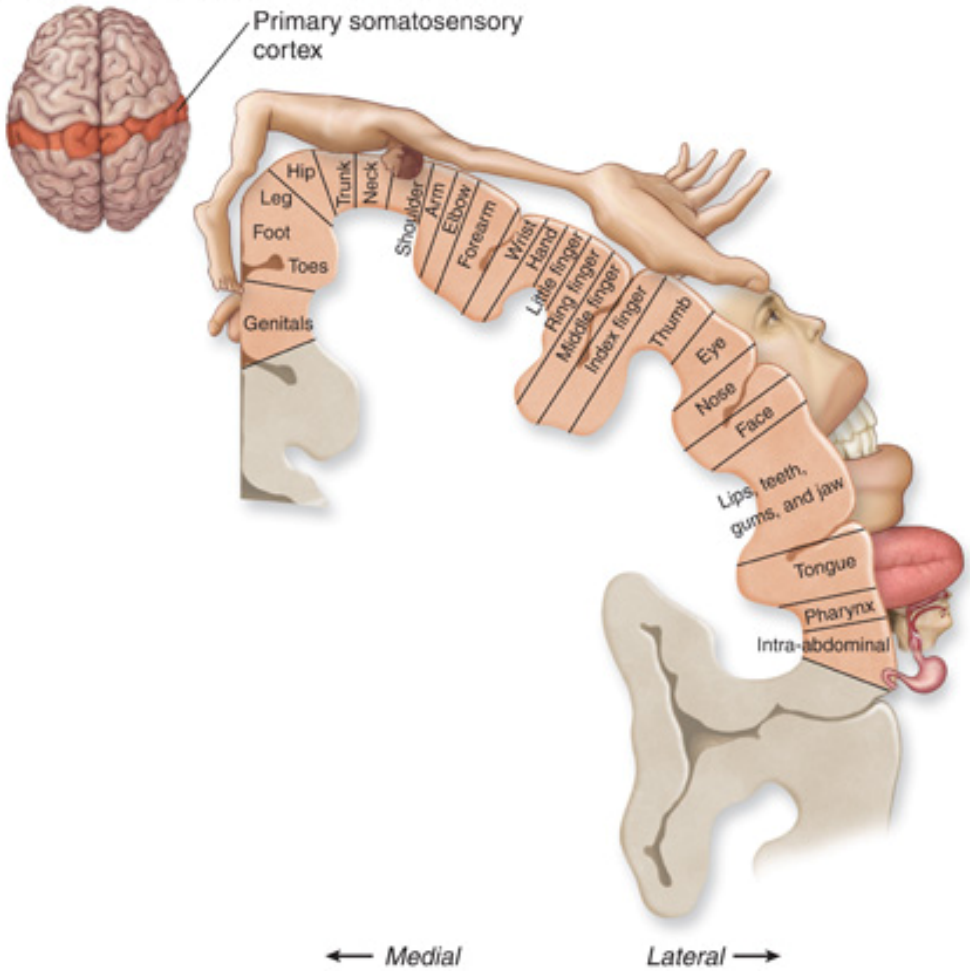

Primary somatosensory cortex

Sensory cortex

- Cortical areas involved in conscious awareness of sensation
- Located in parietal, temporal, and occipital lobes
- Distinct area for each of the major senses

Primary Somatosensory Cortex

- Located along the postcentral gyrus
  - Corresponds to Brodmann areas 1-3
- Involved with conscious awareness of general somatic senses
- Spatial discrimination – precisely locates a stimulus

Primary Somatosensory Cortex

- Projection is *contralateral*
  - Cerebral hemispheres
    - Receive sensory input from the opposite side of the body
- Sensory homunculus – a body map of the sensory cortex

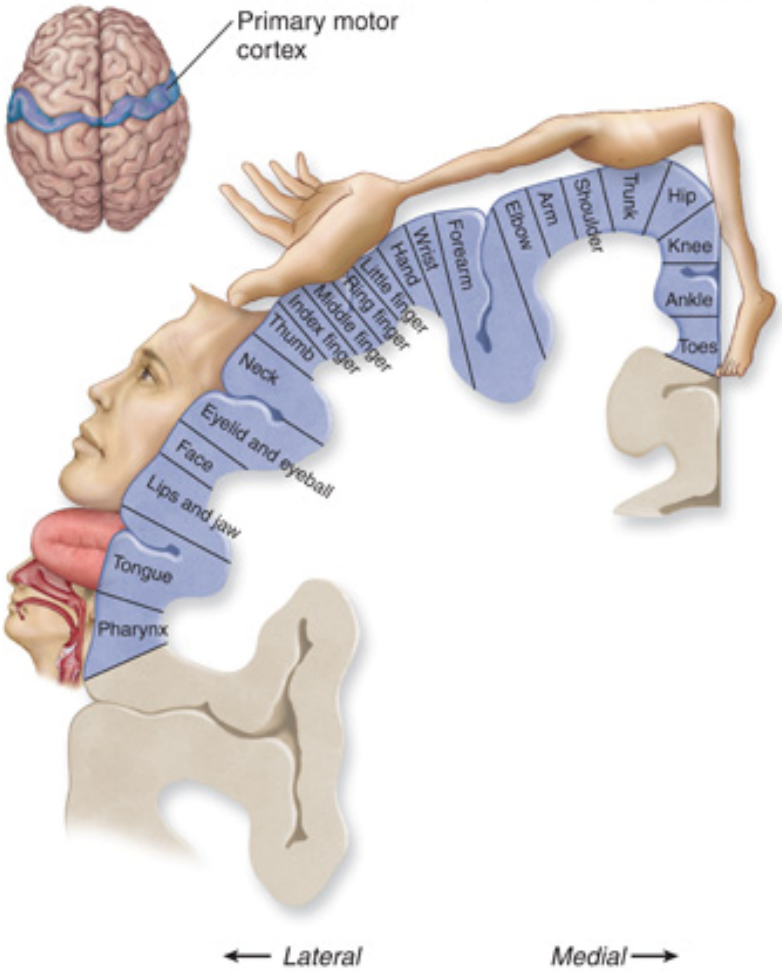

Primary motor cortex

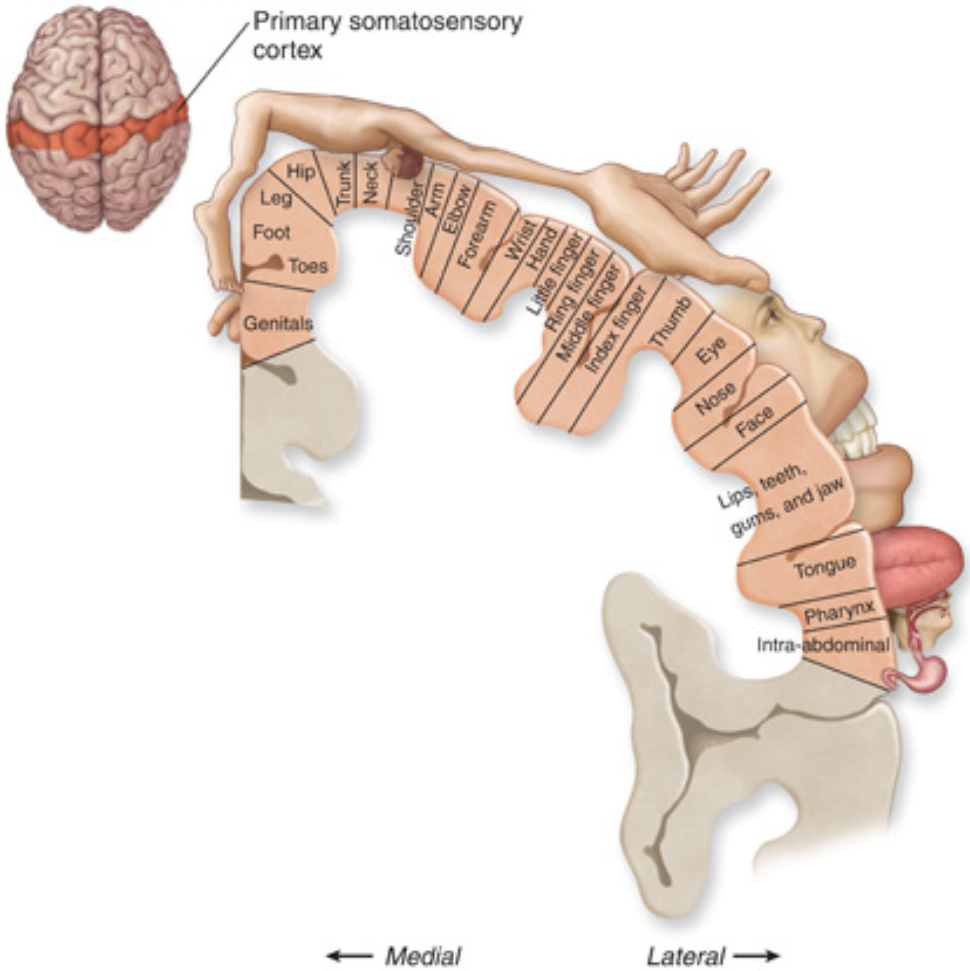

Primary somatosensory cortex

Somatosensory Association Area

- Lies posterior to the primary somatosensory cortex
  - Corresponds to Brodmann areas 5 and 7
- Integrates different sensory inputs
  - Touch, pressure, and others
- Draws upon stored memories of past sensory experiences

Sensory Areas – Visual Areas

- Primary visual cortex
  - Corresponds to Brodmann area 17
  - Located deep within the calcarine sulcus
    - On the posterior and medial part of the occipital lobe
  - Receives visual information that originates on the retina
  - First of a series of areas that interprets visual input

Sensory Areas – Visual Areas

- Visual association area
  - Surrounds the primary visual area
  - Coincides with Brodmann areas 18 and 19
  - Continues the processing of visual information
  - Complex visual processing extends into:
    - Temporal and parietal lobes

Sensory Areas – Auditory Areas

- Primary auditory cortex
  - Function – conscious awareness of sound
  - Location – superior edge of the temporal lobe
  - Corresponds to Brodmann areas 41 and 42

Sensory Areas – Auditory Areas

- Auditory association area
  - Lies posterior to the primary auditory cortex
  - Located within Brodmann area 22
  - Permits evaluation of different sounds
  - Lies in the center of Wernicke's area
  - Involved in recognizing and understanding speech

Sensory Areas – Gustatory Cortex

- Involved in the conscious awareness of taste stimuli
- Corresponds to Brodmann area 43
- Located on the “roof” of the lateral sulcus

Sensory Areas – Vestibular Cortex

- Located in the posterior part of the insula
- Deep to the lateral sulcus

Sensory Areas – Olfactory Cortex

- Lies on the medial aspect of the cerebrum
- Located in a region called the **piriform lobe**
- Olfactory nerves transmit impulses to the olfactory cortex
  - Provides conscious awareness of smells

Sensory Areas – Olfactory Cortex

- Part of the rhinencephalon – “nose brain”
- Includes – the piriform lobe, olfactory tract, and olfactory bulb
- Connects the brain to the limbic system
  - Explains why smells trigger emotions
- Orbitofrontal cortex
  - Involved with consciously identifying and recalling specific smells

Association areas

- Make associations between different types of sensory information
- Associate new sensory input with memories of past experiences
- New name for association areas – **higher order processing areas**

Association Areas – Prefrontal Cortex

- Large region of the frontal lobe anterior to motor areas
- Performs cognitive functions
  - All aspects of thinking and perceiving
  - Remembering and recalling information
  - Also related to mood
  - Has close links to the limbic part of the forebrain

Association Areas – Prefrontal Cortex

- Functional neuroimaging techniques
  - Reveal functions of specific parts of the prefrontal cortex
- Anterior pole of frontal cortex
  - Active in solving the most complex problems
- The farther rostrally one goes in the CNS, the more complex the neural functions

Association Areas – Prefrontal Cortex

- Functional areas located on the medial side of the frontal lobe
  - Regions anterior to the corpus callosum
    - Involved in complex personal and social interactions
  - Regions superior to the corpus callosum
    - Involved in “mentalization

Association Areas – General Interpretation Area

- Function is currently under investigation
- Located at the interface of:
  - The visual, auditory, and somatosensory association areas
- Newer studies show most of this region is involved in the visual processing of spatial relationships

Association Areas – Language Area

- Surrounds the lateral sulcus in the left cerebral hemisphere
- Five parts have been identified
  - Broca's area – speech production
  - Wernicke's area – speech comprehension
  - Lateral prefrontal cortex – conceptual analysis of spoken words

Association Areas – Language Area

- Five parts have been identified (continued)
  - Most of the lateral and inferior temporal lobe
    - Coordination of auditory and visual aspects of language
  - Parts of the insula
    - Initiation of word articulation
    - Recognition of rhymes and sound sequences

Association Areas – Insula

- Functions of its cortex – not well understood
- Some parts function in language and the sense of balance
- Other parts – visceral function
  - Conscious perception of:
    - Upset stomach
    - Full bladder
    - Some aspects of the sense of smell

Lateralization of Cortical Functioning

- The two hemispheres control opposite sides of the body
- Hemispheres are specialized for different cognitive functions

Lateralization of Cortical Functioning

- Left cerebral hemisphere – more control over:
  - Language abilities, math, and logic
- Right cerebral hemisphere – more involved with:
  - Visual-spatial skills
  - Reading facial expressions
  - Intuition, emotion, artistic and musical skills

Cerebral White Matter

- Different areas of the cerebral cortex communicate:
  - With each other
  - With the brainstem and spinal cord
- Fibers are usually myelinated and bundled into tracts

Cerebral White Matter

- Types of tracts
  - Commissures – composed of commissural fibers
    - Allows communication between cerebral hemispheres
    - Corpus callosum – the largest commissure
  - Association fibers
    - Connect different parts of the same hemisphere

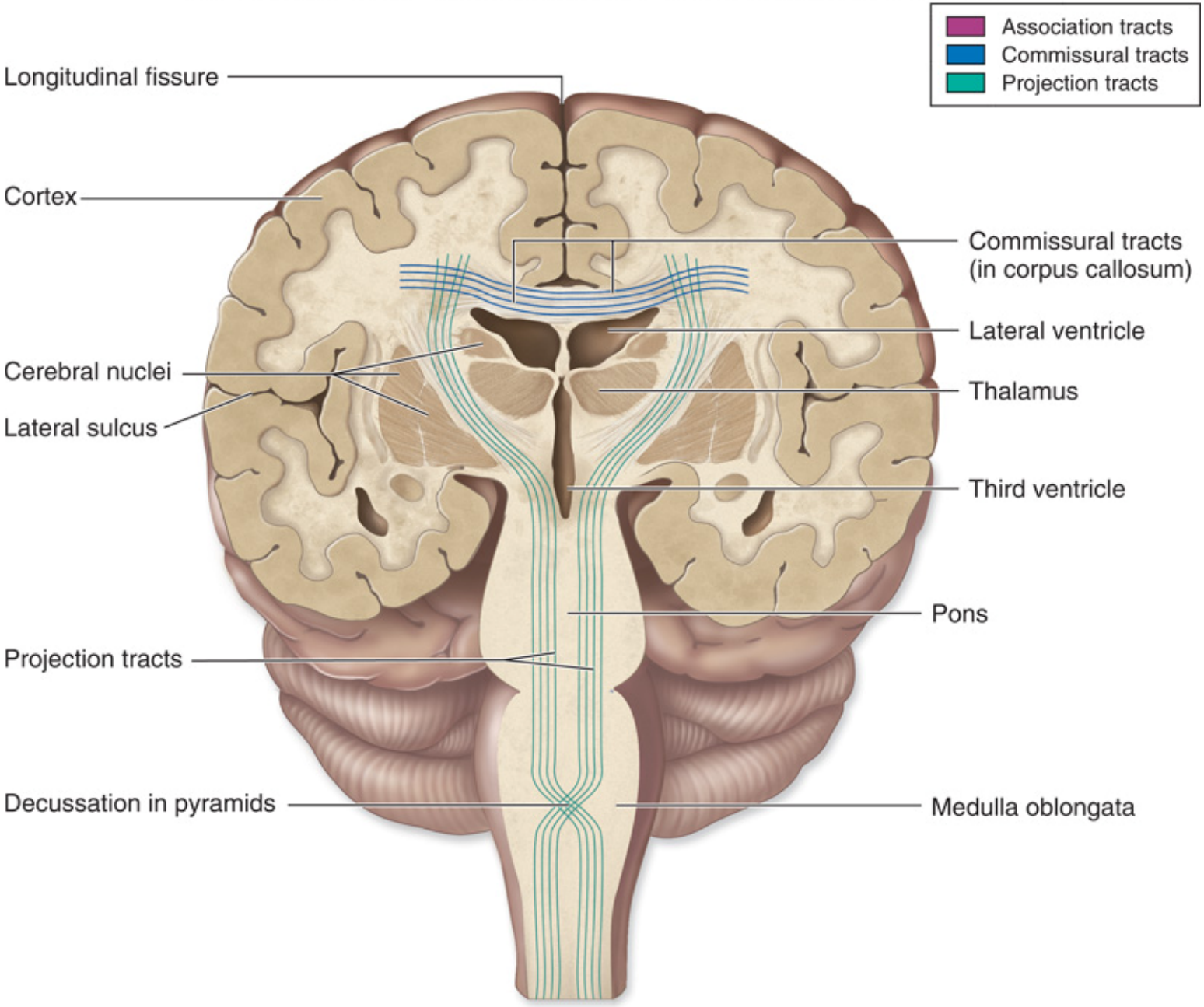

(b) Coronal section

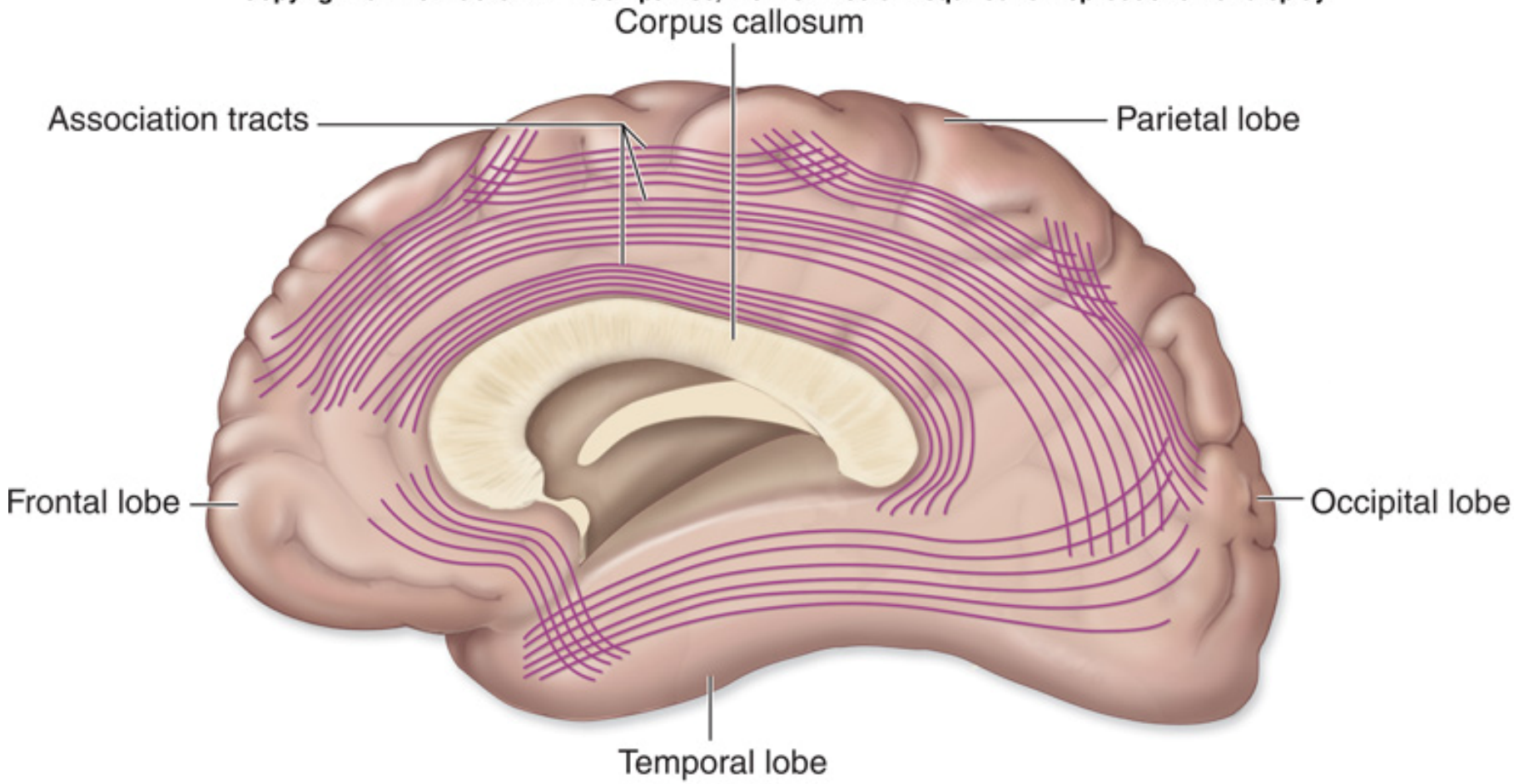

(a) Sagittal view



Cerebral White Matter

- Types of tracts (continued)
  - Projection fibers – run vertically
    - Descend from the cerebral cortex
    - Ascend to the cortex from lower regions

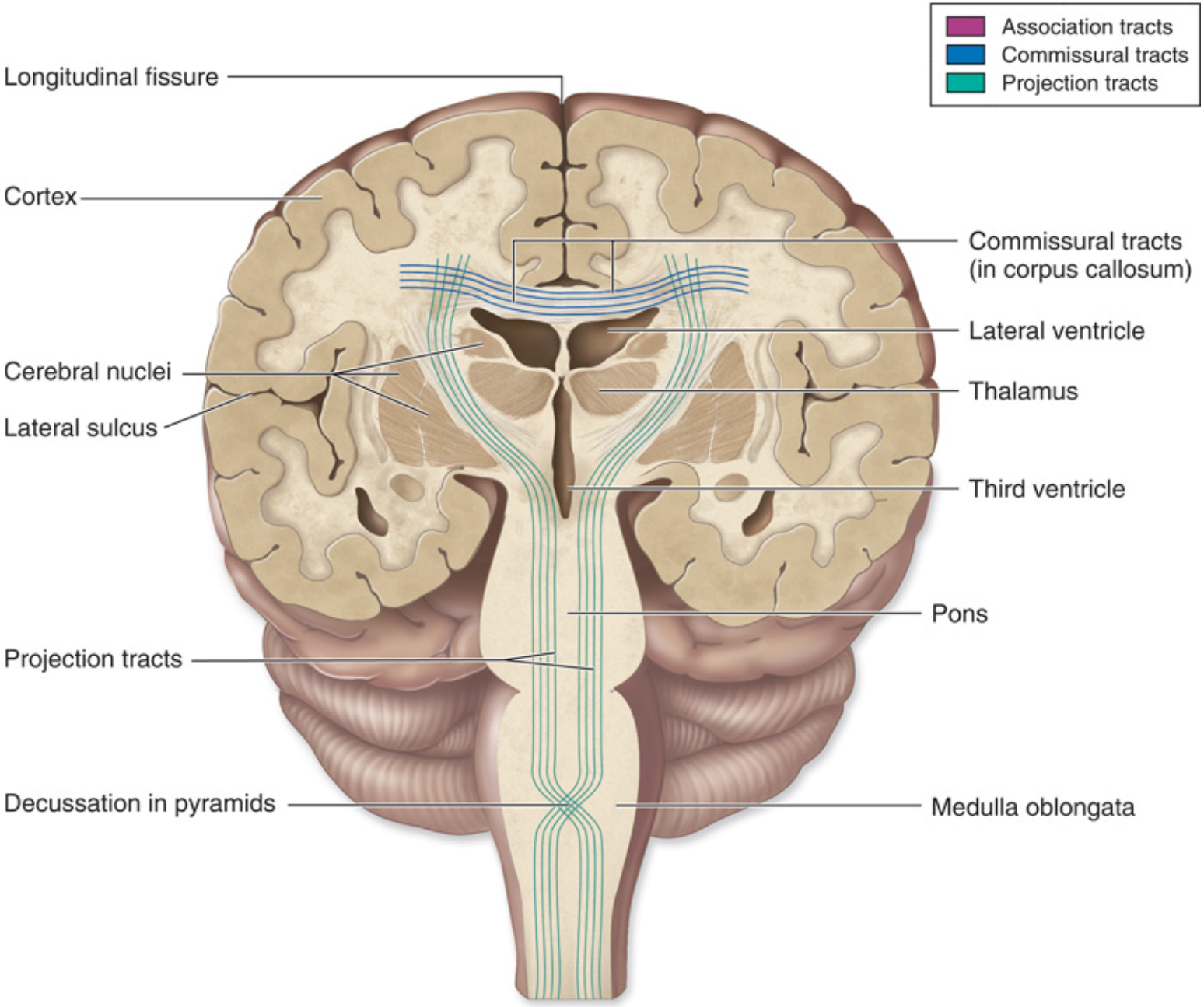

(b) Coronal section

Projection tracts

- Internal capsule – projection fibers form a compact bundle
  - Passes between the thalamus and basal nuclei
- Corona radiata – superior to the internal capsule
  - Fibers run to and from the cerebral cortex

Basal nuclei

- A group of nuclei deep within the cerebral white matter
  - Caudate nucleus – arches over the thalamus
  - Lentiform nucleus – “lens shaped”
  - Amygdala – sits on top of the caudate nucleus
    - Functionally belongs with the limbic system

Basal nuclei

- Lentiform nucleus
  - Divided into two parts
    - Globus pallidus
    - Putamen

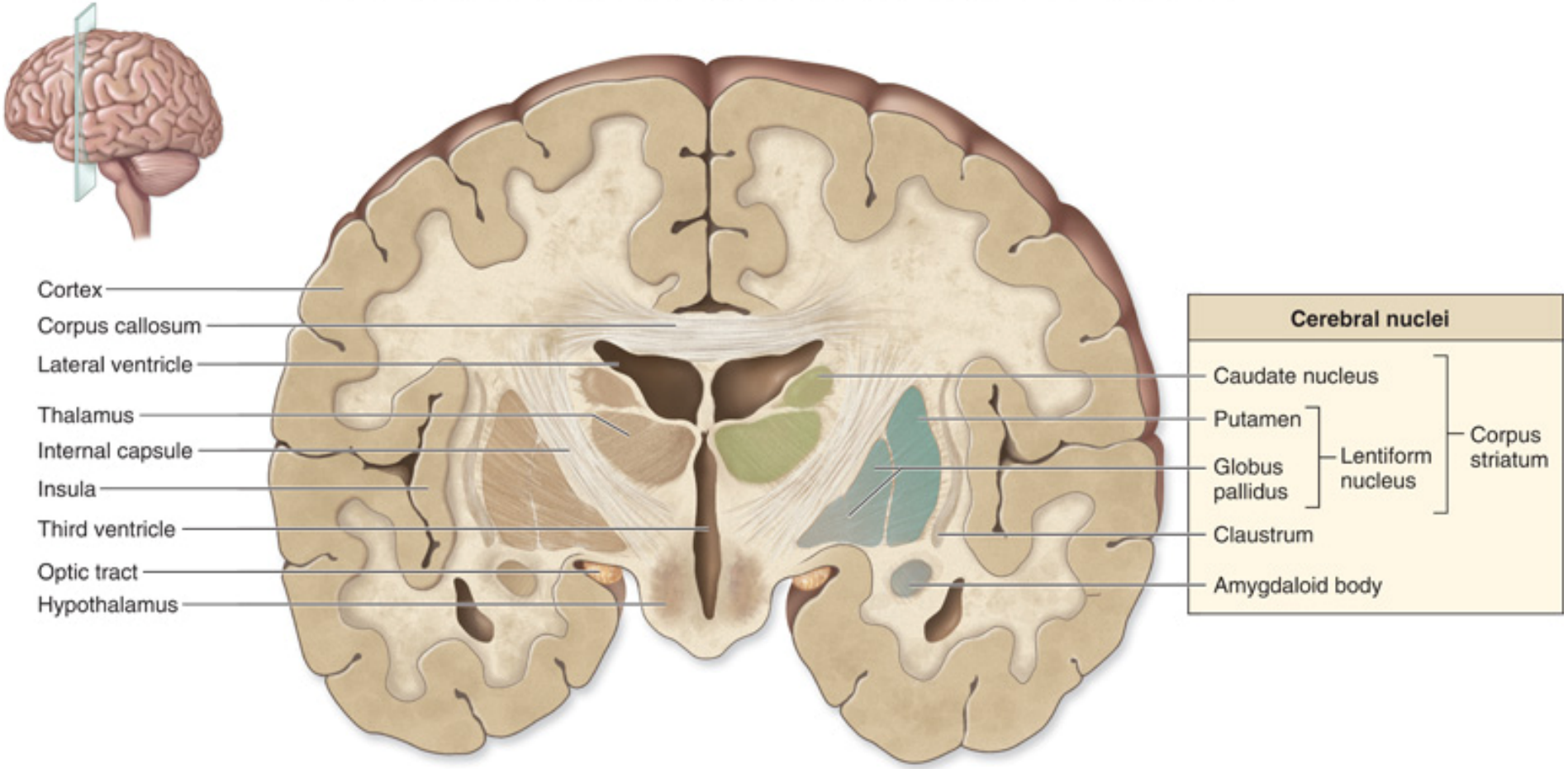

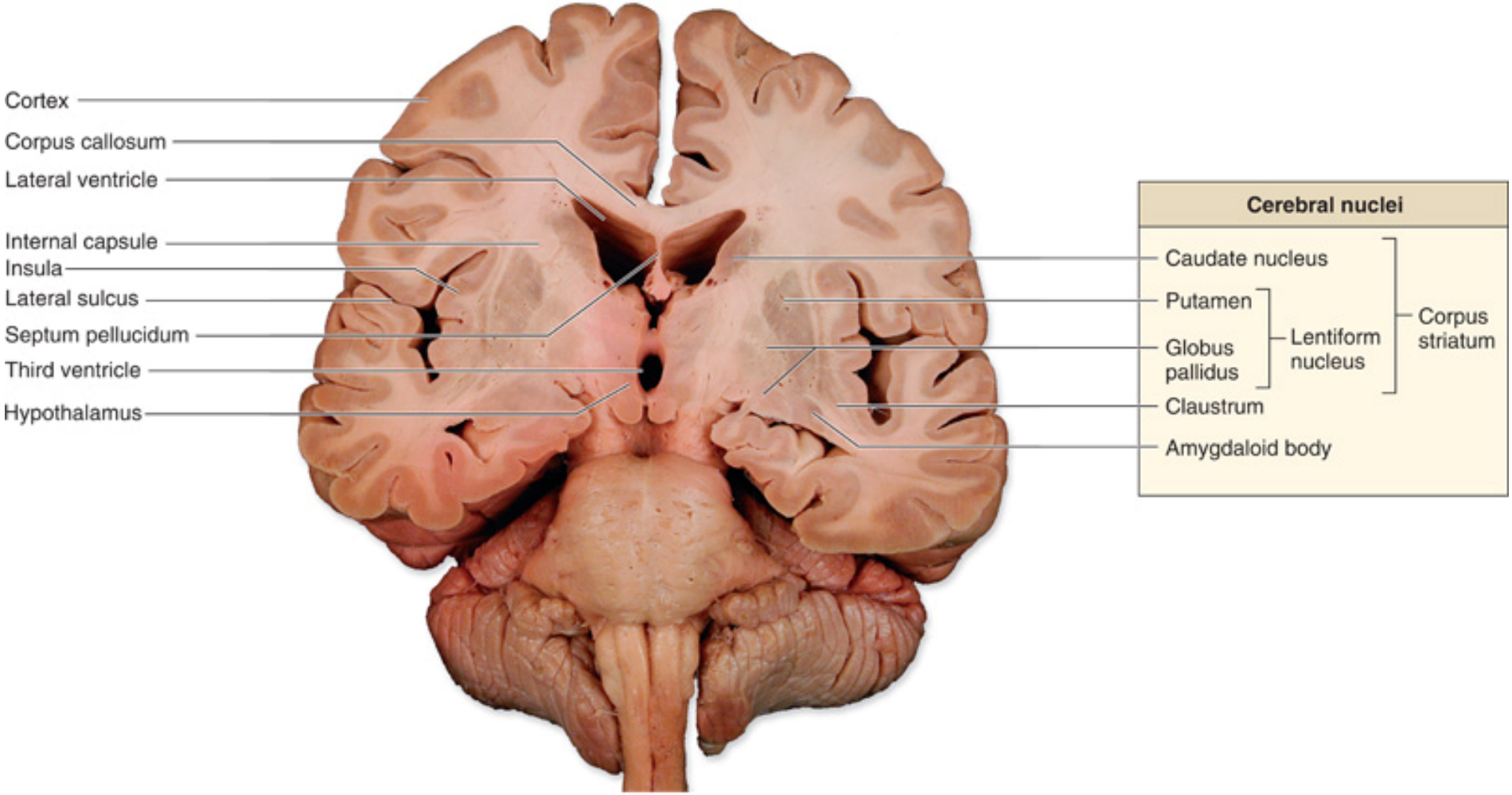

Coronal section

Basal nuclei

- Cooperate with the cerebral cortex in controlling movements
- Receive input from many cortical areas
- Evidence shows that they:
  - Start, stop, and regulate intensity of voluntary movements
  - In some way estimate the passage of time

The Diencephalon

- Forms the center core of the forebrain
- Surrounded by the cerebral hemispheres
- Composed of three paired structures:
  - Thalamus, hypothalamus, and epithalamus
- Border the third ventricle
- Primarily composed of gray matter

The Thalamus

- Makes up 80% of the diencephalon
- Contains approximately a dozen major nuclei
- Send axons to regions of the cerebral cortex
- Nuclei act as relay stations for incoming sensory messages

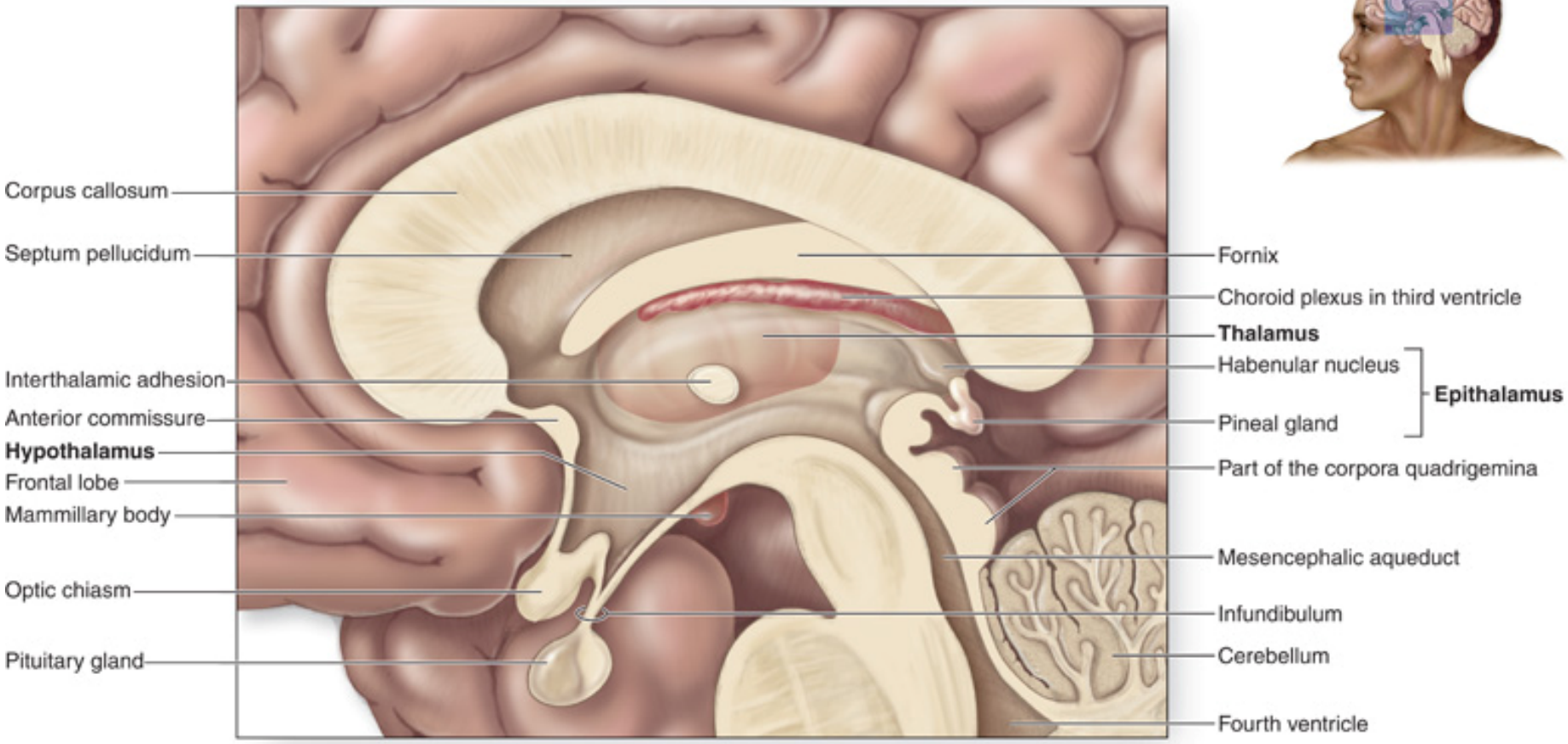

Midsagittal section

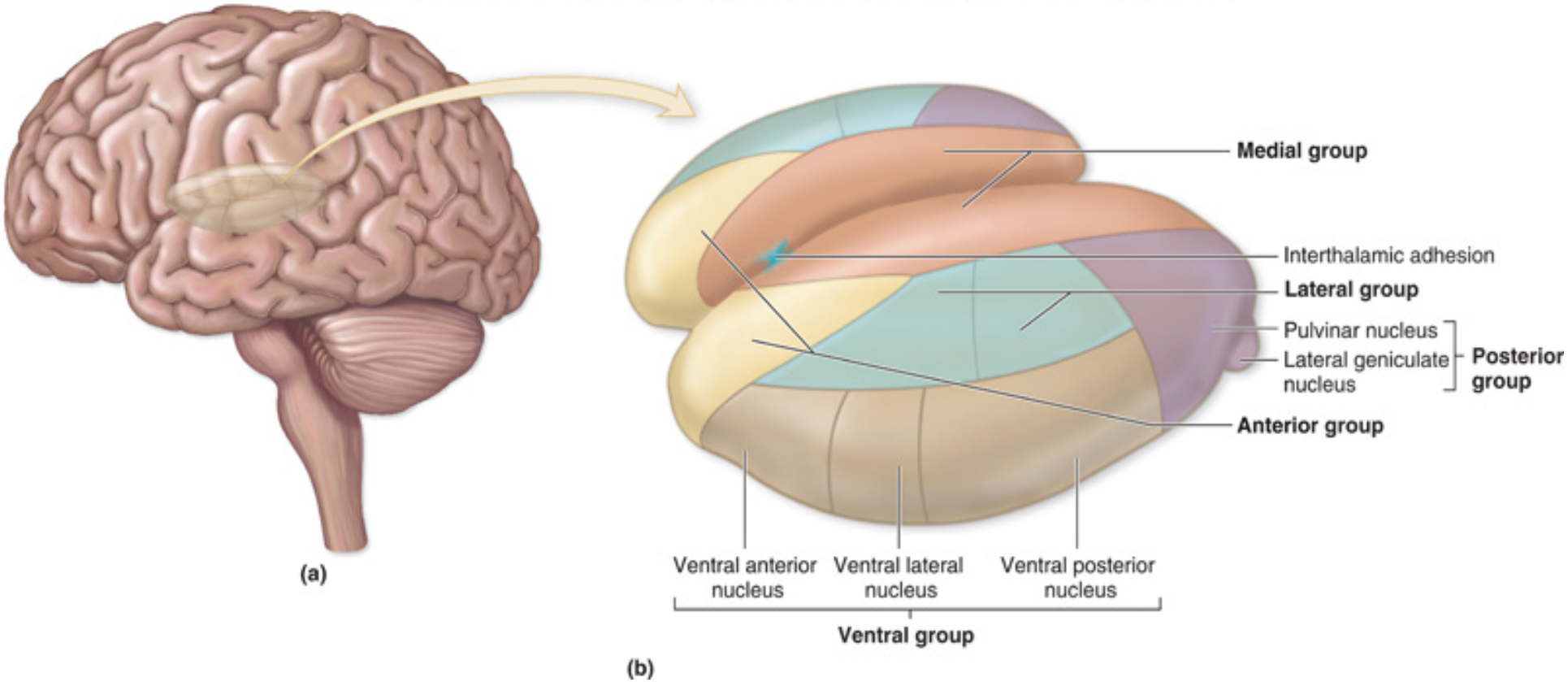

The Thalamus

- Afferent impulses converge on the thalamus
  - Synapse in at least one of its nuclei
- Is the “gateway” to the cerebral cortex
- Nuclei organize and amplify or tone down signals

The Diencephalon – The Hypothalamus

- Lies between the optic chiasm and the mammillary bodies
- Pituitary gland projects inferiorly
- Contains approximately a dozen nuclei
- Main visceral control center of the body

The Hypothalamus

- Functions include the following:
  - Control of the autonomic nervous system
  - Control of emotional responses
  - Regulation of body temperature
  - Regulation of hunger and thirst sensations
  - Control of behavior
  - Regulation of sleep-wake cycles
  - Control of the endocrine system
  - Formation of memory

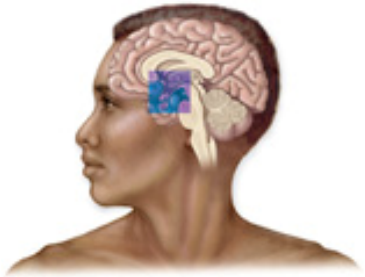

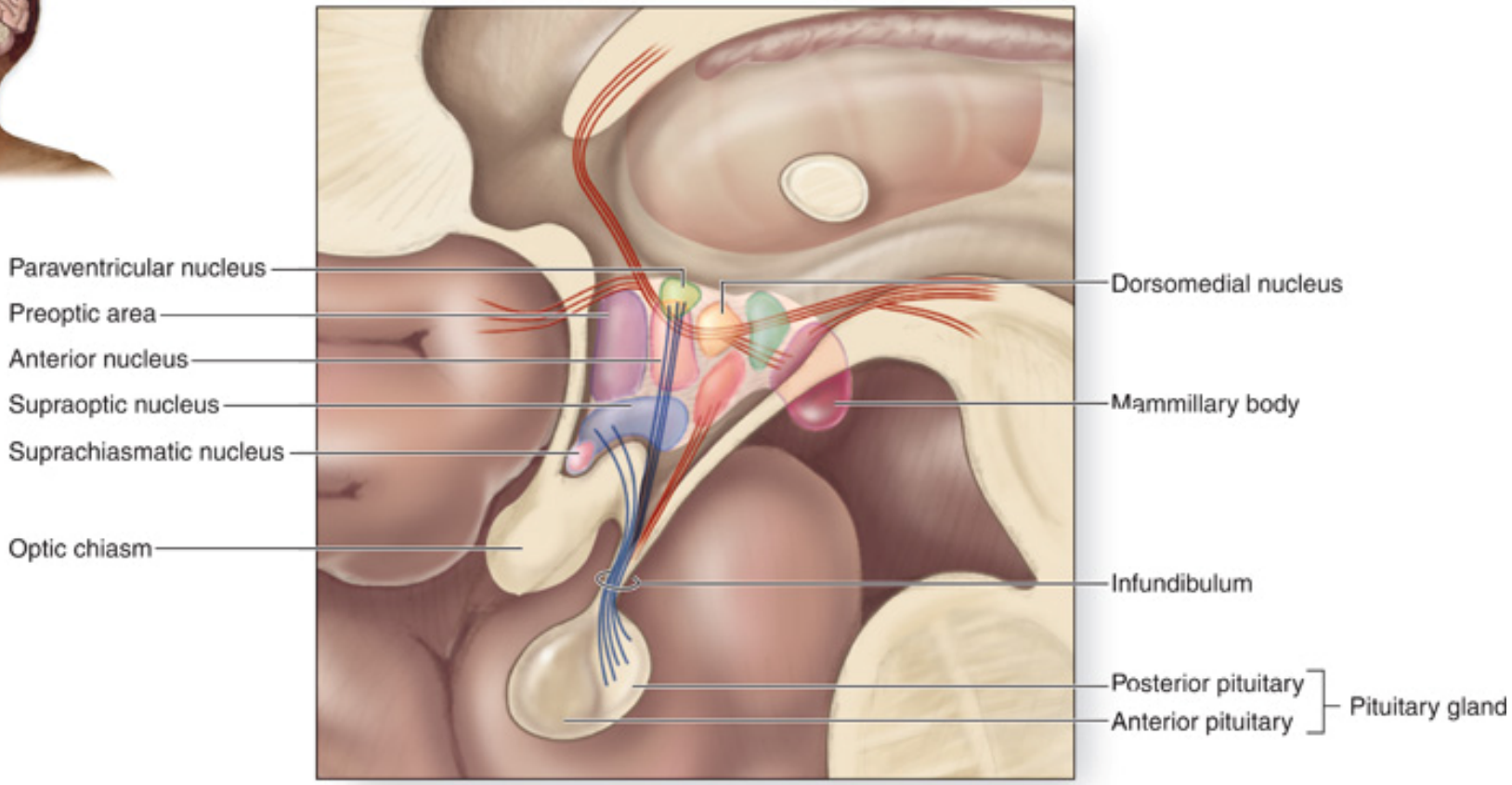

Sagittal section of hypothalamus

The Diencephalon – The Epithalamus

- Forms part of the “roof” of the third ventricle
- Consists of a tiny group of nuclei
- Includes the **pineal gland (pineal body)**
  - Secretes the hormone melatonin
  - Under influence of the hypothalamus

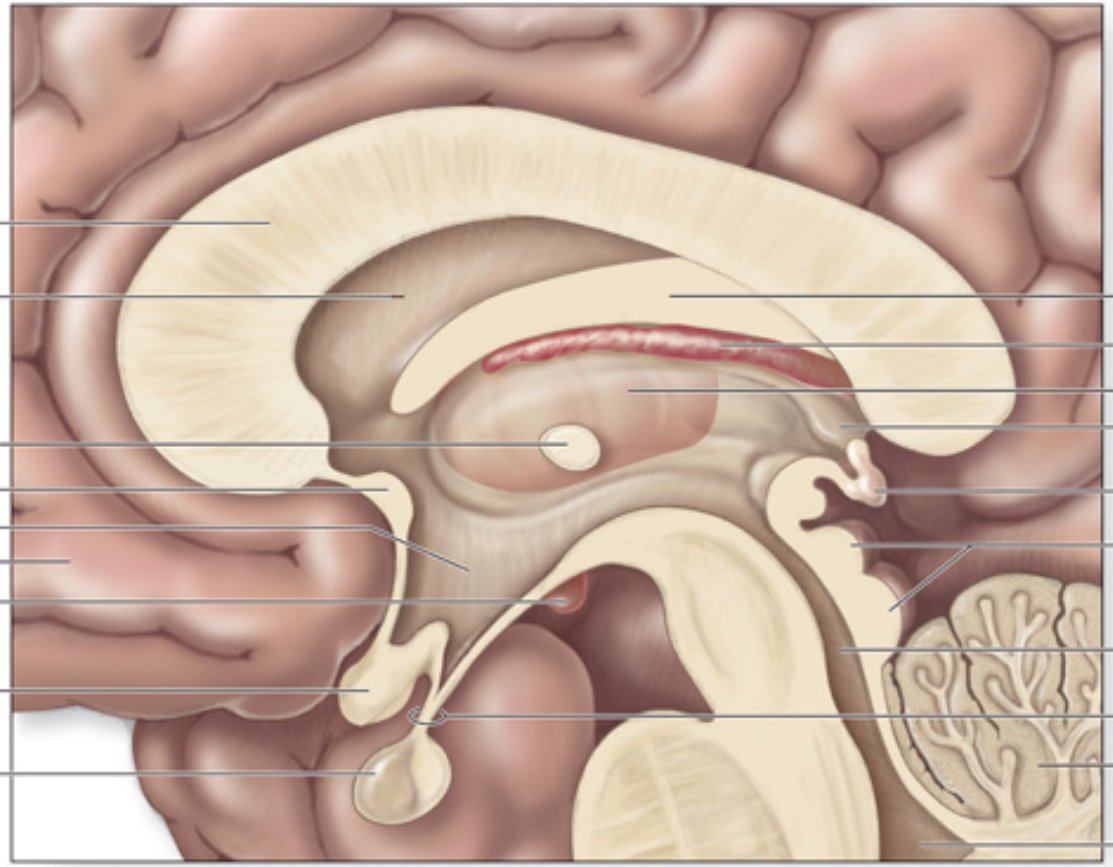

Midsagittal section

The Brain Stem

- Includes the midbrain, pons, and medulla oblongata
- Several general functions
  - Produces automatic behaviors necessary for survival
  - Passageway for all fiber tracts running between the cerebrum and spinal cord
  - Heavily involved with the innervation of the face and head
    - 10 of the 12 pairs of cranial nerves attach to it

The Brain Stem – The Midbrain

- Lies between the diencephalon and the pons
- Central cavity – the cerebral aqueduct
- Cerebral peduncles located on the ventral surface of the brain
  - Contain pyramidal (corticospinal) tracts
- Superior cerebellar peduncles
  - Connect midbrain to the cerebellum

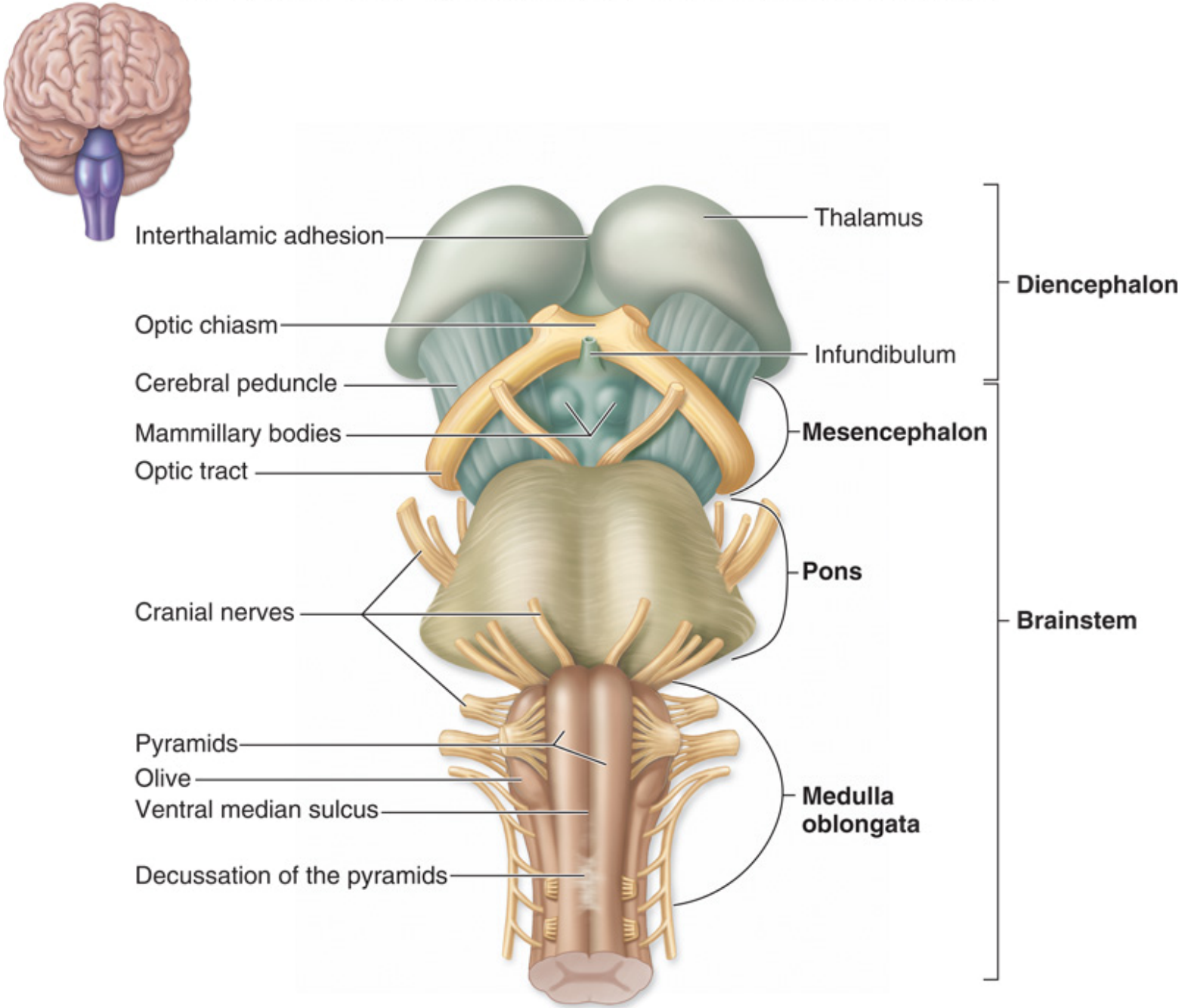

(a) Anterior view

The Brain Stem – The Midbrain

- Periaqueductal gray matter surrounds the cerebral aqueduct
  - Involved in two related functions
    - Fright-and-flight reaction
    - Mediates response to visceral pain

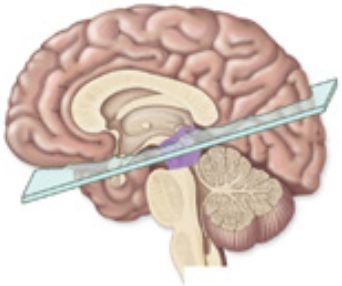

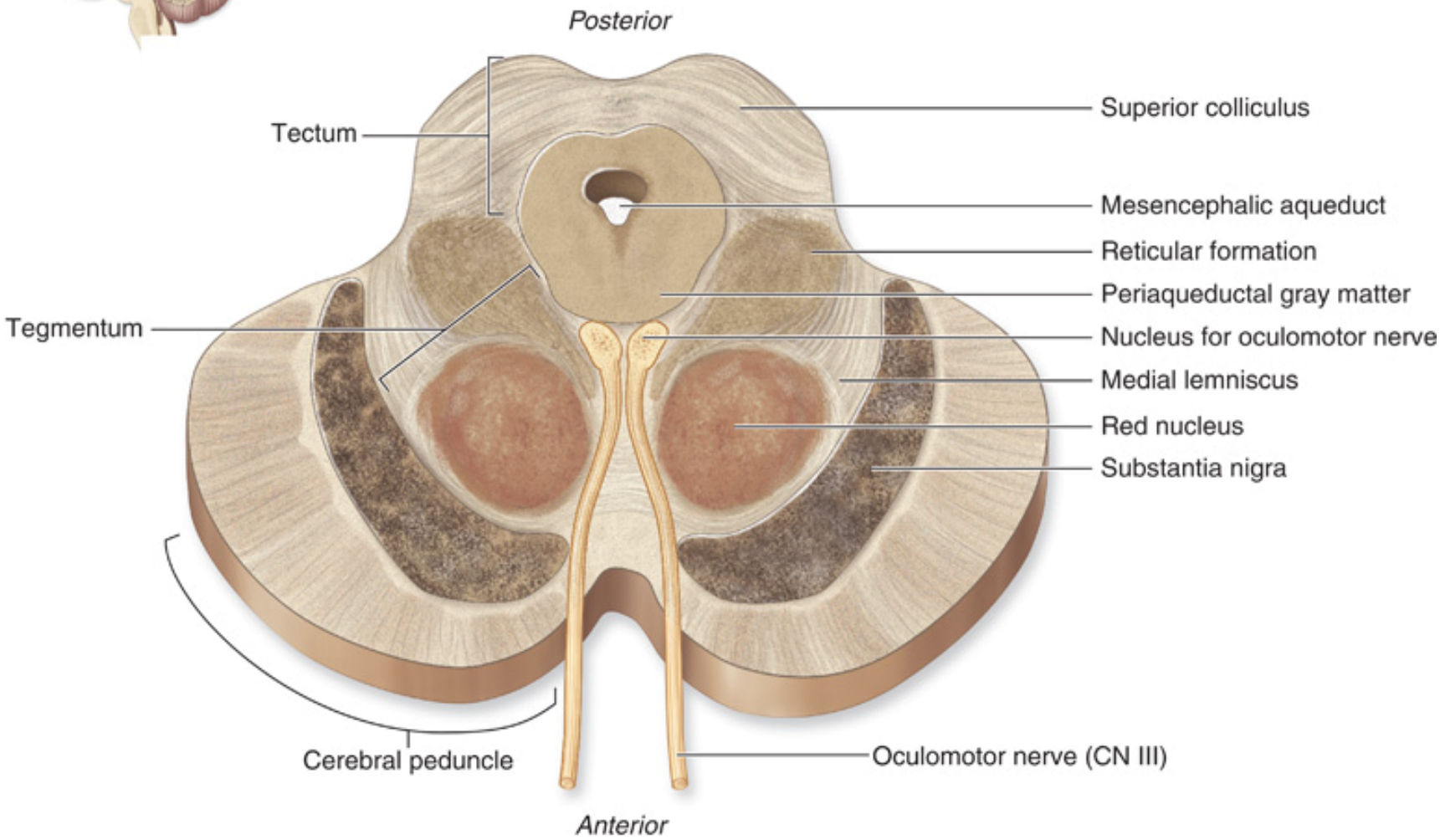

Cross-sectional view of mesencephalon

The Brain Stem – The Midbrain

- Corpora quadrigemina – the largest nuclei
  - Divided into the superior and inferior colliculi
    - Superior colliculi – nuclei that act in visual reflexes
    - Inferior colliculi – nuclei that act in reflexive response to sound

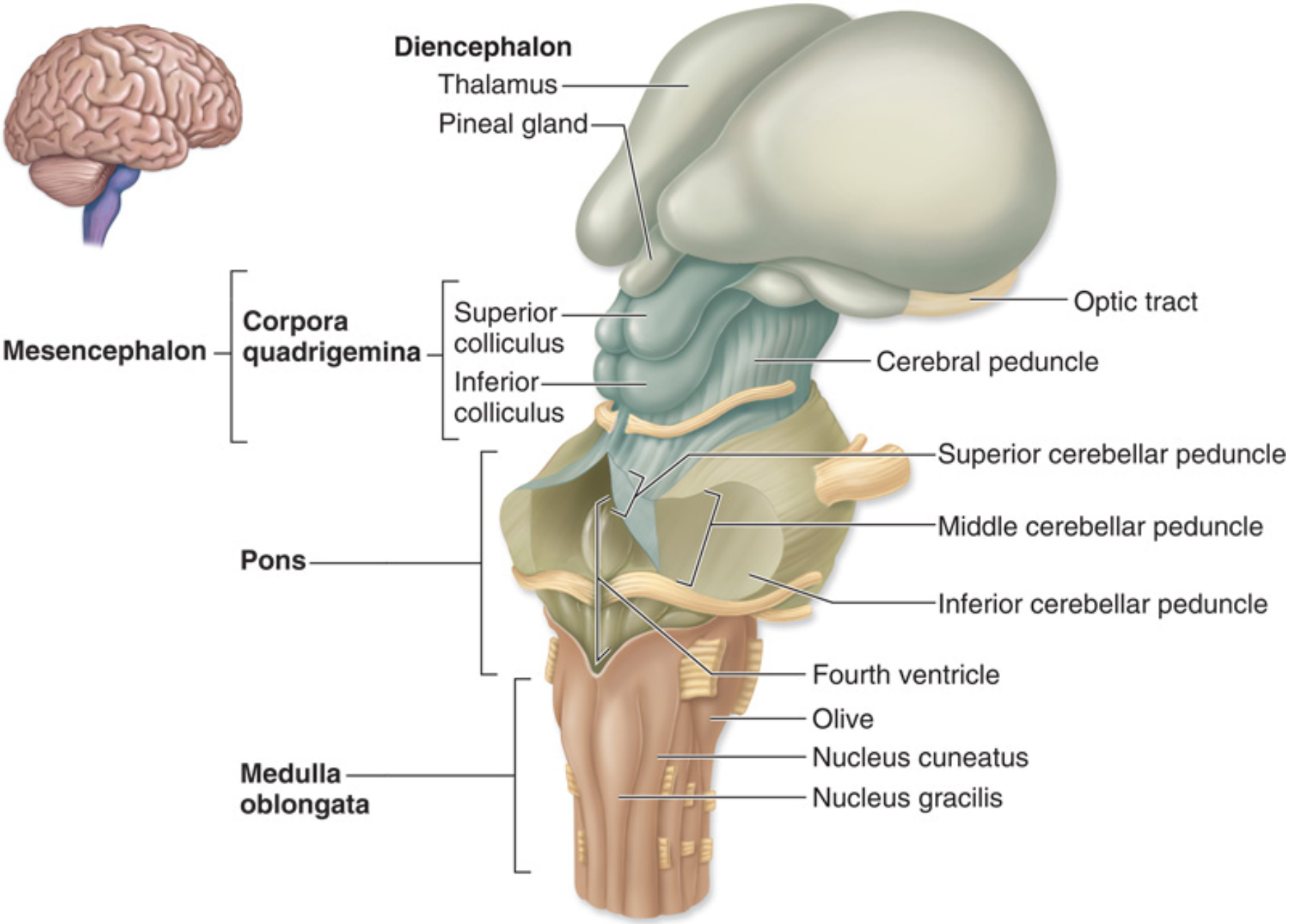

(b) Posterolateral view

The Brain Stem – The Midbrain

- Imbedded in the white matter of the midbrain
  - Two pigmented nuclei
  - Substantia nigra – neuronal cell bodies contain melanin
    - Functionally linked to the basal nuclei
  - Red nucleus – lies deep to the substantia nigra
    - Largest nucleus of the reticular formation

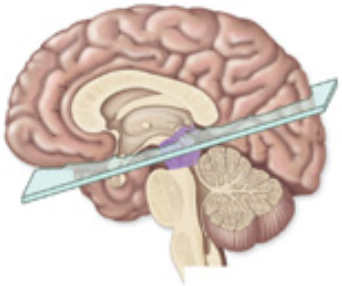

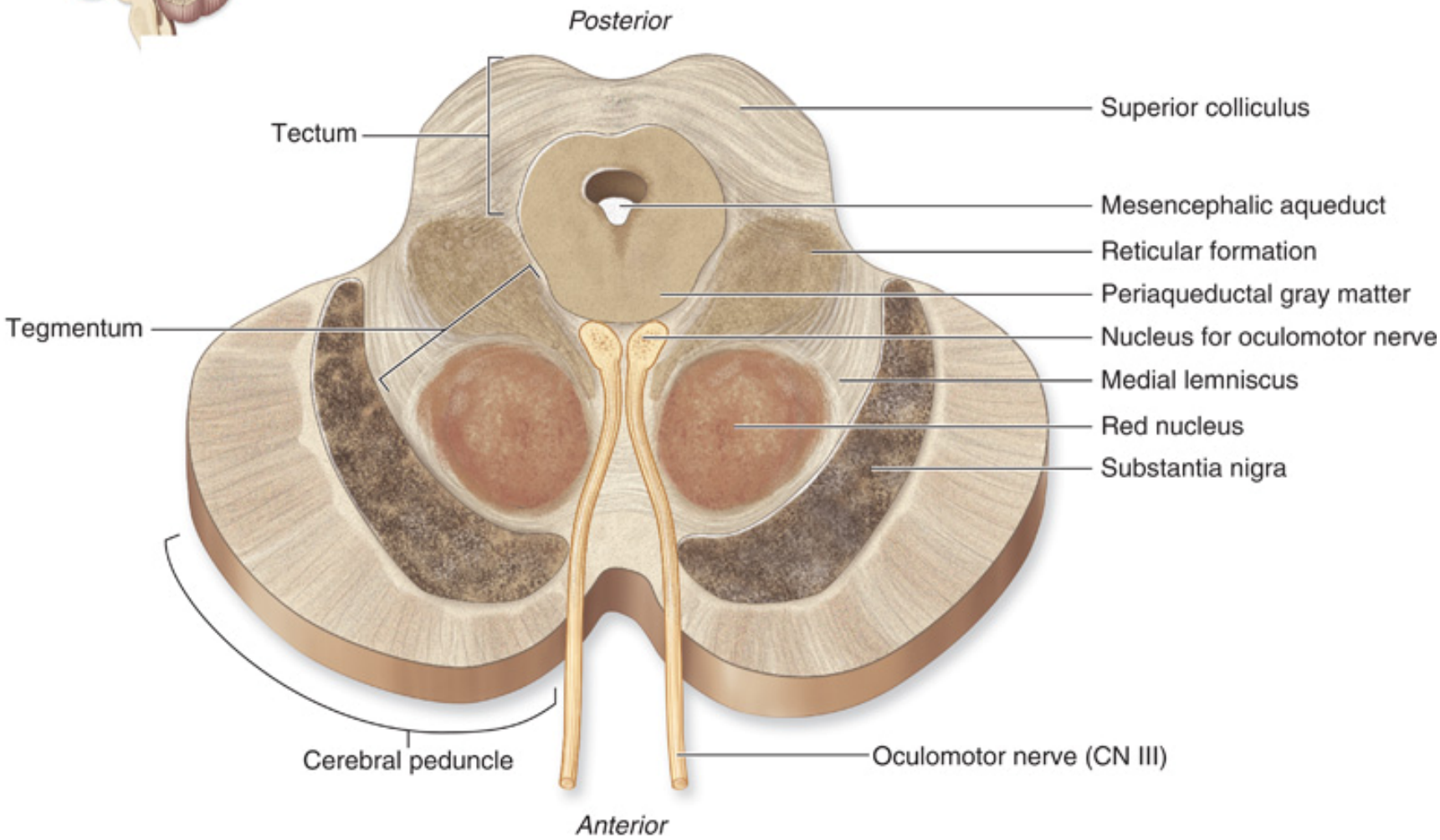

Cross-sectional view of mesencephalon

The Brain Stem – The Pons

- Located between the midbrain and medulla oblongata
- Contains the nuclei of cranial nerves V, VI, and VII
- Two general groups of cranial nerve nuclei
  - Motor nuclei
  - Sensory nuclei

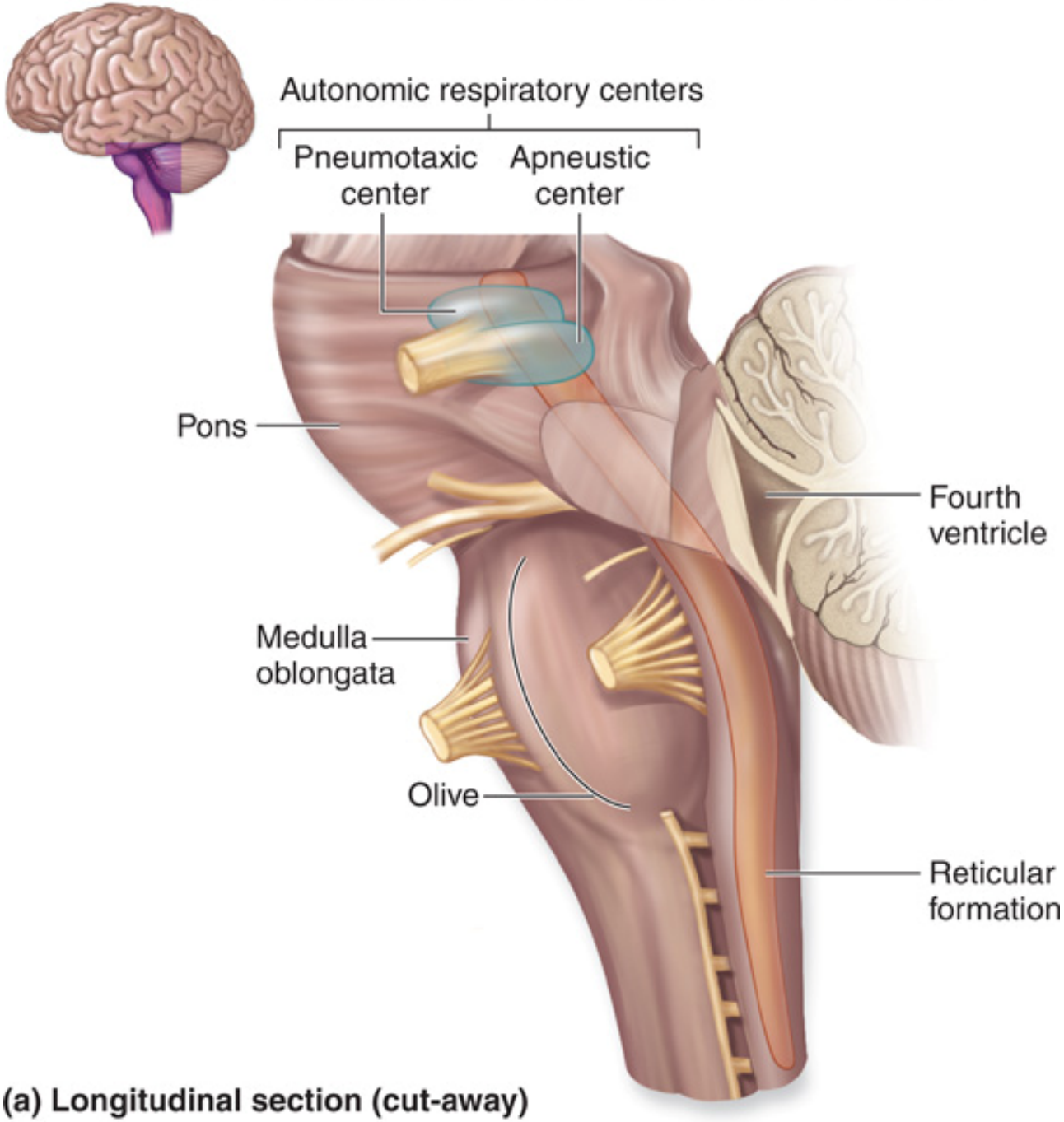

(a) Longitudinal section (cut-away)

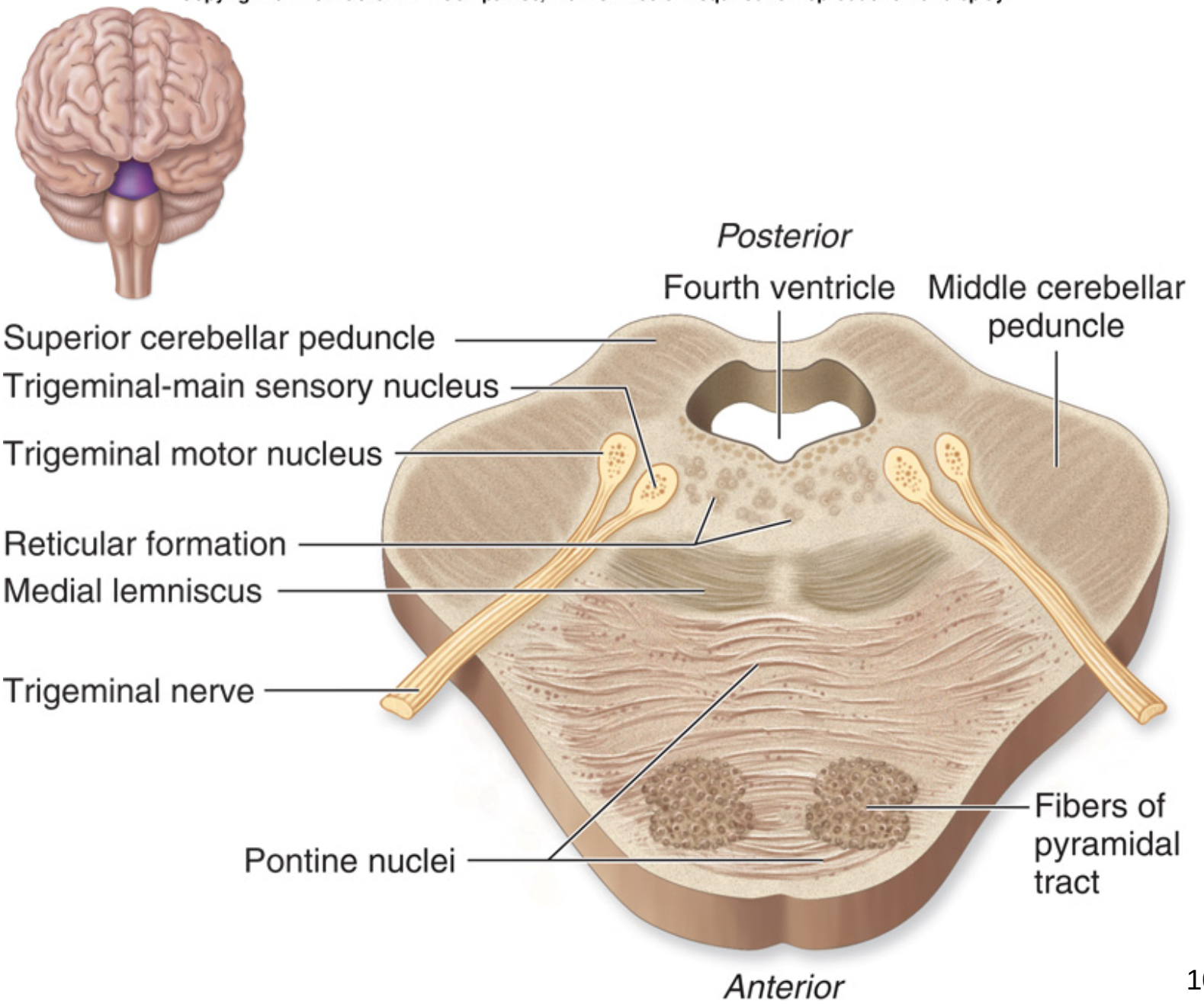

(b) Pons cross section

The Brain Stem – The Medulla Oblongata

- Most caudal level of the brain stem
  - Continuous with the spinal cord
  - **Choroid plexus** lies in the roof of the fourth ventricle
  - Pyramids of the medulla – lie on its ventral surface
    - Decussation of the pyramids – crossing over of motor tracts
  - Cranial nerves VIII–XII attach to the medulla

The Brain Stem – The Medulla Oblongata

- The core of the medulla contains:
  - Much of the reticular formation
    - Nuclei influence autonomic functions
  - Visceral centers of the reticular formation include:
    - Cardiac center
    - Vasomotor center
    - The medullary respiratory center
    - Centers for hiccupping, sneezing, swallowing, and coughing

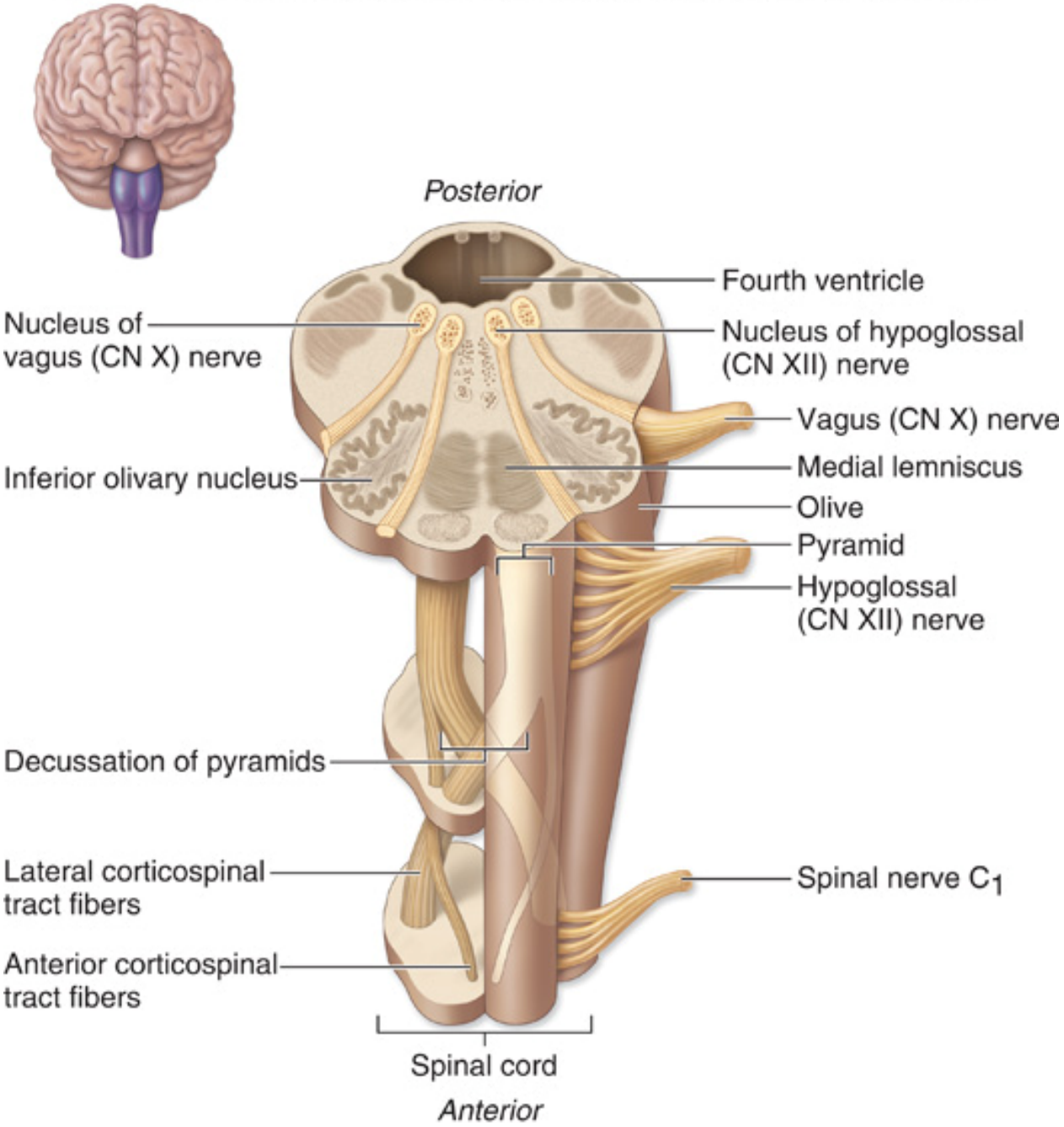

(a) Medulla oblongata, cross-sectional view

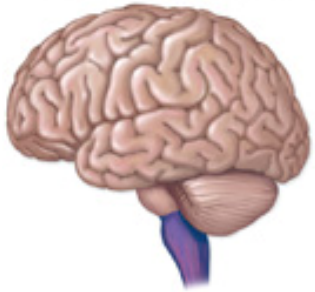

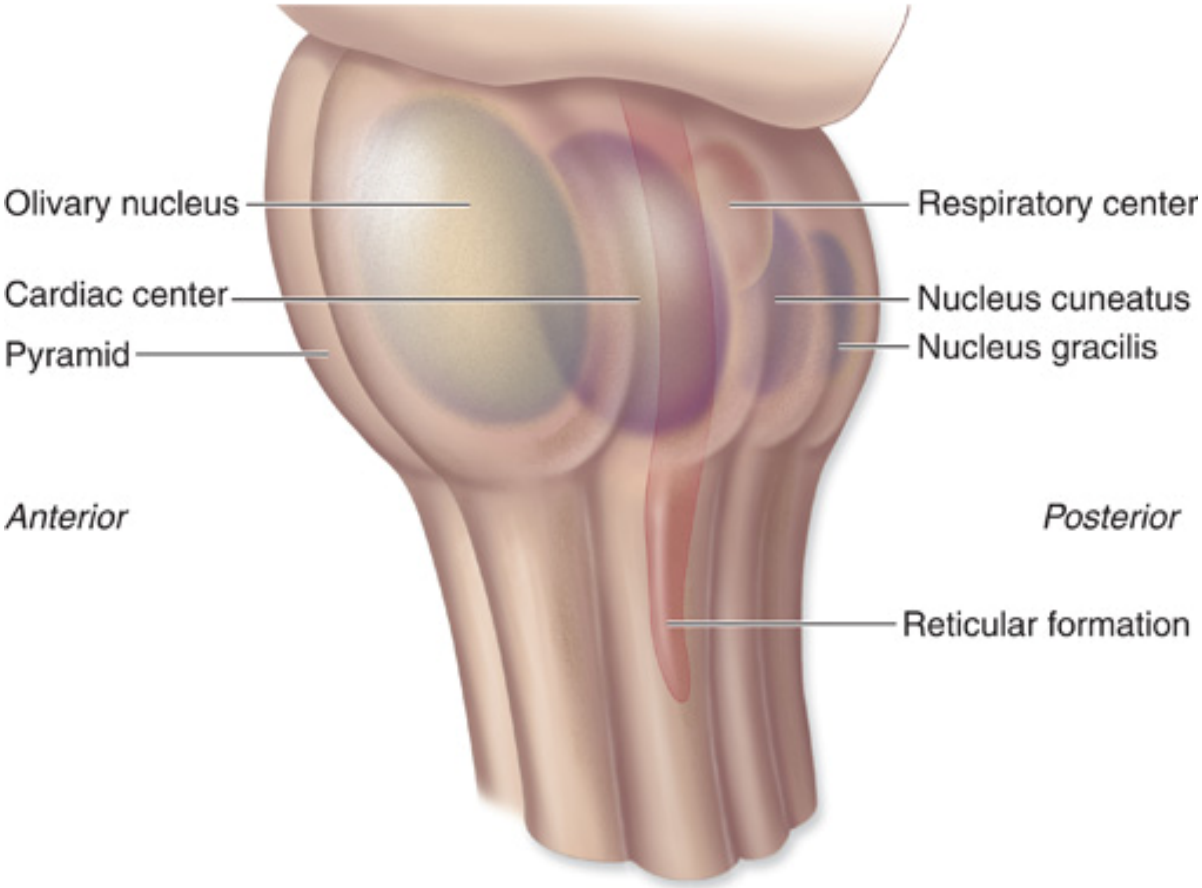

(b) Medulla oblongata, lateral view

The Cerebellum

- Located dorsal to the pons and medulla
  - Smoothes and coordinates body movements
  - Helps maintain equilibrium

The Cerebellum

- Consists of two cerebellar hemispheres
- Surface folded into ridges called **folia**
  - Separated by fissures
- Hemispheres each subdivided into:
  - Anterior lobe
  - Posterior lobe

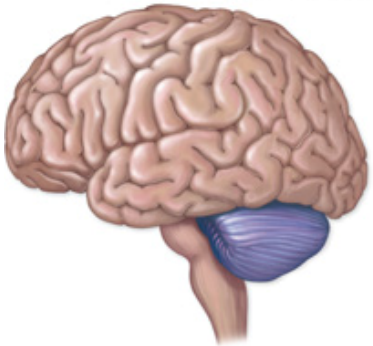

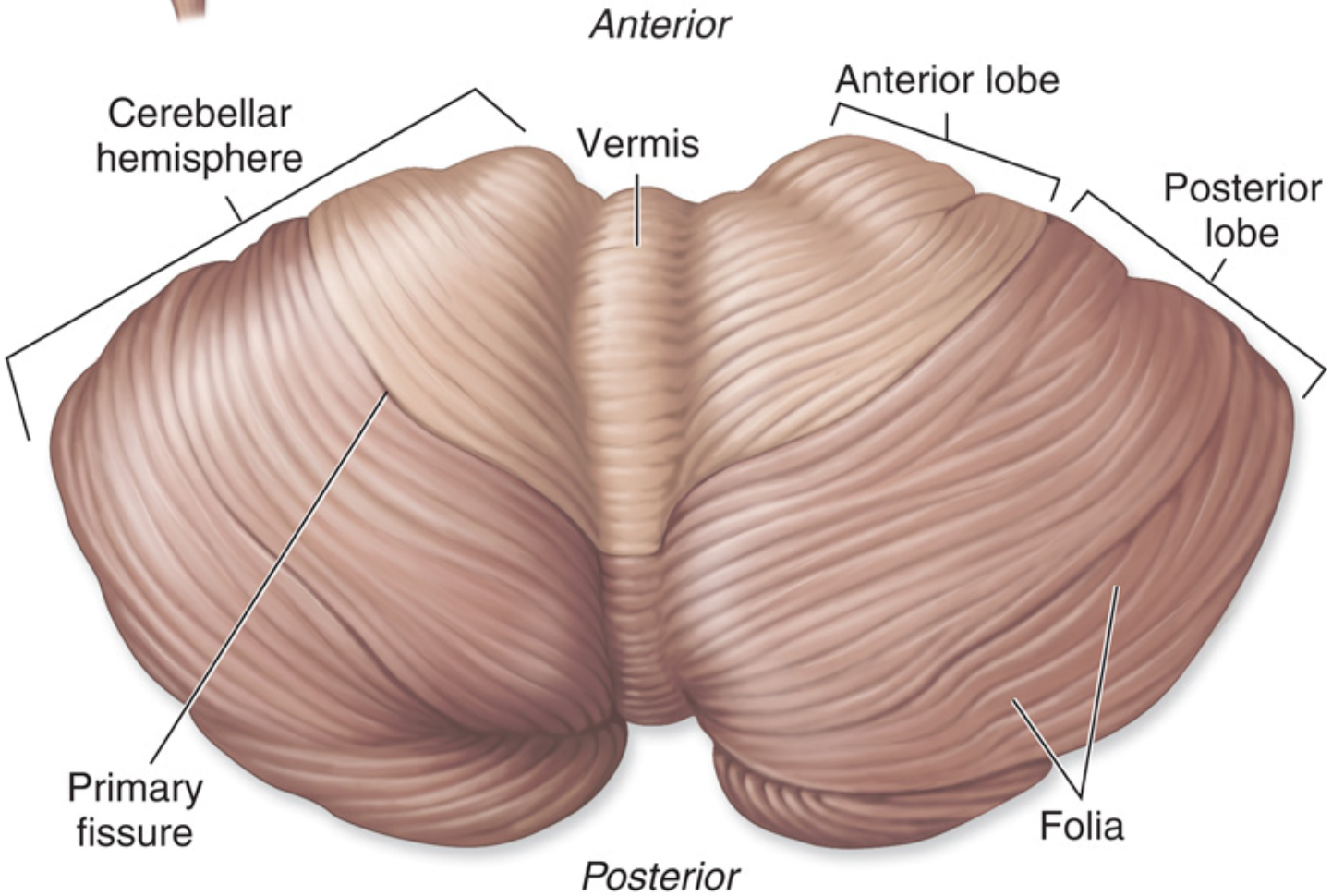

(b) Cerebellum, superior view

The Cerebellum

- Composed of three regions
  - Cortex – gray matter
  - Internal white matter
  - Deep cerebellar nuclei – deeply situated gray matter
- Cerebellum must receive information
  - On equilibrium
  - On current movements of limbs, neck, and trunk
  - From the cerebral cortex

The Cerebellum – Cerebellar Peduncles

- Fibers to and from the cerebellum are **ipsilateral**
  - Run to and from the *same* side of the body
- Thick tracts connecting the cerebellum to the brain stem
  - Superior cerebellar peduncles
  - Middle cerebellar peduncles
  - Inferior cerebellar peduncles

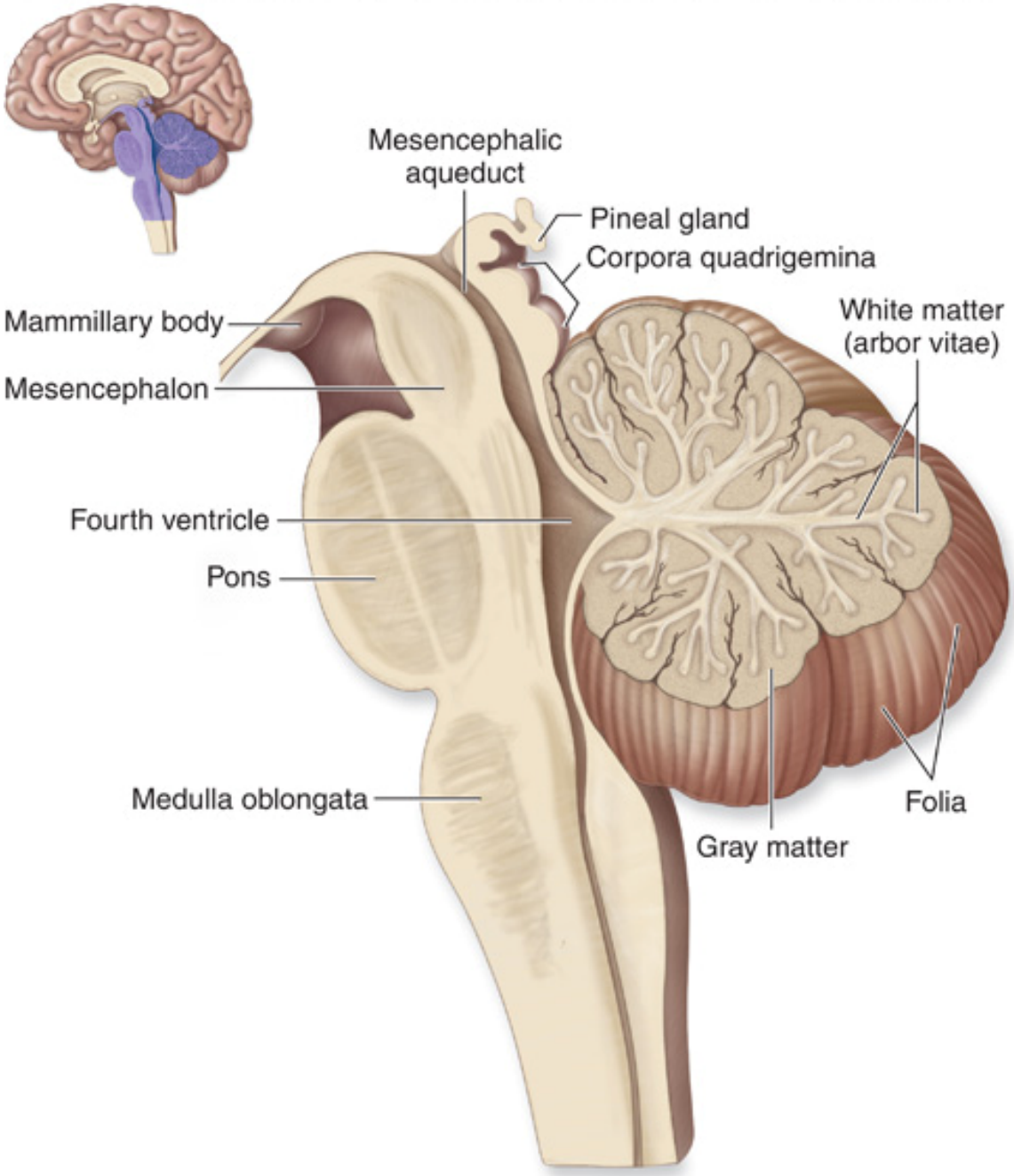

(a) Midsagittal section

Functional Brain Systems

- Networks of neurons functioning together
  - The limbic system – spread widely in the forebrain
  - The reticular formation – spans the brain stem

Functional Brain Systems – The Limbic System

- Location
  - Medial aspect of cerebral hemispheres
  - Also within the diencephalon
- Composed of:
  - Septal nuclei, cingulate gyrus, and hippocampal formation
  - Part of the amygdala
- The fornix and other tracts link the limbic system together

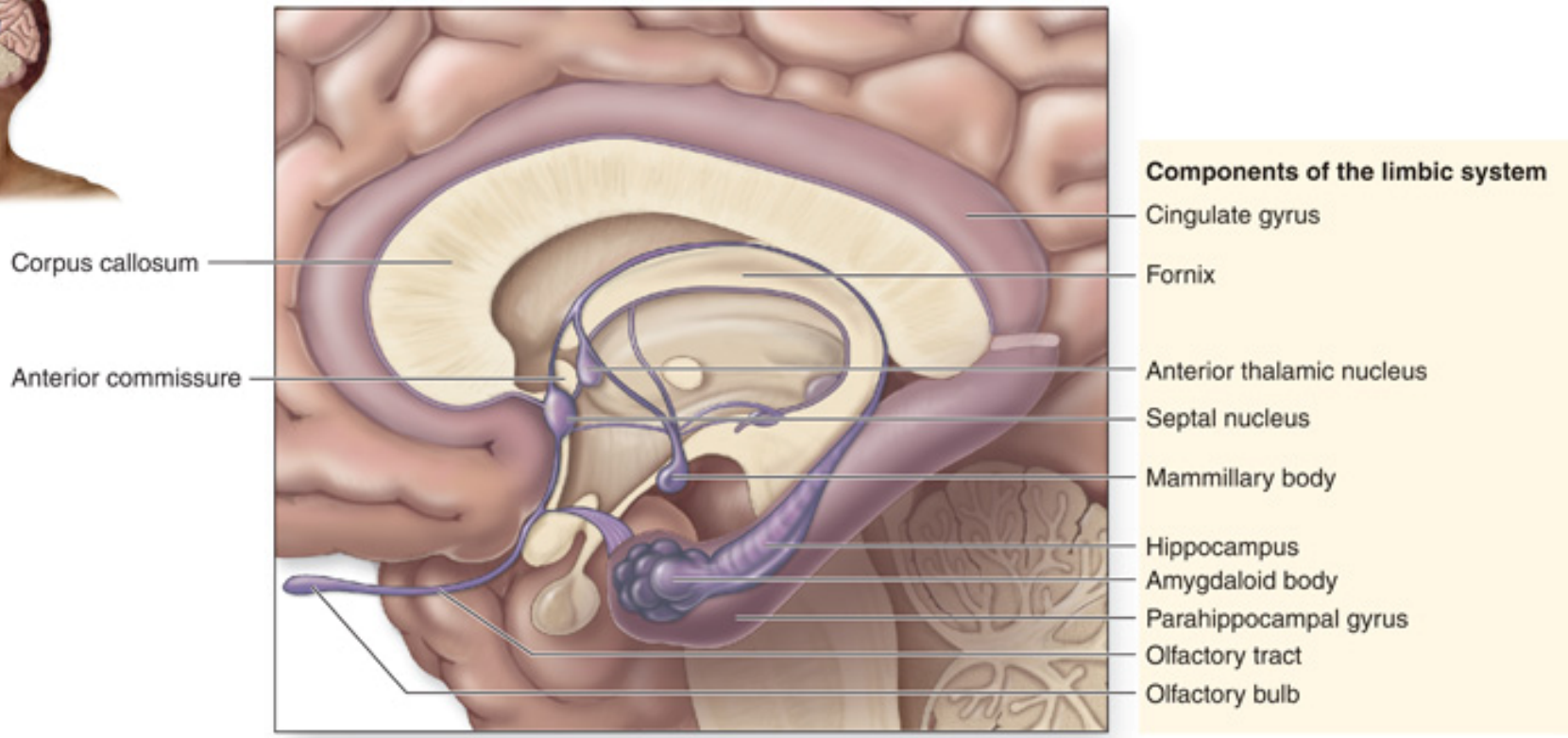

Midsagittal section

Functional Brain Systems – The Limbic System

- The “emotional brain”
  - Cingulate gyrus
    - Allows us to shift between thoughts
    - Interprets pain as unpleasant
- Hippocampal formation
  - Hippocampus and the parahippocampal gyrus

Functional Brain Systems – The Reticular Formation

- Runs through the central core of the medulla, pons, and midbrain
- Forms three columns
  - Midline raphe nuclei
  - Medial nuclear group
  - Lateral nuclear group

Functional Brain Systems – The Reticular Formation

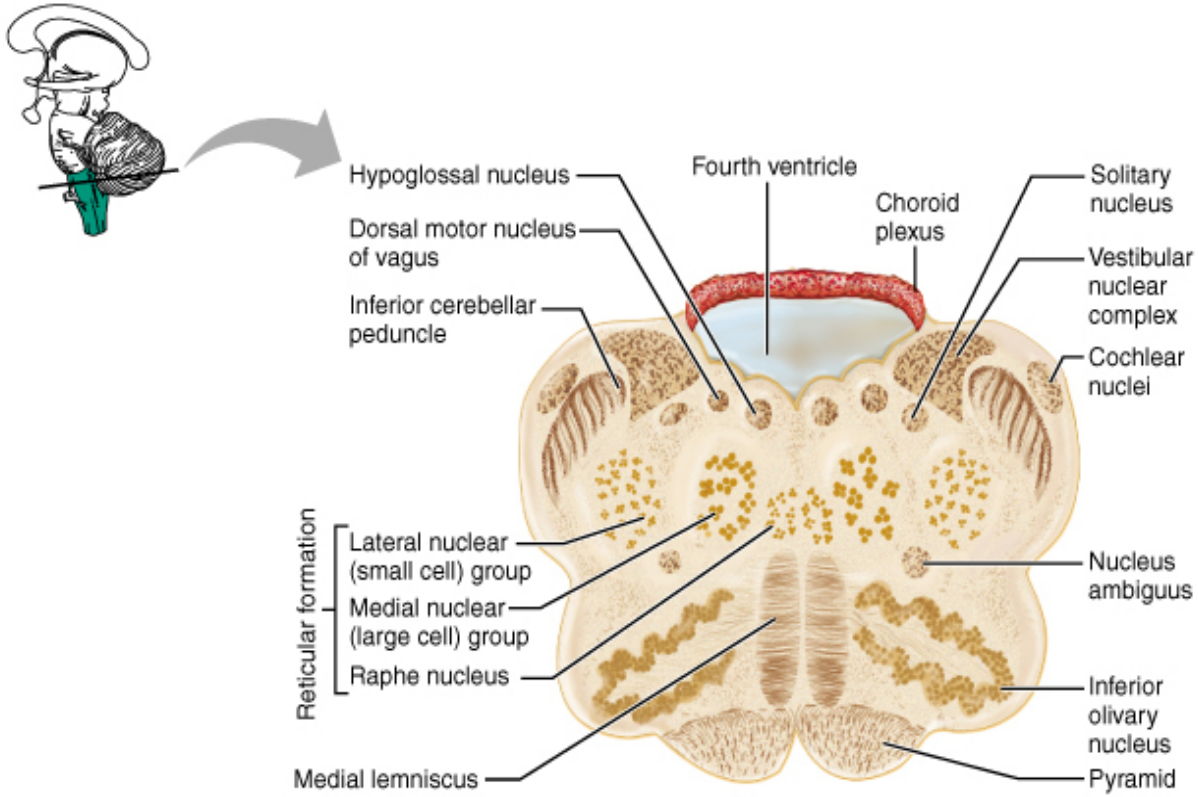

(c) Medulla oblongata

Functional Brain Systems – The Reticular Formation

- Widespread connections
  - Ideal for arousal of the brain as a whole
- Reticular activating system (RAS)
  - Maintains consciousness and alertness
  - Functions in sleep and arousal from sleep

Functional Brain Systems – The Reticular Formation

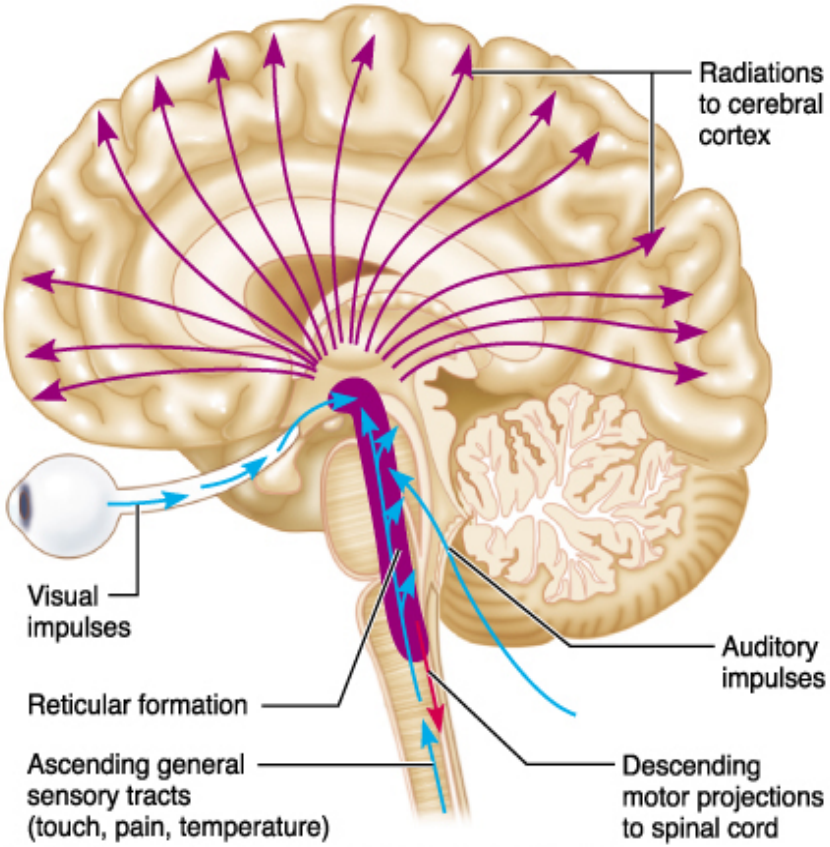

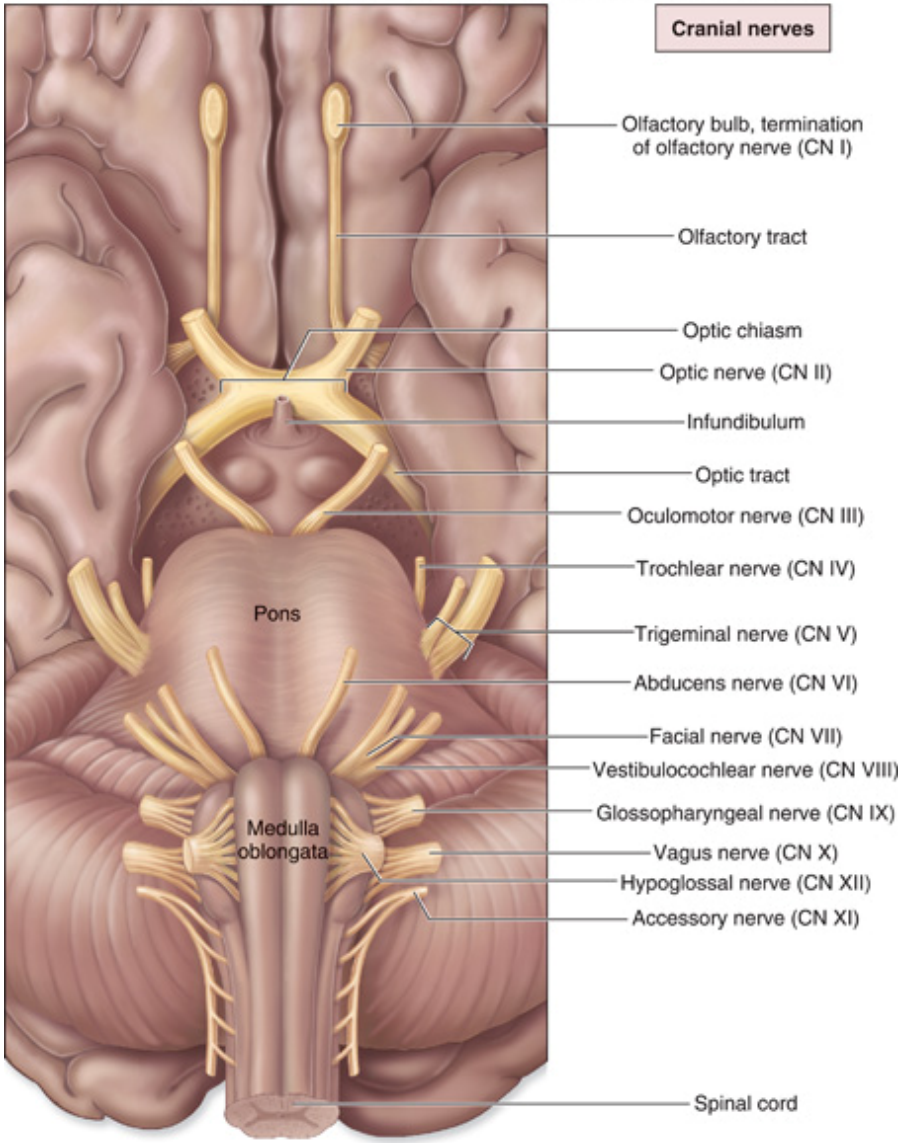

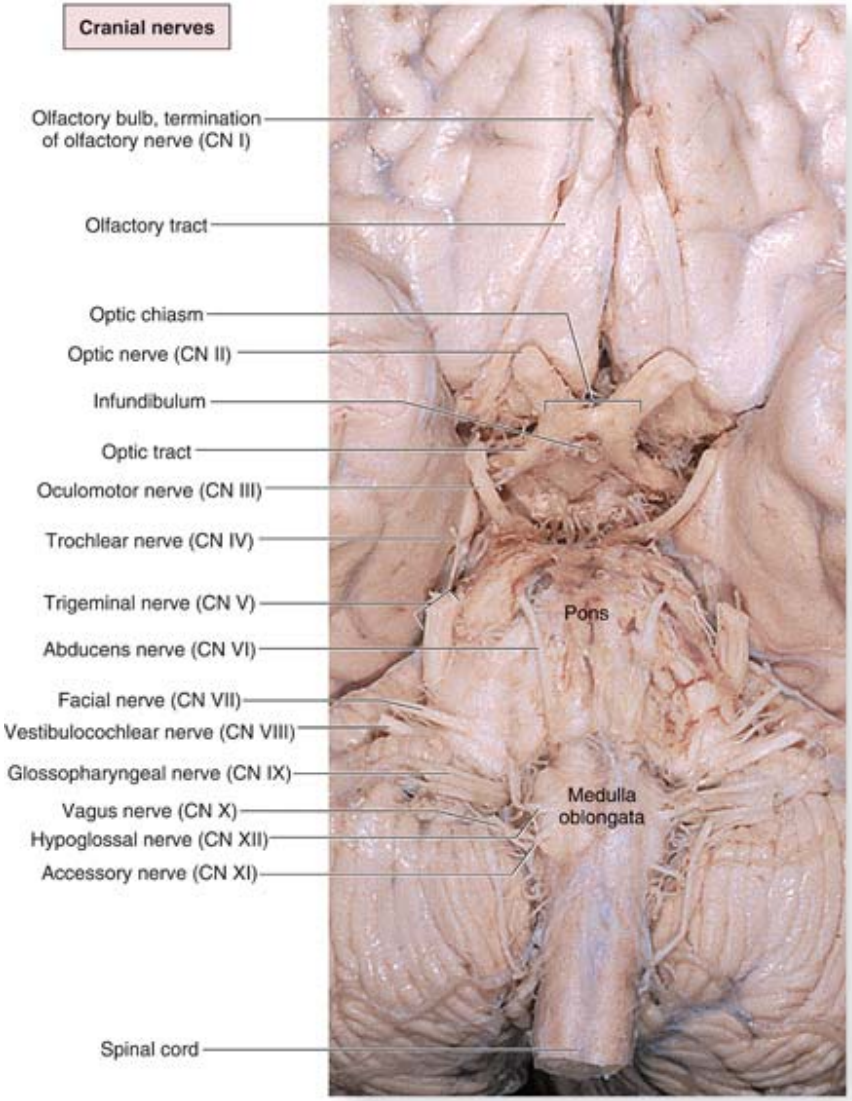

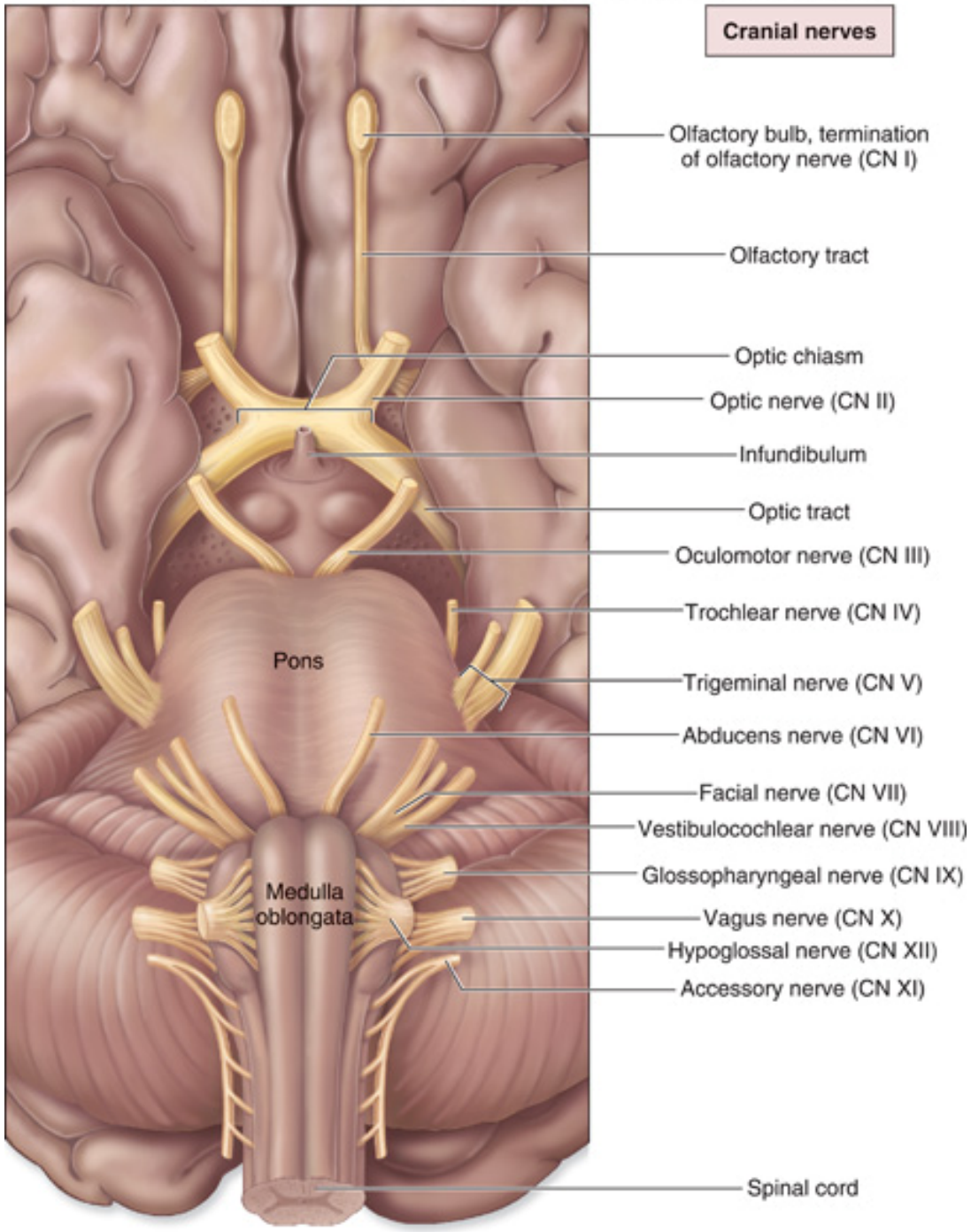

Cranial nerves