Skull, Brain and Cranial Nerves

Head and Neck Continued

Skull

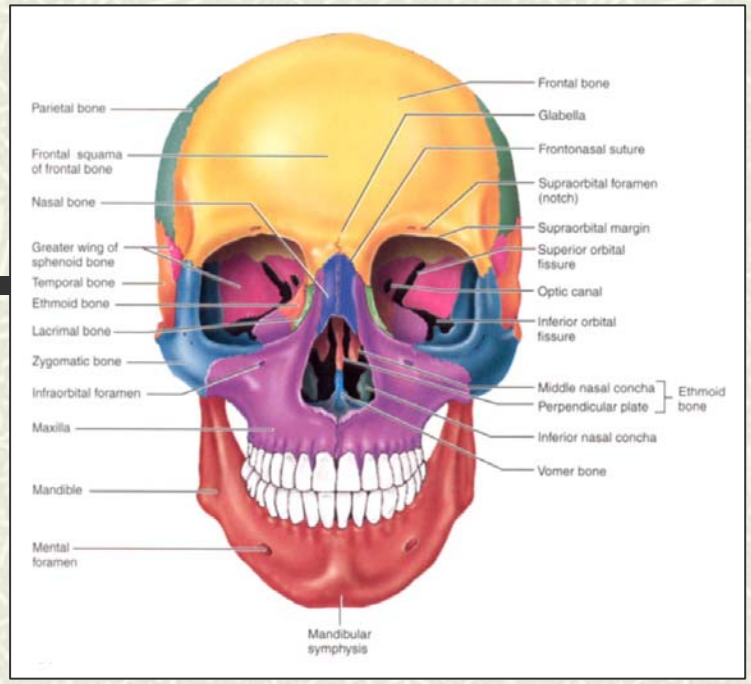

- Part of Axial Skeleton
- Cranial bones = cranium
  - Enclose and protect brain
  - Attachment for head + neck muscles
- Facial bones =framework of face
  - Form cavities for sense organs
  - Opening for air + food passage
  - Hold teeth
  - Anchor face muscles

pg 149

Bones of Skull

- Flat bones: thin, flattened, some curve
- Sutures: immovable joints joining bones
- Calvaria = Skullcap =Vault
  - Superior, Lateral, Posterior part of skull
- Floor = Base
  - Inferior part of skull
- 85 openings in skull
  - Spinal cord, blood vessels, nerves

Cranial Fossae

- Created by bony ridges
- Supports, encircles brain
- 3 Fossae
  - Anterior
  - Middle
  - Posterior
- Other small cavities in skull
  - Middle Ear, Inner Ear
  - Nasal
  - Orbit

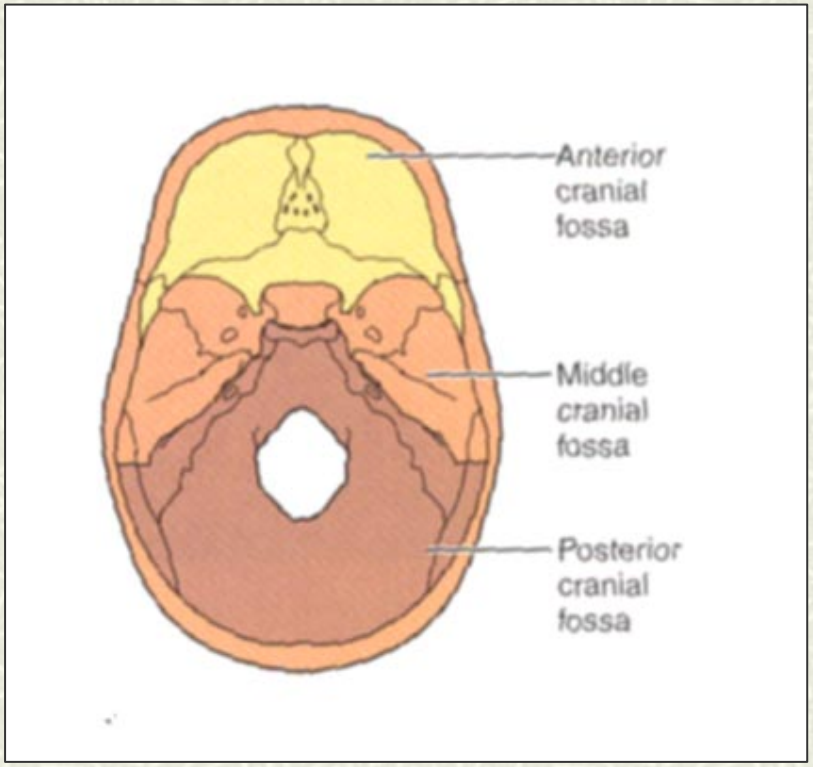

pg 153

Skull through Life

- Ossifies late in 2nd month of development
- Frontal + Mandible start as 2 halves-then fuse
- Skull bones separated by unossified membranes = **Fontanels**
  - Allow compression of skull during delivery
  - Mostly replaced w/bone after 1st year
- Growth of Skull
  - ½ adult size by age 9 months
  - ¾ adult size by 2 years
  - 100% adult size by 8-9 years
  - Face enlarges between ages 6-13 years

The Brain

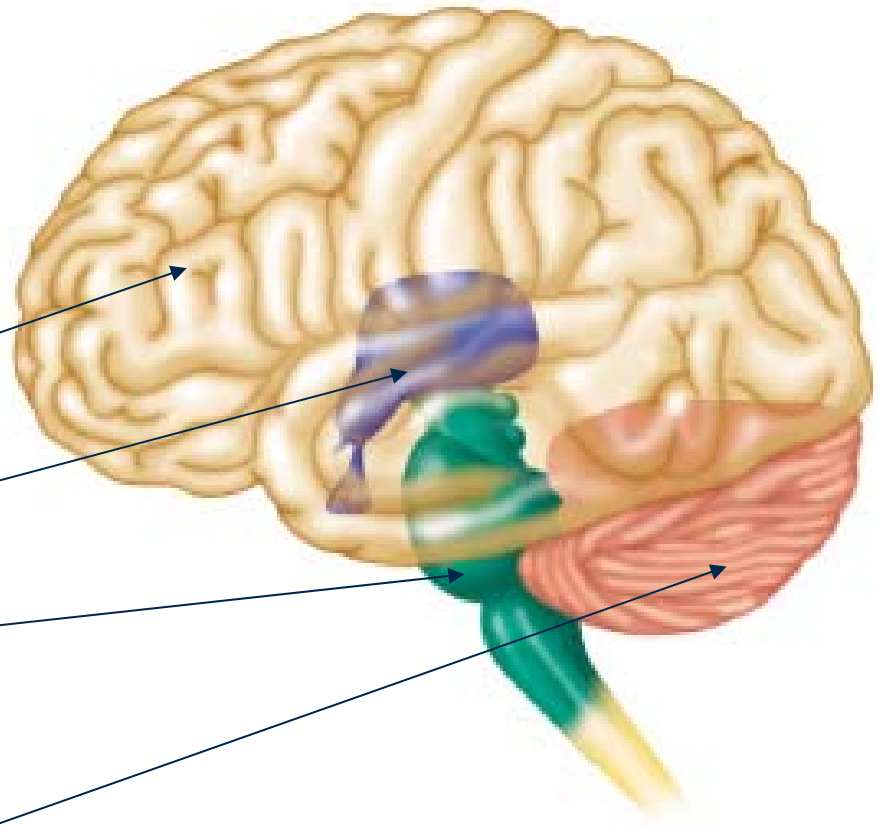

- 4 Parts
  - Cerebrum
  - Diencephalon
  - Brain Stem
    - Pons
    - Medulla
    - Midbrain
  - Cerebellum
- Gray matter surrounded by White matter

Cummings.

Meninges: 3 membranes around brain and spinal cord

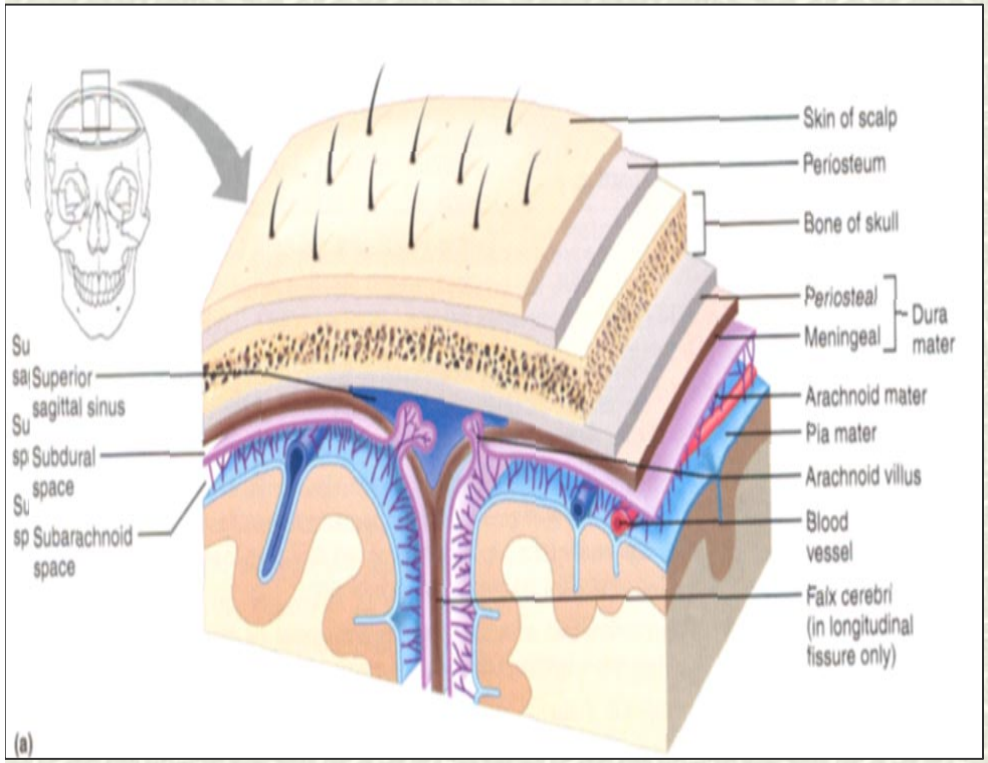

pg 375

- Made of Connective tissue
- Functions
  - Cover, Protect CNS
  - Enclose, protect blood vessels supplying CNS
  - Contain CSF
- 3 Layers
  - Dura Mater (external)
  - Arachnoid Mater (middle)
  - Pia Mater (internal)

Meninges (continued)

- Dura mater
  - Strongest, 2 Layers, Fibrous Connective Tissue
    - Periosteal layer (Periosteum): External/superficial layer
    - Meningeal layer: Internal/deep layer
  - Layers fused except around dural sinuses (venous blood filled→ internal jugular vein)
  - **Partitions: limit movement of brain**
    - **Falx Cerebri** –vertical, between cerebral hemispheres
    - **Falx Cerebelli** -vertical, between cerebellar hemispheres
    - **Tentorium Cerebelli** –horizontal, between cerebrum and cerebellum

Meninges

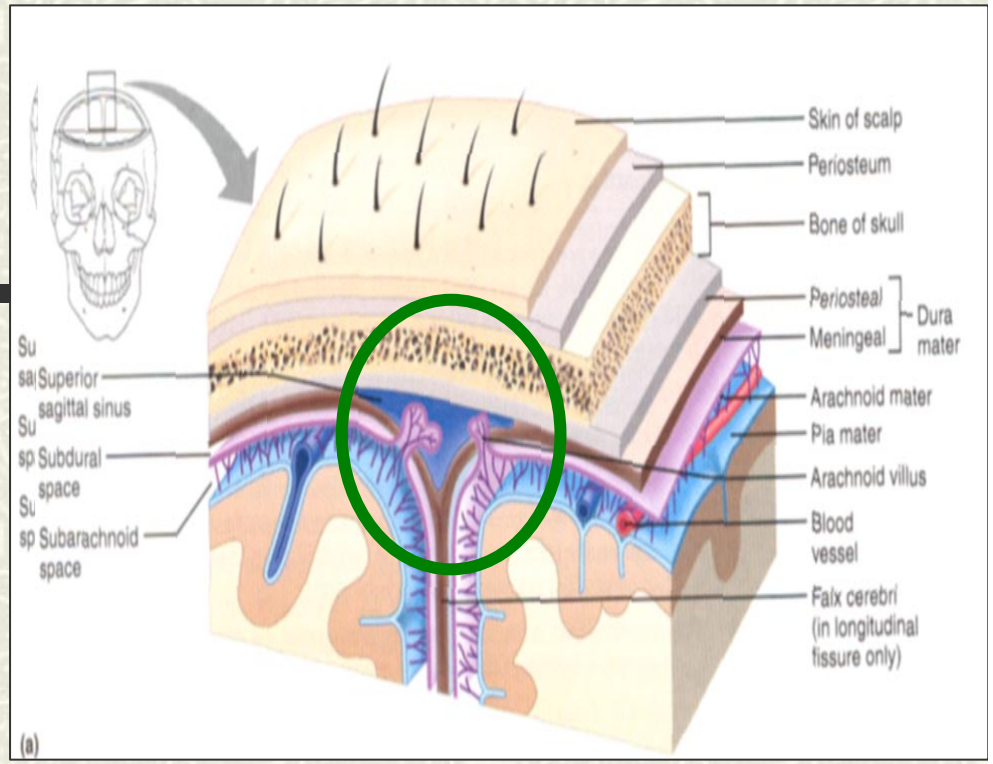

- Arachnoid Mater
  - Middle layer
  - Subarachnoid Space-between arachnoid mater and pia mater (contains most of CSF, blood vessels)
  - Arachnoid Villi- projections of arachnoid mater through dura into superior sagittal sinus, act as valves to help CSF pass into dural sinuses

Meninges (continued)

- Pia Mater
  - Innermost layer
  - Delicate, highly vascular
  - Clings directly to brain tissue, dips into convolutions

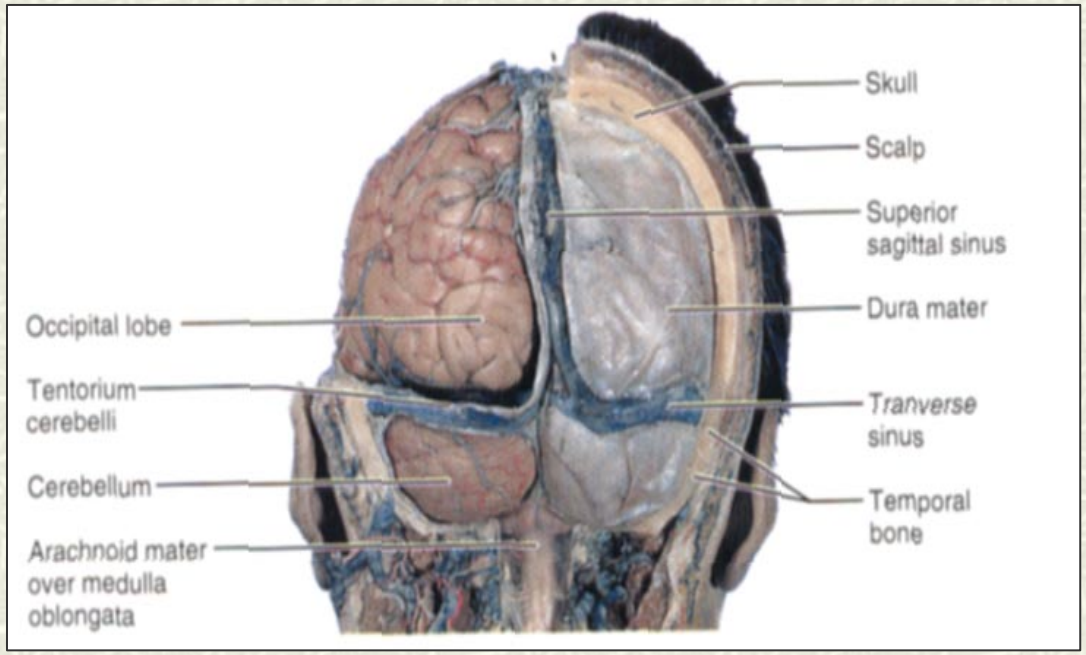

pg 375

Ventricles

- Expansions of brain's central cavity
- Lined with Ependymal Cells
- Filled with CSF (cerebrospinal fluid)
- Ventricles continuous w/each other + central canal of spinal cord

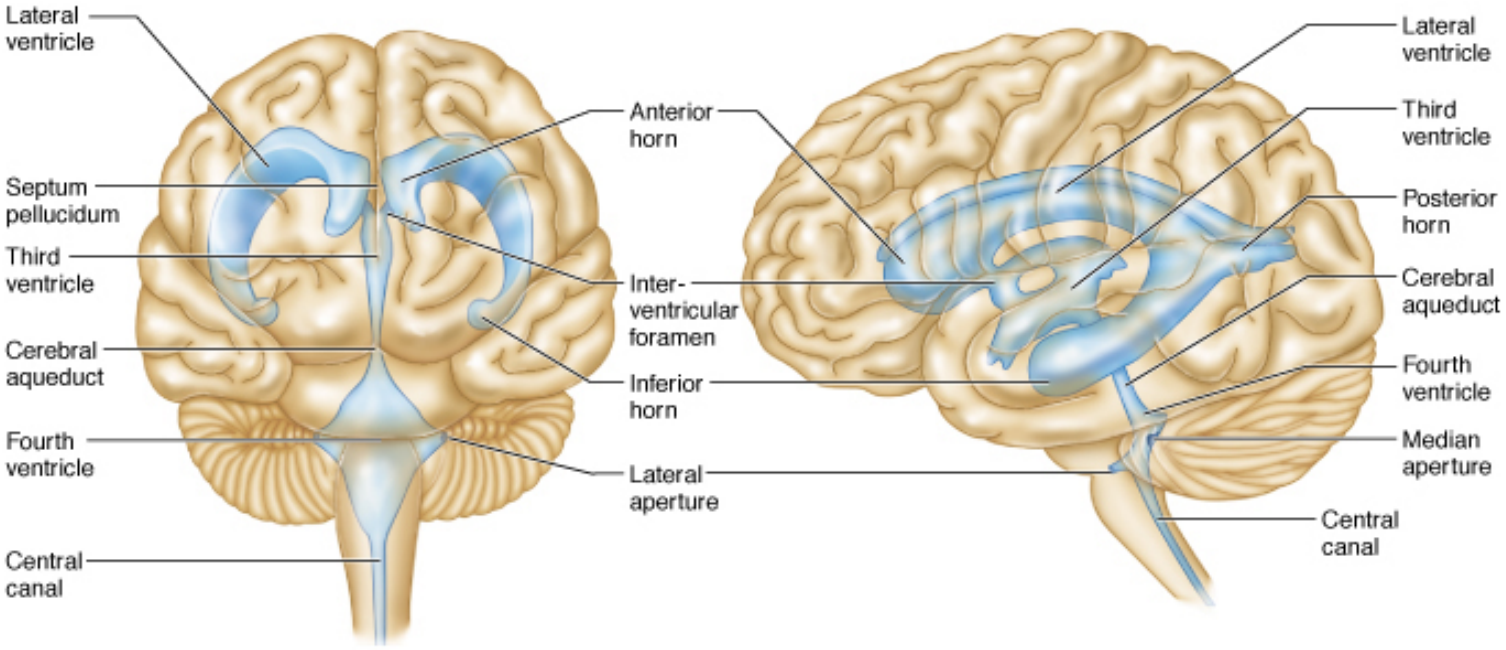

(a) Anterior view (b) Left lateral view

pg 376

Ventricles (continued)

- Lateral Ventricles (#1+2)
  - Cerebral Hemisphere
  - Separated by Septum Pellucidum
- Third Ventricle
  - Diencephalon
  - Interventricular Foramen: connects to lateral ventricle
- Fourth Ventricle
  - Hindbrain
  - Cerebral Aqueduct: connects 3rd and 4th ventricles
  - Connects to central canal of spinal cord & medulla
  - 3 openings connect 4th to subarachnoid space
    - 2 lateral apertures
    - 1 median aperture

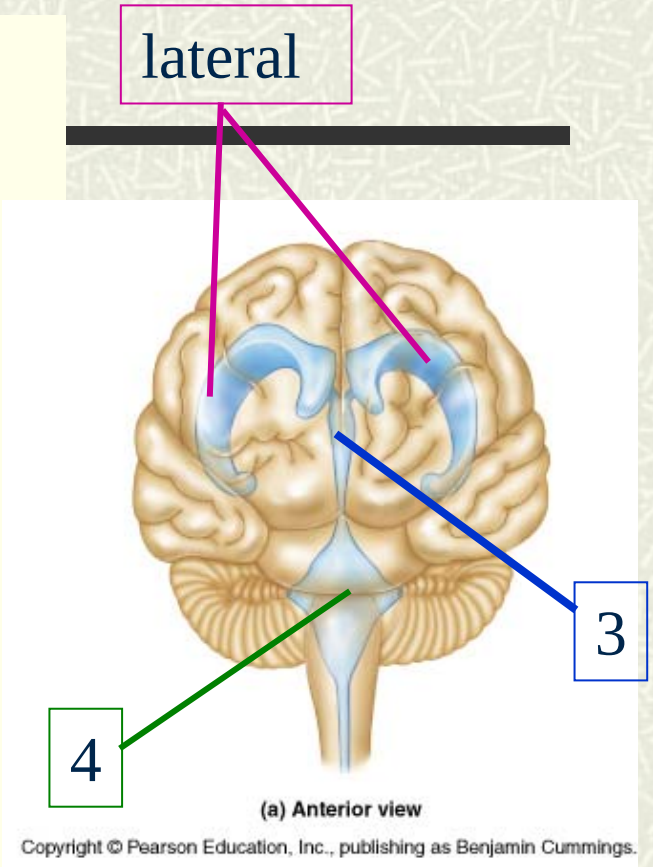

pg 376

Cerebrospinal Fluid

- Liquid cushion for brain and spinal cord
- Nourishes brain
- Removes waste
- Conducts chemical signals between parts of CNS (e.g. hormones)
- Forms as a filtrate of blood in choroid plexuses

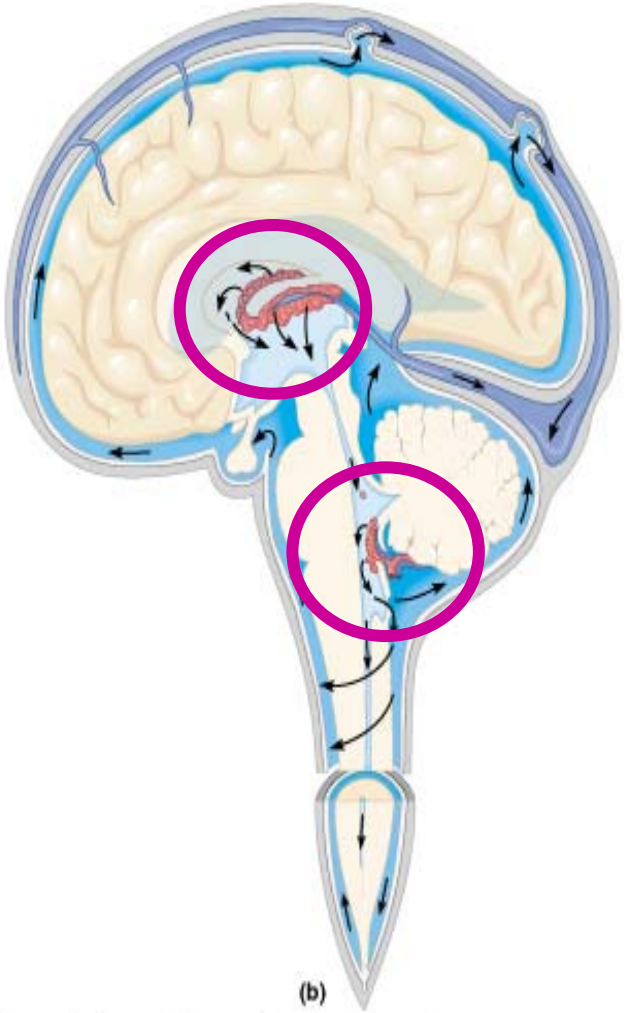

pg 376

Choroid Plexuses

- **Choroid Plexuses**: groups of capillaries surrounded by ependymal cells
- Made of sodium, chloride ions, proteins, glucose, O_2

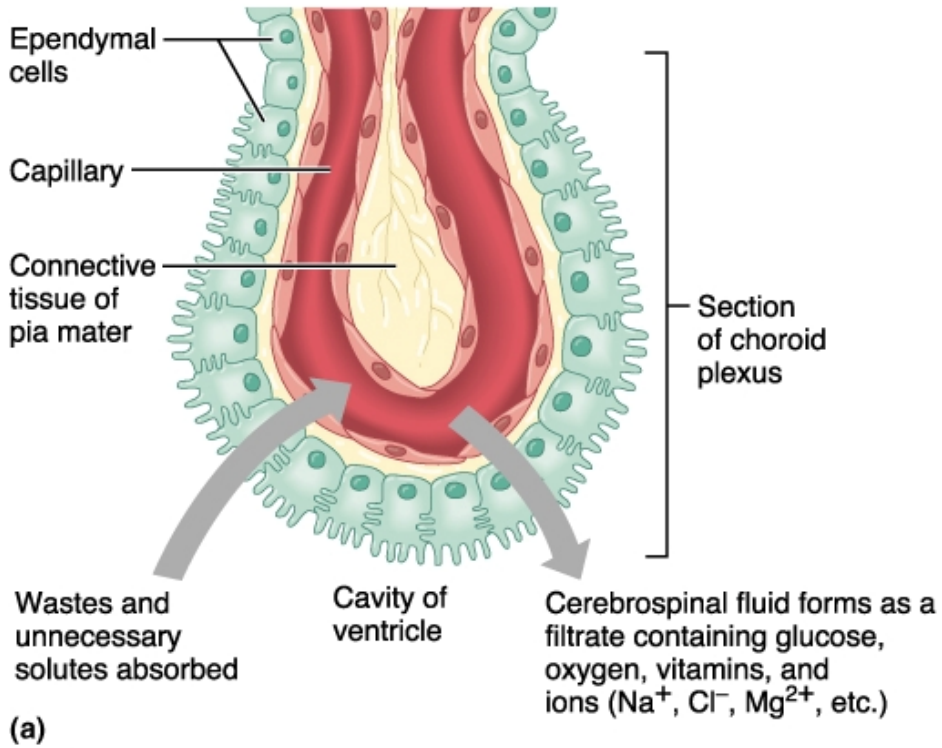

Flow of CSF

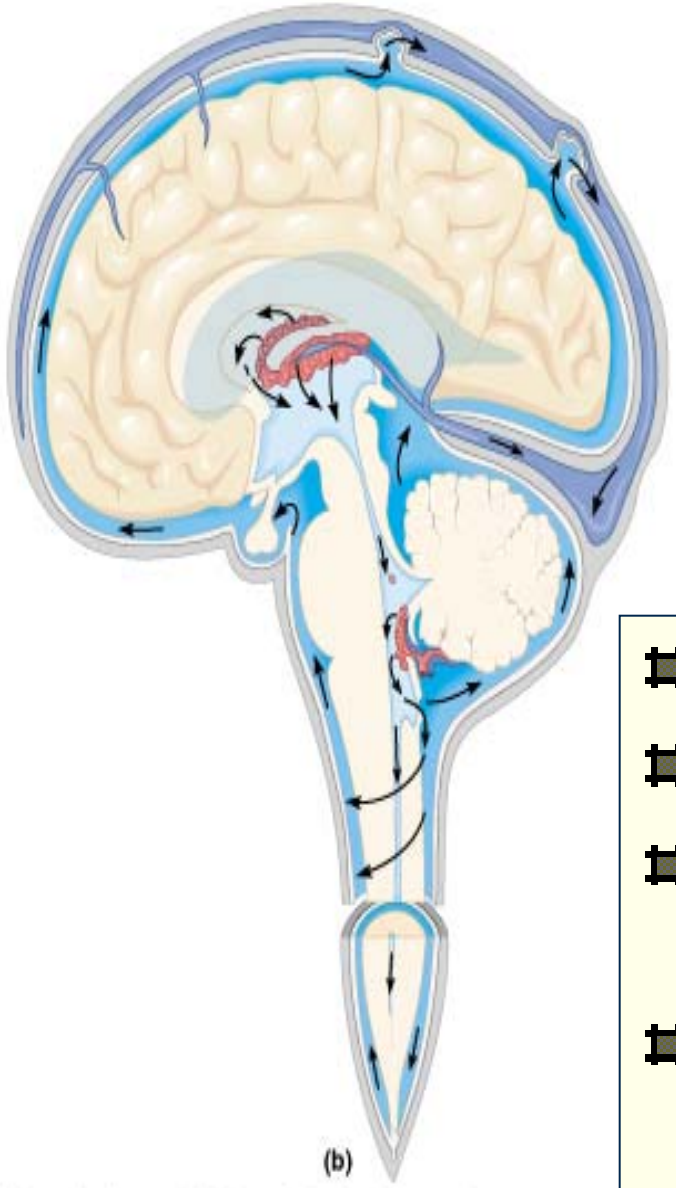

- Formed in Choroid plexuses
- Through Ventricles
- Into Subarachnoid space & central canal from 4th ventricle
- Through Arachnoid Villi into Superior Sagittal Sinus
- Into Internal Jugular Vein

Organization of the Brain

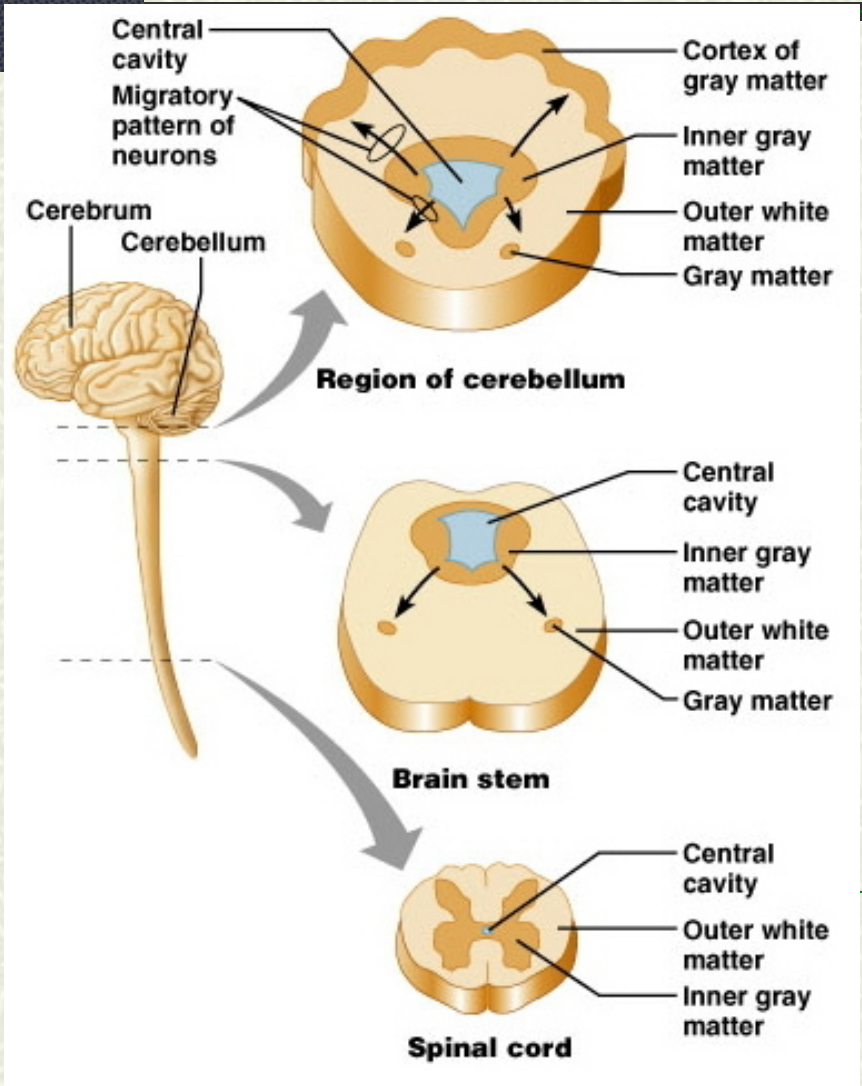

- Composed of gray and white matter
- Different organization than in the spinal cord
  - Cortex: external sheets of gray matter in cerebrum & cerebellum
  - Nuclei: deep masses of gray matter surrounded by white matter

Cerebrum

- "Executive Suite" of nervous system
  - Self-awareness, initiate + control voluntary movements, communicate, remember, understand
- Made of Gray matter, White matter, Basal gangli (nuclei)
- Most superior region
- Covers diencephalon + top of brain stem like mushroom cap
- Many small grooves + deep fissures
  - Transverse-separates cerebral hemisphere + cerebellum
  - Longitudinal-separates right + left cerebral hemispheres
- Sulci – grooves on surface
- Gyri-ridges of brain tissue between sulci

Cerebral Hemispheres:

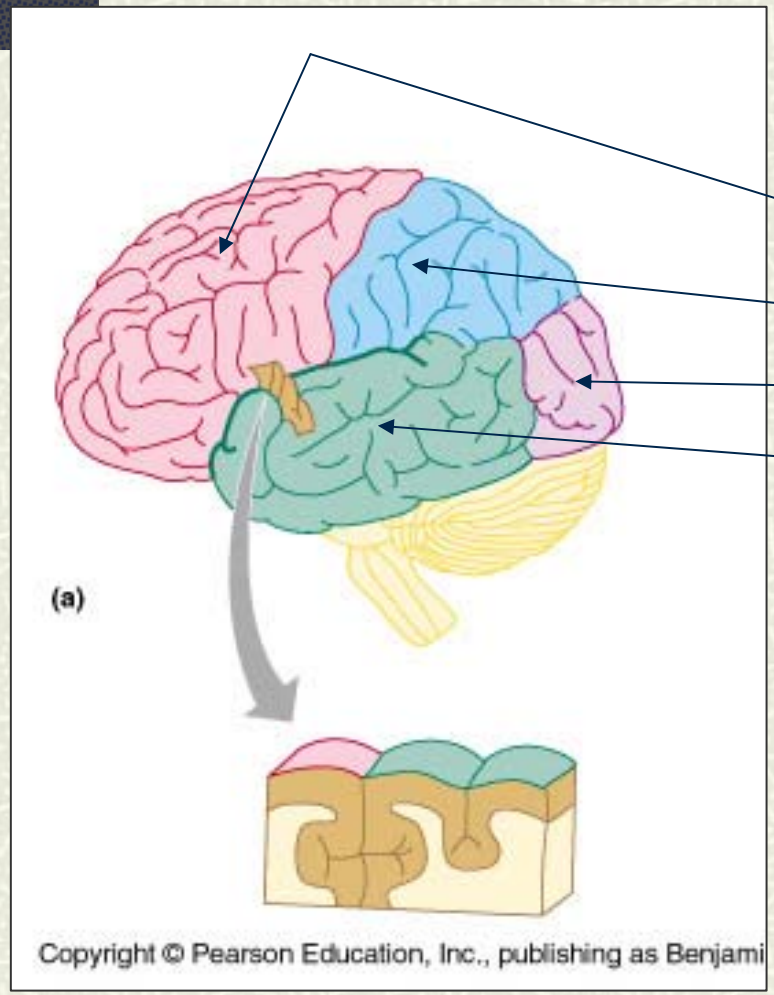

- Each hemisphere divided into 5 lobes
  - Frontal
  - Parietal
  - Occipital
  - Temporal
  - Insula
- Created by deep sulci
- Functional areas: motor, sensory
- Associative areas: integrate

pg 349

Diencephalon

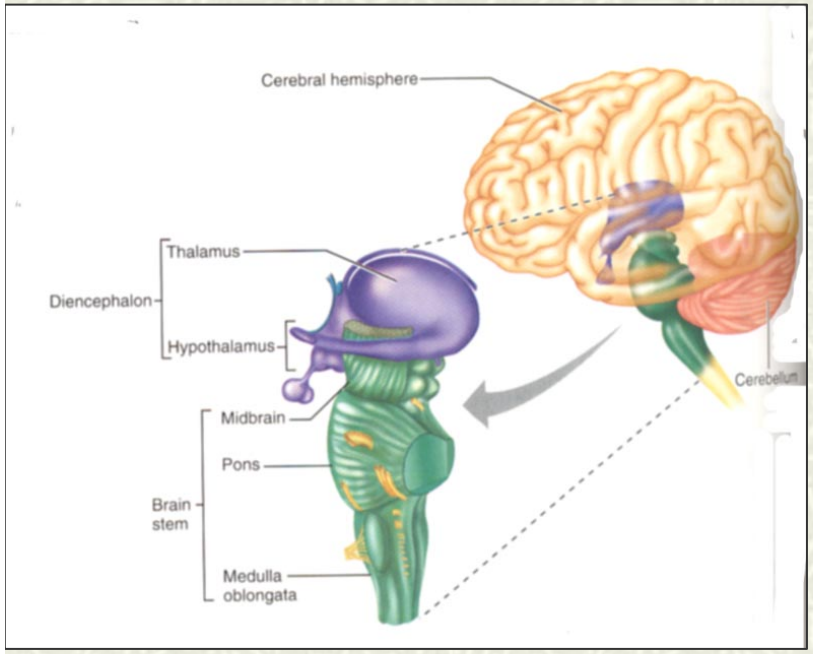

- Surrounded by cerebral hemispheres
- Made of 3 Paired Structures
  - **Thalamus**
    - Communicates sensory info of cerebral cortex
  - **Hypothalamus**
    - Regulates many body activities
    - Emotion, sleep, memory, etc.
    - Pituitary Gland-hormones
  - **Epithalamus**
    - Pineal Gland-hormone

pg 366

Brainstem:

- Medulla Oblongata, Pons, Midbrain
- Passage of all signals between spinal cord and brain

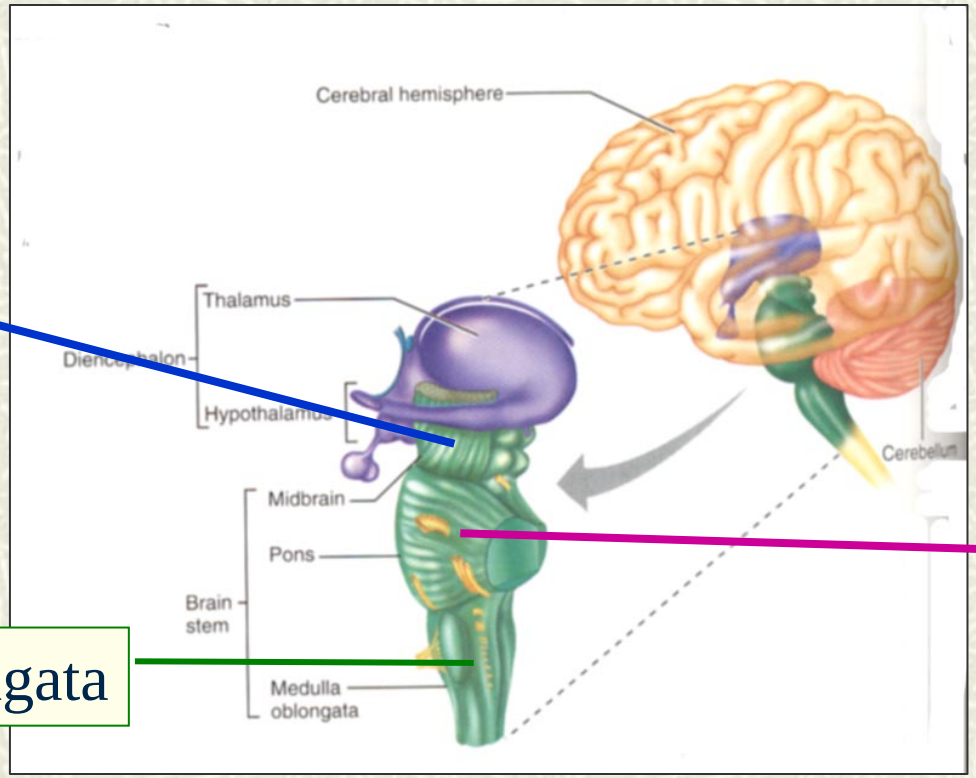

Midbrain

Pons

Medulla oblongata

pg 366

Brainstem: Medulla Oblongata

- Regulates several basic physiological functions
  - Heartbeat (rate and force)
  - Blood pressure (vasoconstriction/dilation of arteries)
  - Breathing (rate and depth)
  - Others: speech, coughing, sneezing, salivation, swallowing, gagging, vomiting, sweating
- Attachment of CN IX, X, XI, XII

Brainstem: The Pons

- Contains many tracts carrying signals:
  - from cerebrum to cerebellum & medulla
  - up to thalamus
  - between right and left hemispheres of cerebellum
  - from brainstem to cerebellum
- Attachment of CN V, VI, VII, VIII

Brainstem: Midbrain

- Carries signals
  - Between higher and lower brain centers
  - From cerebellum to cerebral cortex
- Visual and Auditory reflex centers
- Somatic motor
- Attachment for CN III, IV

Cerebellum

- Smooths + coordinates body movements directed by other parts of brain
- 2 Cerebellar Hemispheres
  - Information on equilibrium
  - Movement of neck, trunk, limbs
  - Information from Cerebral cortex

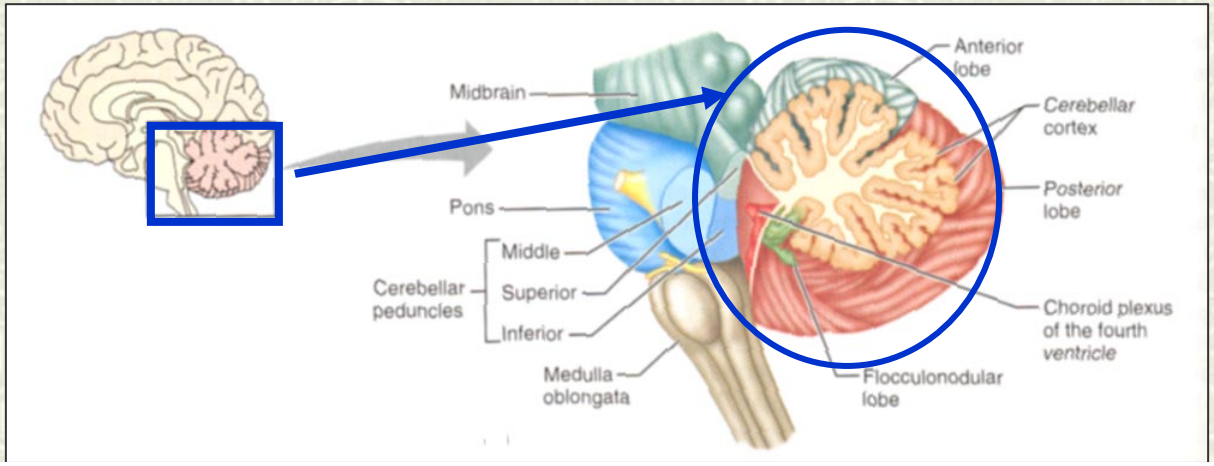

pg 372

Blood Brain Barrier

- Protects brain from blood-borne toxins (e.g. urea, food toxins, bacteria)
- Endothelium of brain capillaries are loaded with tight junction to decrease permeability
- Not complete protection, some things still have to get through (e.g. fat-soluble molecules can pass through)

Blood Supply to the Brain

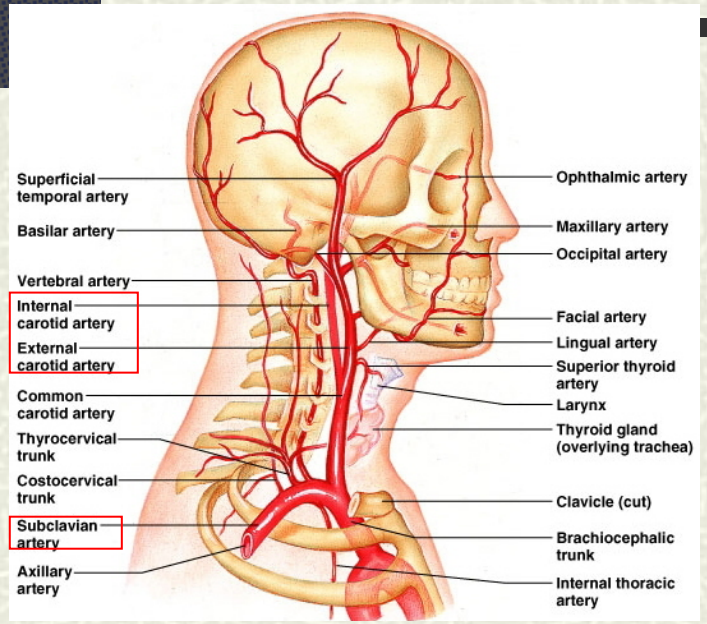

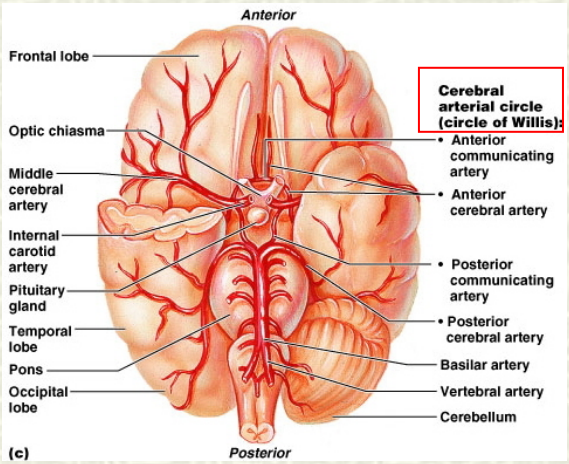

- Arteries
  - External carotid arteries and branches
    - Tissues of head & face, skin, muscles
    - Middle meningeal a. = brain
      - Boxers!
  - Internal carotid arteries and branches
    - Opthalmic a. = Eye & Orbits
    - Ant & Middle Cerebral arts = Cerebrum
  - Vertebral arteries
    - Posterior brain
    - Vertebrae & Cervical Spinal Cord
    - Branches form Cerebral Arterial Circle = Anastomosis

Blood Supply to the Brain

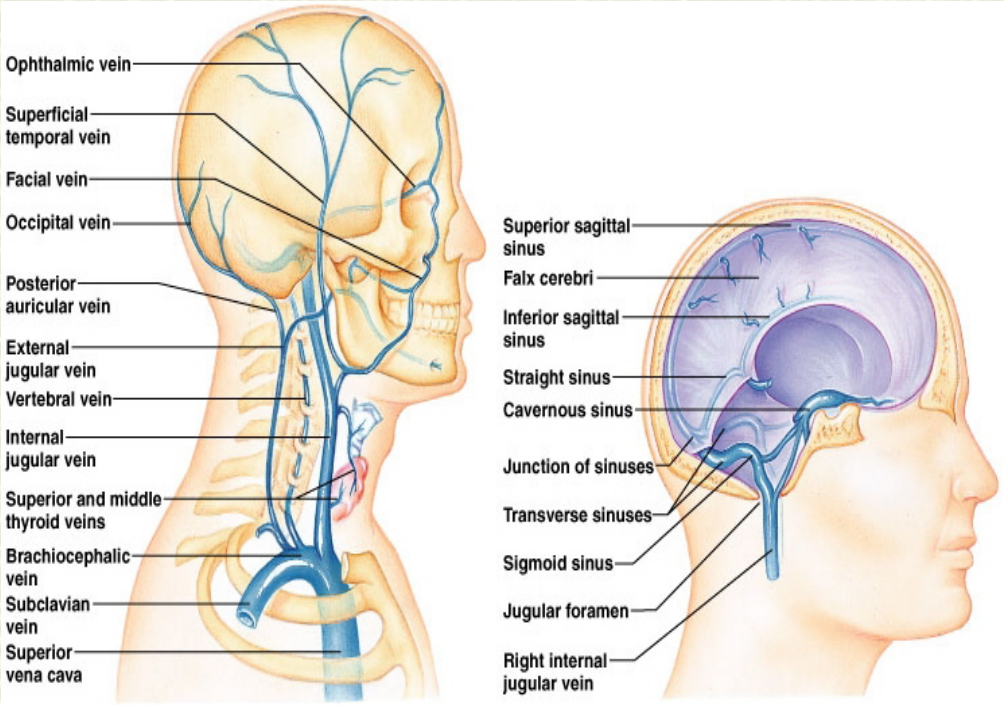

- Veins
  - Dural sinuses
    - Intracranial-receive blood from veins in brain, bring to Internal Jugular
  - Internal jugular
    - Drains brain
  - External jugular
    - Drains scalp and face (superficial)
  - Vertebral
    - Drains cervical vertebrae, cervical spinal cord, small neck muscles

Cranial Nerves: I - XII

- 12 Pairs
- Numbered Anterior to Posterior
- Attach to Ventral surface of brain
- Exit brain through foramina in skull
- I + II attach to Forebrain (cerebrum + diencephalon)
- III-XII attach to Brainstem (midbrain, pons, medulla)
- Only X goes beyond the head-neck

Foramina serving Cranial Nerves

- You must know what foramina each CN leaves the skull through
- (refer to handout in lab)

How to Remember CN I-XII

Oh! Oh! Oh!

To Touch And Feel

Very Good Velvet!

Ah Heaven!

I	Olfactory	(oh)
II	Optic	(oh)
III	Oculomotor	(oh)
IV	Trochlear	(to)
V	Trigeminal (1-3)	(touch)
VI	Abducens	(and)
VII	Facial	(feel)
VIII	Vestibulocochlear	(very)
IX	Glossopharyngeal	(good)
X	Vagus	(velvet)
XI	Accessory	(ah)
XII	Hypoglossal	(heaven)

Motor vs. Sensory Nerves

- Sensory = Afferent
  - Send nervous impulse from sensory receptors to brain to bring in information
  - e.g. pressure, temperature, pain
- Motor = Efferent
  - Send nervous impulses from brain to body to accomplish an action
  - e.g. movement of a muscle, activation of a gland

Sensory Nerves

- Sensory = Afferent
  - Visceral Sensory (sensory innervation of viscera)
    - stretch, pain, temp., chemical changes, irritation in viscera
    - Special: taste
  - Somatic Sensory (sensory innervation of outer part body)
    - touch, pain, pressure, vibration, temp. in skin, body wall, limbs
    - Special: hearing, equilibrium, vision, smell

Motor Nerves

- Motor Nerves
  - Visceral Motor (motor innervation muscle in viscera + glands)
    - innervation smooth + cardiac muscle, glands
  - Branchial Motor (motor innervation of pharyngeal arch m.)
    - facial expression, pharyngeal constrictors, suprahyoid, sternocleidomastoid, trapezius
  - Somatic Motor (motor innervation of skeletal muscle)
    - innervation of skeletal muscles (except pharyngeal arch m.)

Mnemonic for CN Function

- Some (CN I)
- Say (CN II)
- Marry (CN III)
- Money (CN IV)
- But (CN V)
- My (CN VI)
- Brother (CN VII)
- Says (CN VIII)
- Big (CN IX)
- Brains (CN X)
- Matter (CN XI)
- Most! (CN XII)

- S = Sensory function M = Motor function
- B = BOTH (Sensory and Motor function)

Cranial Nerve Function

I Olfactory--------Sensory--smell

II Optic----------Sensory--vision

III Oculomotor----Motor----extrinsic eye muscles

IV Trochlear-------Motor----extrinsic eye muscles

V Trigeminal

- **V_1** Opthalmic-----Sensory-cornea, nasal mucosa, face skin
- **V_2** Maxillary------Sensory-skin of face, oral cavity, teeth
- **V_3** Mandibular---Motor-muscles of mastication
  ---Sensory-face skin, teeth, tongue (general)

Distribution of sensory innervation to skin of face from CN V

CN V = Trigeminal

V_1 = Opthalmic

V_2 = Maxillary

V_3 = Mandibular

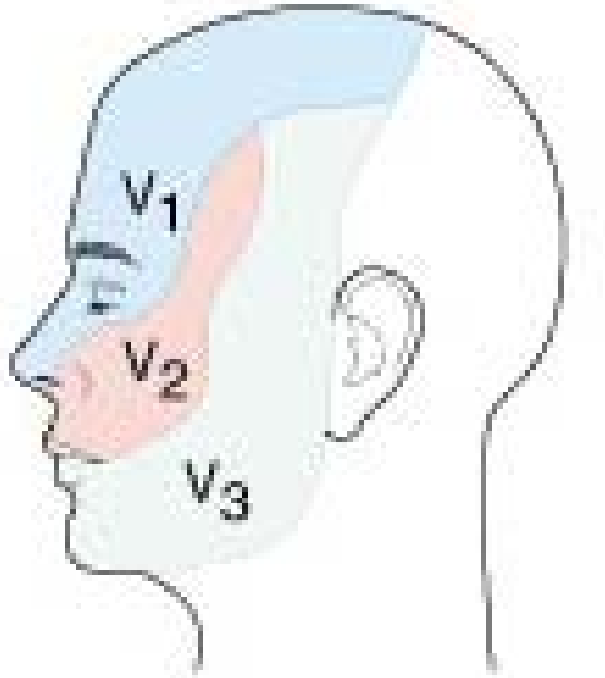

Distribution of sensory fibers of each division

Cranial Nerves (continued)

VI Abducens----------Motor-----eye abduction muscles

VII Facial----------Sensory---part of tongue (taste)

----------Motor------muscles of facial expression

VIII Vestibulocochlear---Sensory----hearing, equilibrium

IX Glossopharyngeal----Motor------stylopharyngeus muscle

----Sensory----tongue (gen & taste), pharynx

X Vagus----------Motor-------pharynx, larynx

----------Sensory----pharynx, larynx, abd. organs

XI Accessory----------Motor------trapezius, sternocleidomastoid

XII Hypoglossal----------Motor-------tongue muscles

Summary of Functional Groups

- Purely Sensory = I, II, VIII
- Primarily Motor = III, IV, VI, XI, XII
- Mixed = V, VII, IX, X

- Parasympathetic Fibers = III, VII, IX, X
  (Division of Autonomic NS = Visceral Motor)

pg 449

Parasympathetic Fibers

- CN III = Oculomotor
  - Contracts Iris (controls pupil)
  - Contracts Ciliary Muscle (controls lens)
- CN VII = Facial
  - Innervates Salivary glands (mandibular & sublingual)
  - Innervates Lacrimal gland
- CN IX = Glossopharyngeal
  - Innervates Parotid Salivary gland
- CN X = Vagus
  - Innervates thoracic & abdominal viscera

Parasympathetic

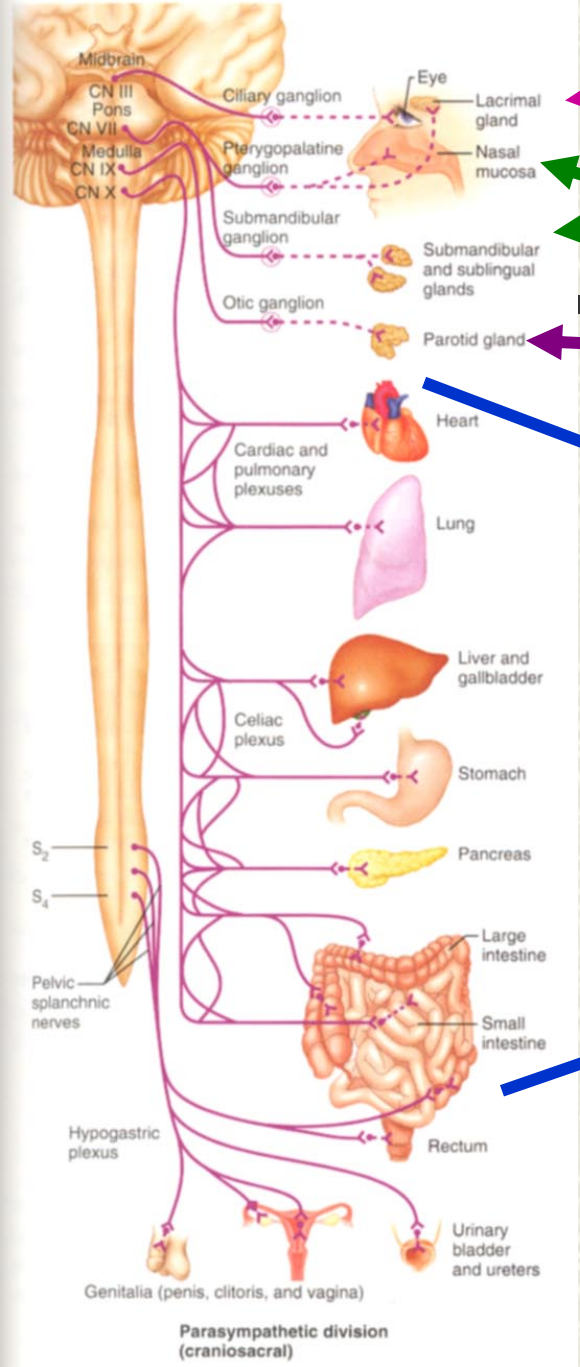

III

VII

IX

X

Anatomy of the Eye and Ear

Eye: Dominant Sense

(70% of body's sense receptors)

- Orbit: eye, fat cushion, optic n, a + v, extrinsic eye muscles
  - My Eyes Feel Like Pulling Some Z's!
- Accessory structures:
  - Eyebrow: coarse hair, shade eye, block perspiration
  - Eyelid = Palpebrae: mobile, upper + lower, skin-covered, CT support (tarsal plates)
  - Eyelash: Fine hairs, richly innervated

Glands Associated w/Eyelids

- Types of Glands
  - Tarsal Gland: (sebaceous glands)
    - Embedded in tarsal plates, open at edge of eyelids
  - Ciliary Gland: (modified sweat glands)
    - Within eyelids
  - Sebaceous glands – open into hair follicles
- Function of Secretions
  - Slow evaporation of fluid on eye surface
  - Soften and lubricate eyelashes, skin
  - Kill bacteria
  - Collect dirt

Eye (continued)

- More Accessory structures
  - Conjunctiva-transparent mucous membrane on inner eyelid + anterior surface of eye, mucus keeps eye moist
  - Lacrimal Apparatus-gland + ducts flow into nasal cavity
    - Tears-keep eye moist, wash out irritant
    - Contain mucus, antibodies, lysozome
  - Lacrimal Gland-Superolateral to eye, produce fluid
    - Innervated by CN VII (parasympathetic fibers)

Flow of Tears

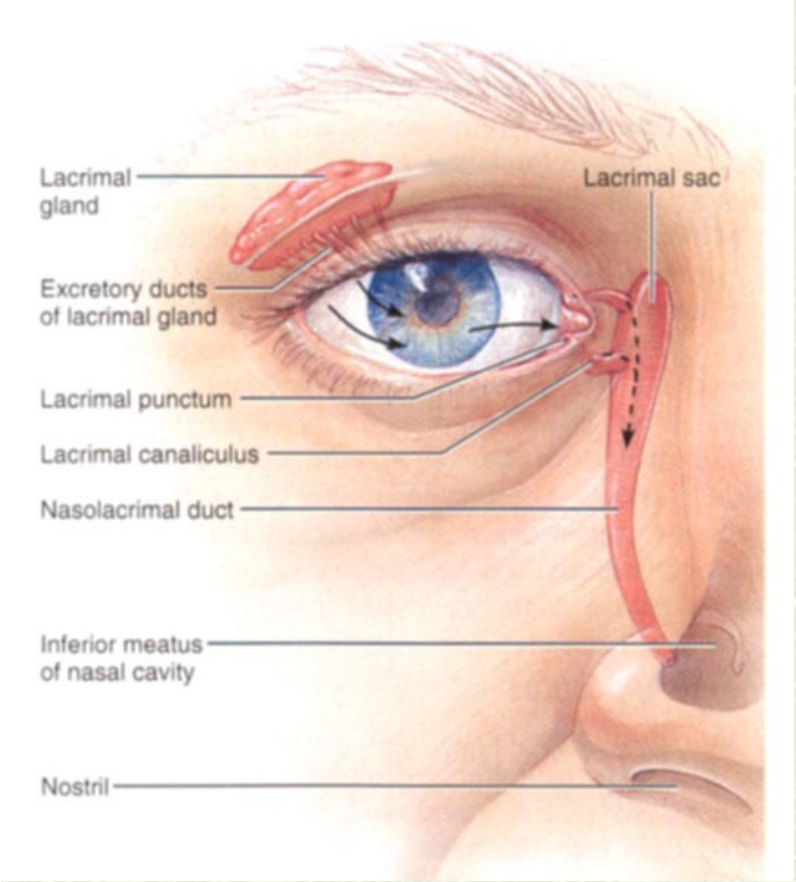

- Lacrimal gland
- Excretory ducts to eye
- Blink →across eye
- Lacrimal puncta
- Lacrimal canaliculi
- Lacrimal sac (in lacrimal fossa)
- Naso-lacrimal duct
- Nasal cavity

pg 472

6 Extrinsic Eye Muscles

- Direct gaze, hold eye in orbit
- O: orbit walls I: outer surface of eye
- 4 Rectus Muscles (turn M-L, S-I)
- 2 Obliques
  - **Superior Oblique**-depresses, some lateral movement
  - **Inferior Oblique**-elevates, some lateral movement
- Innervation
  - Lateral Rectus = CN VI (abducens)
  - Middle, Superior, Inferior Rectus + Inf. Oblique = CN III (o-m)
  - Superior Oblique = CN IV (trochlear)

Extrinsic Eye Muscles

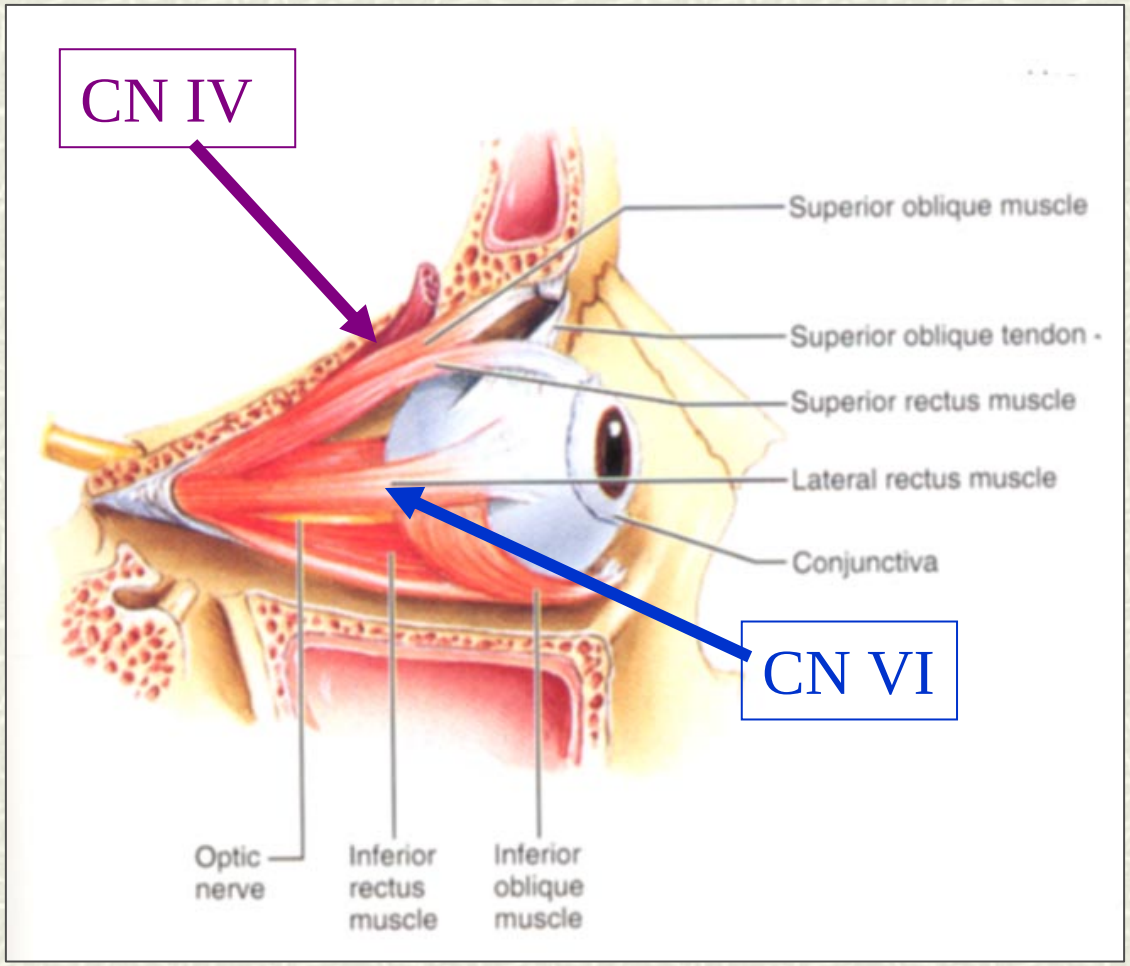

CN III = the rest

Pg 473

Eye Function + Structure

- Function
  - Gather, Focus + Process light
  - Contain, Protect + Support Sensory Receptors
- Structure: 3 Layers (Tunics)
  - Fibrous: (external) Dense CT = Sclera, Cornea
  - Vascular: (middle)= Choroid, Ciliary Body, Iris
  - Sensory: (internal) = Retina

Fibrous Tunic (external)

- Sclera: made of Dense CT
  - Opaque, white, hard
  - Protects, insertion for muscles
  - Posterior 5/6 of eye
- Cornea: made of Dense CT between 2 layers epithelium
  - Transparent, avascular, highly innervated
  - Entrance for light, assists in bending light
  - Anterior 1/6 of eye
  - Layer of renewable stem cells for corneal epithelium
- Scleral Venous Sinus: between sclera + cornea
  - Drains aqueous humor from eye

Tunics of Eye

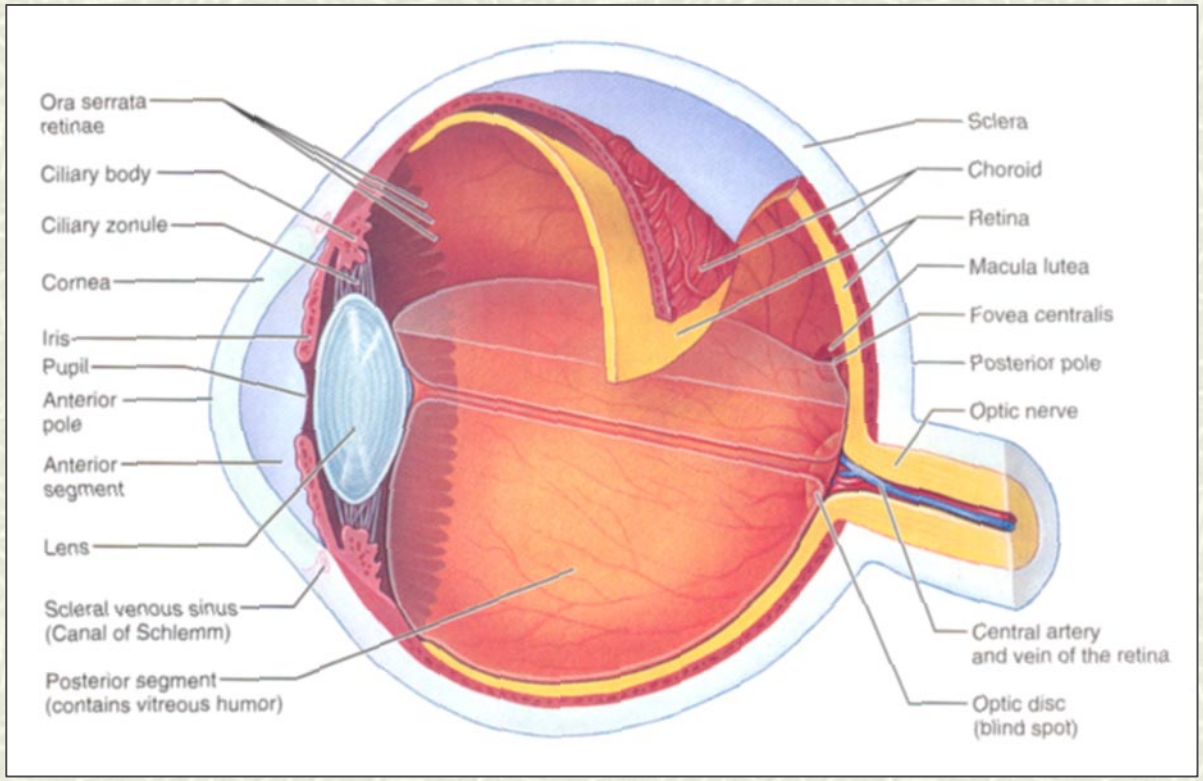

pg 474

Vascular Tunic (middle)

- Choroid: highly vascularized, darkly pigmented membrane, post. 5/6
  - nourishes other tunics
  - absorbs light, prevent scattering & confusion
- Ciliary Body: continuous w/choroid, thick ring of tissue around lens
  - smooth muscle (ciliary muscle) = focuses lens
- Iris: visible, colored part between cornea + lens
  - Attached to ciliary body
  - Pupil = opening in iris
  - smooth muscle = dilate + constrict pupil = light enters

Retina = Sensory Tunic (internal)

- Neural layer (inner)
  - thick, sheets nervous tissue
  - contain photoreceptors (rods + cones)
- Pigmented layer (outer)
  - contains melanocytes
  - absorb light, prevent scattering

Eye Anatomy (continued)

- Lens
  - thick, transparent, biconvex disc
  - changes shape to focus light on retina
  - made of epithelium + fibers (contain proteins)
  - divides eye into anterior/posterior segments
- Aqueous Humor: clear fluid in anterior segment
  - provides nutrients, O_2 to lens/cornea
- Vitreous Humor: jelly-like in posterior segment
  - transmit light, support post. surface of lens + hold 2 layers of retina together, maintain intraocular pressure

Flow of Aqueous Humor

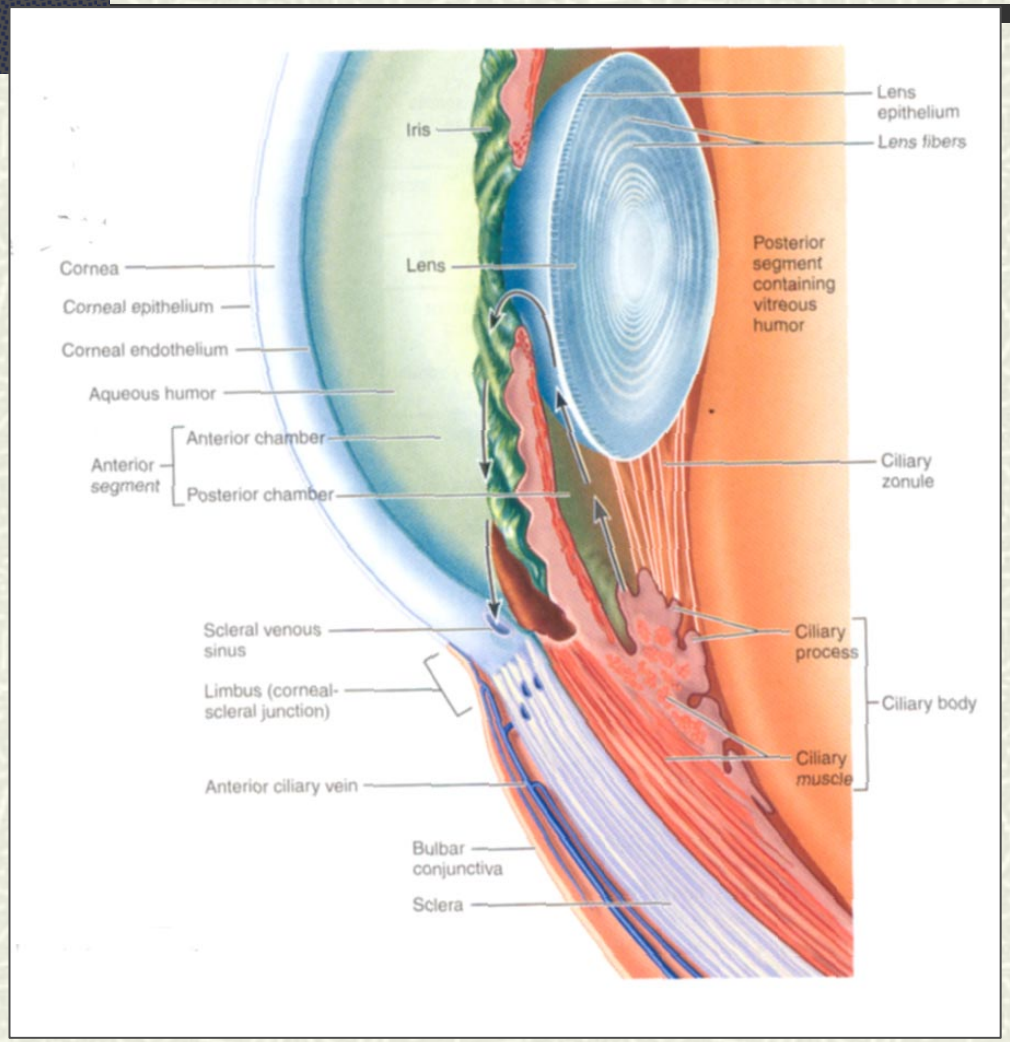

- Produced in Ciliary Process (of C. body)
- From Posterior Chamber (of Anterior Segment)
- To Anterior Chamber (of Anterior Segment)
- Nourish lens+ cornea
- Drains into Scleral Venous Sinus
- Returned to blood

pg 475

Eyeball Anatomy!

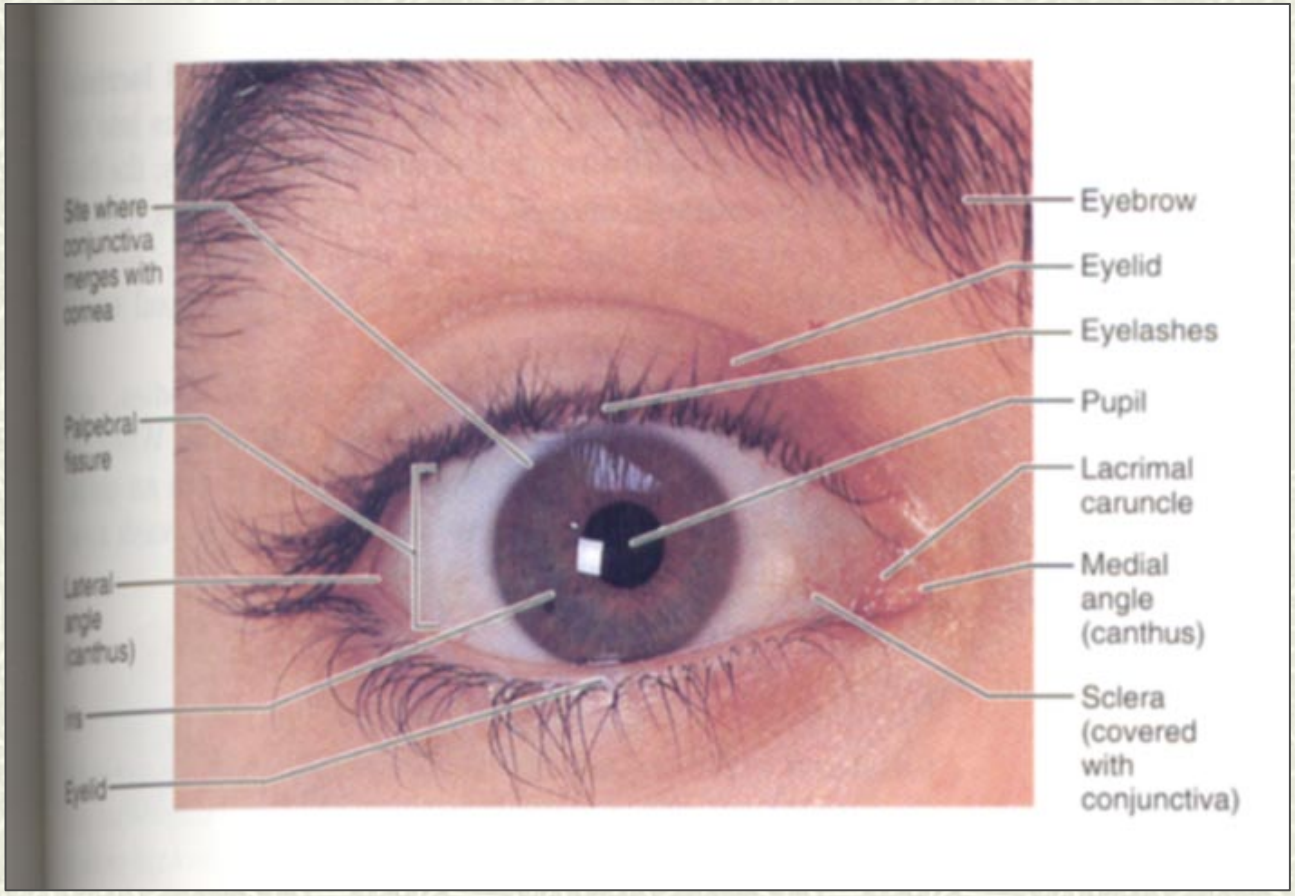

pg 474

The Ear: Outer, Middle, Inner

- Outer: Hearing
  - Auricle = Pinna
    - external elastic cartilage
    - gathers + funnels sound into ear opening
  - External Auditory Meatus (canal)
    - short tube from auricle to ear drum
    - lateral 1/3 = elastic cartilage
    - medial 2/3 = temporal bone
    - Lined w/skin containing hair + glands produce ear wax

The Ear

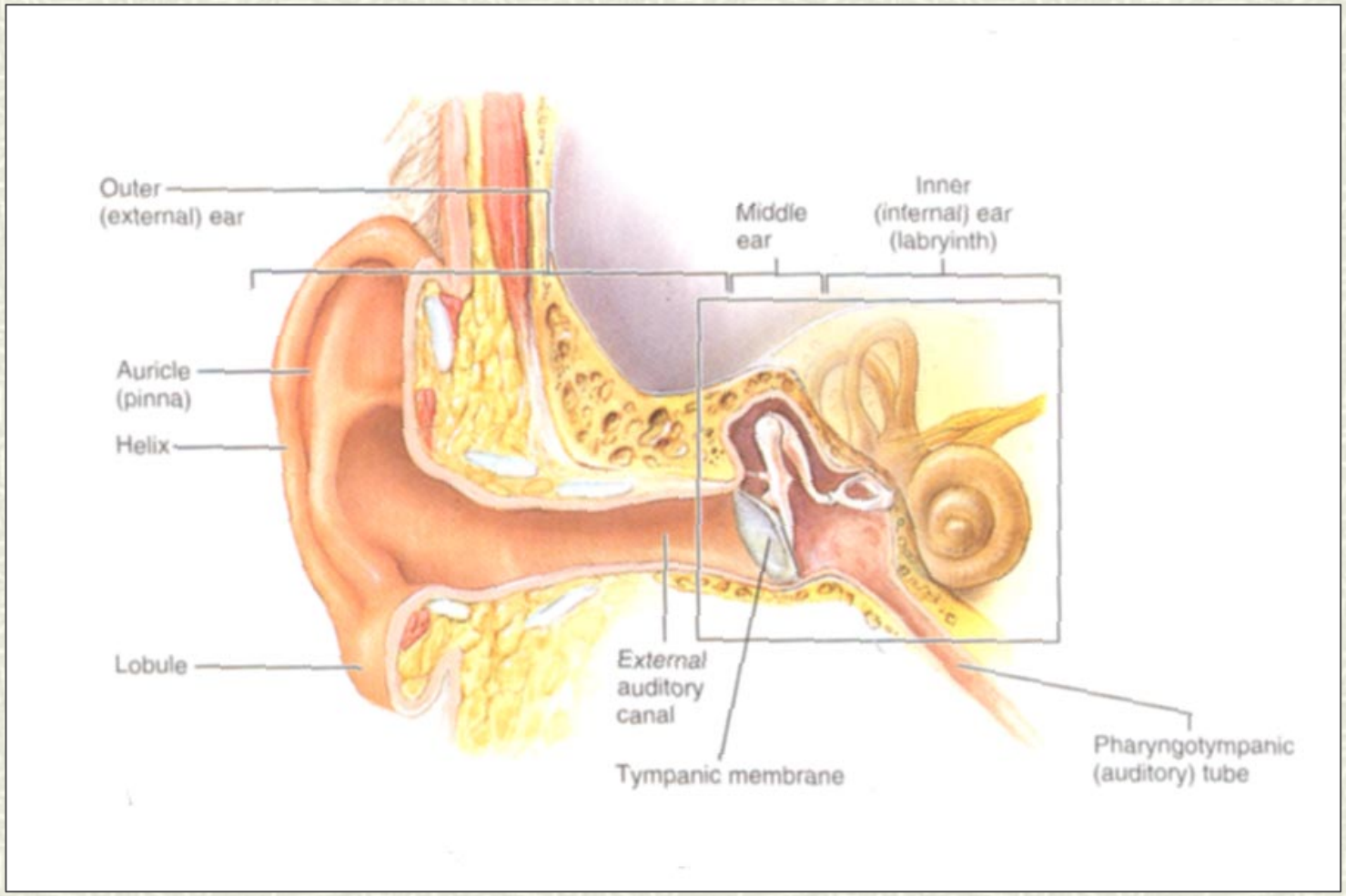

pg 487

The Ear: Outer, Middle, Inner

- Middle = Tympanic Cavity: Hearing
  - small, air-filled space in petrous portion temporal bone
  - lined w/mucousal membrane
  - lateral border = tympanic membrane
    - Fibrous connective tissue
    - Flattened cone-shape
    - Lateral side = covered in skin, medial side = covered by mucous membrane
  - medial border = bone separating middle/inner ear
    - Medial wall contains Oval window + Round window
  - Pharyngotympanic tube (was called eustachian tube): links middle ear and pharynx (behind nasal cavity)
    - lateral 1/3 = bone, medial 2/3 = cartilage
    - opens briefly to equalize middle ear pressure to outside air pressure

Middle Ear (continued)

- Ossicles: tiny bones transmit vibration from eardrum to inner ear; amplify sound 20X
- Eardrum → Malleus → Incus → Stapes → → Oval Window → Inner Ear
- Suspensory Ligaments hold ossicles in middle ear
- Tensor Tympani-O: cartilage part of pharyngotympanic tube; I: Malleus
- Stapedius-O: posterior wall middle ear; I: Stapes

The Ear: Outer, Middle, Inner

- Inner Ear = Hearing + Equilibrium
  - **Bony Labyrinth**-cavity in petrous bone
    - Semicircular canal, Vestibule, Cochlea
    - Contains **perilymph** (produced by cells of bony canal)
  - **Membranous Labyrinth**-continuous series of membrane-walled sacs + ducts; fit loosely in bony labyrinth
    - Semicircular ducts, Utricle + Saccule, Cochlear ducts
    - Contain **endolymph** (produced in cochlear duct)

Inner Ear: structures + functions

Bony Labyrinth	Membranous Labyrinth	Function of Membranous Labyrinth
1. Semicircular canals	Semicircular ducts	Equilibrium; rotational acceleration of head
2. Vestibule	Utricle + Saccule	Equilibrium; static equilib + linear equilib of head
3. Cochlea	Cochlear duct	Hearing

Middle + Inner Ear

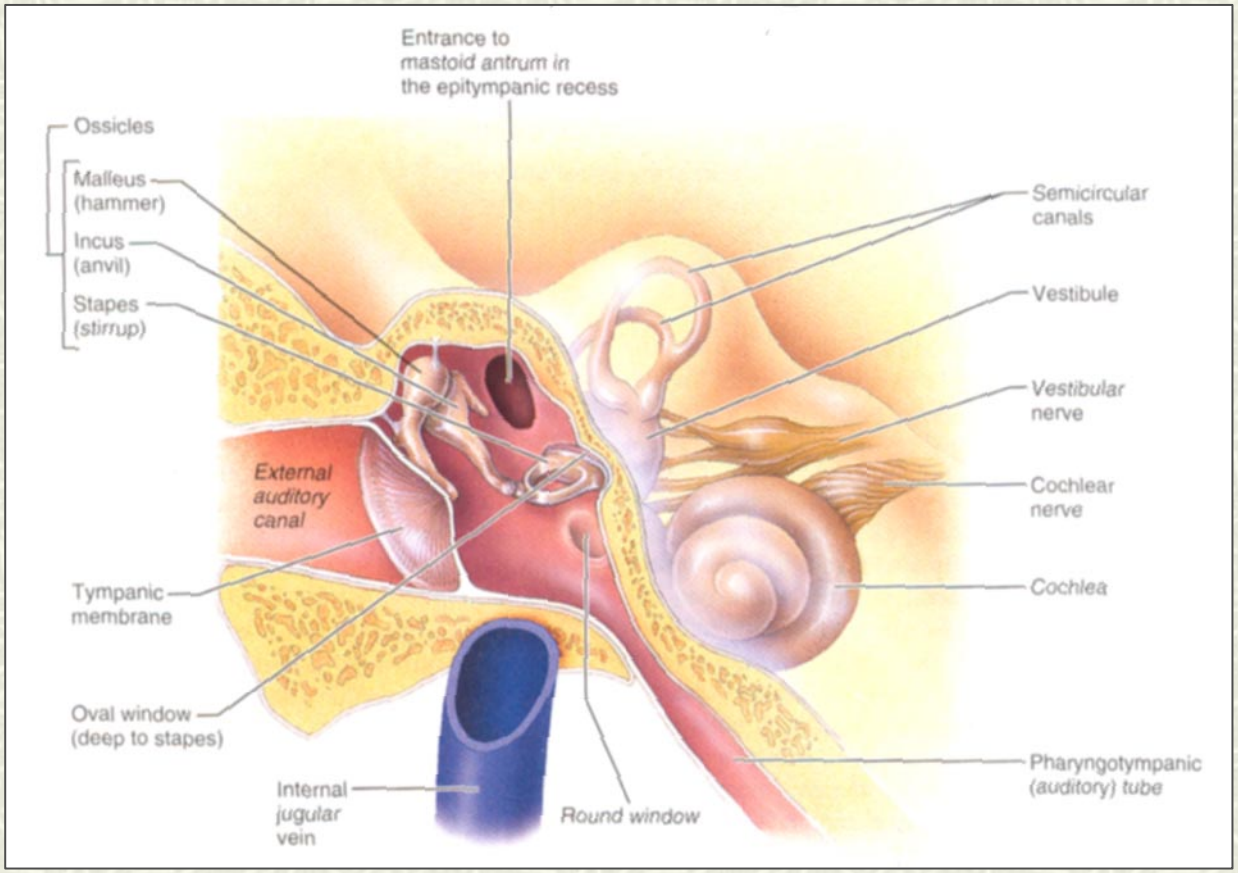

Functional Brain Systems: networks of neurons functioning together despite spanning great distance in brain

- Limbic System
  - Cerebral hemispheres, Diencephalon
  - Process fear, shift from thoughts to expression of emotion
  - Consolidate and retrieve memories

- Reticular Formation
  - Medulla, Pons, Midbrain
  - Maintains cerebral cortex alertness
  - Filters out repetitive stimuli
  - Regulates skeletal + voluntary muscle activity