X-Ray Rounds:
(Plain) Radiographic Evaluation of the Shoulder

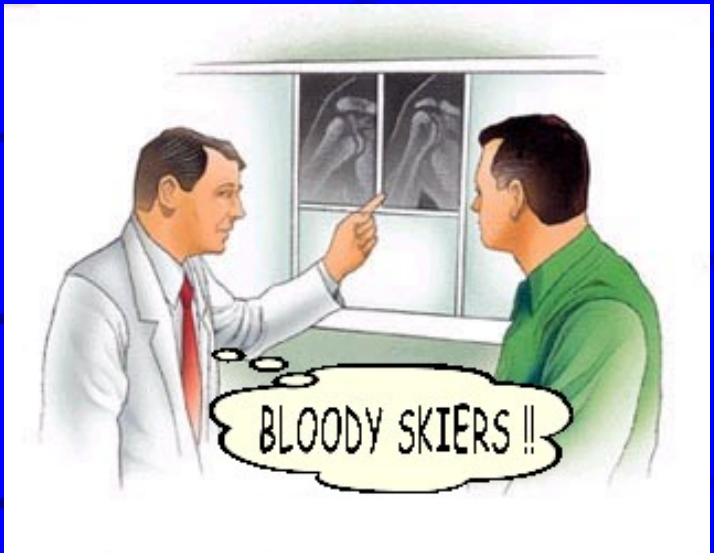

Anatomy

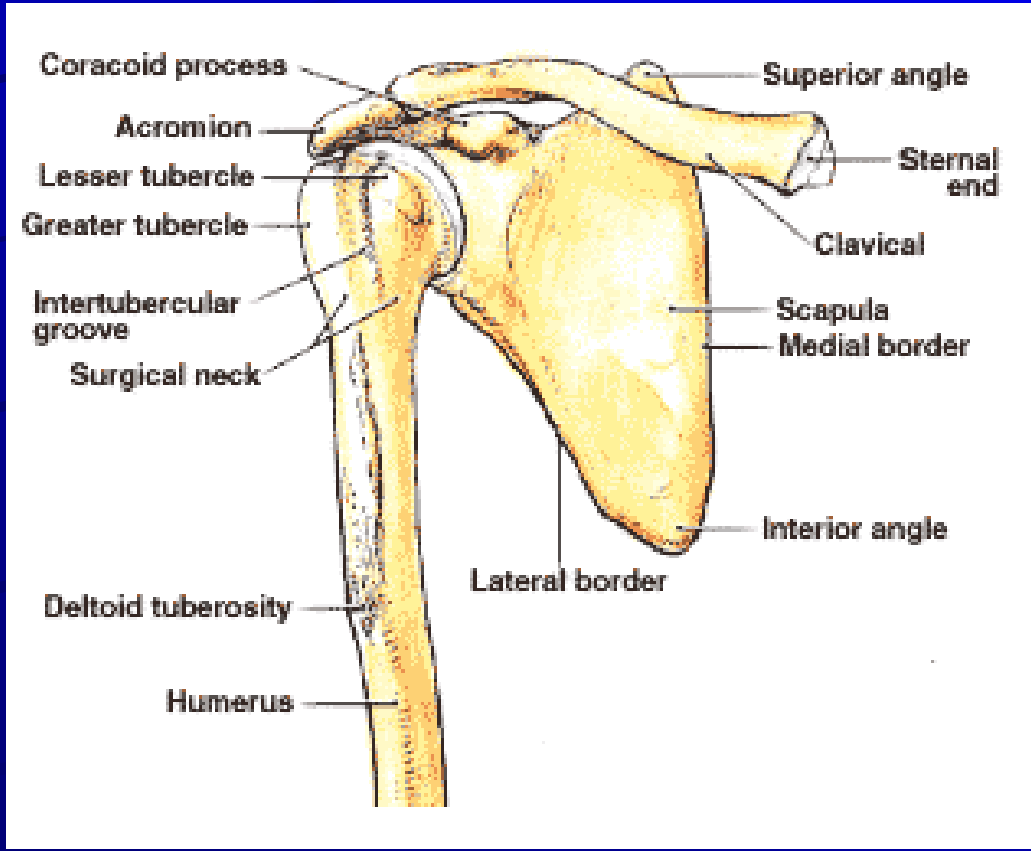

- 3 Bones
  - Humerus
  - Scapula
  - Clavicle
- 3 Joints
  - Glenohumeral
  - Acromioclavicular
  - Sternoclavicular
- 1 “Articulation”
  - Scapulothoracic

Anatomy

- Humerus
  - Head *
  - Anatomic neck
  - Surgical neck
  - Greater tubercle*
  - Lesser tubercle*
  - Intertubercular groove
  - Deltoid tuberosity
  - Shaft *

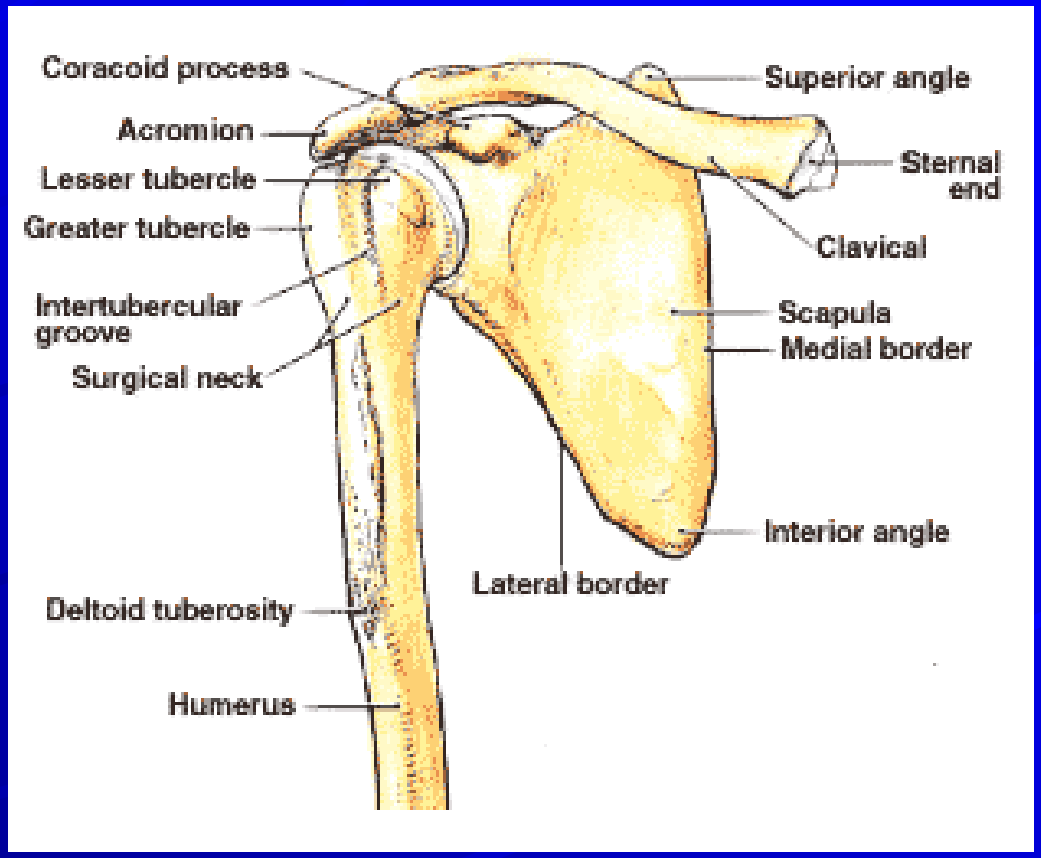

Anatomy

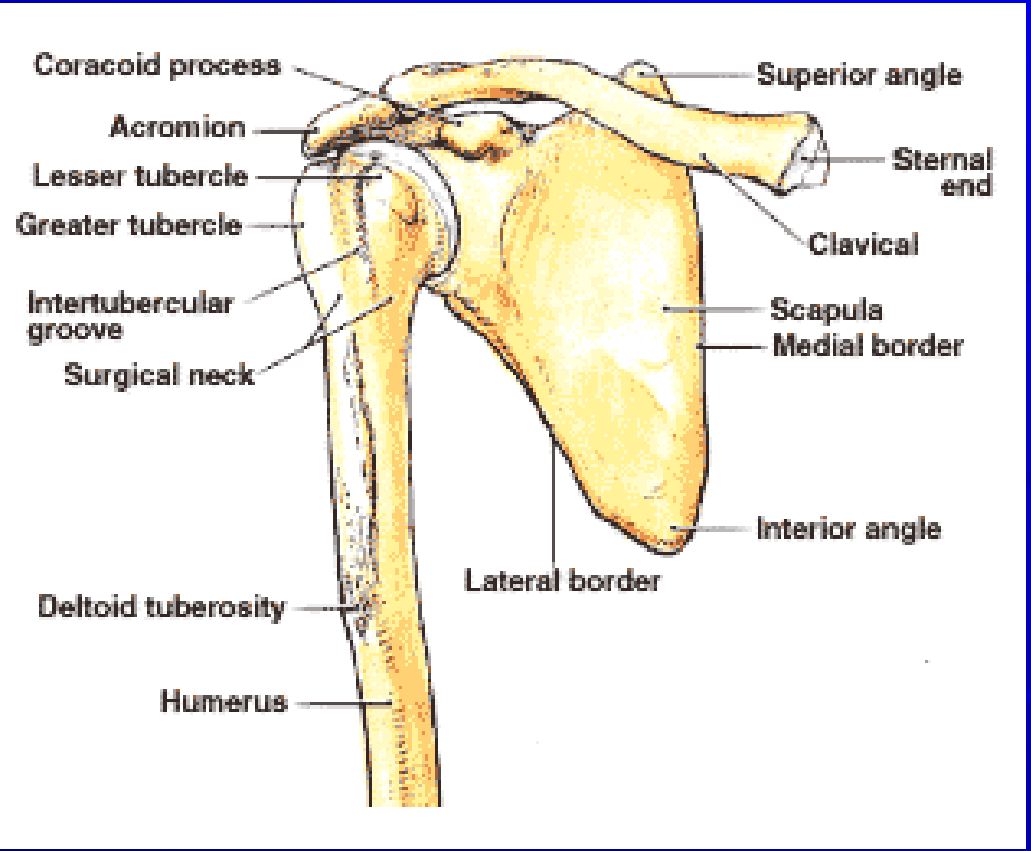

- Scapula
  - Body
    - Ventral (Costal) surface
    - Dorsal surface
  - Borders
    - Superior
    - Lateral (Axillary)
    - Medial (Vertebral)
  - Angles
    - Superior
    - Inferior
    - Lateral (Head)

Anatomy

- Scapula
  - Glenoid
  - Acromion
  - Coracoid
  - Subscapular fossa
  - Scapular spine
  - Supraspinatus fossa
  - Infraspinatus fossa
  - Great scapular notch
  - Suprascapular notch

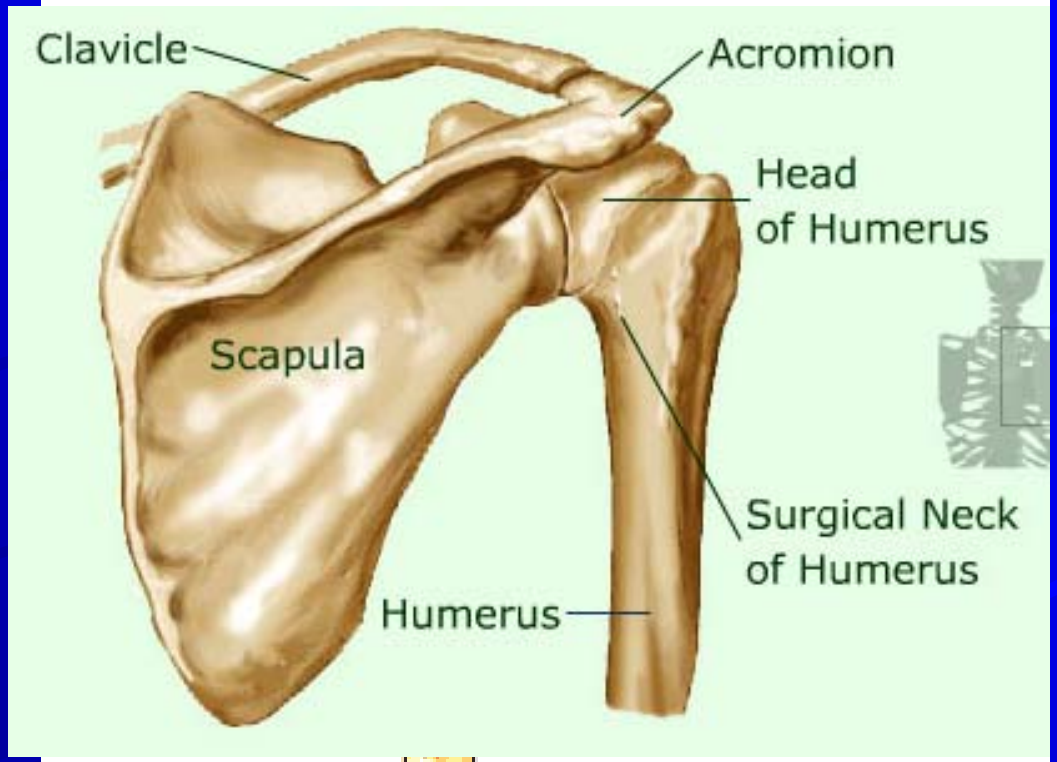

Anatomy

- Scapular “Y” (Lateral)

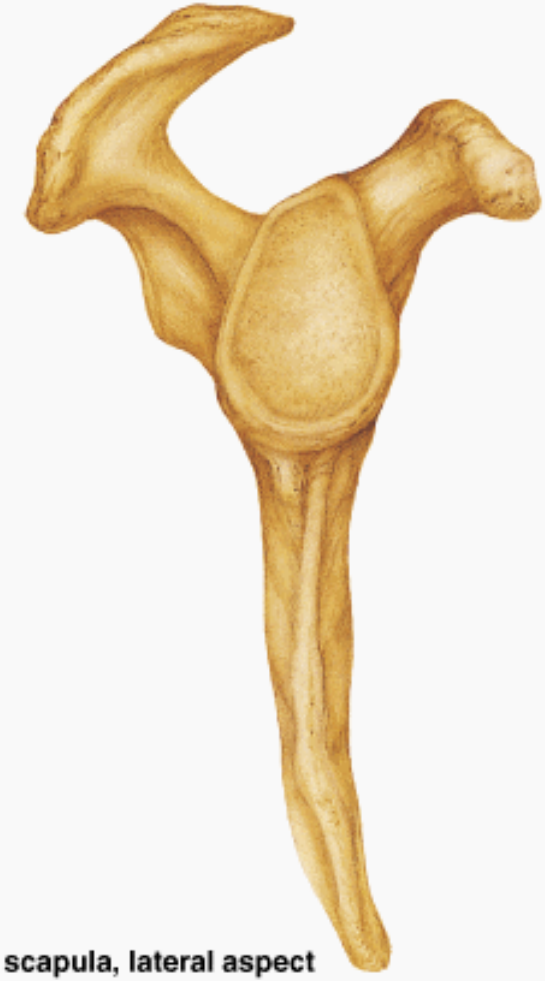

(f) Right scapula, lateral aspect

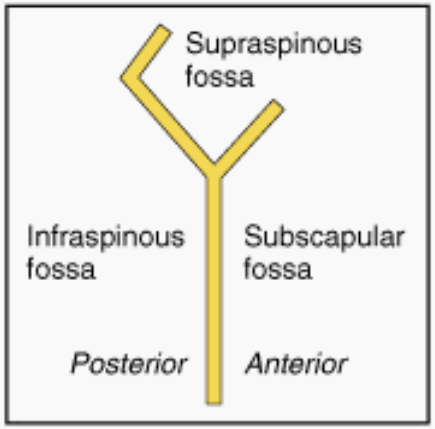

Anatomy

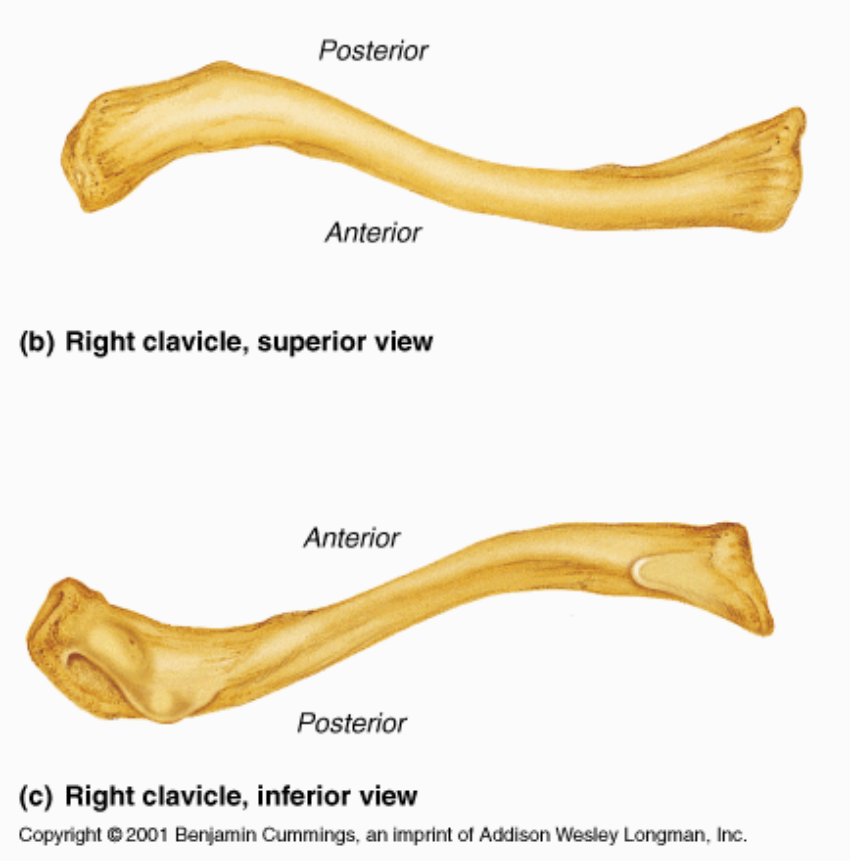

- Clavicle
  - First bone to start ossification; last to finish
  - The only bony strut b/w UE and axial skeleton
  - Flat outer (lateral, acromial) third
    - Traps, Delt, AC / CC ligaments
  - Tubular medial (inner, sternal) third
    - Strongest in axial load
  - Middle third
    - Most vulnerable to Fx

Anatomy

- Glenohumeral joint
  - Ball and socket
  - Purpose: placement of primary prehensile limb
  - Very mobile; majority (0-120°) of shoulder movement (0-180°)
  - Price: instability
  - 45% of all dislocations
  - Joint stability depends on multiple factors

Anatomy

- Glenohumeral joint
  - Passive stability
    - Joint conformity
    - Vacuum effect of jt vol
    - Synovial fluid adhesion and cohesion
    - Scapular inclination
    - Glenoid labrum (50%)
    - Coracoid ligaments
      - CCL, CAL
    - Joint capsule
    - Glenohumeral ligaments
      - SGHL, MGHL, IGHLC
    - Bony restraints
      - Glenoid fossa, Acromion, Coracoid

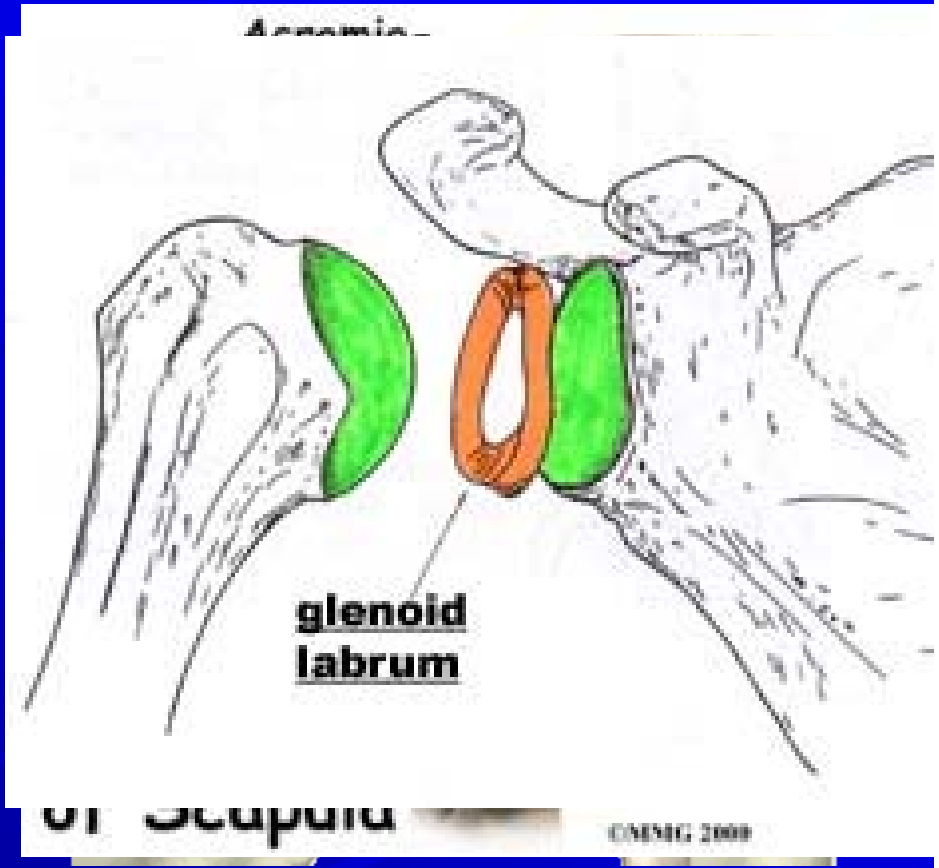

- Coracohumeral ligament

Anatomy

- Glenohumeral joint
  - Active stability
    - Biceps (long head)
    - Rotator cuff
    - Pectoralis muscles, trapezius, serratus anterior, rhomboids, levator scapulae, etc. (NOT deltoid)

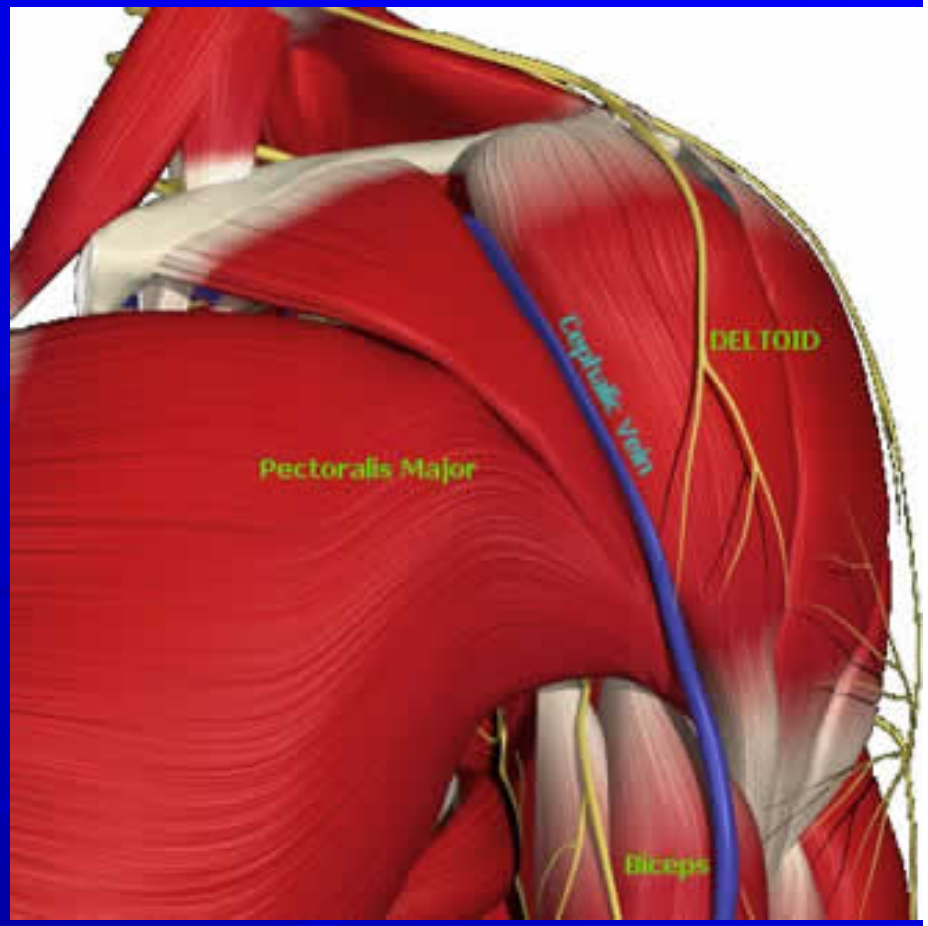

Anatomy

- Acromioclavicular joint
  - Diarthrodial joint
  - Thin capsule
  - AC ligaments
    - Anterior, posterior, superior, inferior
  - Coracoacromial ligament
  - Coracoclavicular ligaments
    - Trapeziod ligament
    - Conoid ligament

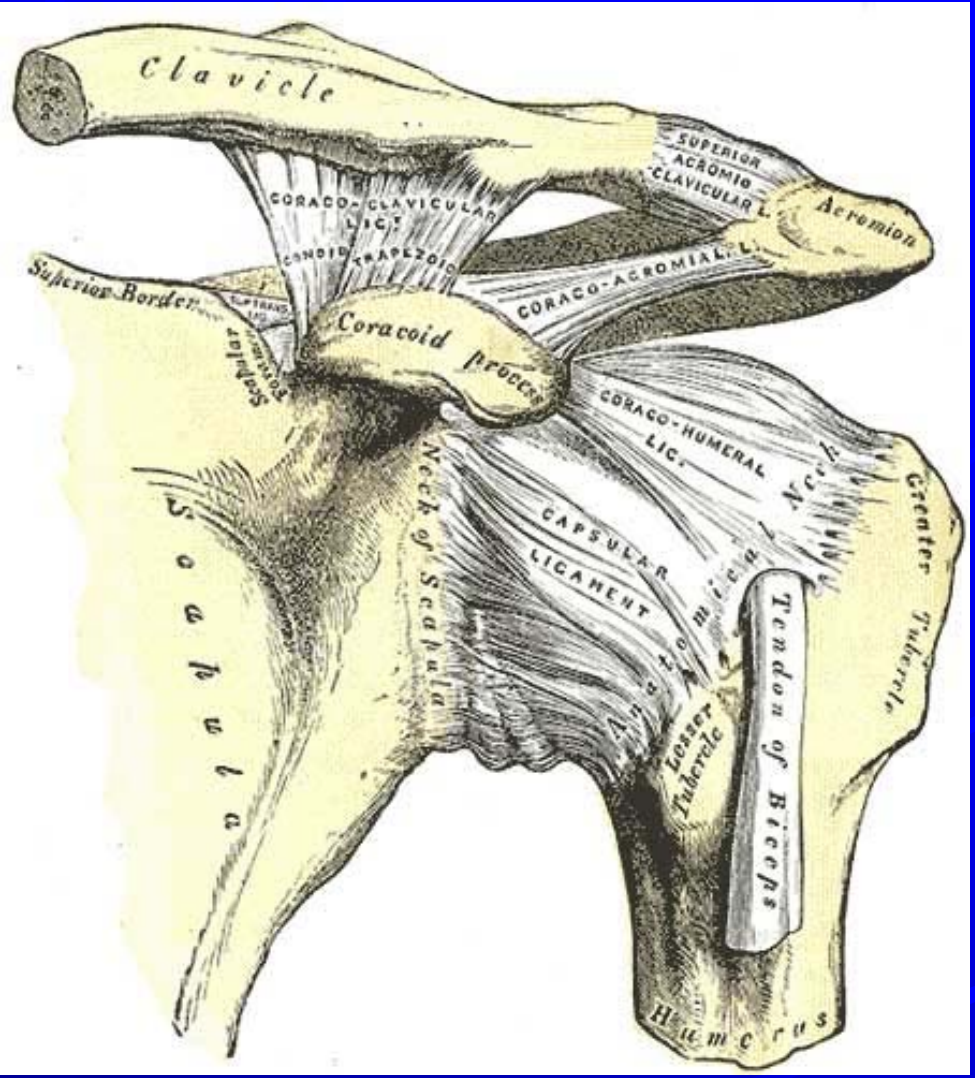

Anatomy

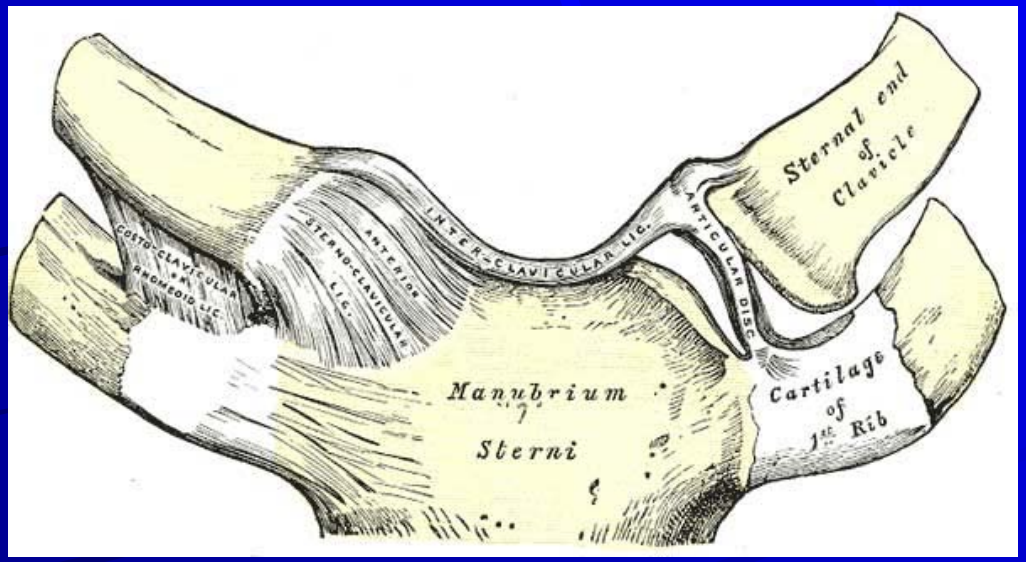

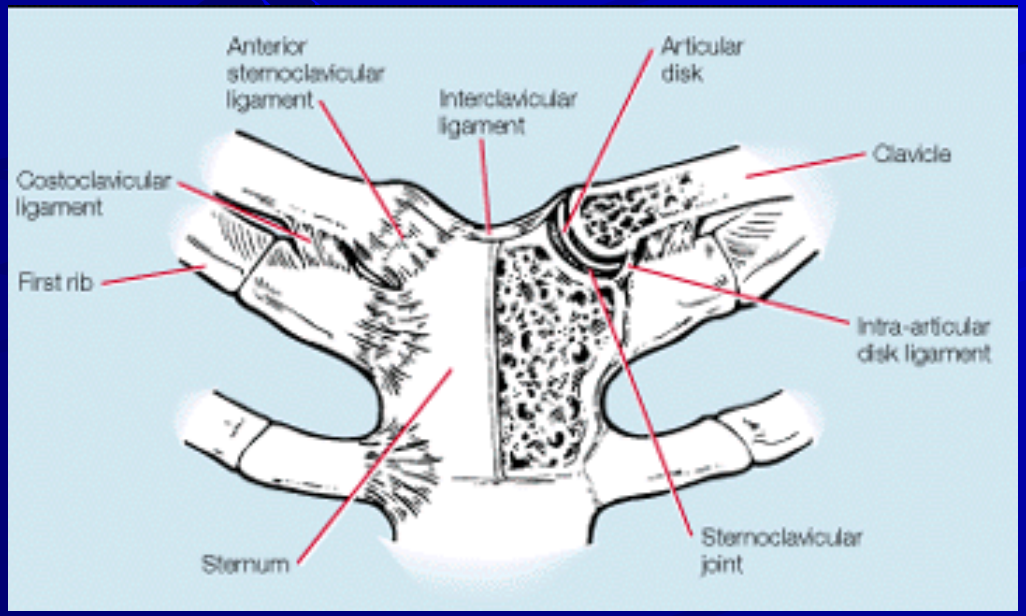

- Sternoclavicular joint
  - Diarthrodial joint
  - Joint capsule
  - Articular disk
  - Intraarticular disk ligament
  - Sternoclavicular ligaments
    - Anterior, posterior
  - Interclavicular ligament

Anatomy

- Coordinated shoulder motion
  - Glenohumeral motion
  - Acromioclavicular motion
  - Sternoclavicular motion
  - Scapulothoracic motion

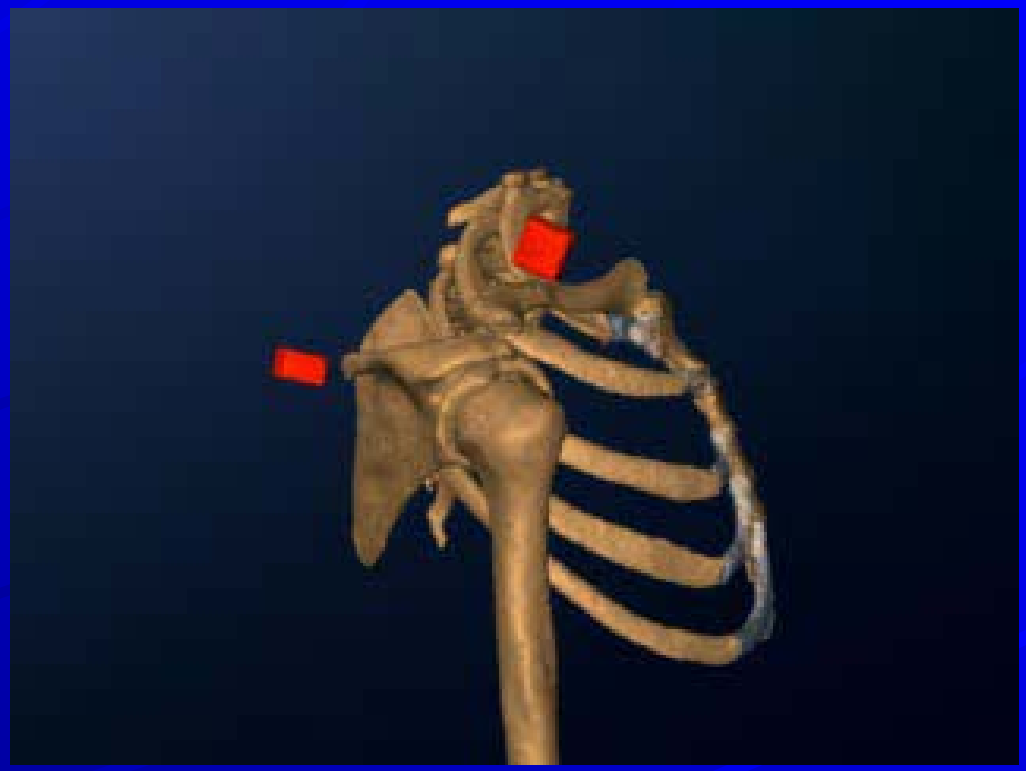

Scapular-humeral rhythm

AP View of the Shoulder

- "Transthoracic," or "Routine" AP View
  - AP relative to thorax
  - Suboptimal view of Glenohumeral joint
  - Good view of AC joint
- "Scapular," "Grashey," or "Glenohumeral" AP View
  - Better visualize bony relationships incl GH joint
  - Suboptimal view of AC joint
- Both have been called "True" AP Views

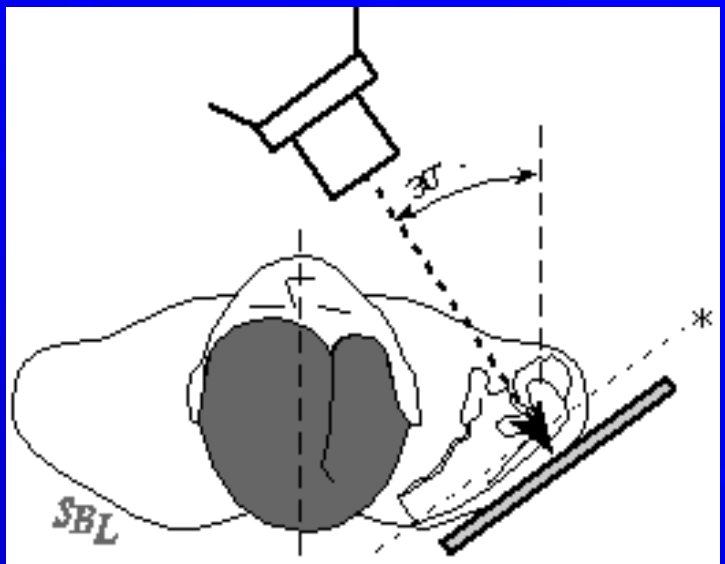

Figure 14-76

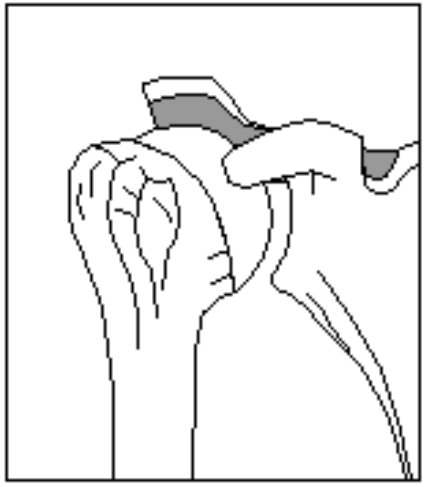

AP View of the Shoulder

- "Routine" AP View
  - Clavicle
  - Scapula
    - Acromion & scapular spine
    - Coracoid
    - Borders & angles
  - AC & SC joints
  - Glenoid
    - Both ant & post lips
    - May obscure HH
  - Humerus
    - Head & necks
    - Gr & Lsr tuberosities

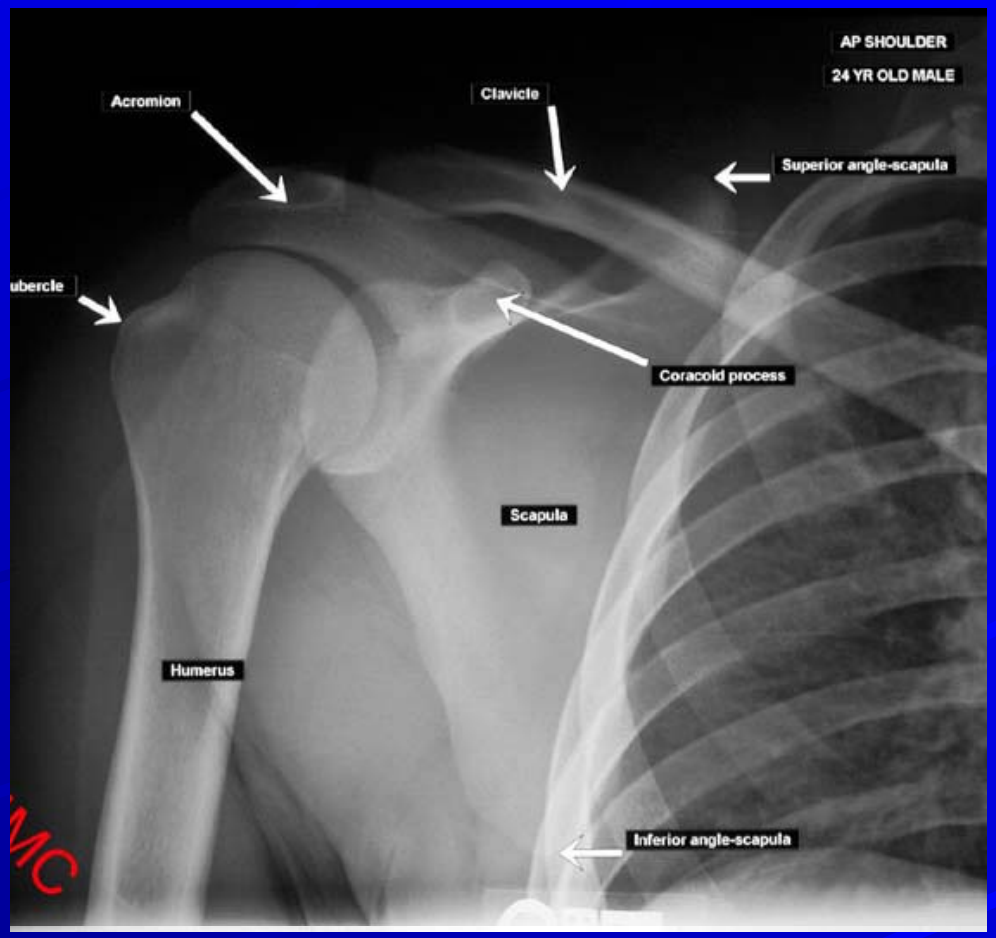

AP View of the Shoulder

- "Glenohumeral," "Grashey," or "Scapular" AP View
  - Same structures
  - AC joint not visualized as well
  - Better visualize the glenoid & humeral head (especially with ER view)

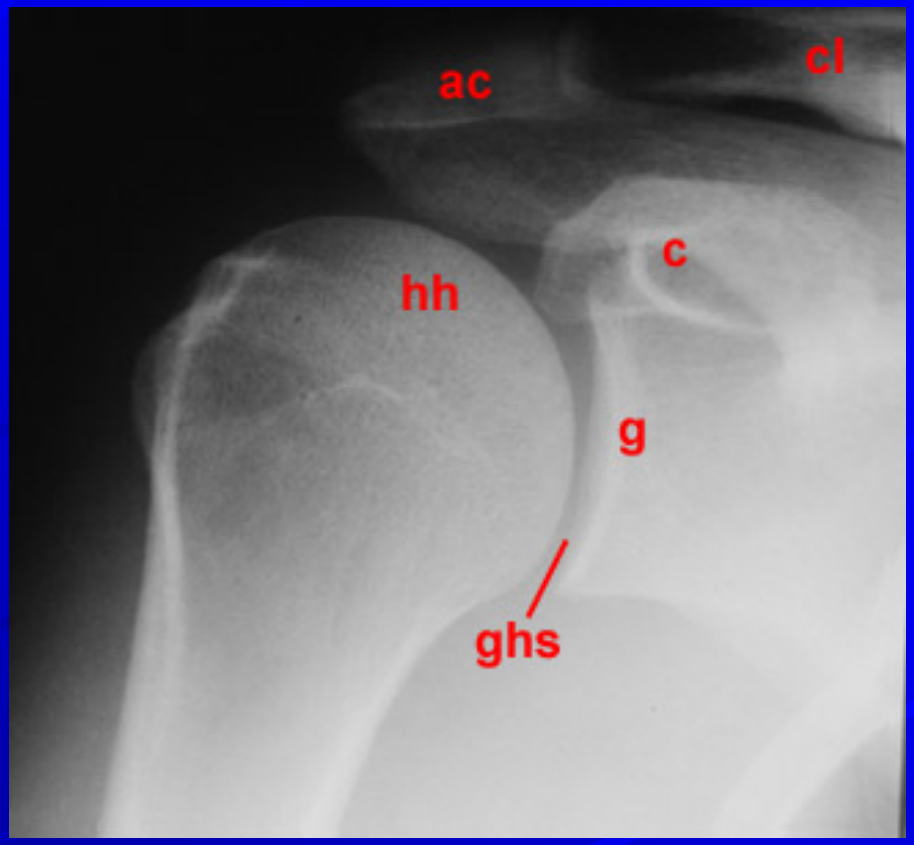

AP View of the Shoulder

PROCEDURE

Figure 1: Courtesy of Kevin D. Nowicki, MD, and Warren G. Harding III, MD

a

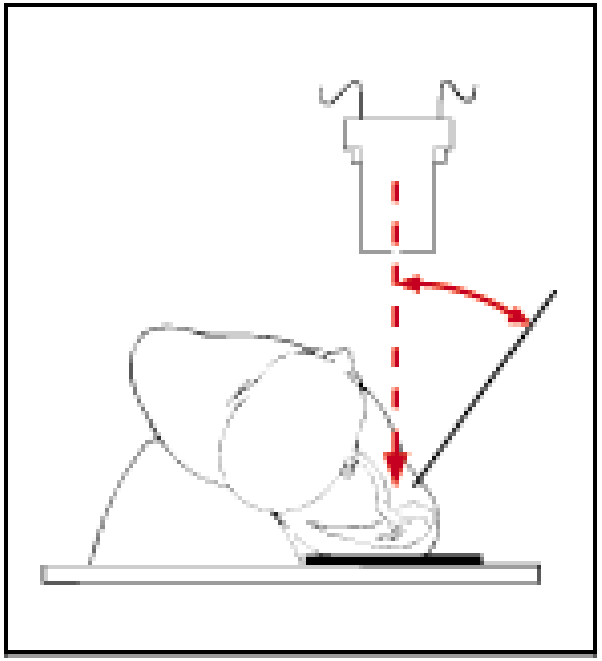

b

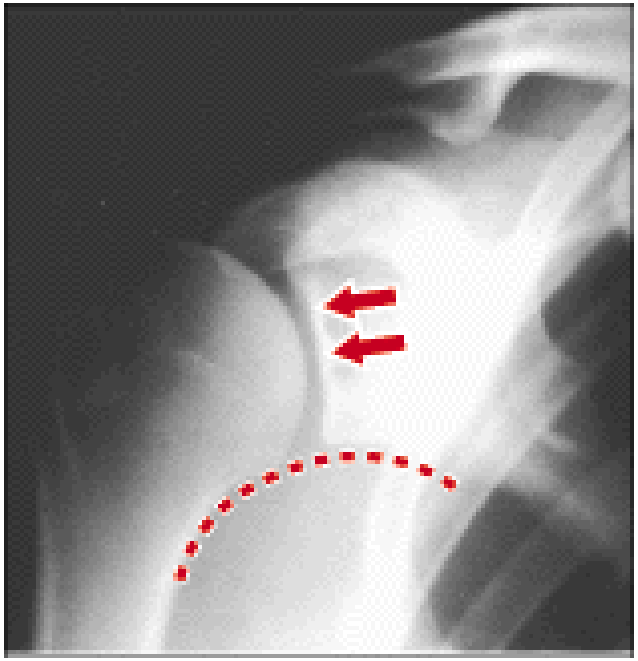

Figure 1. For routine radiographic examination of the shoulder, one view should be a scapular AP view with the humerus in external rotation (a). The x-ray beam is directed at a 35° angle to the sagittal plane. This view provides clear definition of the glenohumeral joint (b) (arrows), but leaves the acromioclavicular joint poorly defined. Note the smooth arch of the scapulohumeral line (dotted line).

AP View of the Shoulder

- AP View in External Rotation
  - Greater tuberosity & soft tissues profiled and better visualized
  - Best w/ Scapular AP
- AP View in Internal Rotation
  - May demonstrate Hill-Sachs lesions
    - GH instability
  - Best w/ Routine AP

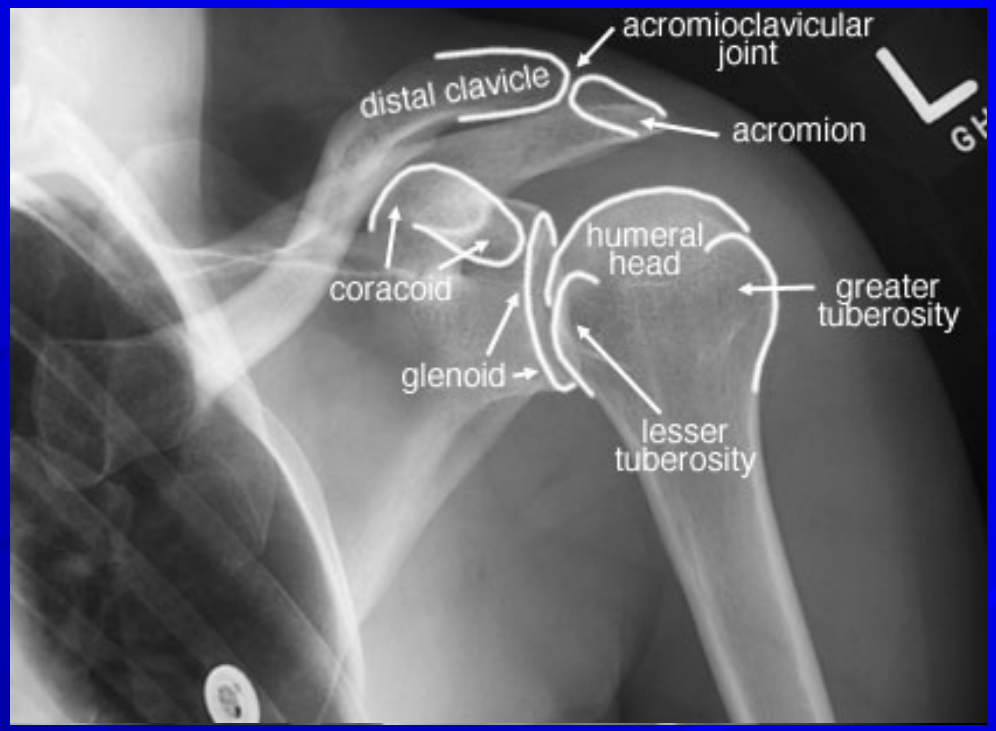

Which AP view should I get?

- Routine AP with humeral head in internal rotation (IR)
- Scapular / Glenohumeral AP with humeral head in external rotation (ER)

Harding WG, Nowicki KD. Plane talk about shoulder radiographs. Phys Sportsmed 1998; 26(2)

Transthoracic Lateral View of the Shoulder

- Not usually done
- Not as useful
- Many obscuring over- and underlying structures

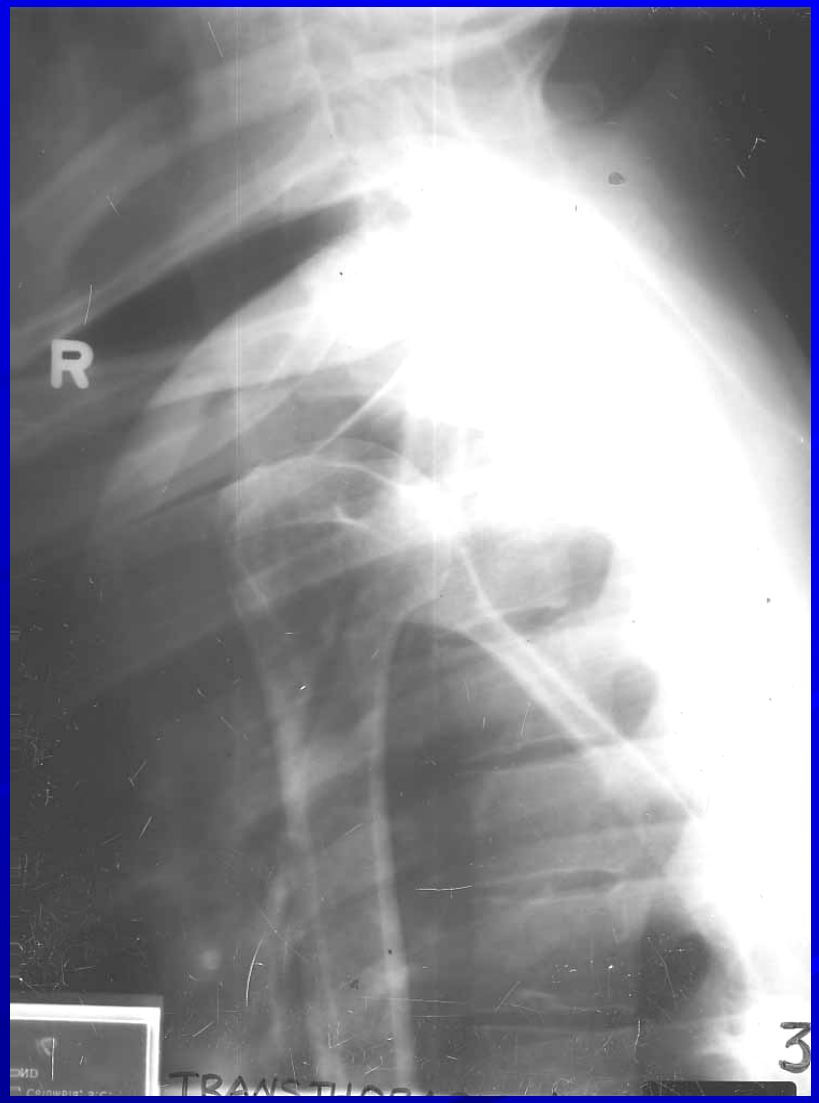

Axillary Lateral View of the Shoulder

- Good view of anterior-posterior relationship of GH joint

- Coracoid
- Acromion
- Humerus
- Glenoid
- GH joint

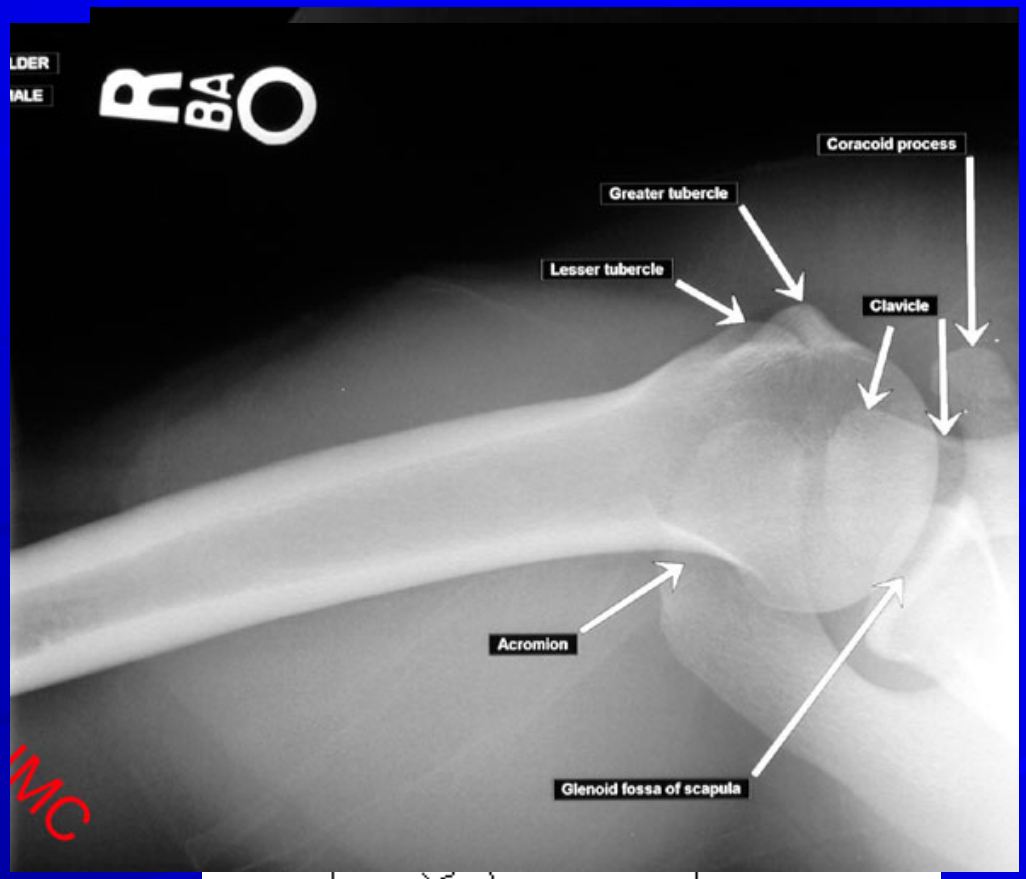



Axillary Lateral View of the Shoulder

- Alternate Axillary views

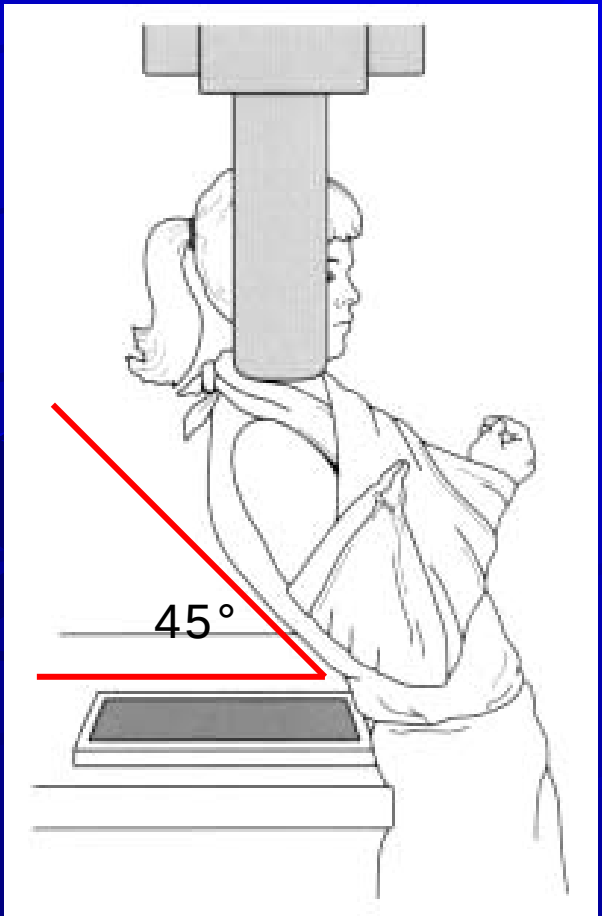

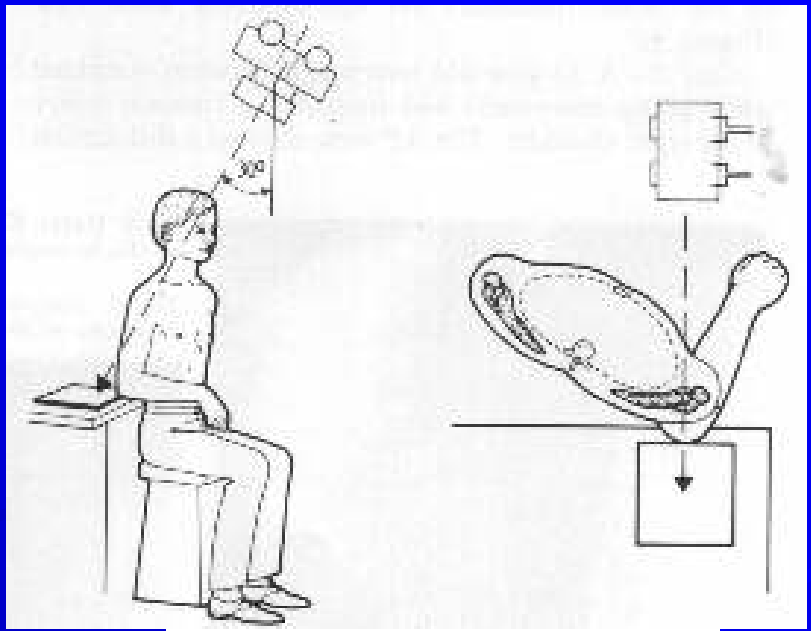

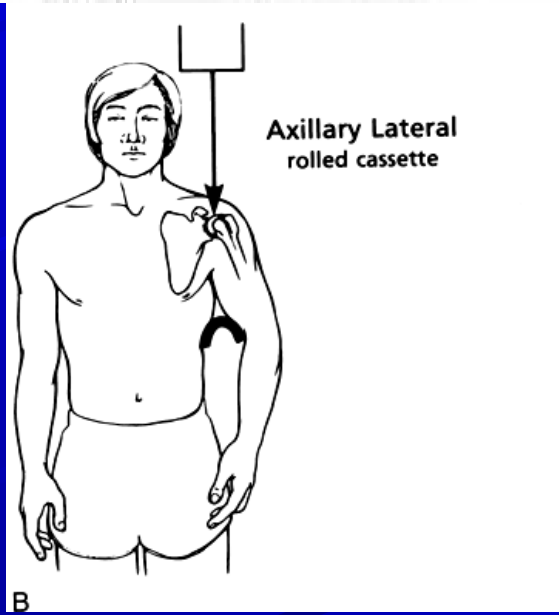

Velpeau View – magnified axillary view

Scapular "Y" Lateral View of the Shoulder

- Relationship b/w humeral head and glenoid

- Acromion
- Coracoid
- Scapular body
- Scapular spine

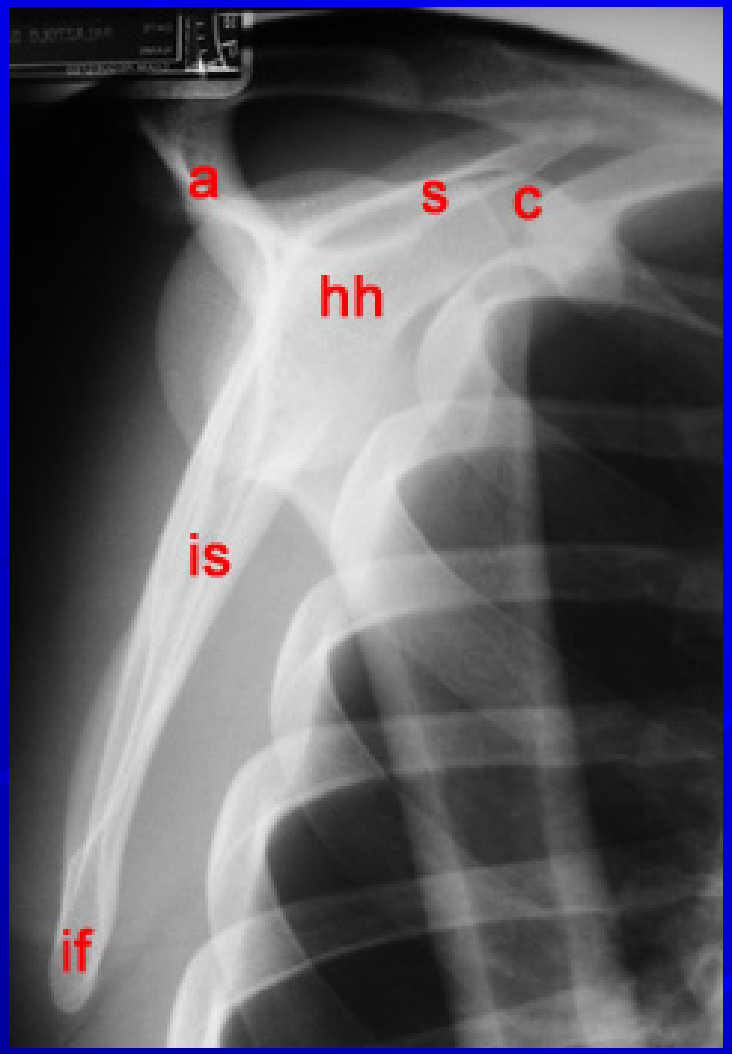

Scapular "Y" Lateral View of the Shoulder

- Scapular outlet view
  - A variation of scapular Y view
  - Same projection, but with beam tilted 5-10° caudad
  - Shoulder impingement: to evaluate the subacromial space and the supraspinatus outlet

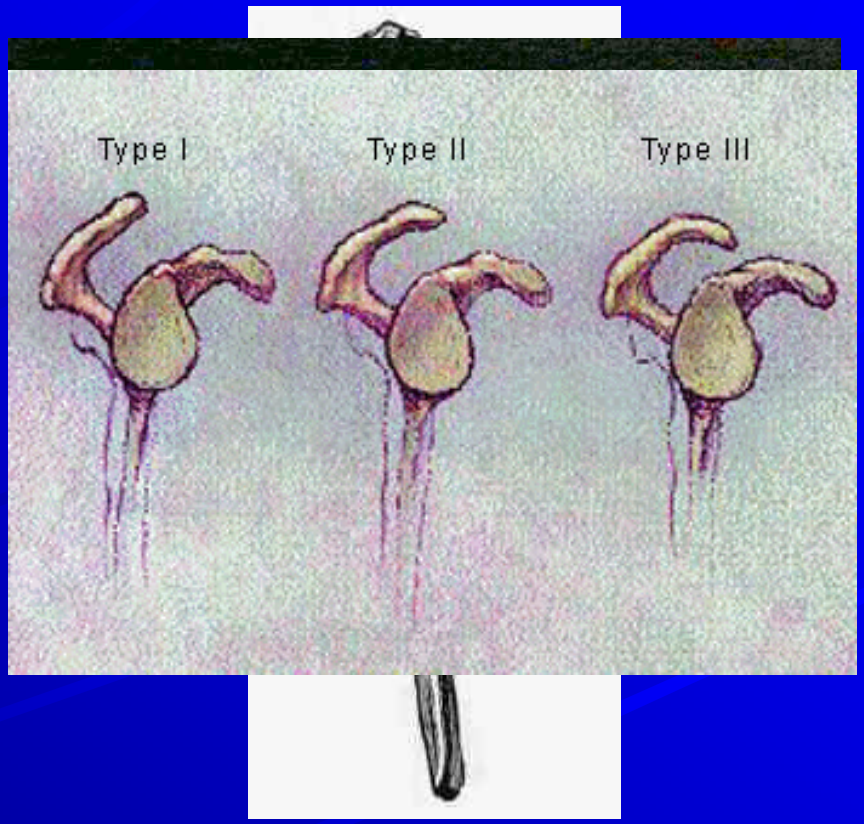

Other Views of the Shoulder

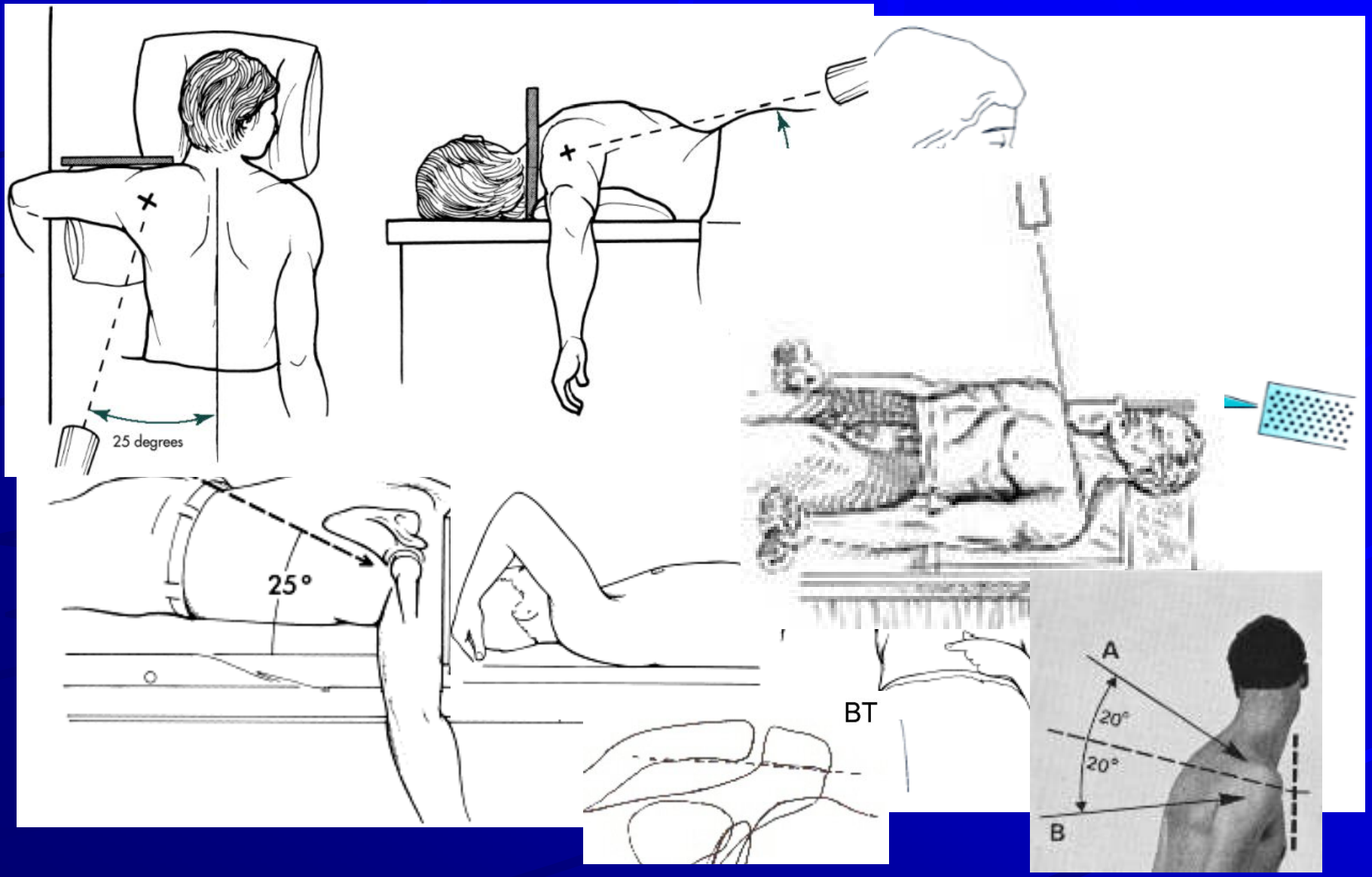

Indications

- American College of Radiology (ACR) Appropriateness Criteria for Musculoskeletal Imaging in Shoulder Trauma
  - Developed in 1995, revised in 2005
  - AP with IR & ER, and lateral (axillary or scapular Y) views recommended for:
    - R/O fracture or dislocation
    - Subacute (~3 months) shoulder pain suspicious for:
      - Bursitis / tendonitis
      - RTC tear or impingement (as initial study)

Indications

- Stevenson and Trojian: JFP in July 2002
  - No definitive studies on the needs of shoulder radiographs have been done
  - Recommended obtaining plain films for:
    - Decreased ROM (especially: abduction < 90°)
    - Severe pain
    - History of trauma
  - Glenohumeral AP, outlet & axillary lateral views
  - Add AP with IR & ER in cases of trauma
  - AC joint views for suspected AC joint disease
  - Neck, chest, abdominal imaging for suspected referred pain

Stevenson JH, Trojian T. Applied evidence: evaluation of shoulder pain. J Fam Pract 2002; 51(7):605-611.

Indications

- Other indications
  - Suspicion of instability
  - Weakness of shoulder motions
  - The patient cannot communicate (altered mental status, alcohol intoxication, or other)
  - Persistent pain and decreased ROM
  - Anytime your history and physical don't give you enough information

Normal routine AP in ER

Normal routine AP in IR

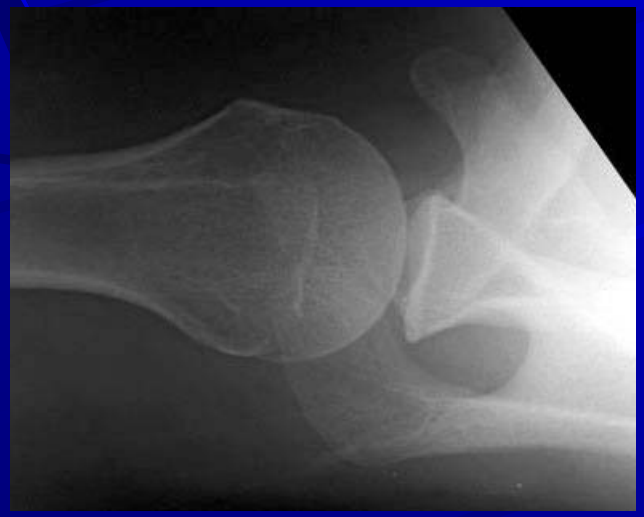

Normal axillary view

Routine AP and axillary views

Neer classification 3-part proximal humerus fracture involving:

- Surgical neck
- Lsr tuberosity

Tx: surgical eval

Proximal Humerus Fractures: Neer Classification

- 2-part fractures
  - May be Tx'd conservatively if:
    - Displaced < 1 cm
    - Angulation < 45 °
    - No dislocations
    - Good reduction
    - No intraarticular involvement
    - Anatomic neck intact
  - Otherwise: surgical evaluation
- All else: surgical evaluation

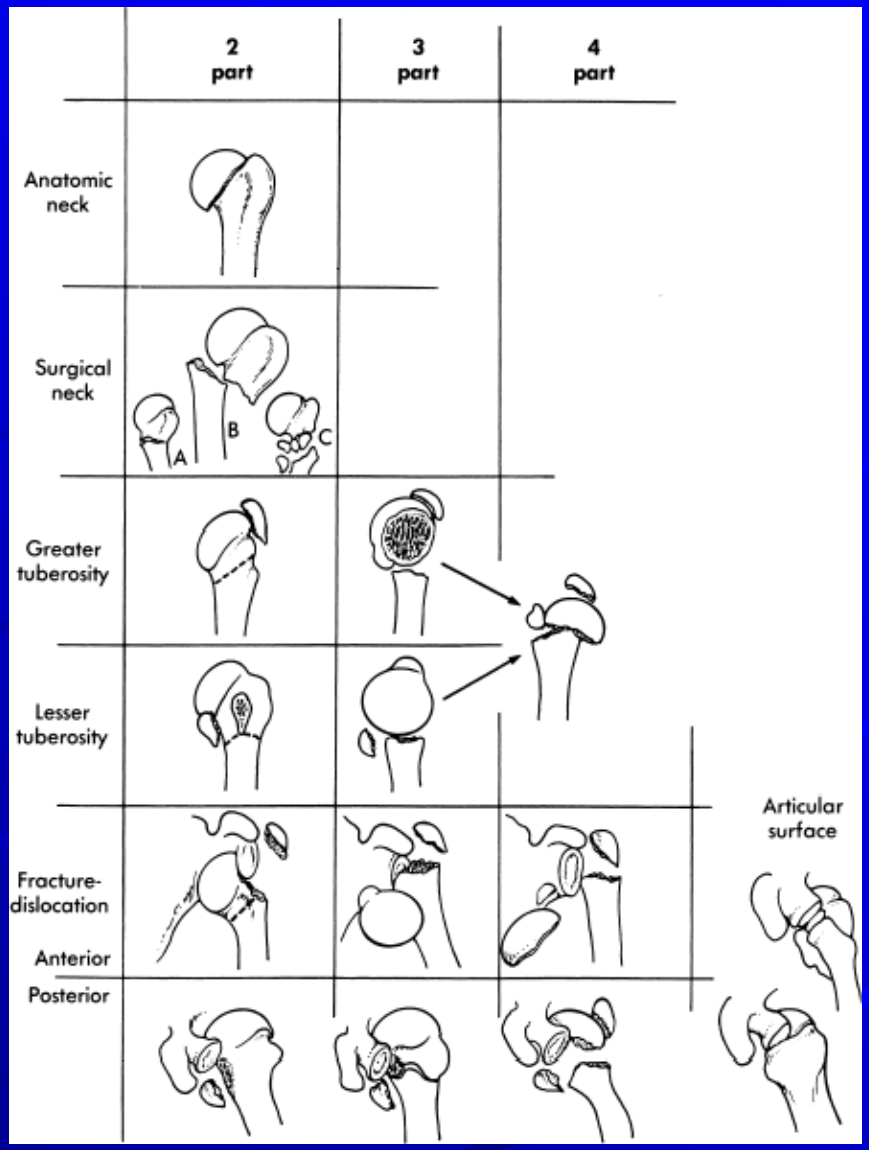

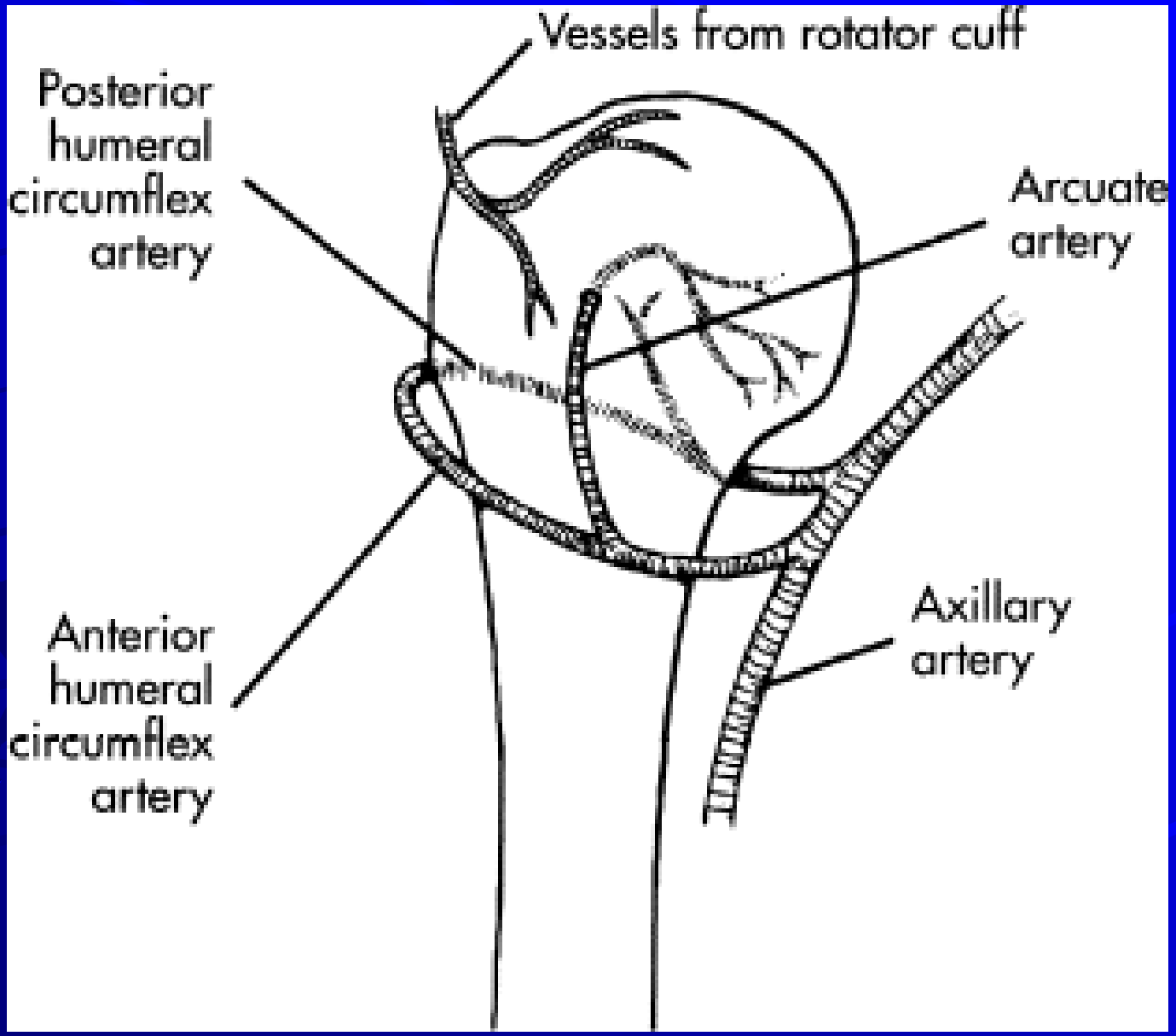
Vessels from rotator cuff
Posterior humeral circumflex artery
Arcuate artery
Anterior humeral circumflex artery
Axillary artery

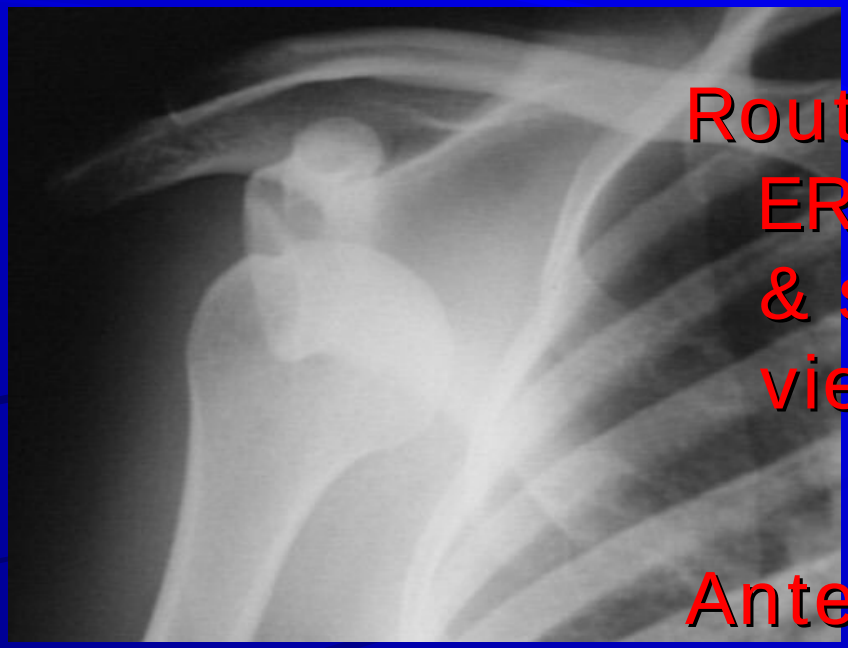

Routine AP
ER, axillar
& scapula
views

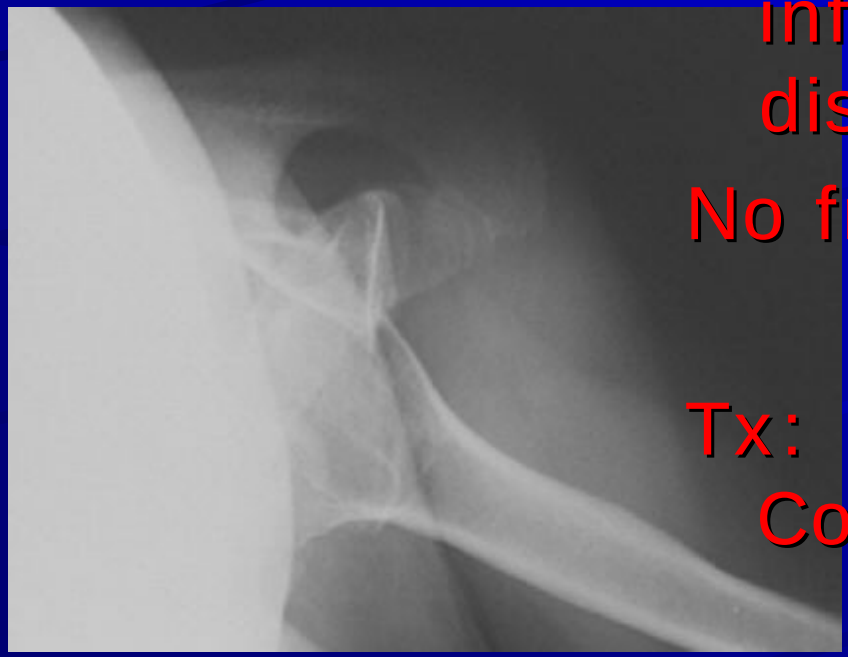

Anterior-
inferior
dislocation

No fracture

Tx:
Conservat

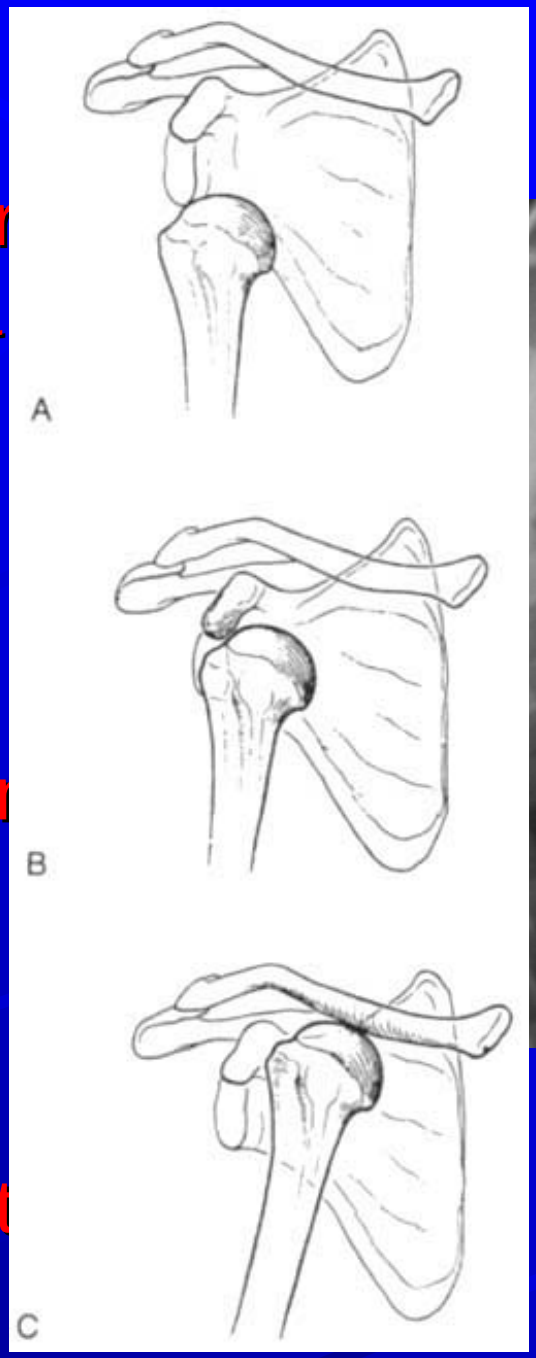

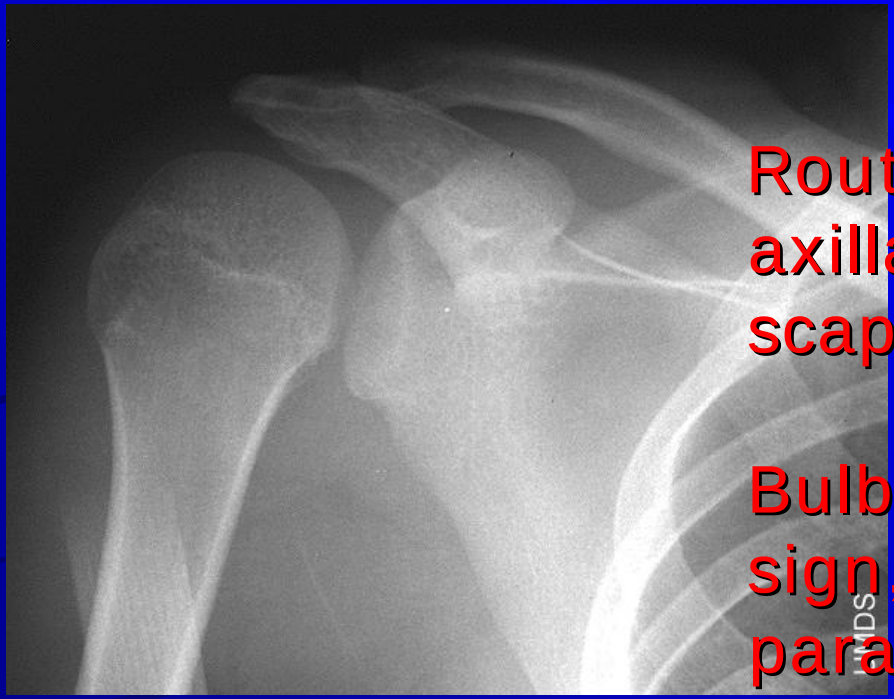

Routine AP in ER, axillary, & scapular Y views

Bulb sign, rim sign, loss of parallelism

Posterior dislocation; No fracture

Tx: Conservative

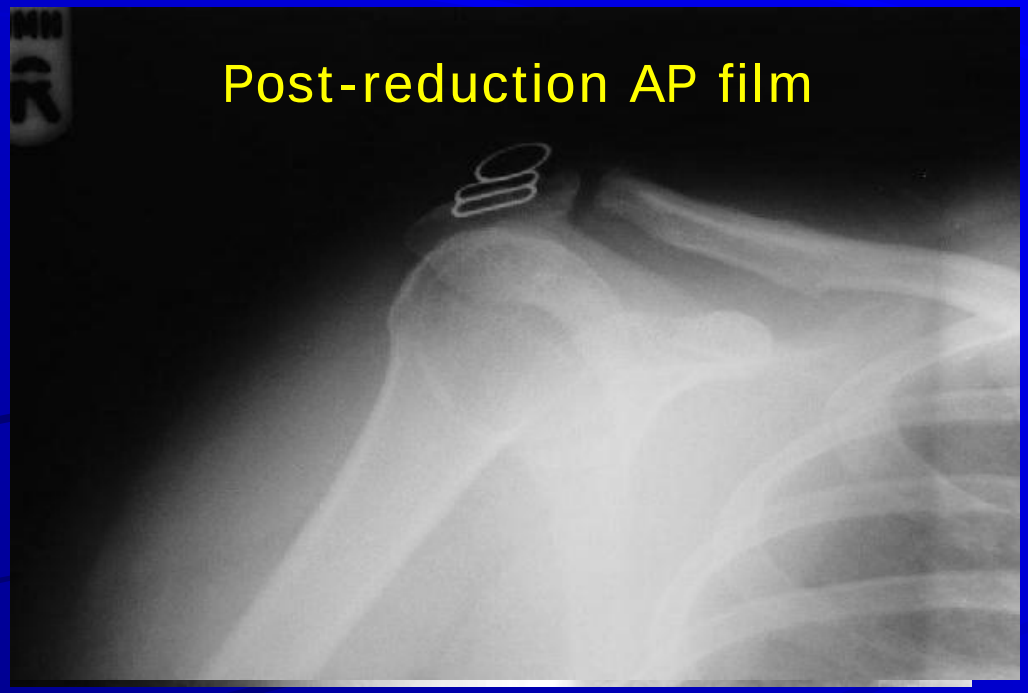

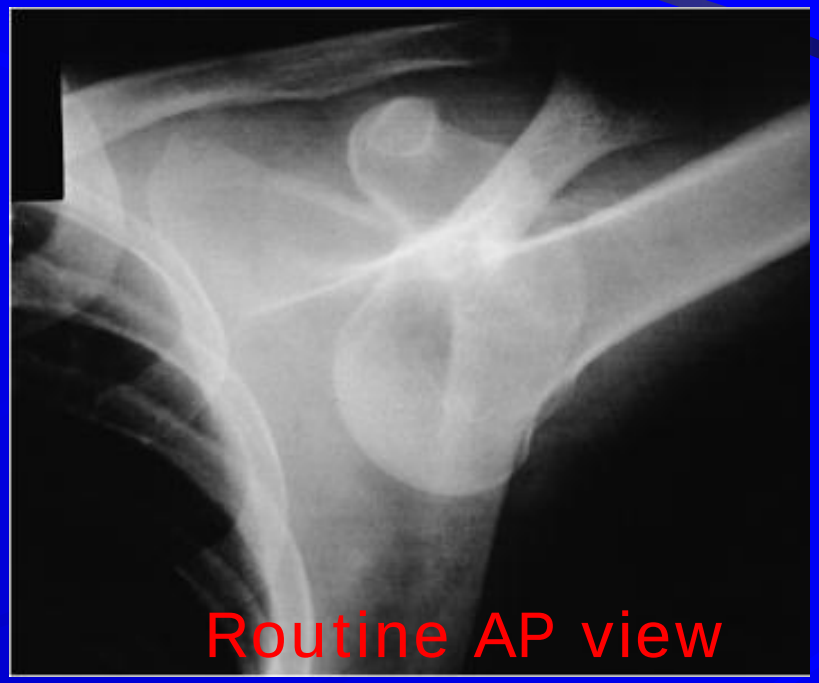

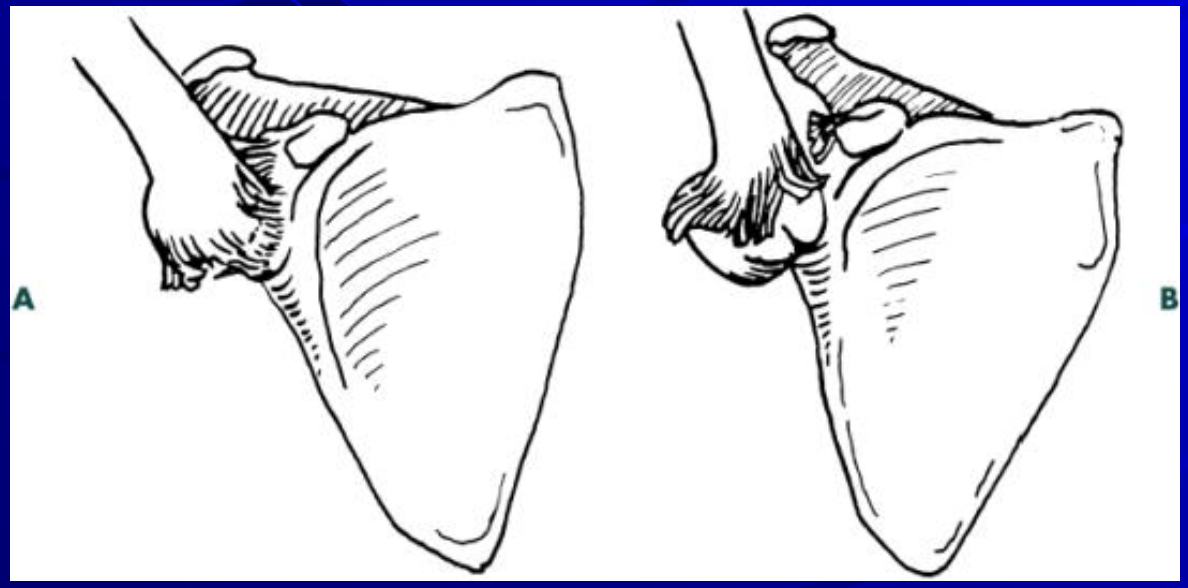

Inferior GH dislocation

(Luxatio erecta)

- Rare

Tx: may attempt CR

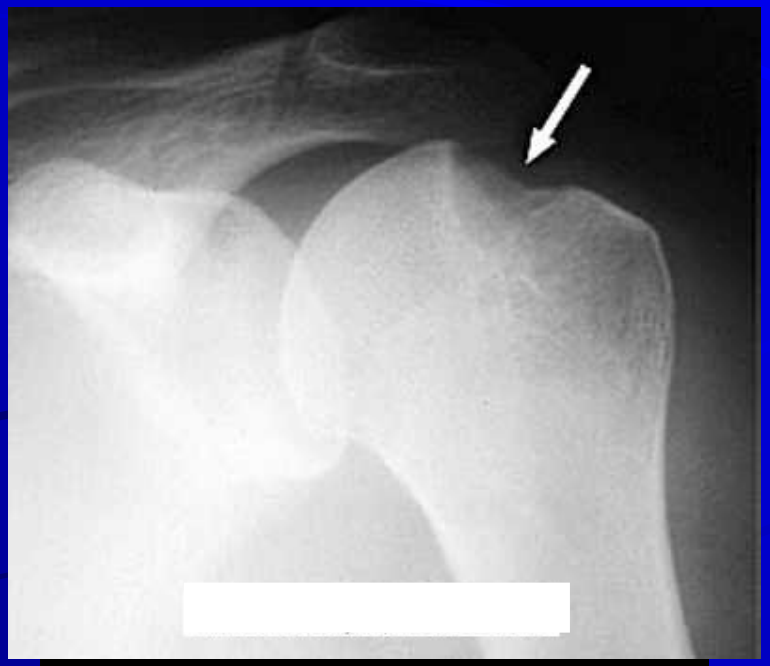

Routine AP in IR and axillary lateral views

No dislocation

+ concave osseous impression in postero-lateral aspect of humeral head

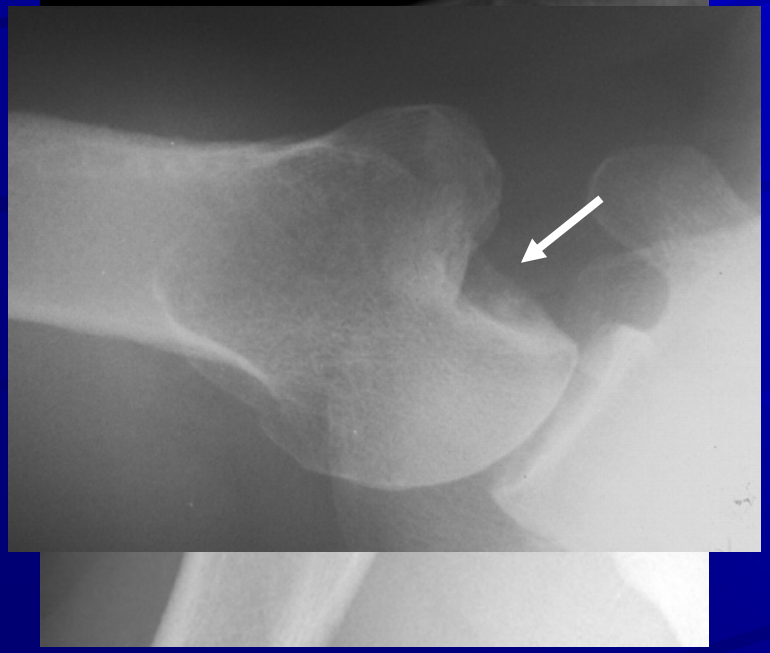

What is this lesion called?

Hill-Sachs lesion

Tx: conservative vs. operative

Hill-Sachs Lesions

Bankart Lesions

Type I: conservative tx

Type II: conservative tx

Type III: conservative tx for most; may consider surgery for active heavy laborers, frequent overhead activity, athletes 20-25 y/o

Type III AC separation

Tx: conservative mostly

Type IV-VI: surgery

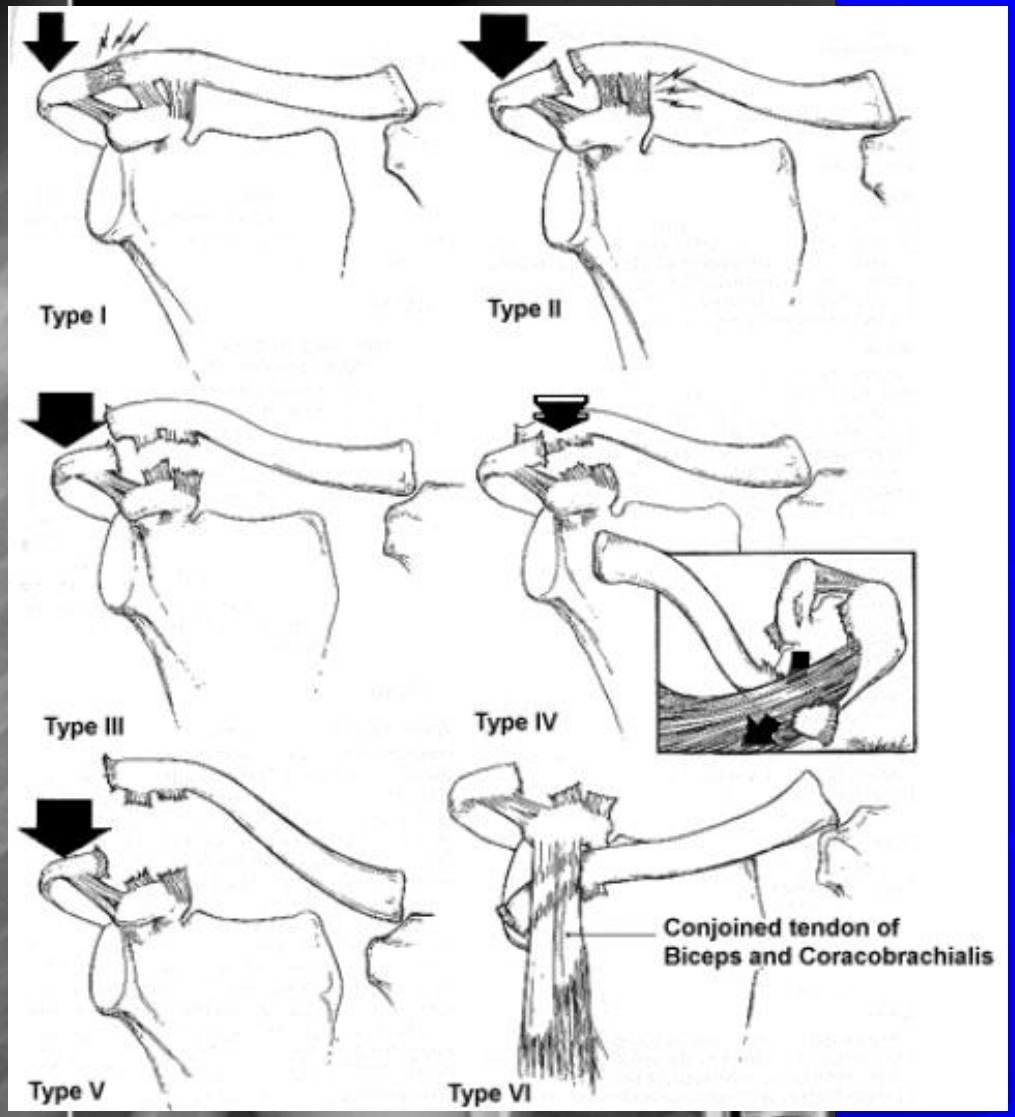

- Clavicle Fractures
- Mostly conservative treatment
- Consider surgery for:
  - Group II Fx's (esp if medial to CCL)
  - Open fractures
  - Neurovascular compromise
- Severe associated injuries
  - E.g. flail chest, mult rib fx's, scapulothoracic dissociation
- [illegible] / malunion

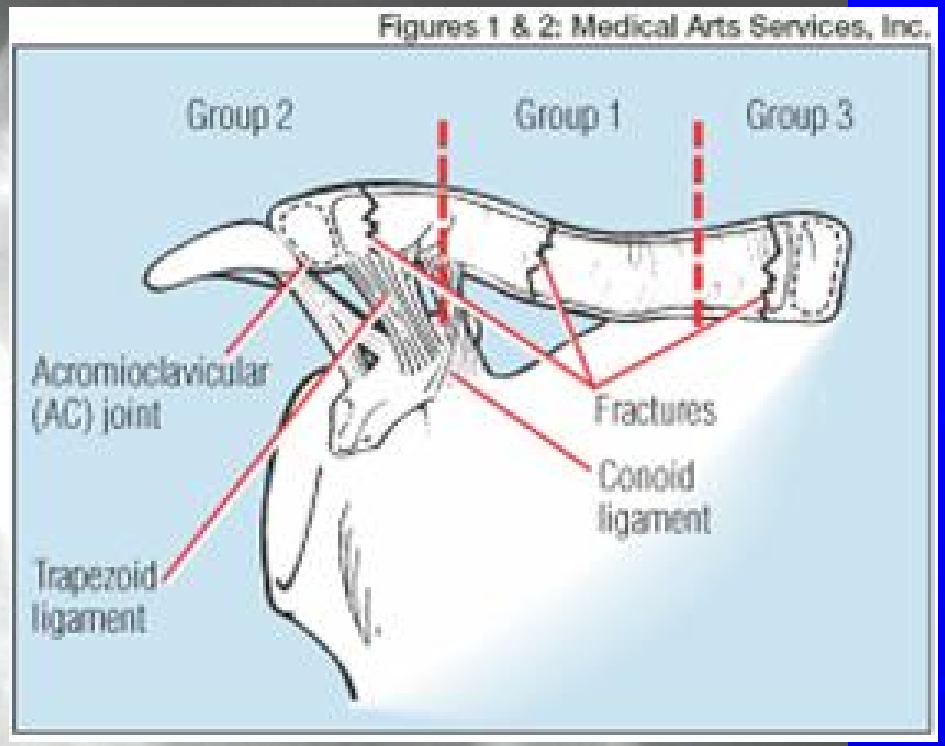

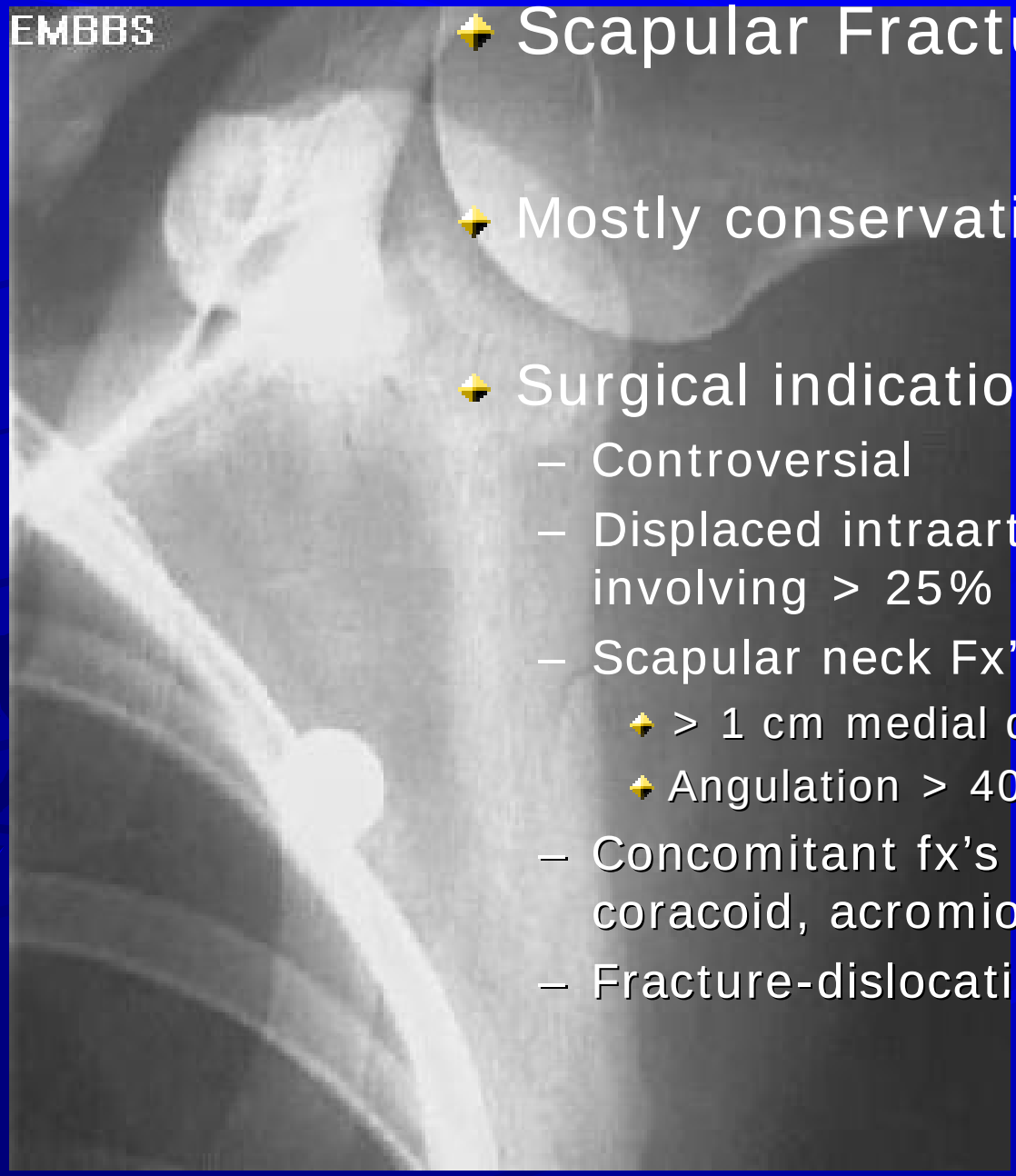

Scapular Fractures

- Mostly conservative treatment
- Surgical indications:
  - Controversial
  - Displaced intraarticular fx's involving > 25% articular surface
  - Scapular neck Fx's with
    - > 1 cm medial displaced
    - Angulation > 40 °
  - Concomitant fx's of clavicles, coracoid, acromion, scapular spine
  - Fracture-dislocations

Routine AP and Axillary Lateral Views

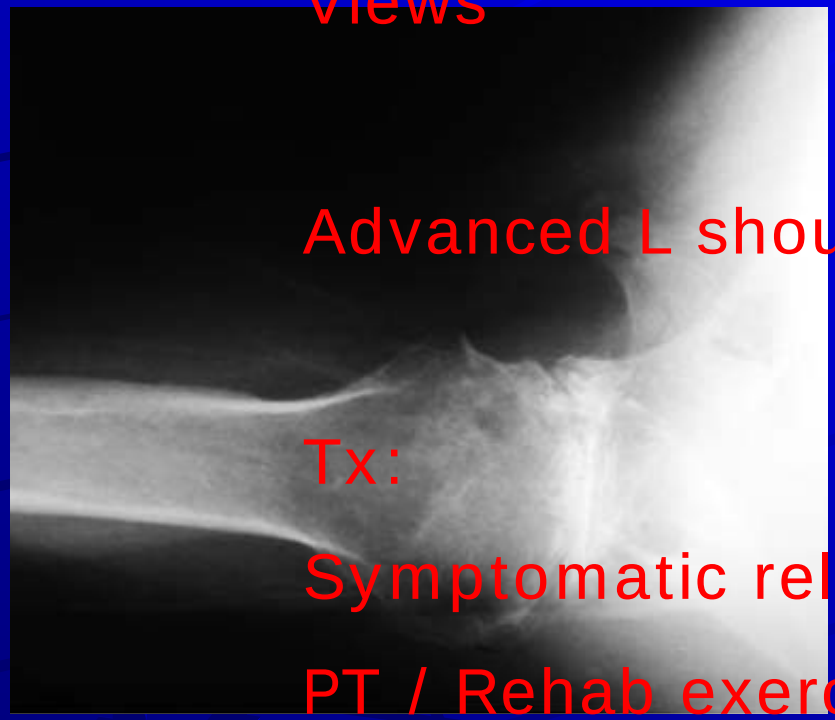

Advanced L shoulder osteoarthritis

Tx:

Symptomatic relief

PT / Rehab exercises

Injections

Consider surgical eval

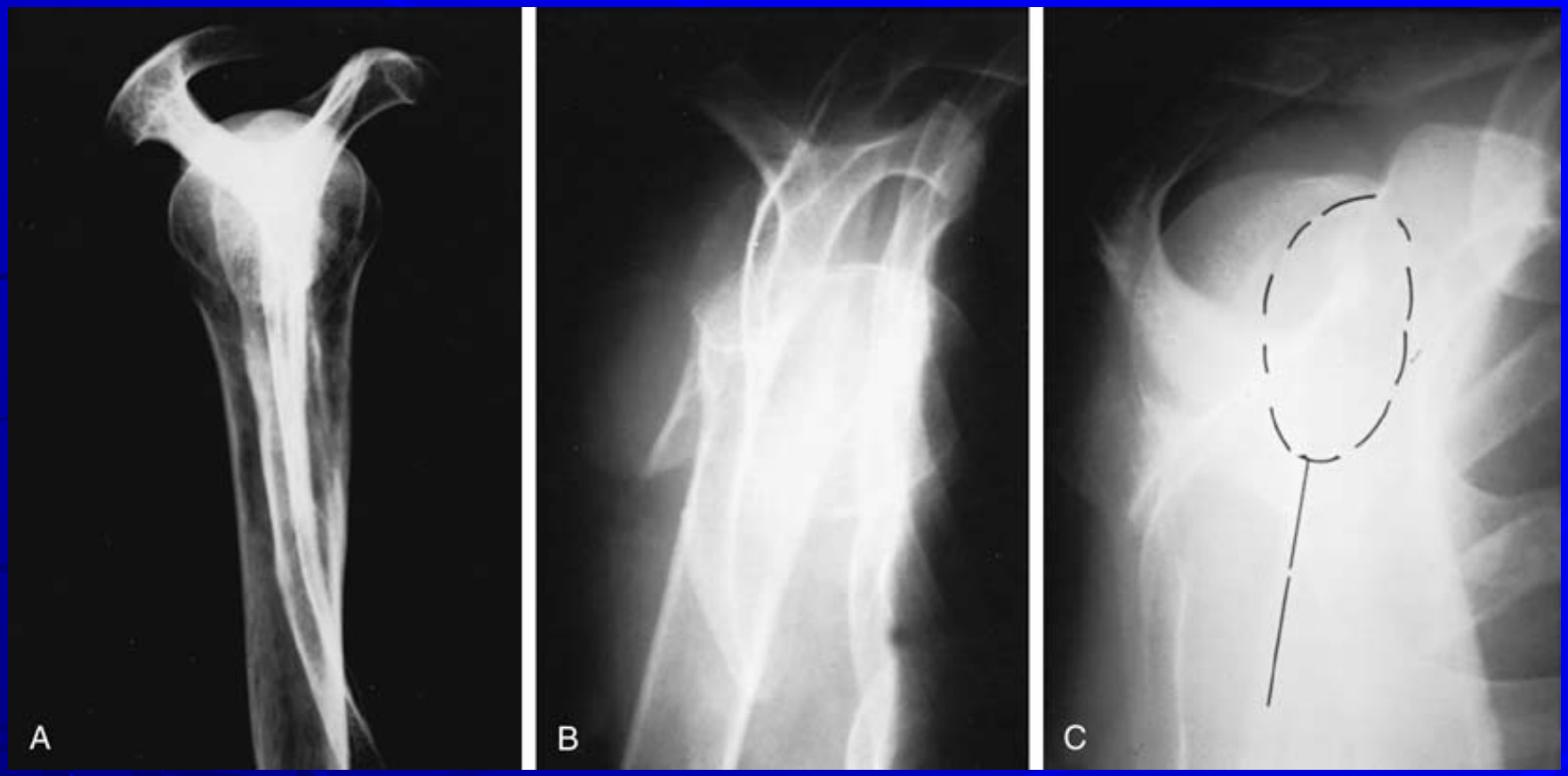

Scapular Y views

A: normal

B: Fracture / anterior dislocation

C: Posterior dislocation

Routine AP, “True” AP, and Axillary lateral views

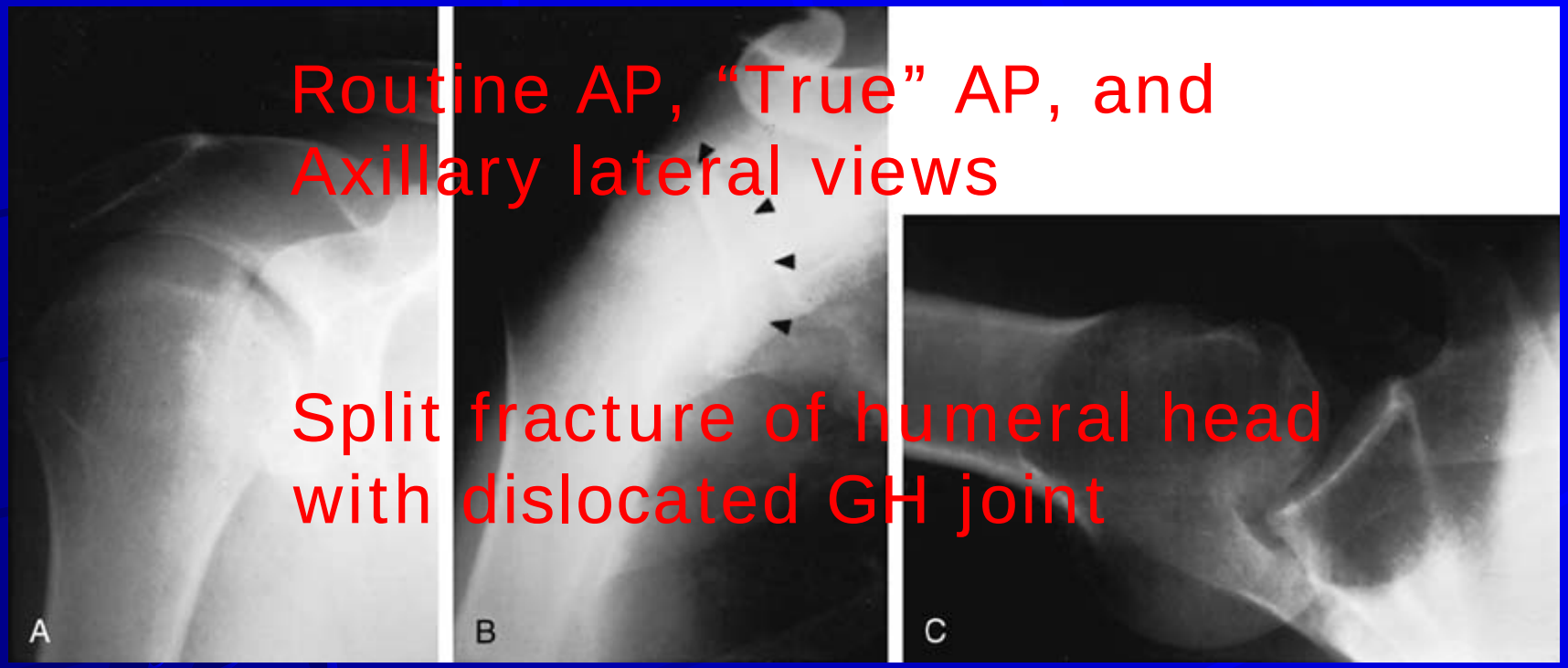

Split fracture of humeral head with dislocated GH joint

Tx: Surgerize!

34 y/o M with shoulder pn and “it feel like it wants to go out of socket”

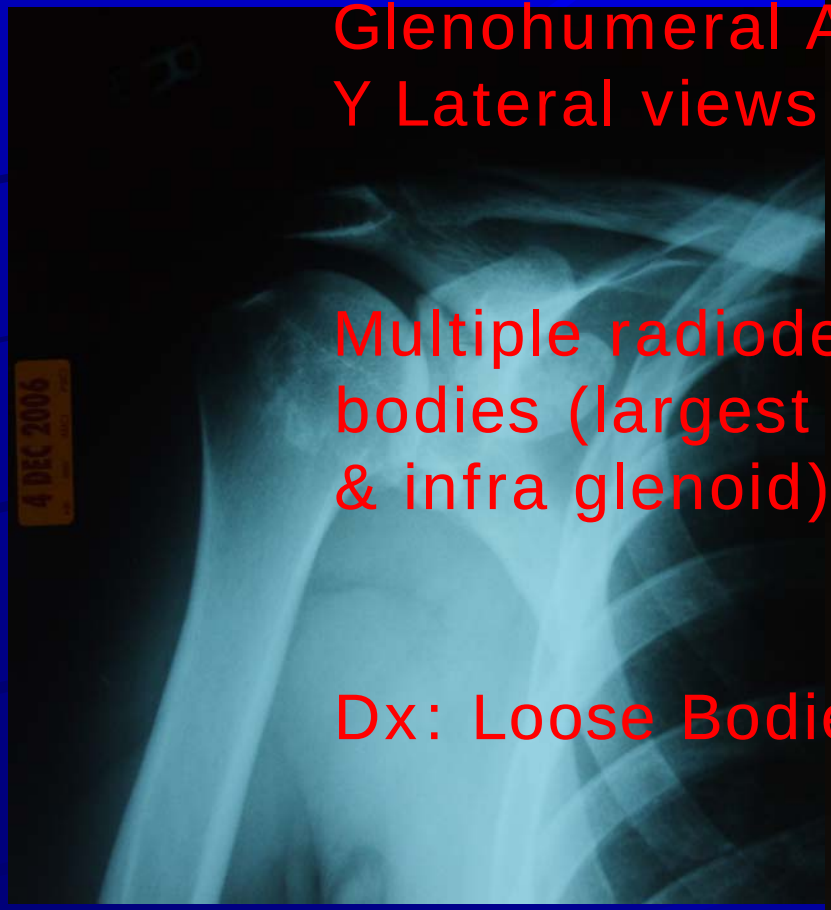

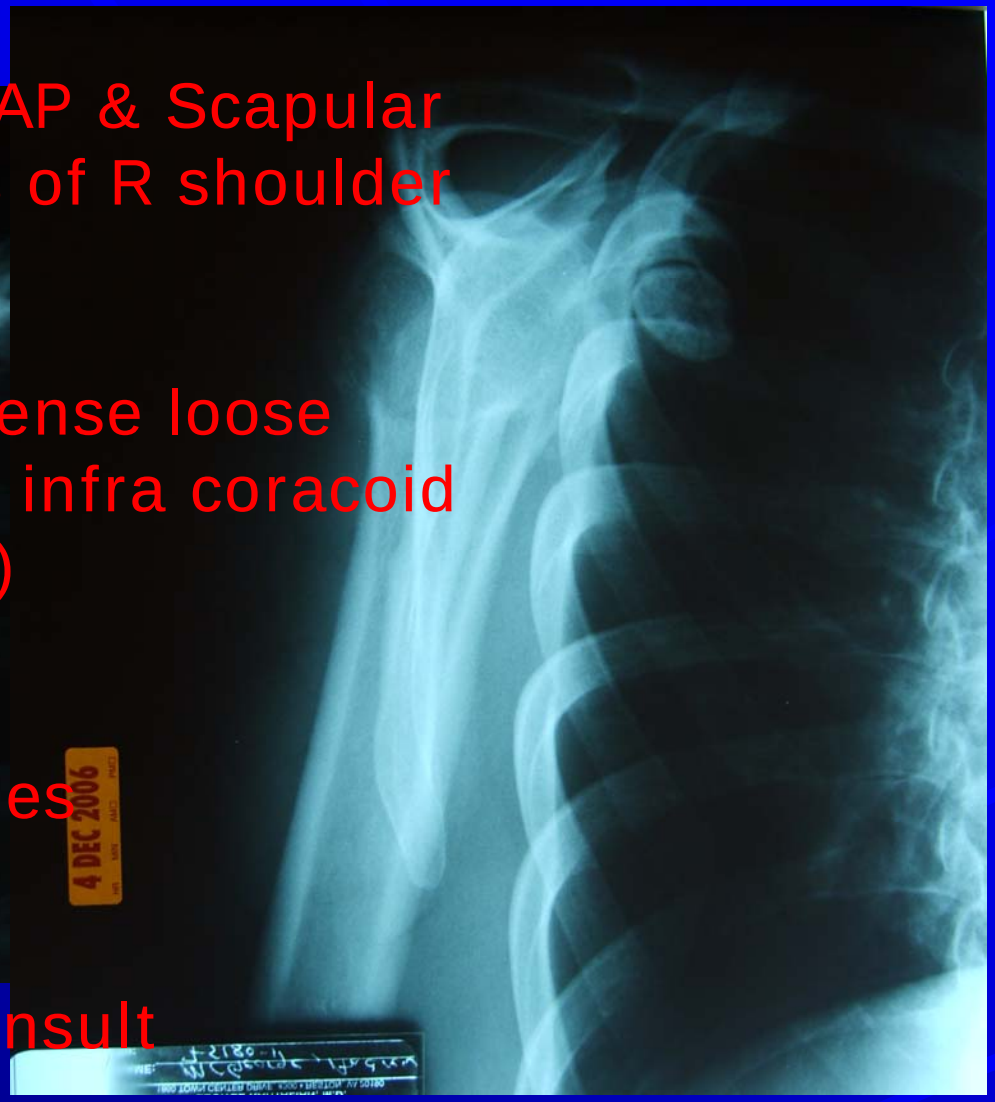

Glenohumeral AP & Scapular Y Lateral views of R shoulder

Multiple radiodense loose bodies (largest infra coracoid & infra glenoid)

Dx: Loose Bodies

Tx: Surgical consult

Glenohumeral AP view of shoulder and humerus

Radiolucent lesions spanning proximal third of L humerus

Enchondromas

Tx: Surgical consult (Biopsy)

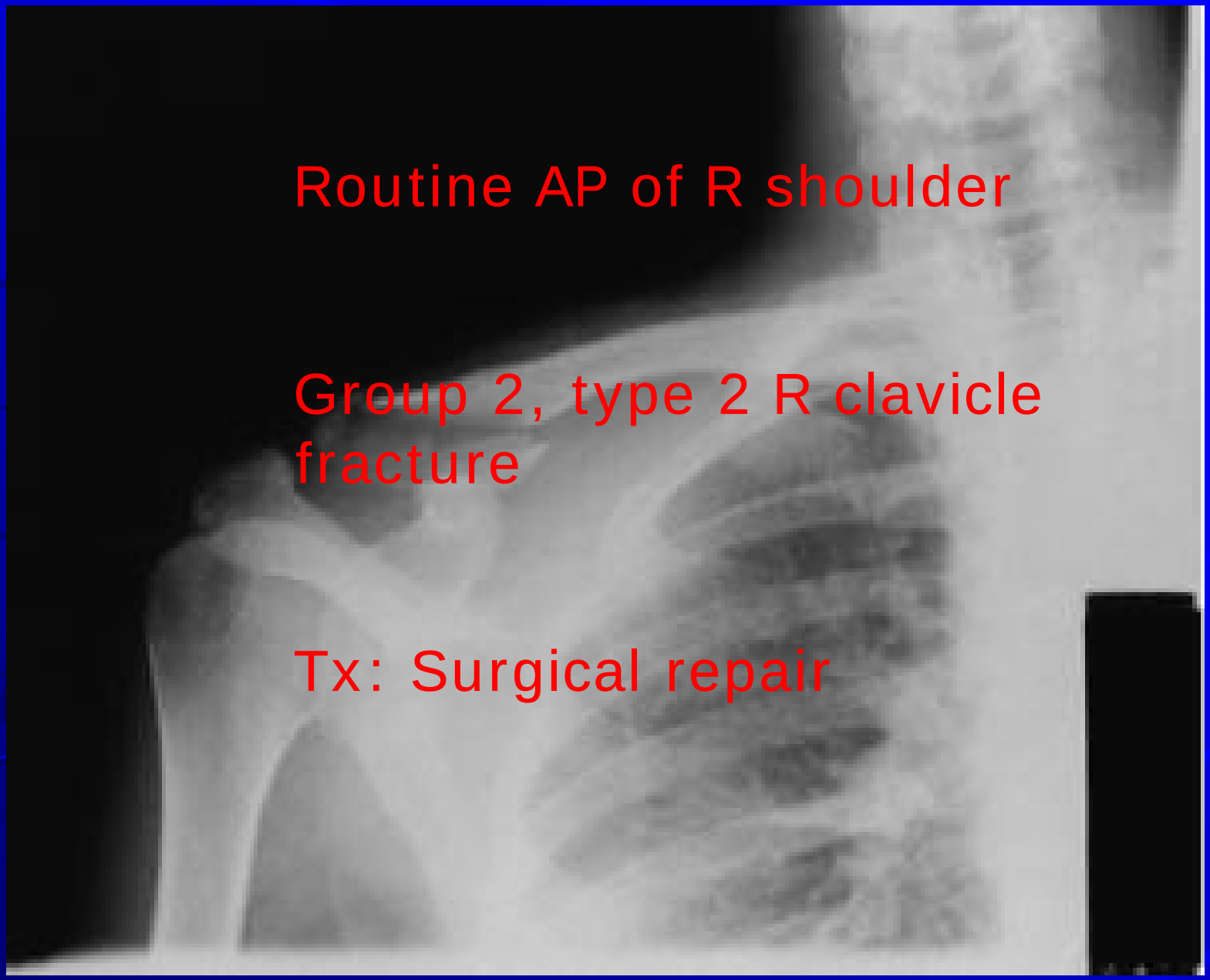

Routine AP of R shoulder

Group 2, type 2 R clavicle fracture

Tx: Surgical repair

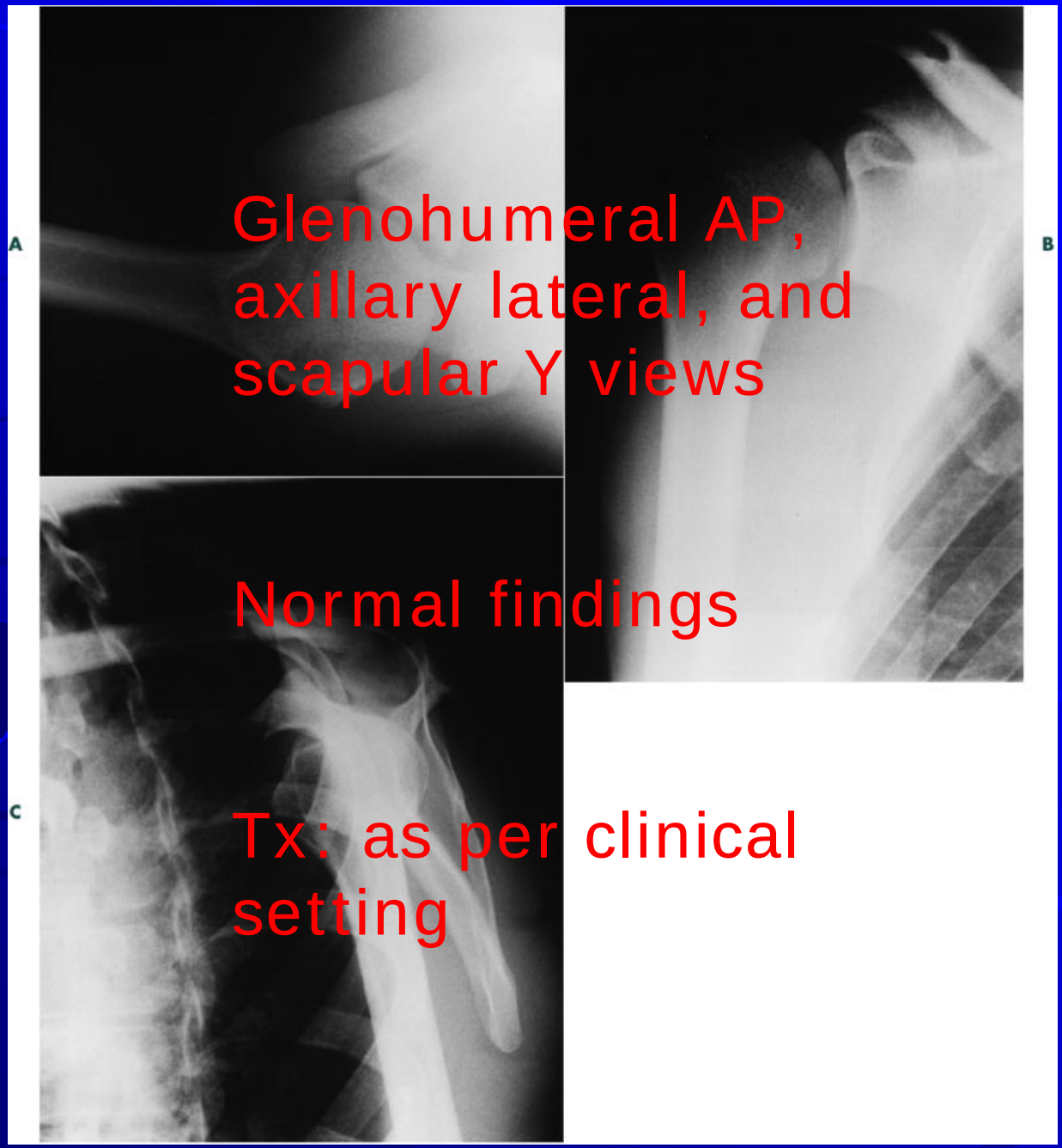

Glenohumeral AP, axillary lateral, and scapular Y views

Normal findings

Tx: as per clinical setting

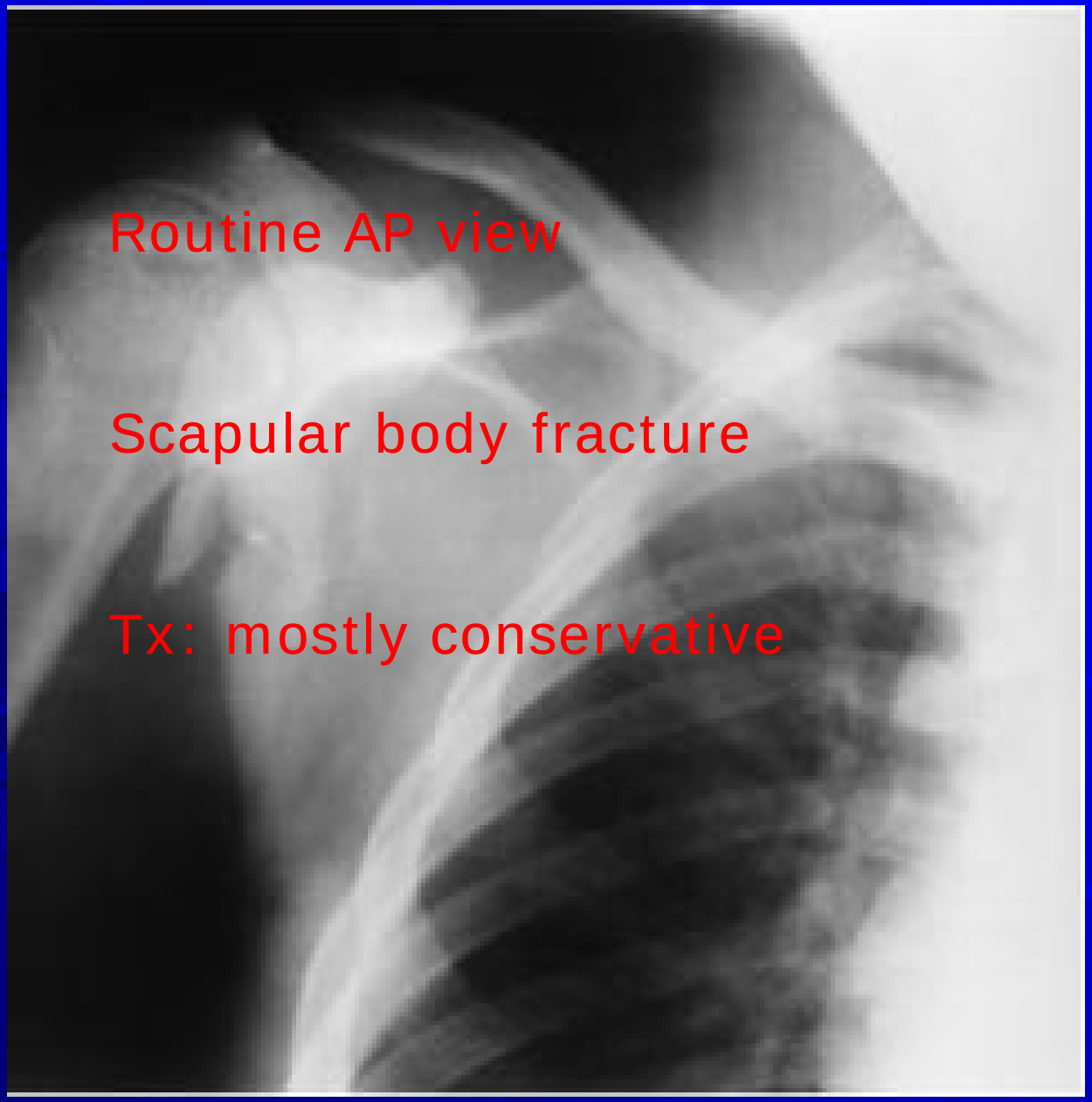

Routine AP view

Scapular body fracture

Tx: mostly conservative

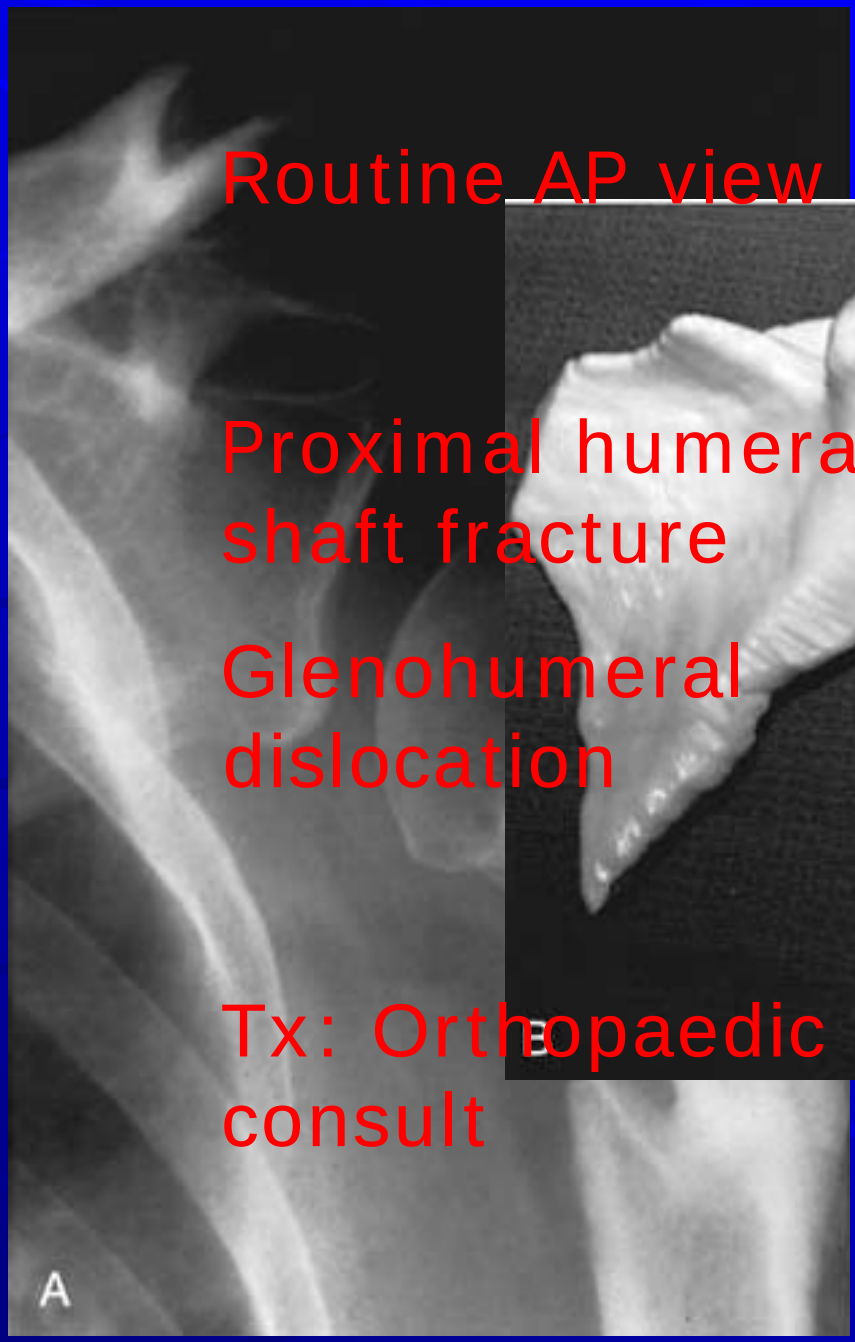

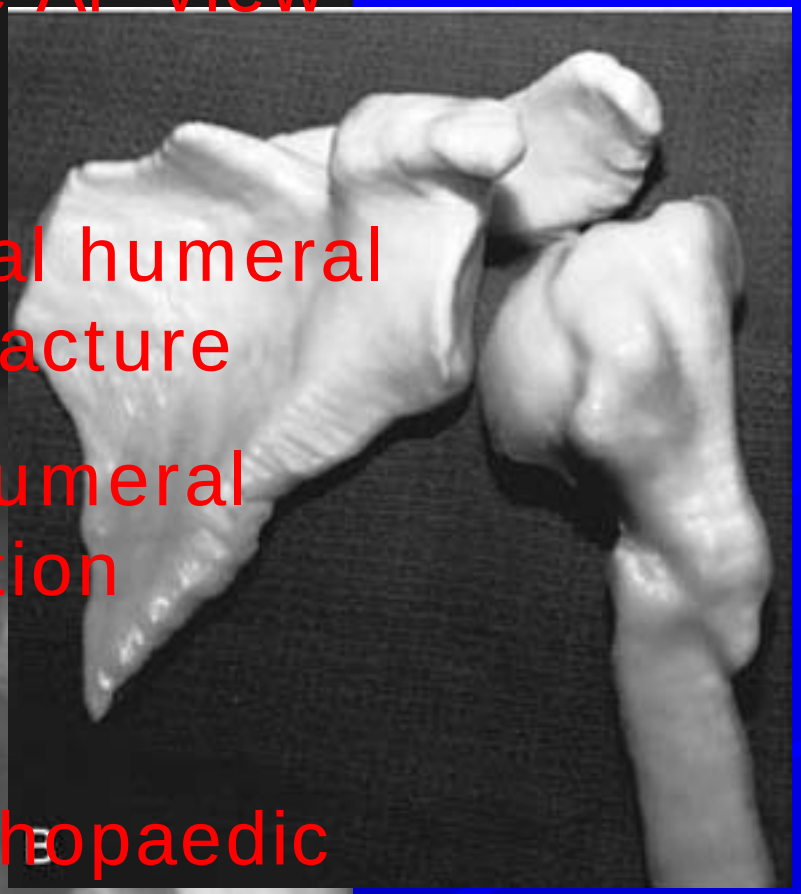

Routine AP view

Proximal humeral shaft fracture

Glenohumeral dislocation

Tx: Orthopaedic consult

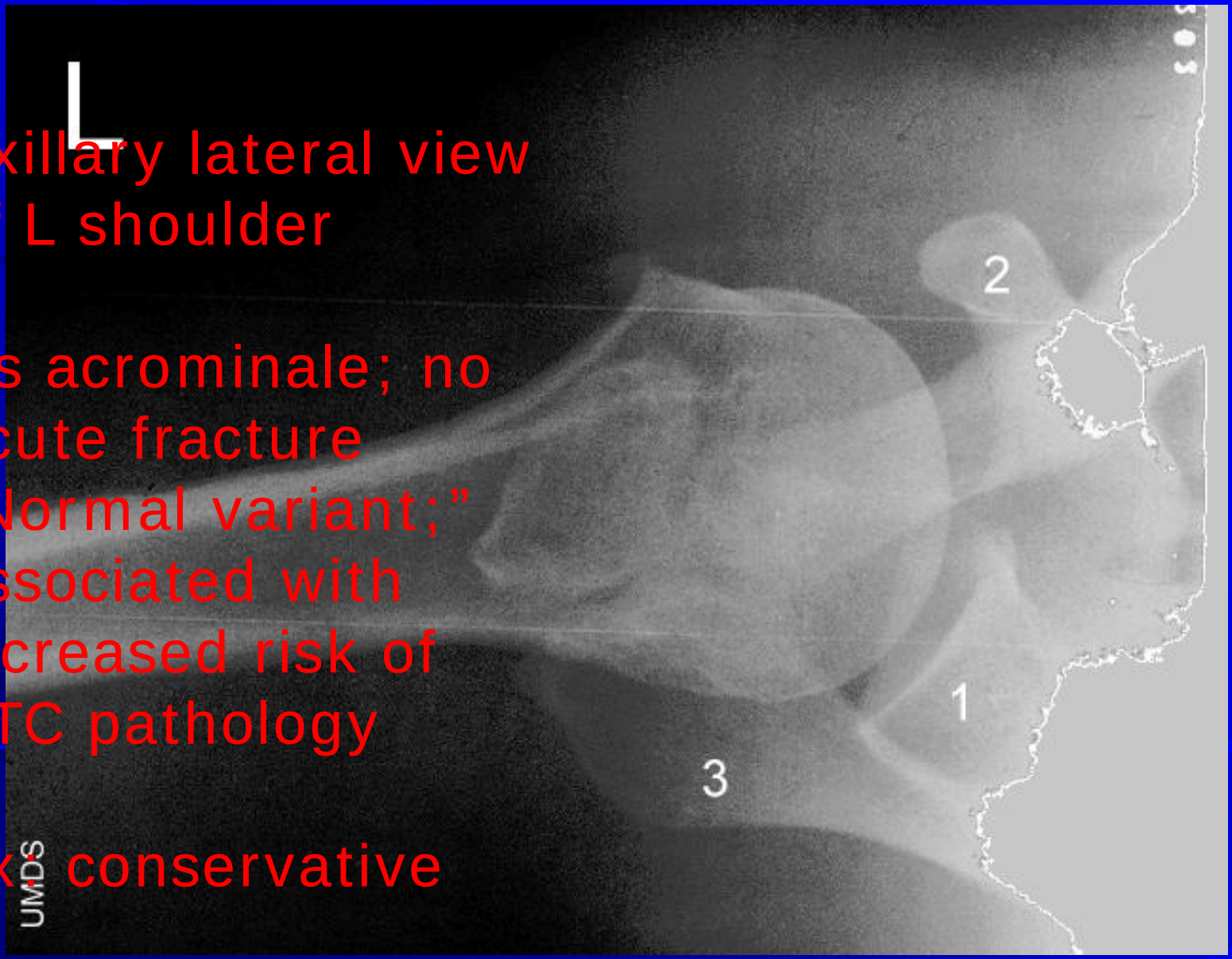

Axillary lateral view of L shoulder

Os acrominale; no acute fracture
"Normal variant;" associated with increased risk of RTC pathology

Tx: conservative

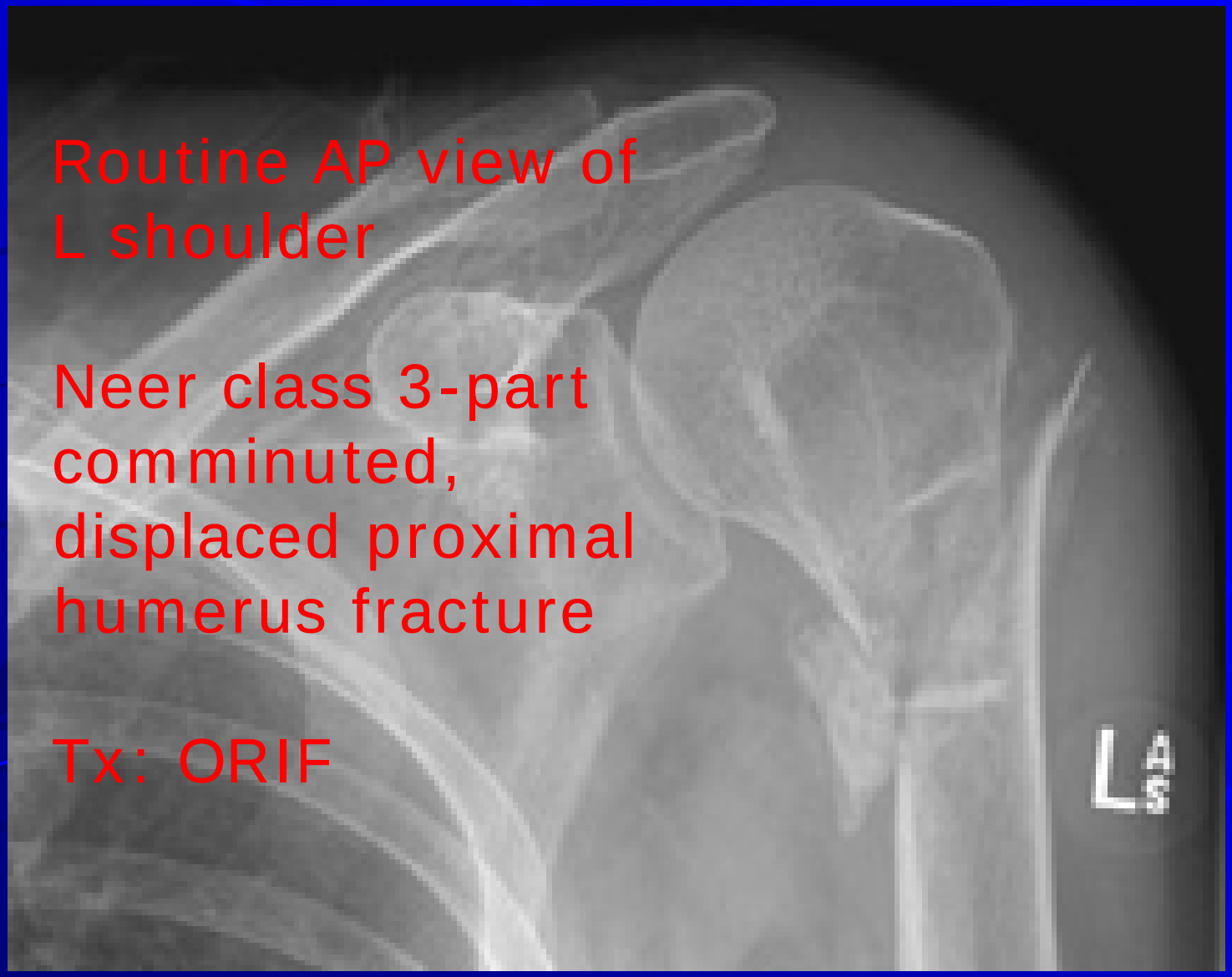
Routine AP view of
L shoulder
Neer class 3-part
comminuted,
displaced proximal
humerus fracture
Tx: ORIF
L

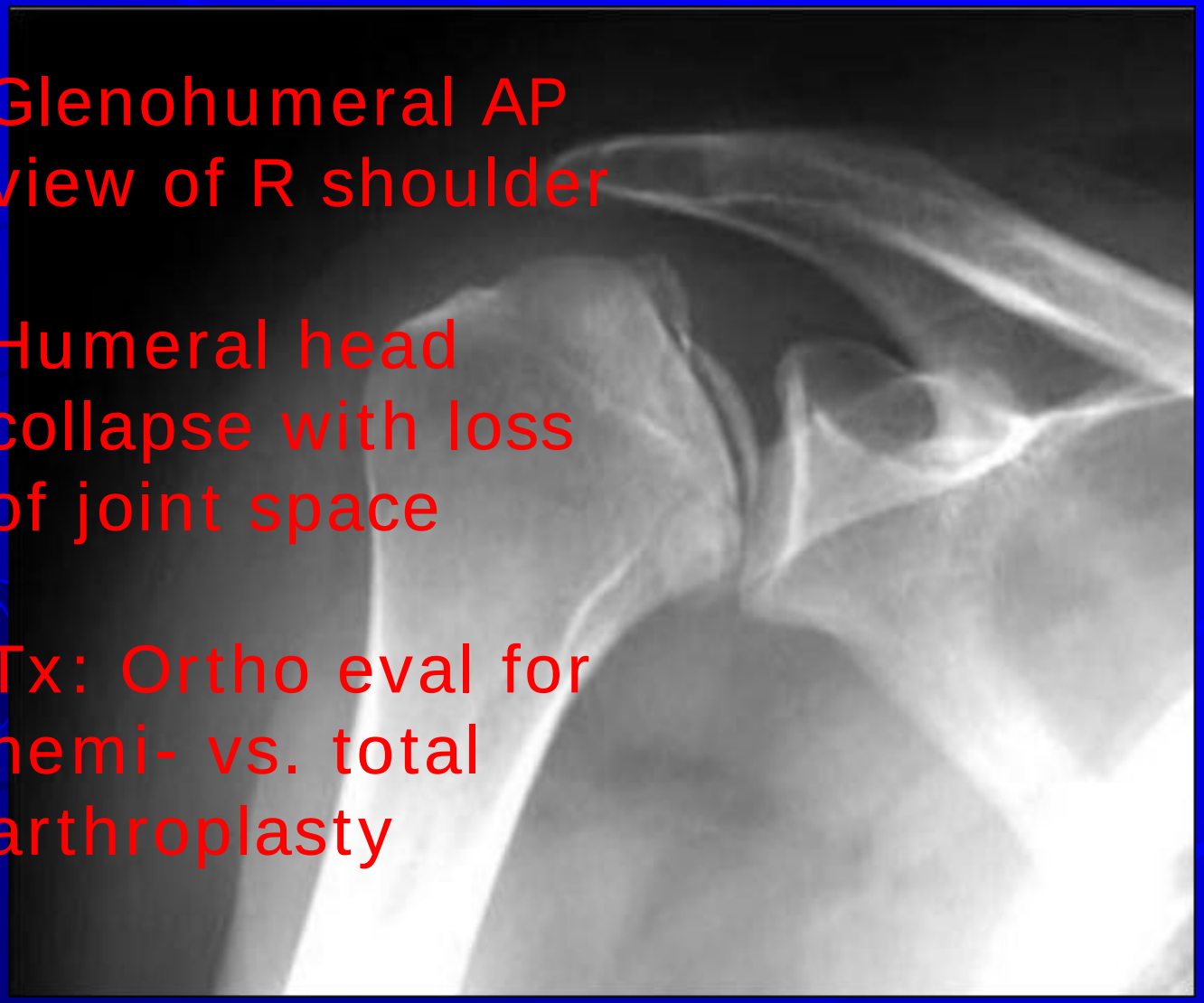

Glenohumeral AP view of R shoulder

Humeral head collapse with loss of joint space

Tx: Ortho eval for hemi- vs. total arthroplasty

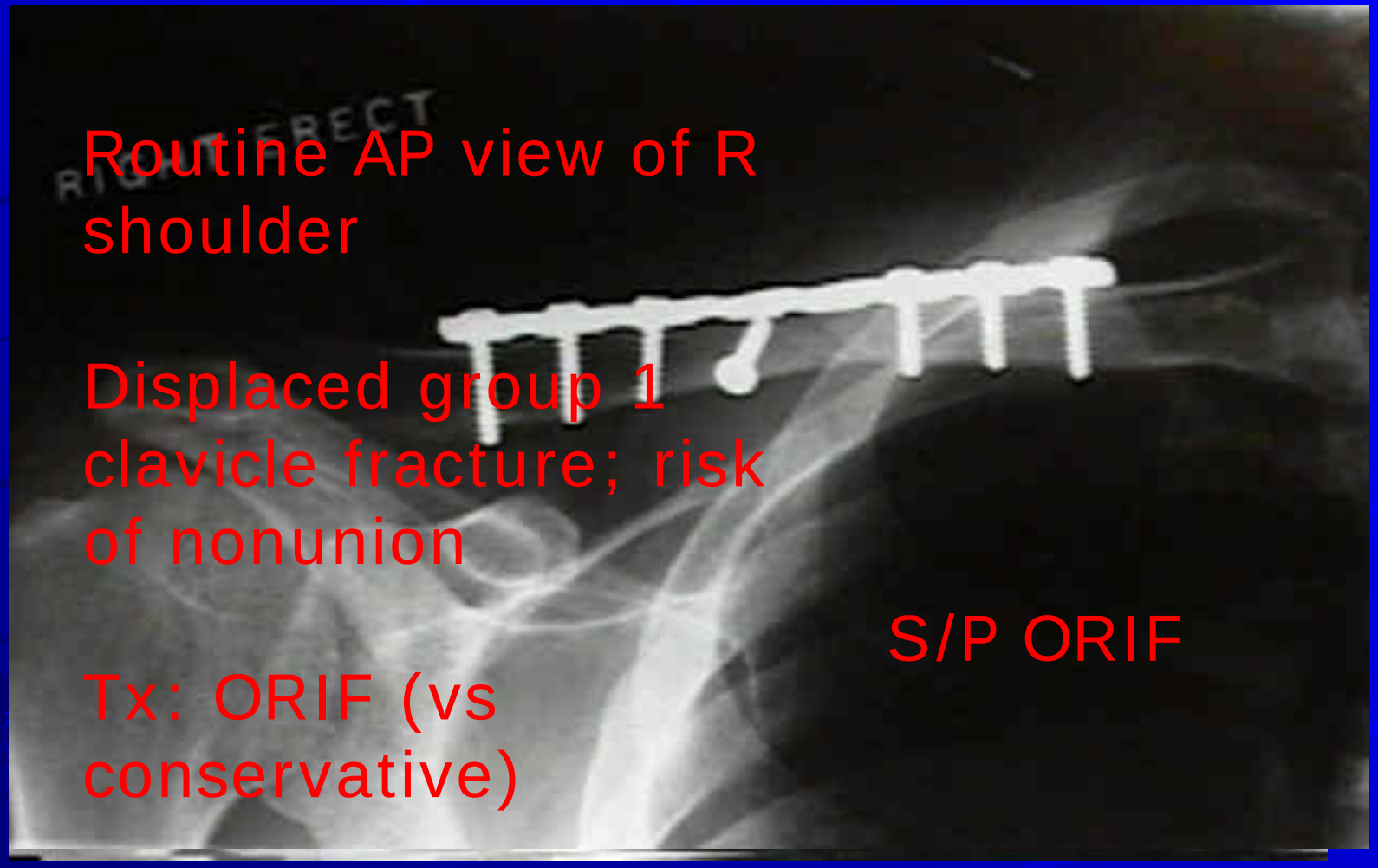
Routine AP view of R shoulder
Displaced group 1 clavicle fracture; risk of nonunion
Tx: ORIF (vs conservative)
S/P ORIF

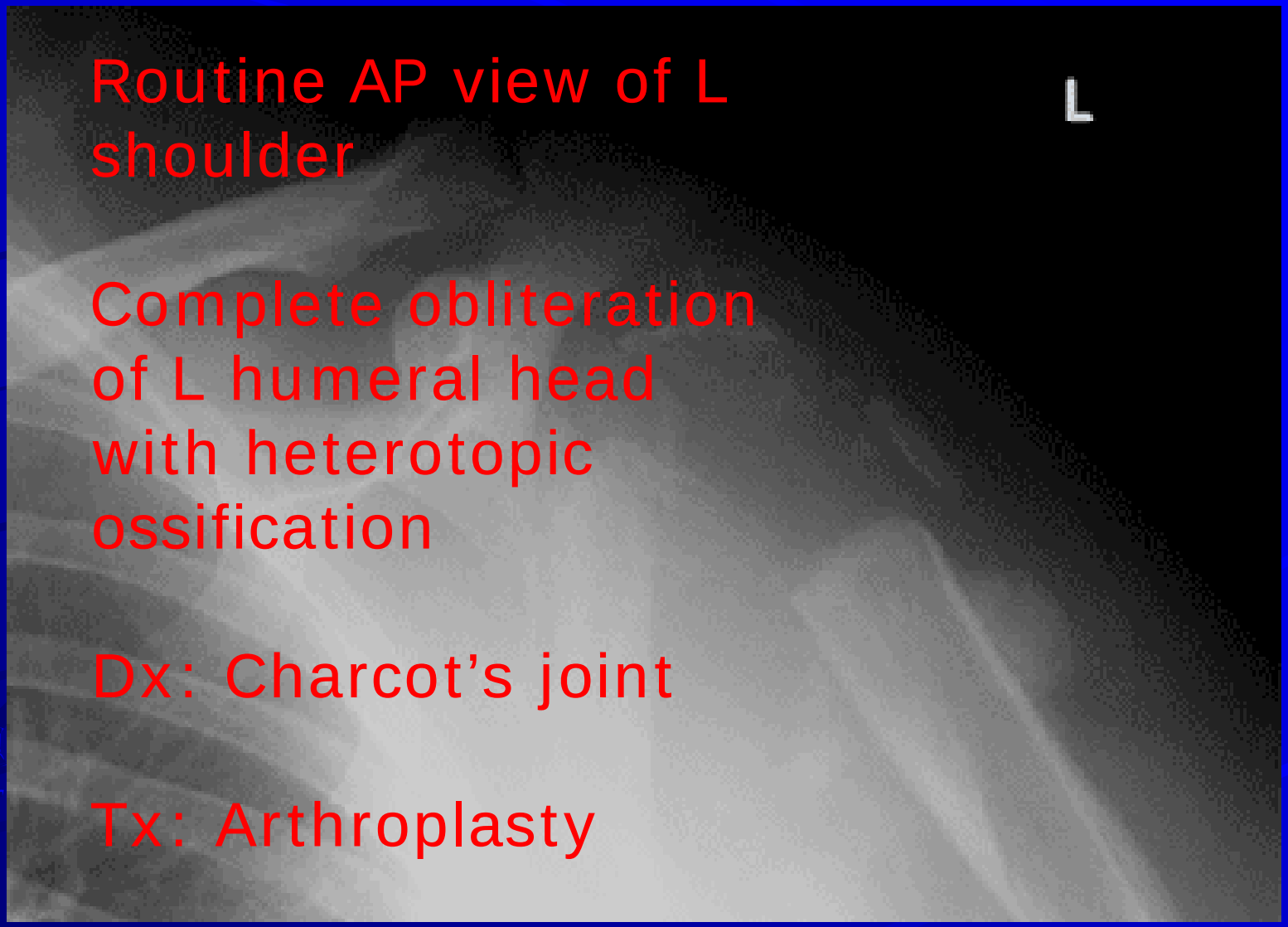

Routine AP view of L shoulder

Complete obliteration of L humeral head with heterotopic ossification

Dx: Charcot's joint

Tx: Arthroplasty

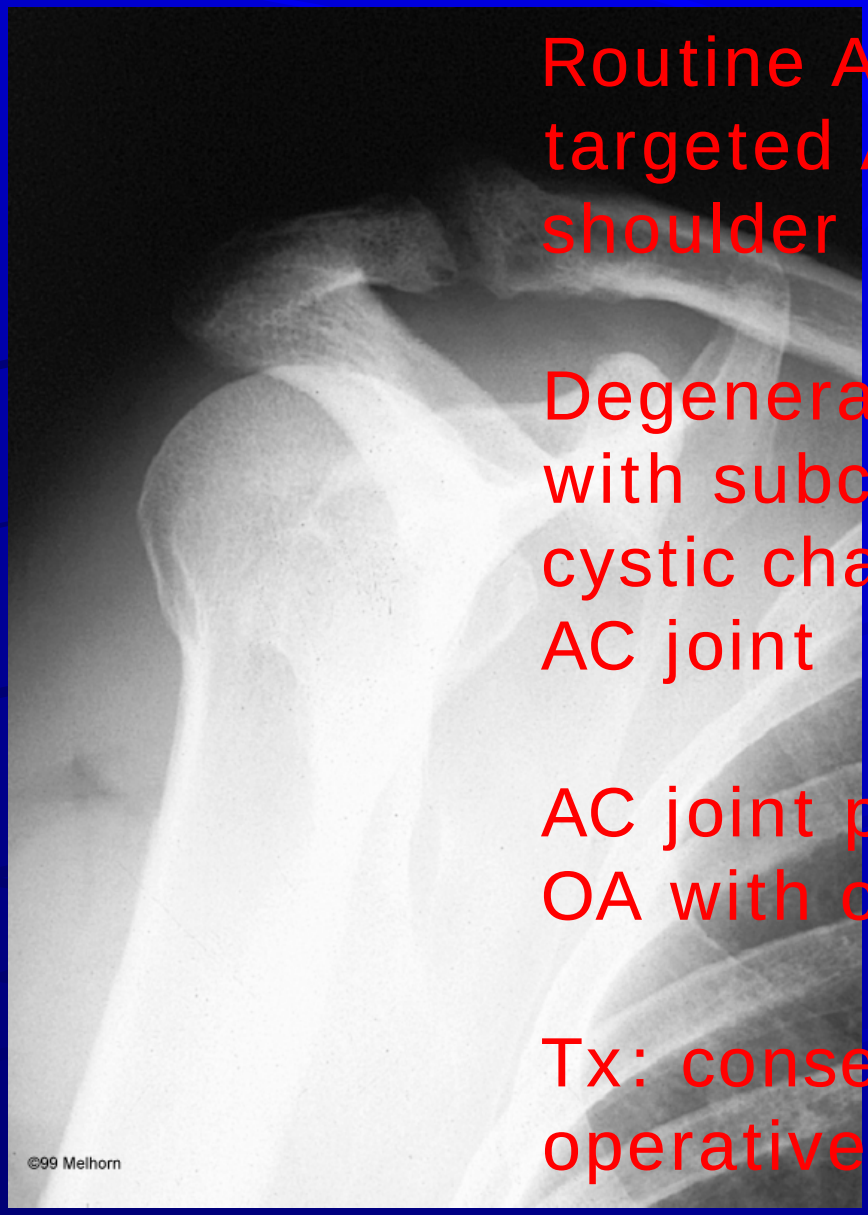

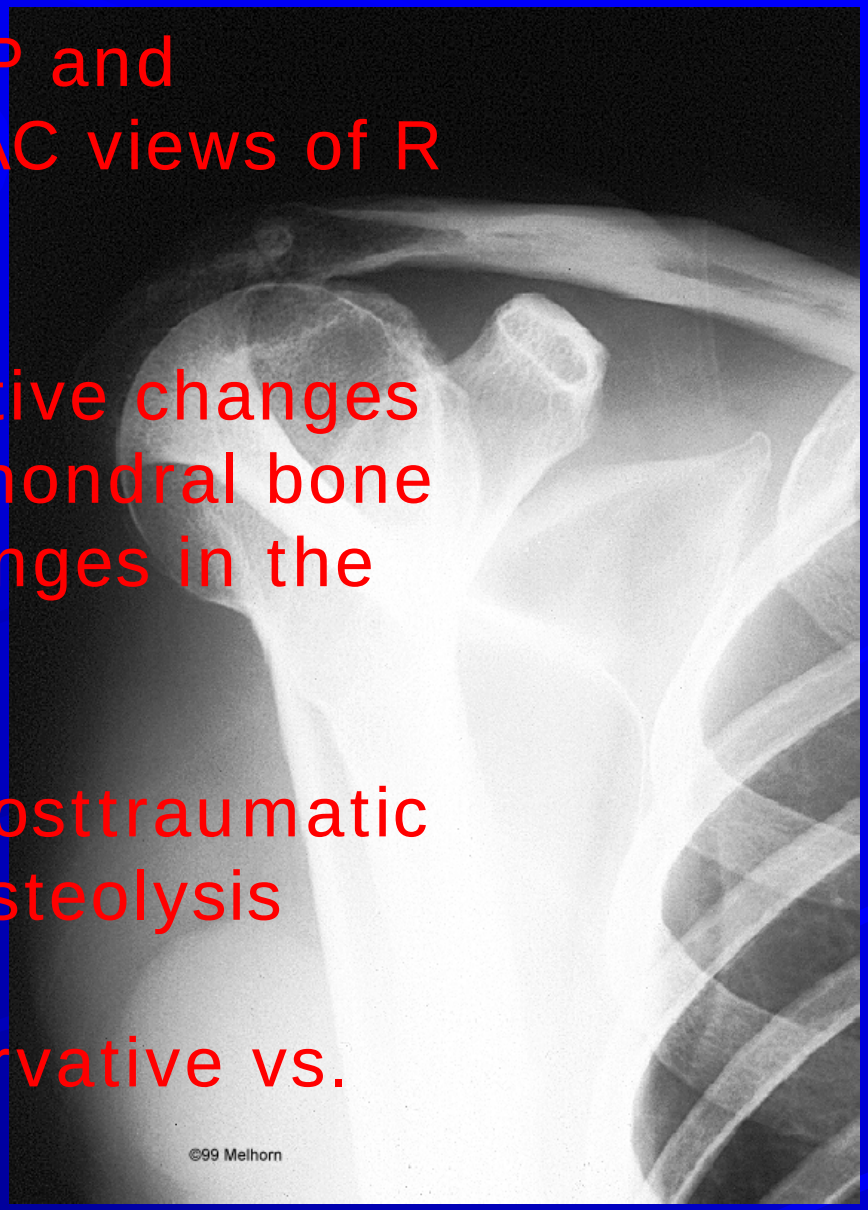

Routine AP and targeted AC views of R shoulder

Degenerative changes with subchondral bone cystic changes in the AC joint

AC joint posttraumatic OA with osteolysis

Tx: conservative vs. operative

Summary

- Know what views to order when:
  - In general:
    - Routine AP with shoulder in internal rotation (IR)
    - “True” glenohumeral AP in external rotation (ER)
    - Axillary lateral view
  - Use alternative lateral views if pt unable to tolerate axillary lateral
    - Modified axillary lateral, Velpeau view, scapular Y
- Know how to describe what you see