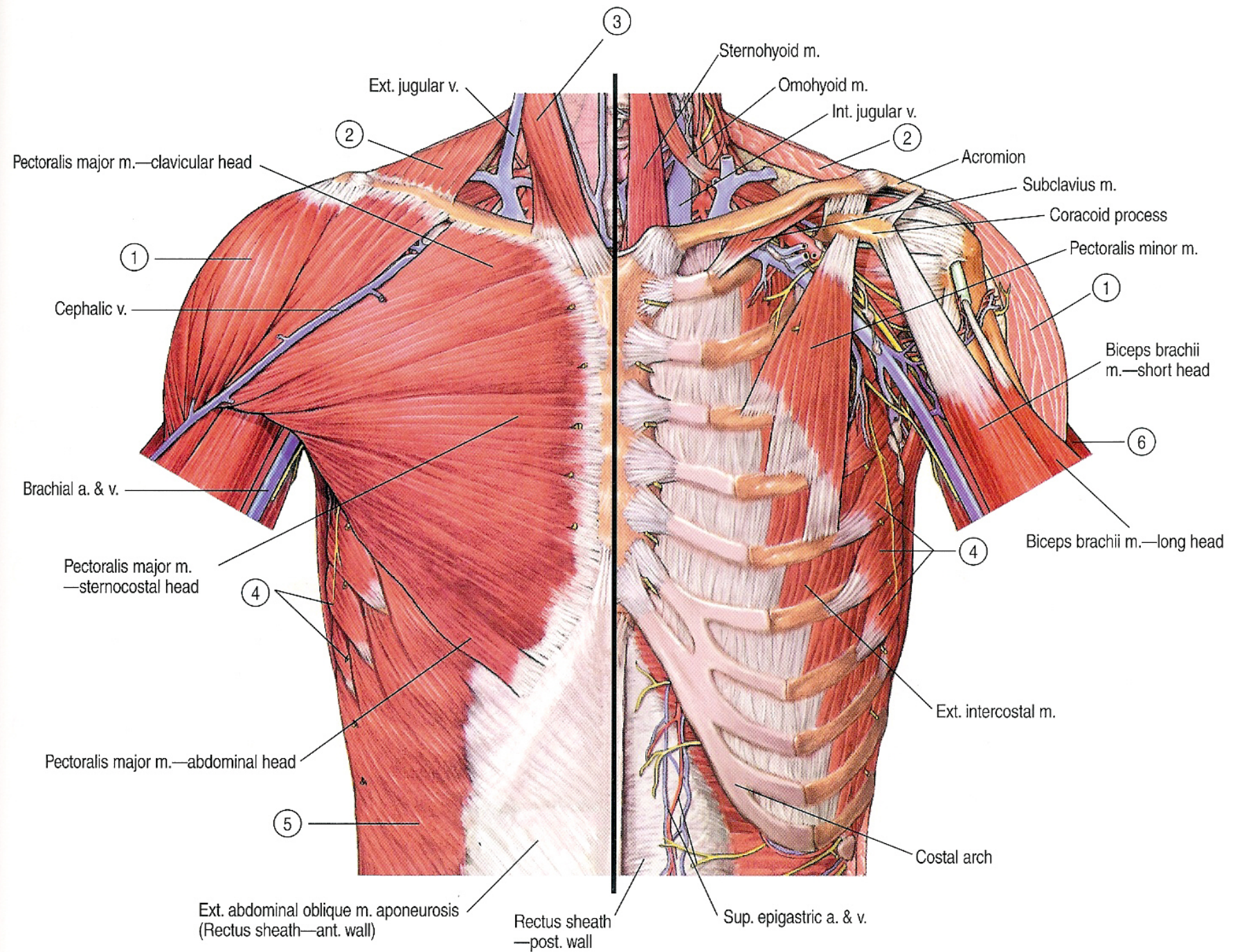


Upper Limb Muscles

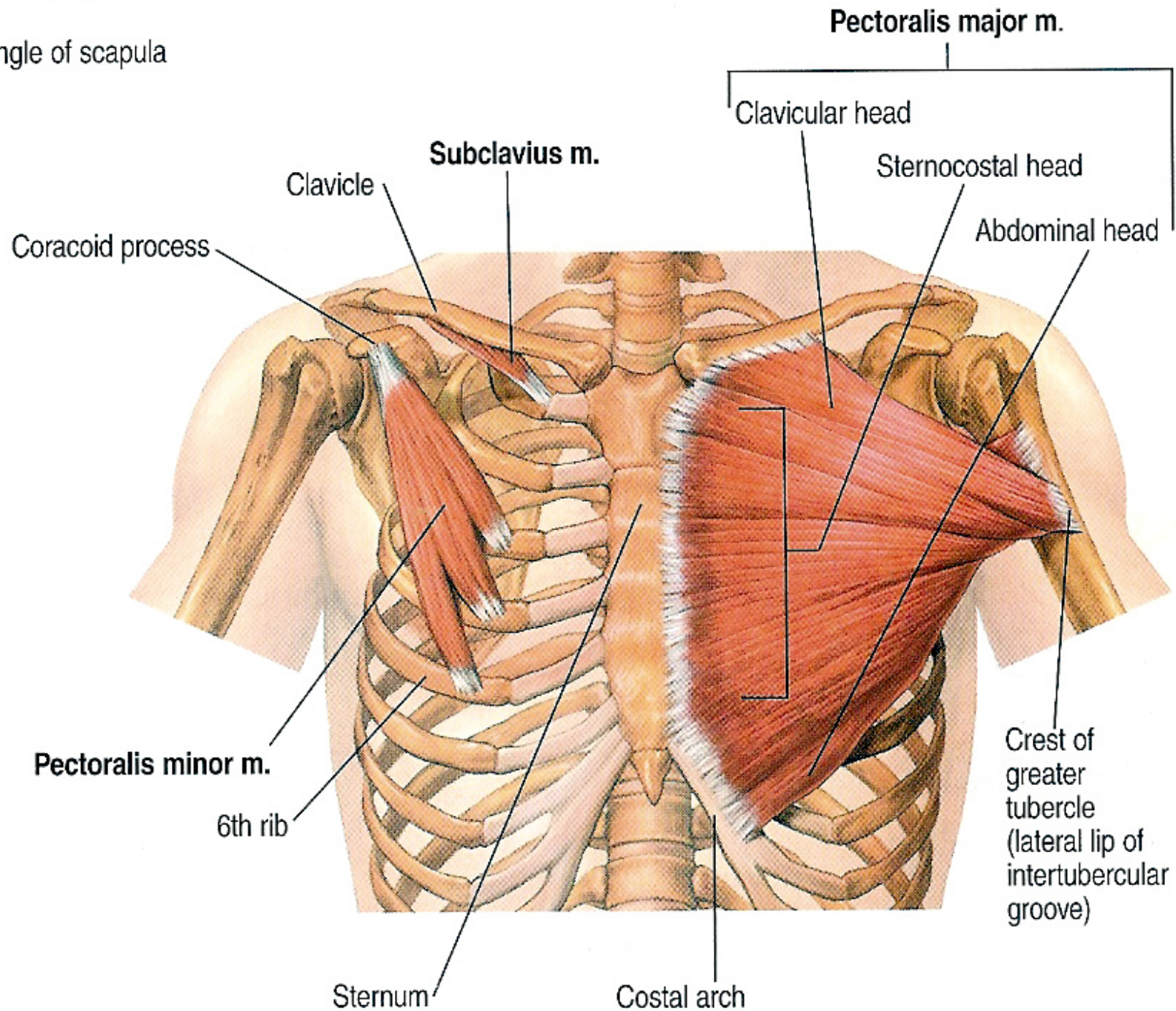
www.fisiokinesiterapia.biz

Muscles of the Pectoral Region



scapulae m.

angle of scapula



Pectoralis major

➤ Origin:

1. Medial half of the clavicle
2. The sternum.
3. Upper six costal cartilage.

➤ Insertion:

Lateral lip of bicipital groove of the humerus.

➤ Nerve Supply:

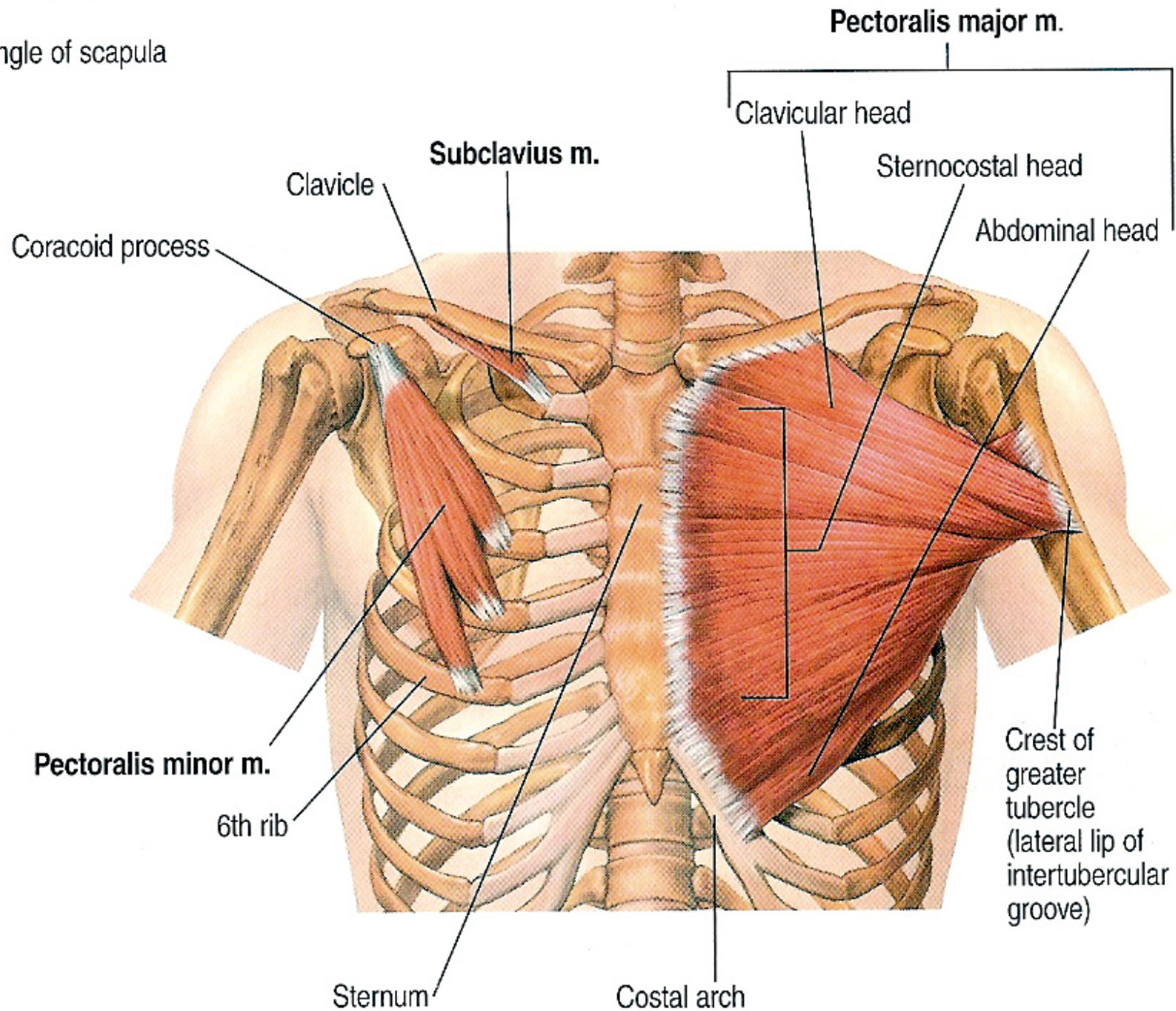
Medial and lateral pectoral nerves.

➤ Action:

- A. Adduction, flexion and medial rotation of the arm.
- B. Climbing.
- C. It is an accessory muscle of inspiration.

scapulae m.

angle of scapula



Pectoralis minor

➤ **Origin:**

3rd, 4th and 5th ribs near their cartilage.

➤ **Insertion:**

Anterior border of the coracoid process of the scapula.

➤ **Nerve Supply:**

Medial pectoral nerves.

➤ **Action:**

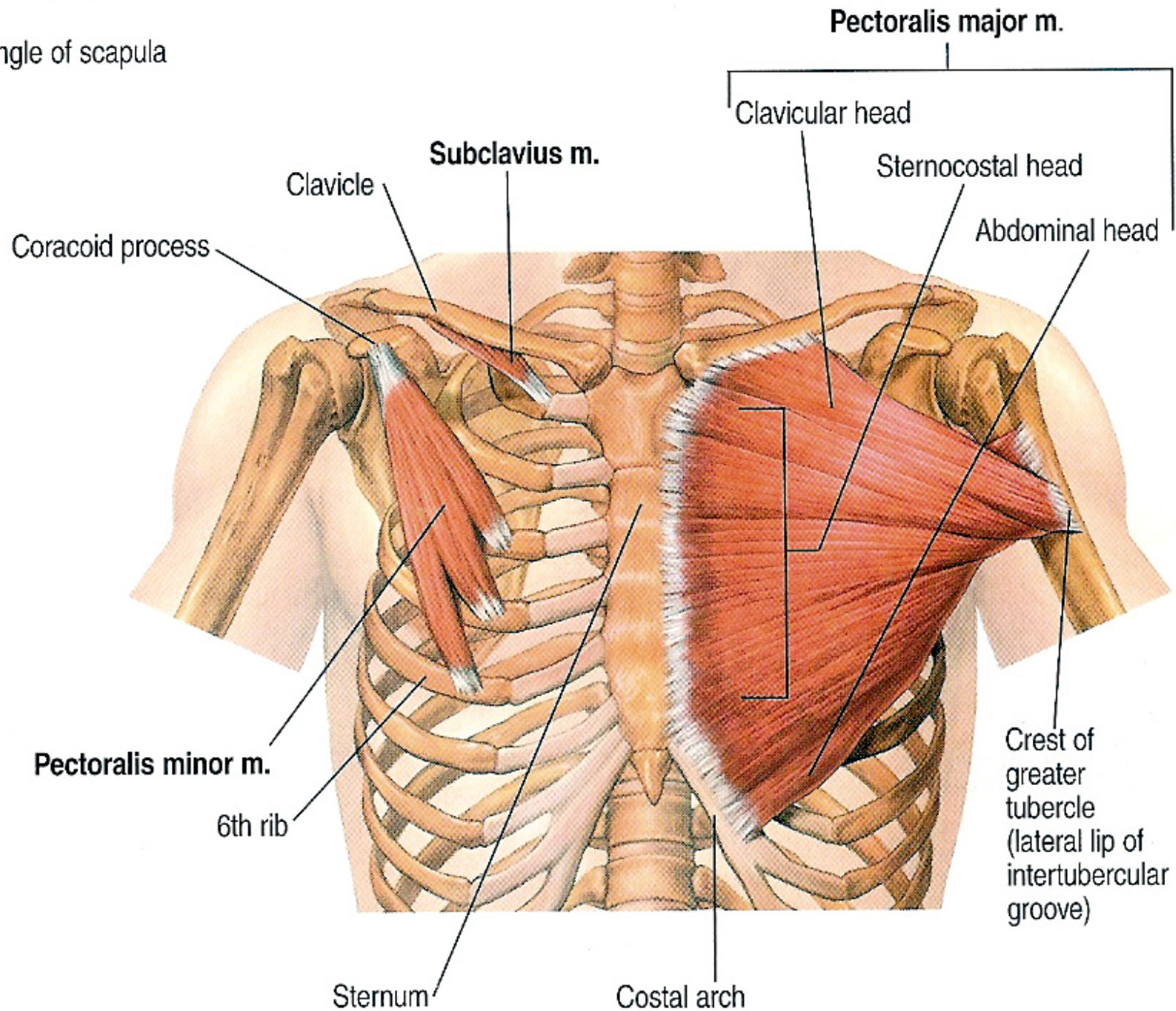
A. Depression and protraction of the scapula.

B. If the insertion is fixed, it elevates the 3rd, 4th and 5th ribs.

C. It rotates the scapula downward (with rhomboids).

scapulae m.

angle of scapula



Subclavius

➤ **Origin:**

The upper surface of the first costal cartilage.

➤ **Insertion:**

Middle third of the inferior surface of the clavicle.

➤ **Nerve Supply:**

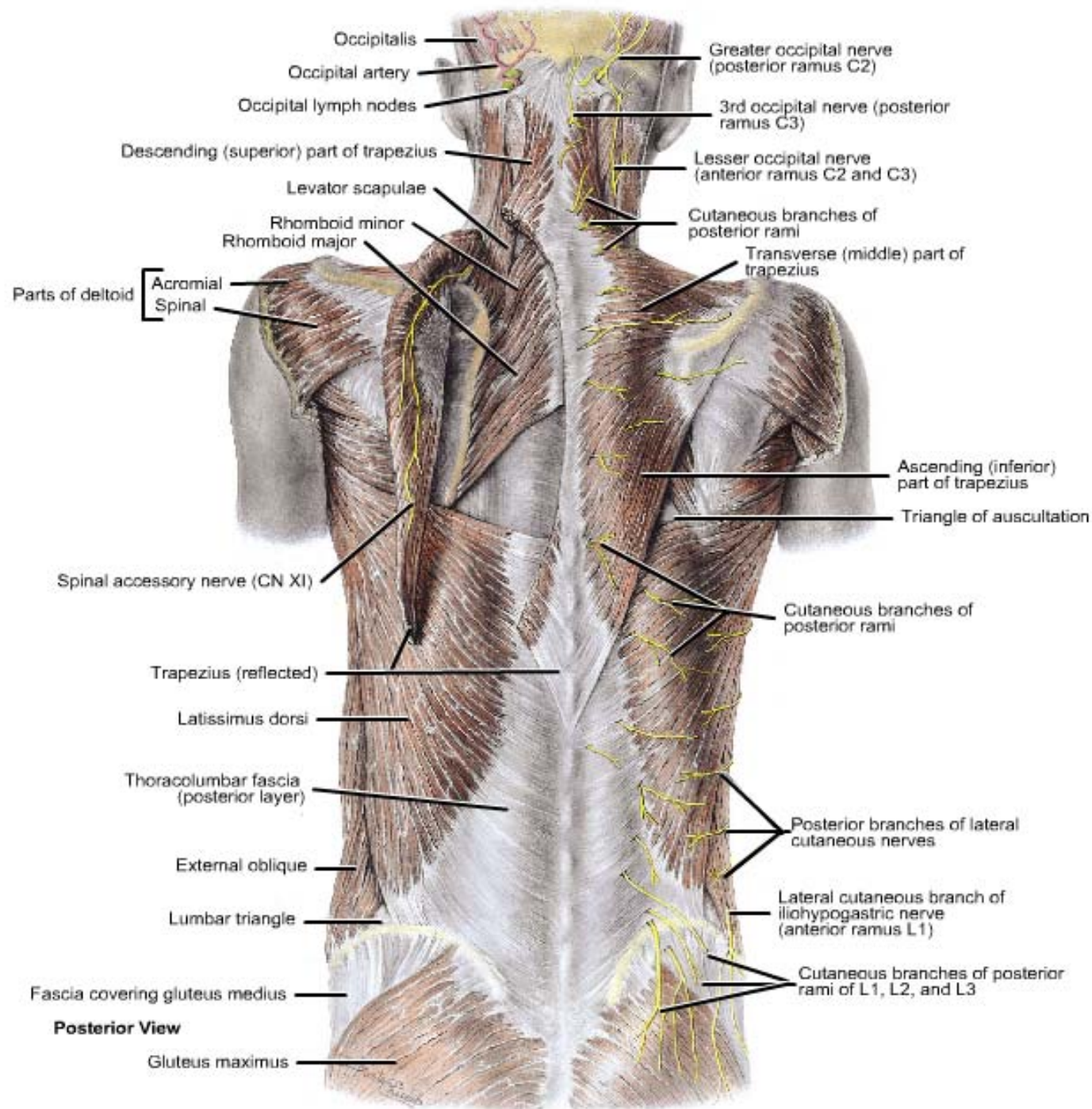
Nerve to subclavius (from upper trunk of brachial plexus).

➤ **Action:**

A. It depresses the clavicle.

B. It steadies the clavicle during movement of the shoulder girdle.

Muscles of the Back



Layers of Back Muscles

■ First Layer:

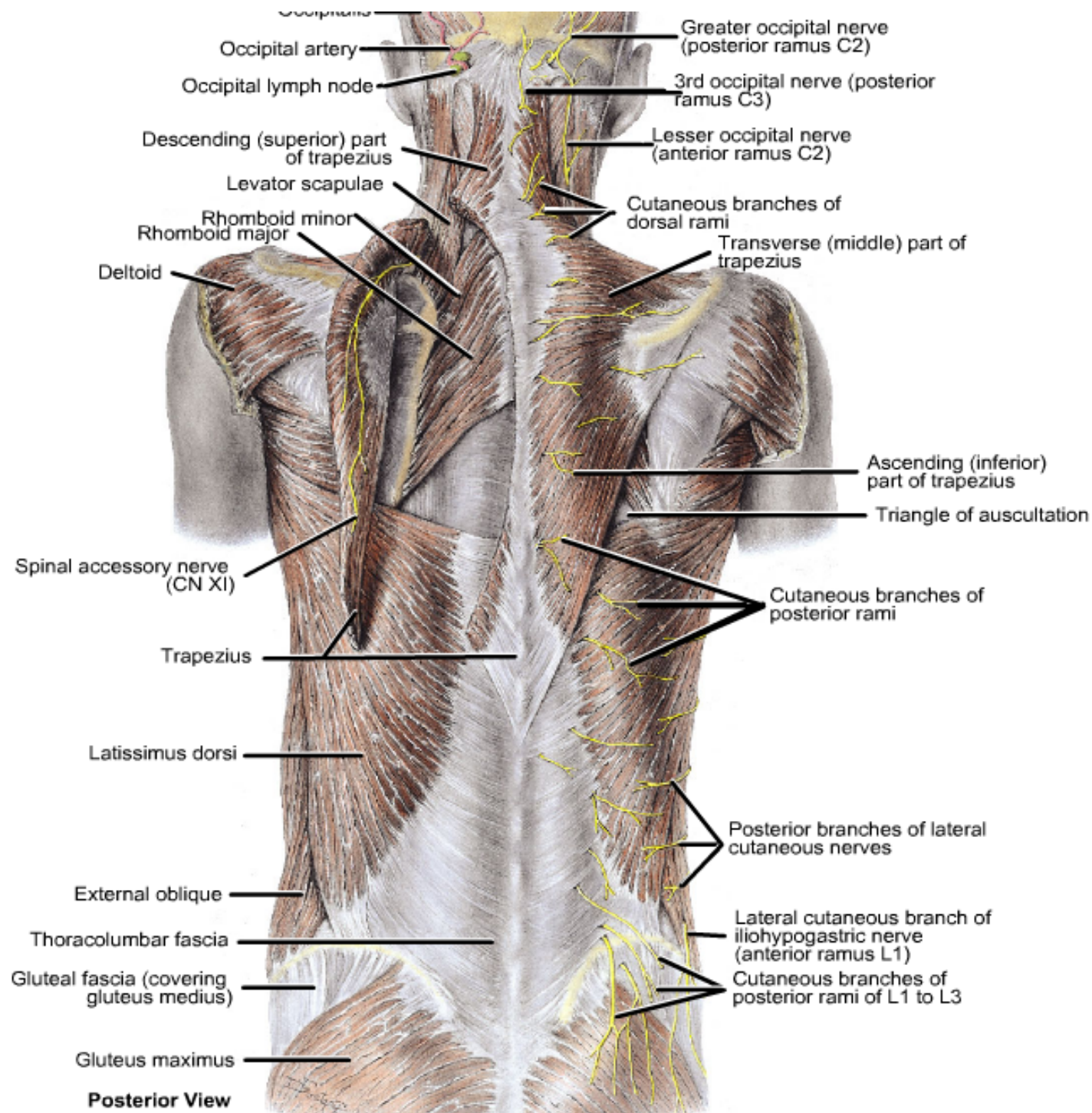
–Trapezius and latissimus dorsi.

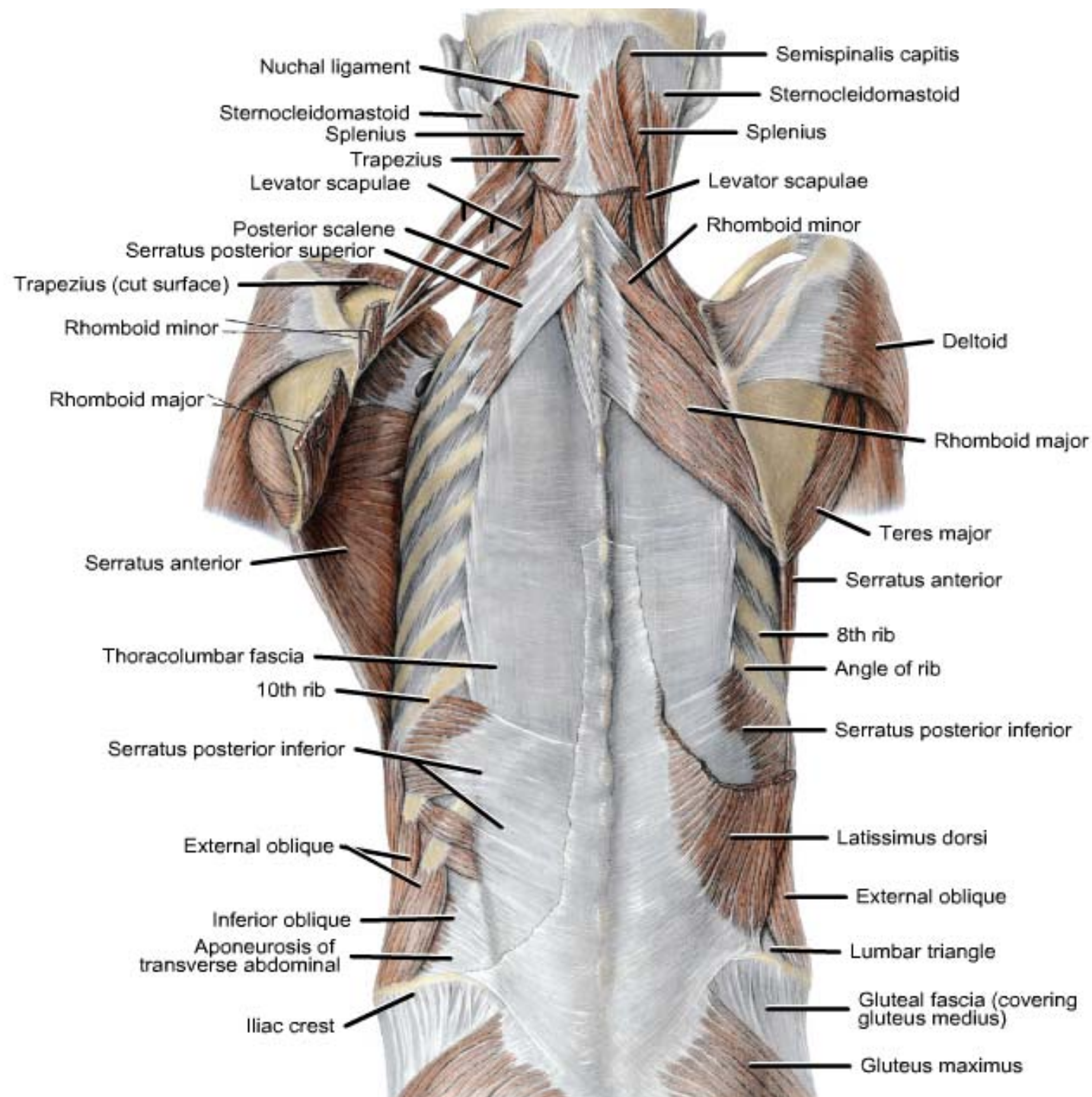
■ Second Layer:

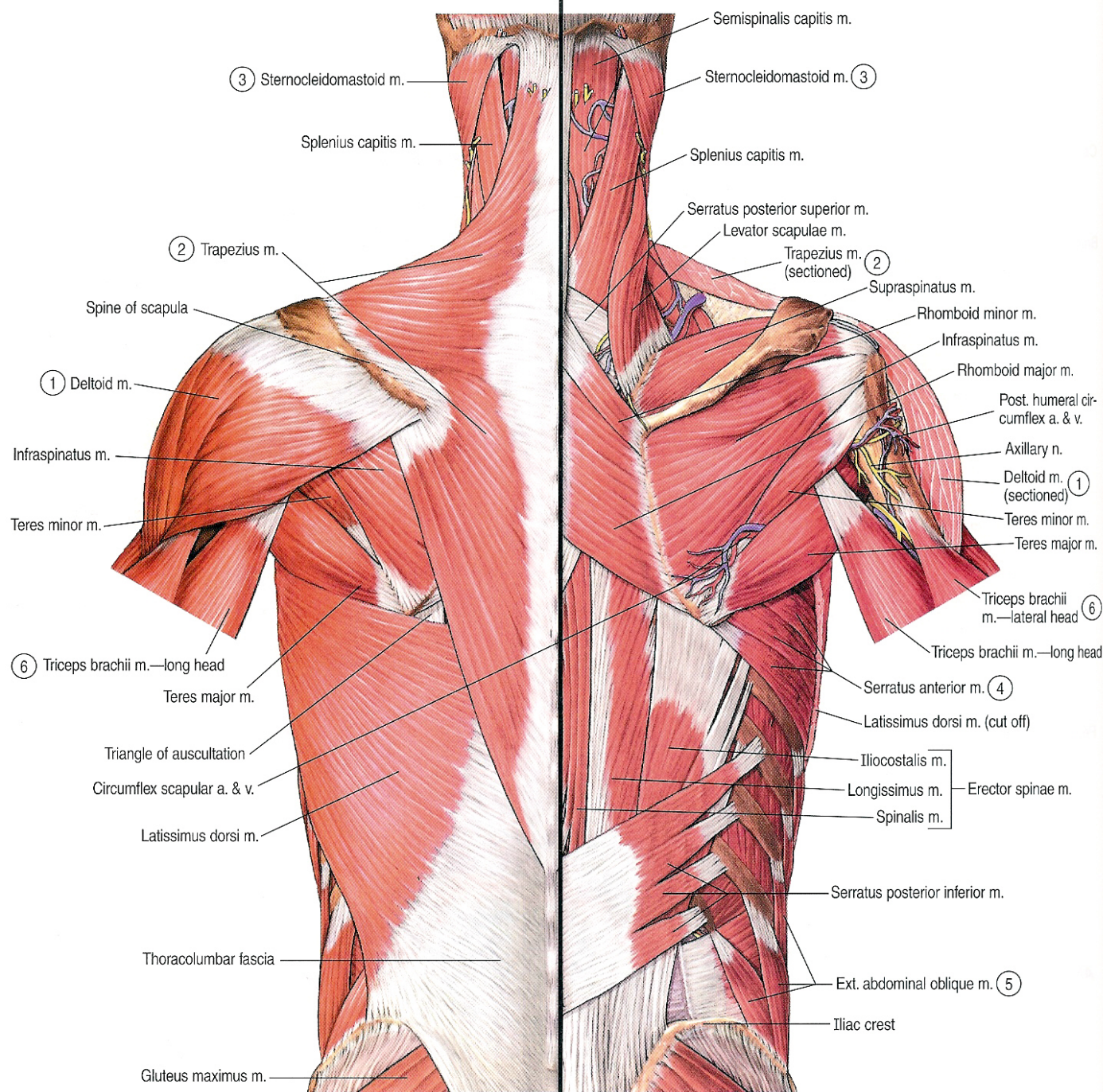
–Levator scapulae, rhomboid minor and rhomboid major.

■ Third Layer:

–Serratus posterior superior and serratus posterior inferior.







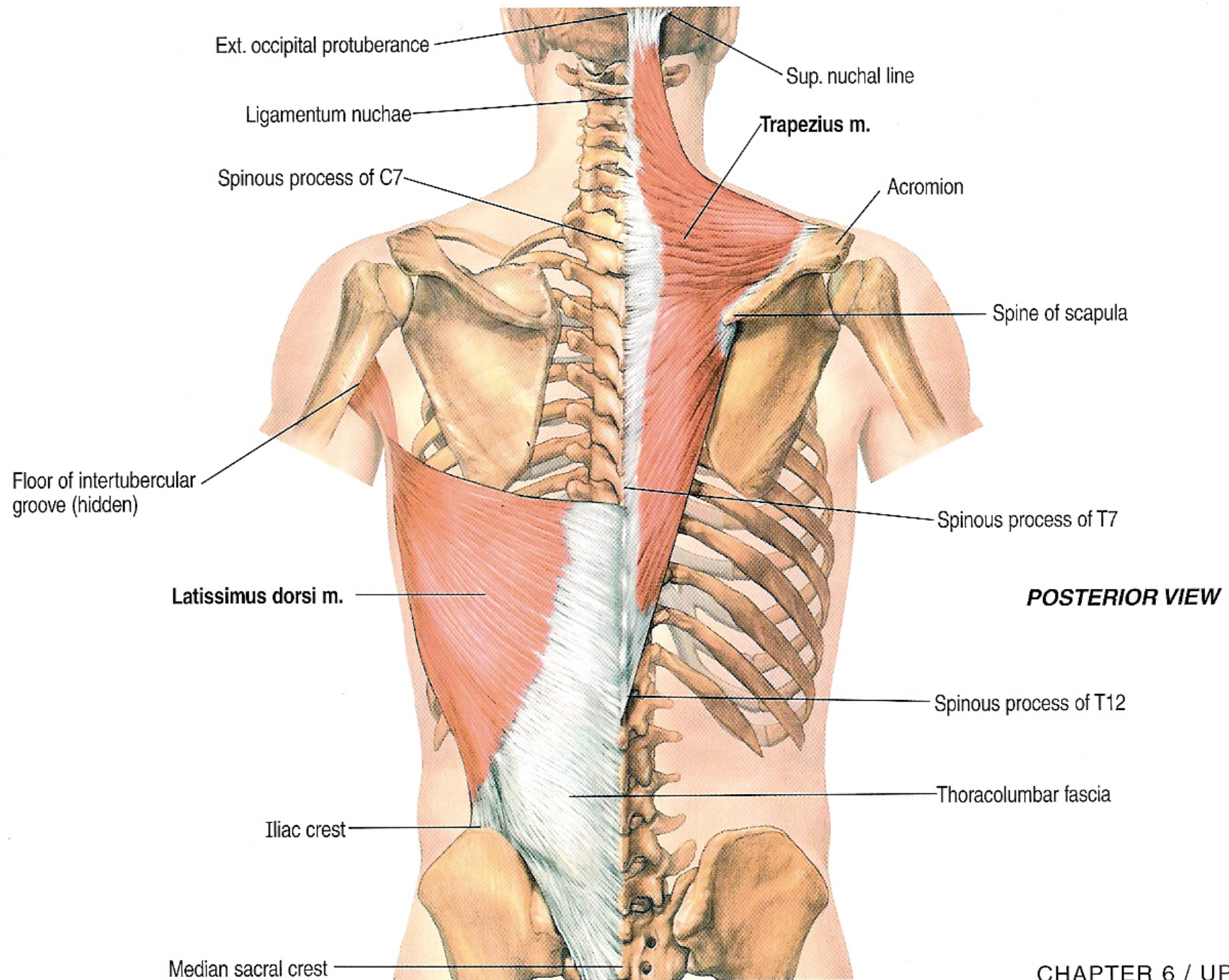
Trapezius

➤ Origin:

1. Medial third of superior nuchal line of occipital b.
2. External occipital protuberance.
3. Ligamentum nuchae.
4. Spine of the seventh cervical vertebra.
5. Spines and supraspinous ligaments of all thoracic vertebrae

➤ Insertion:

1. Upper fibers into the posterior aspect of the lateral third of the clavicle.
2. Middle fibers into the medial border of the acromion process of the scapula.
3. Lower fibers into the spine of the scapula.



Trapezius

➤ Nerve Supply:

- **Motor fibers** from the spinal part of accessory nerve.
- **Proprioceptive sensory fibers** from the third and fourth cervical nerves.

➤ Action:

- A. **Upper fibers:** elevates the scapula.
- B. **Middle fibers:** retracts the scapula.
- C. **Lower fibers:** depresses the scapula.
- D. **With serratus anterior:** rotates the scapula upward (for abduction of the arm more than 90°).
- E. **When scapula is fixed:** both side muscles extend the head.

Latissimus dorsi

➤ Origin:

1. Spines of the lower 6 thoracic vertebrae.
2. Lower 3 or 4 ribs.
3. Lumbar fascia and posterior part of iliac crest.
4. Inferior angle of the scapula.

➤ Insertion:

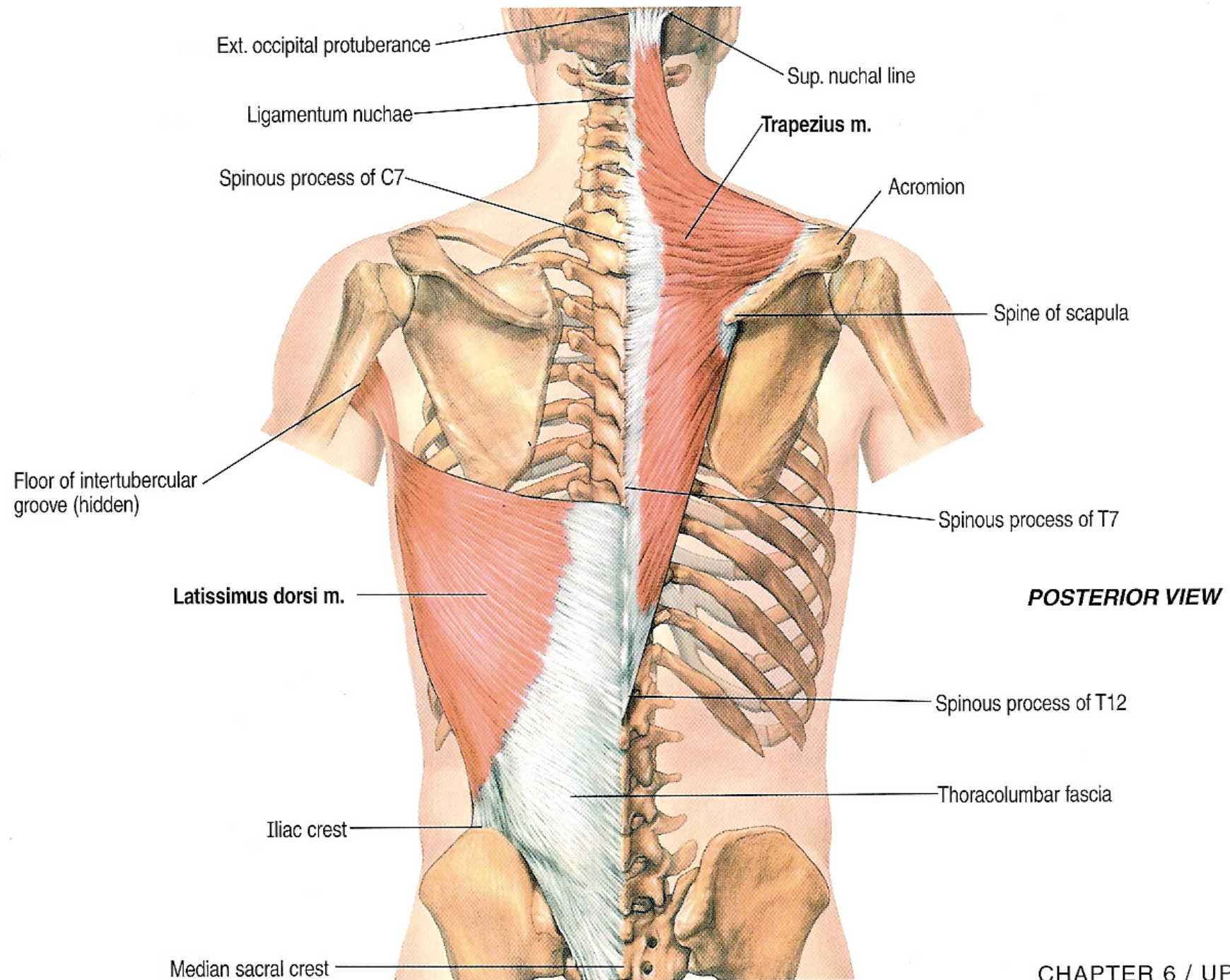
Floor of the bicipital groove of the humerus.

➤ Nerve Supply:

Thoracodorsal nerve.

➤ Action:

- A. Adduction, extension and medial rotation of the arm.
- B. Climbing.



Levator scapulae

➤ Origin:

The transverse processes of the upper four cervical vertebrae.

➤ Insertion:

Dorsal lip of the medial border of the scapula above the level of its spine.

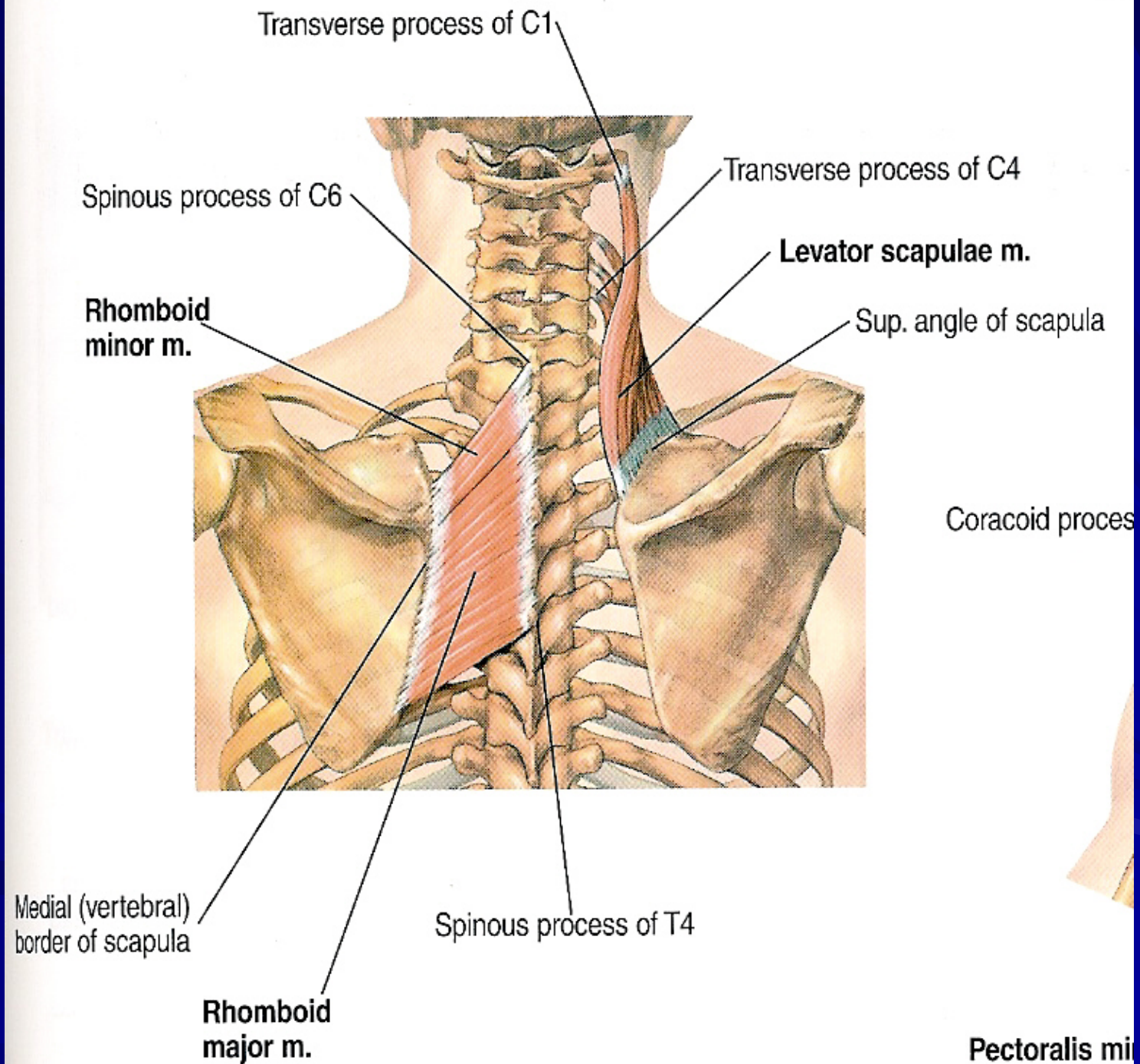
➤ Nerve Supply:

From the ventral rami of the 3rd and 4th cervical nerves and form dorsal scapular nerve (C5).

➤ Action:

A. Elevation of the scapula.

B. If the scapula is fixed, it bends the head to the same side.



Rhomboid minor

➤ Origin:

1. Lower part of ligamentum nuchae.
2. Spine of seventh cervical vertebra.
3. Spine of first thoracic vertebra.

➤ Insertion:

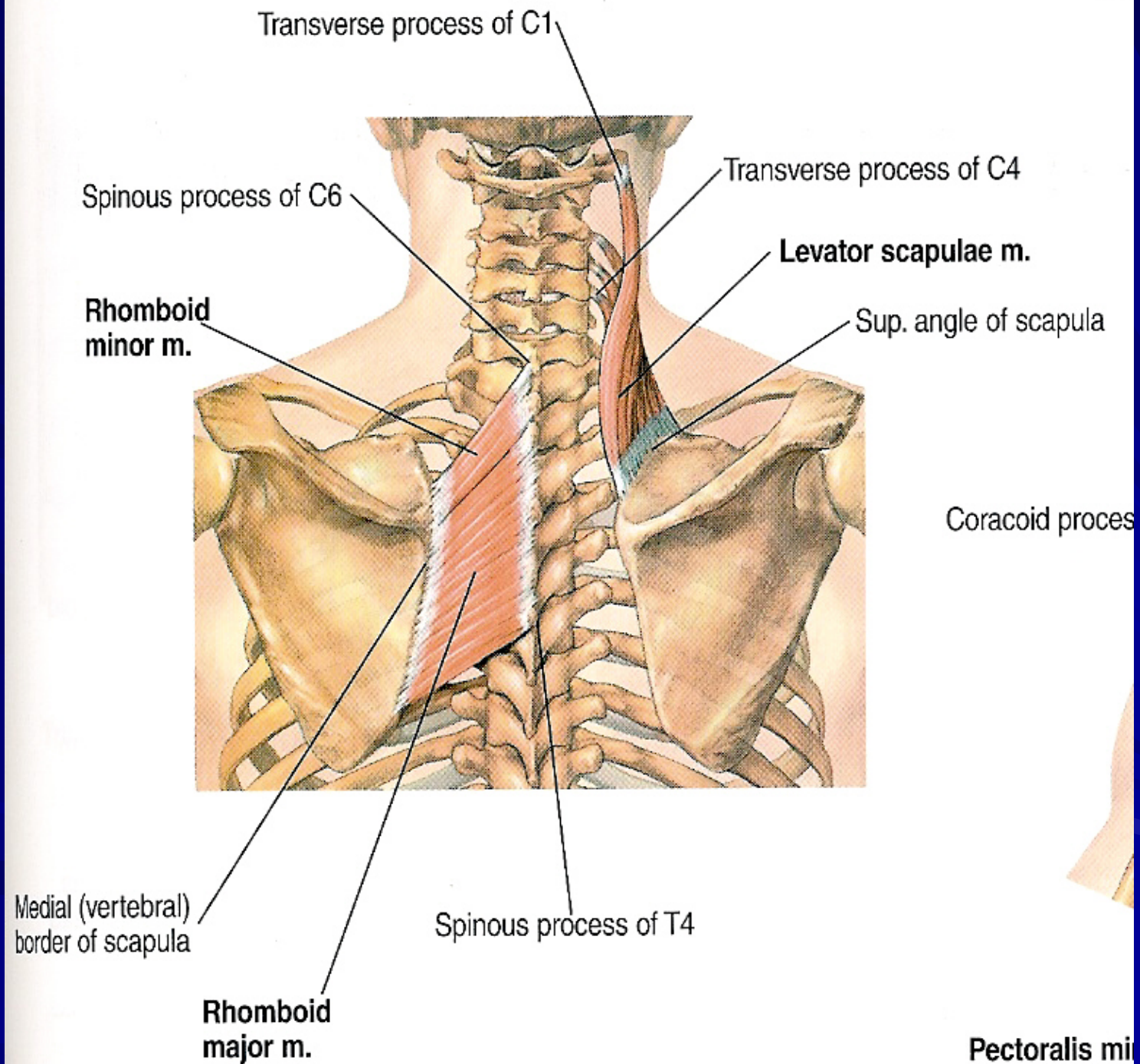
Dorsal lip of the medial border of the scapula opposite the root of its spine.

➤ Nerve Supply:

Dorsal scapular nerve (C5).

➤ Action:

- A. Elevation of the scapula.
- B. With rhomboid major and pectoralis minor, it rotates the scapula downward.



Rhomboid major

➤ Origin:

1. From 2nd to 5th spines of the thoracic vertebrae.
2. And their supraspinous ligaments.

➤ Insertion:

Dorsal lip of the medial border of the scapula below the level of its spine.

➤ Nerve Supply:

Dorsal scapular nerve (C5).

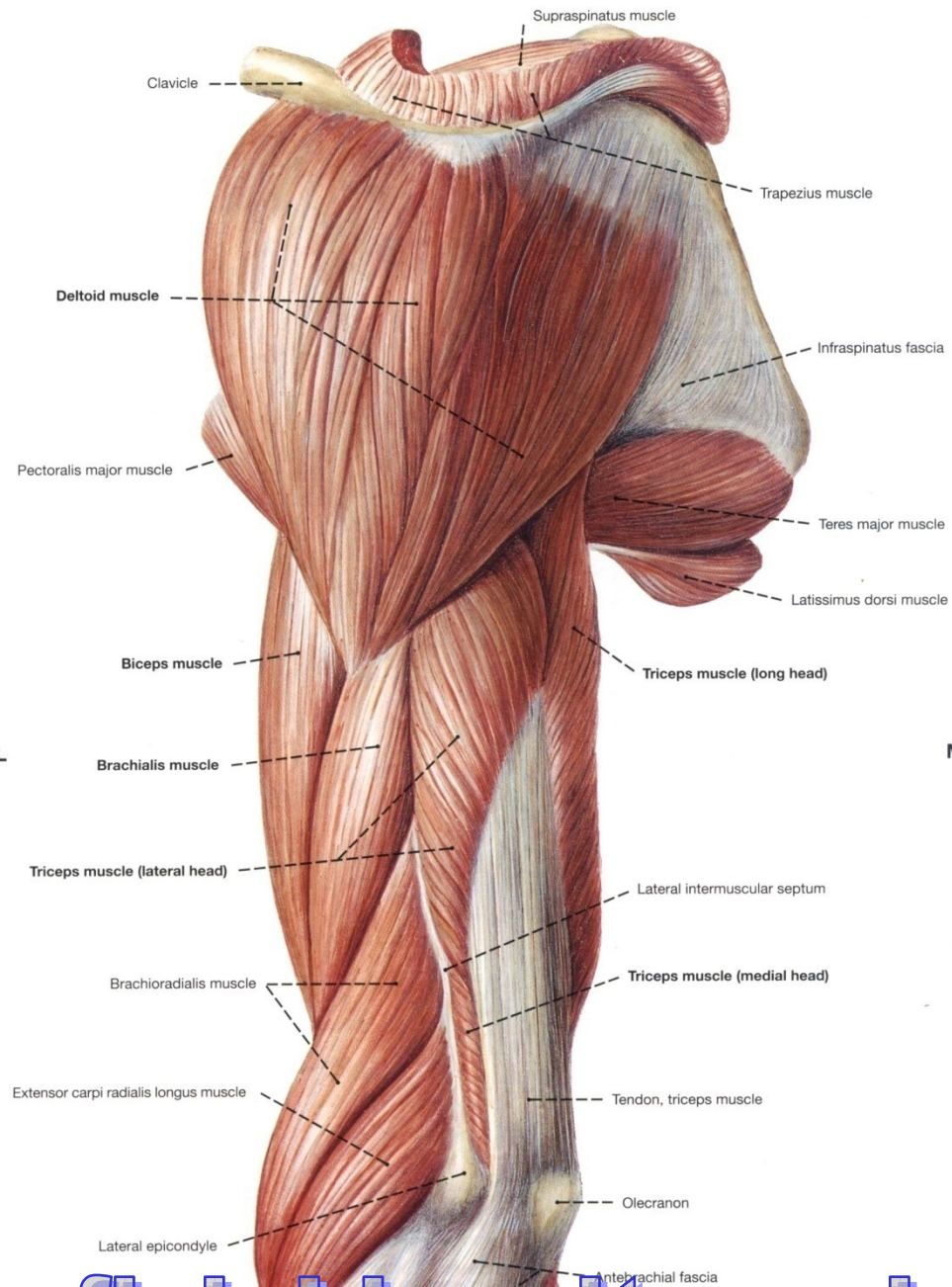
➤ Action:

- A. Elevation of the scapula.
- B. With rhomboid major and pectoralis minor, it rotates the scapula downward.

Muscles of the scapular region

Muscles

- Deltoid.
- Supraspinatus.
- Infraspinatus
- Teres Minor.
- Teres Major.
- Subscapularis.
- Serratus Anterior.



Deltoid

➤ Origin:

1. ***Anterior fibers*** from the lateral third of the anterior border of the clavicle.
2. ***Middle fibers*** from the lateral border of the acromion process of the scapula.
3. ***Posterior fibers*** from the lower border of the spine of the scapula.

➤ Insertion:

Into the deltoid tuberosity, on the middle of the lateral surface of the shaft of the humerus.

lateral head

Spine of scapula

Acromion

Clavicle

Deltoid m.

Deltoid tuberosity
of humerus

LATERAL VIEW

e

Deltoid

➤ Nerve Supply:

From the axillary nerve (C5,6).

➤ Action:

A. Anterior fibers: flexes and medially rotates the arm.

B. Posterior fibers: extends and laterally rotates the arm.

C. Middle fibers: abducts the arm till the level of the head (from 15° to 90°).

Supraspinatus

➤ **Origin:**

From the supraspinous fossa of the scapula.

➤ **Insertion:**

Into the **upper facet** (impression) of the greater tuberosity of the humerus and upper part of the capsule of the shoulder joint.

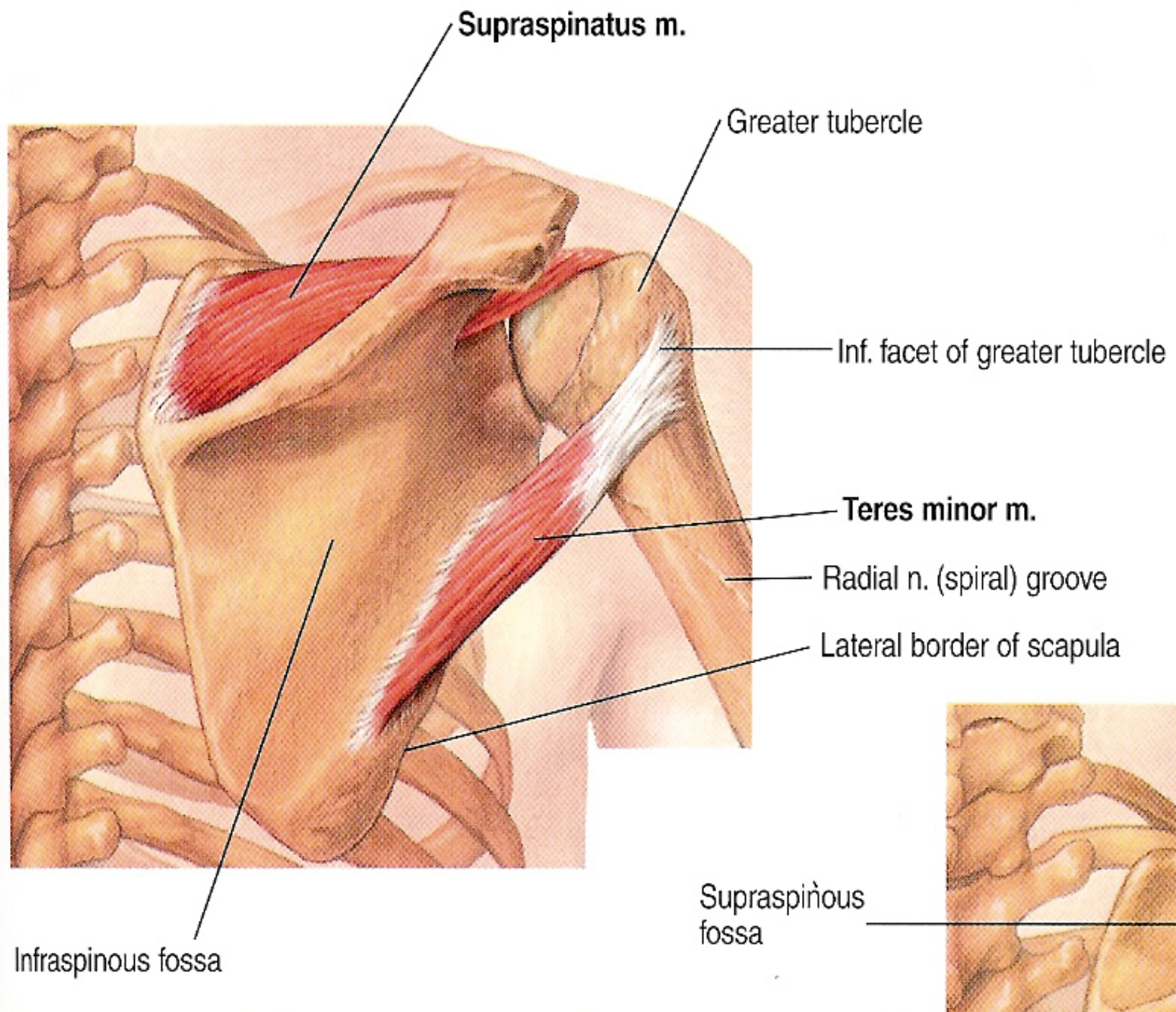
➤ **Nerve Supply:**

From the suprascapular nerve (C5,6).

➤ **Action:**

A. Starts abduction of the arm (from 0° to 15°).

B. Stabilizes and supports the shoulder joint (rotator cuff muscle).



Infraspinatus

➤ **Origin:**

From the infraspinous fossa of the scapula.

➤ **Insertion:**

Into the **middle facet** (impression) of the greater tuberosity of the humerus and posterior part of the capsule of the shoulder joint.

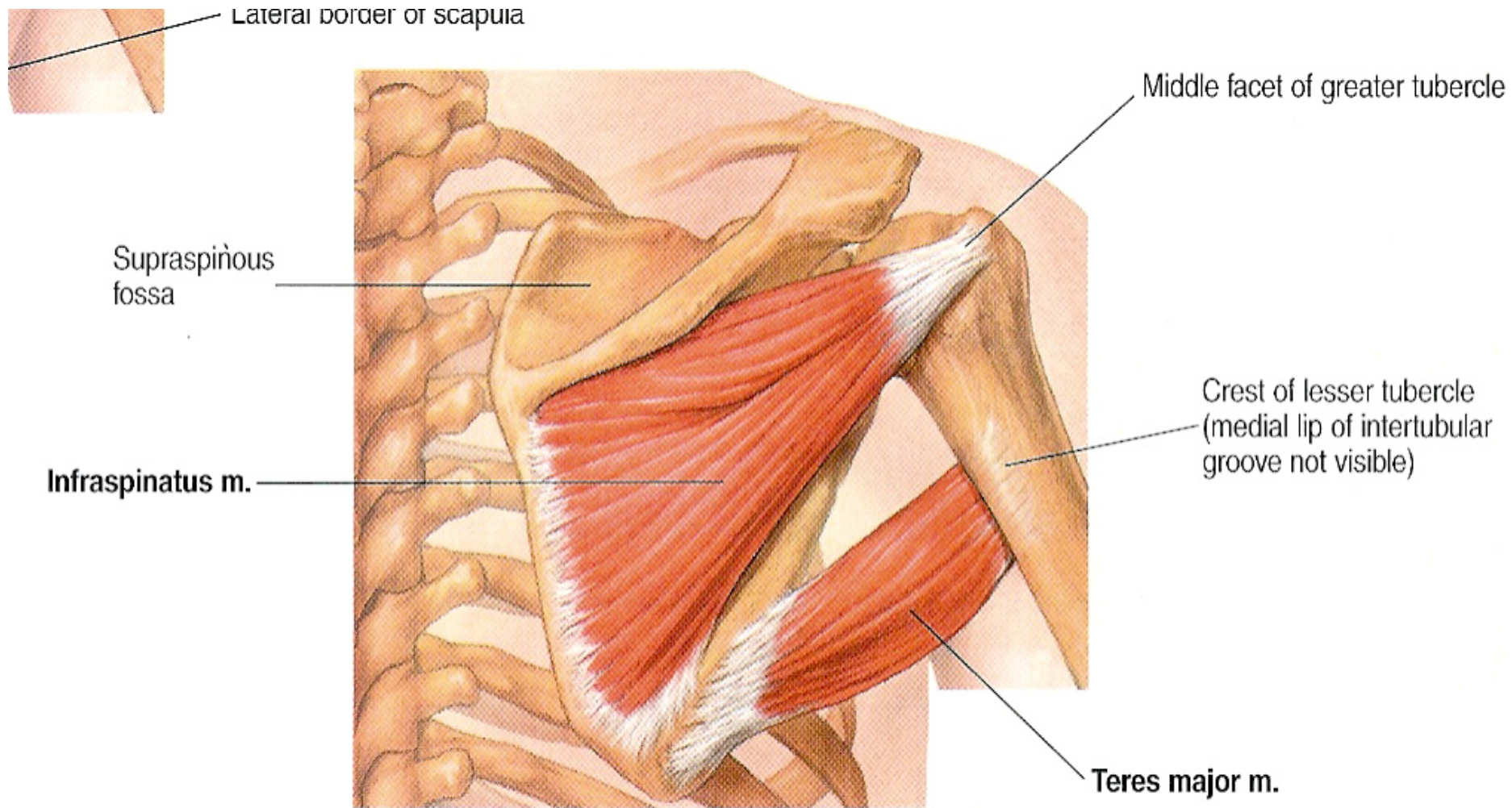
➤ **Nerve Supply:**

From the suprascapular nerve (C5,6).

➤ **Action:**

A. Laterally rotates the arm.

B. Stabilizes and supports the shoulder joint (rotator cuff muscle).



Teres minor

➤ Origin:

From the upper 2/3 of the dorsal lip of the lateral border of the scapula.

➤ Insertion:

Into the **lower facet** (impression) of the greater tuberosity of the humerus and posterior part of the capsule of the shoulder joint.

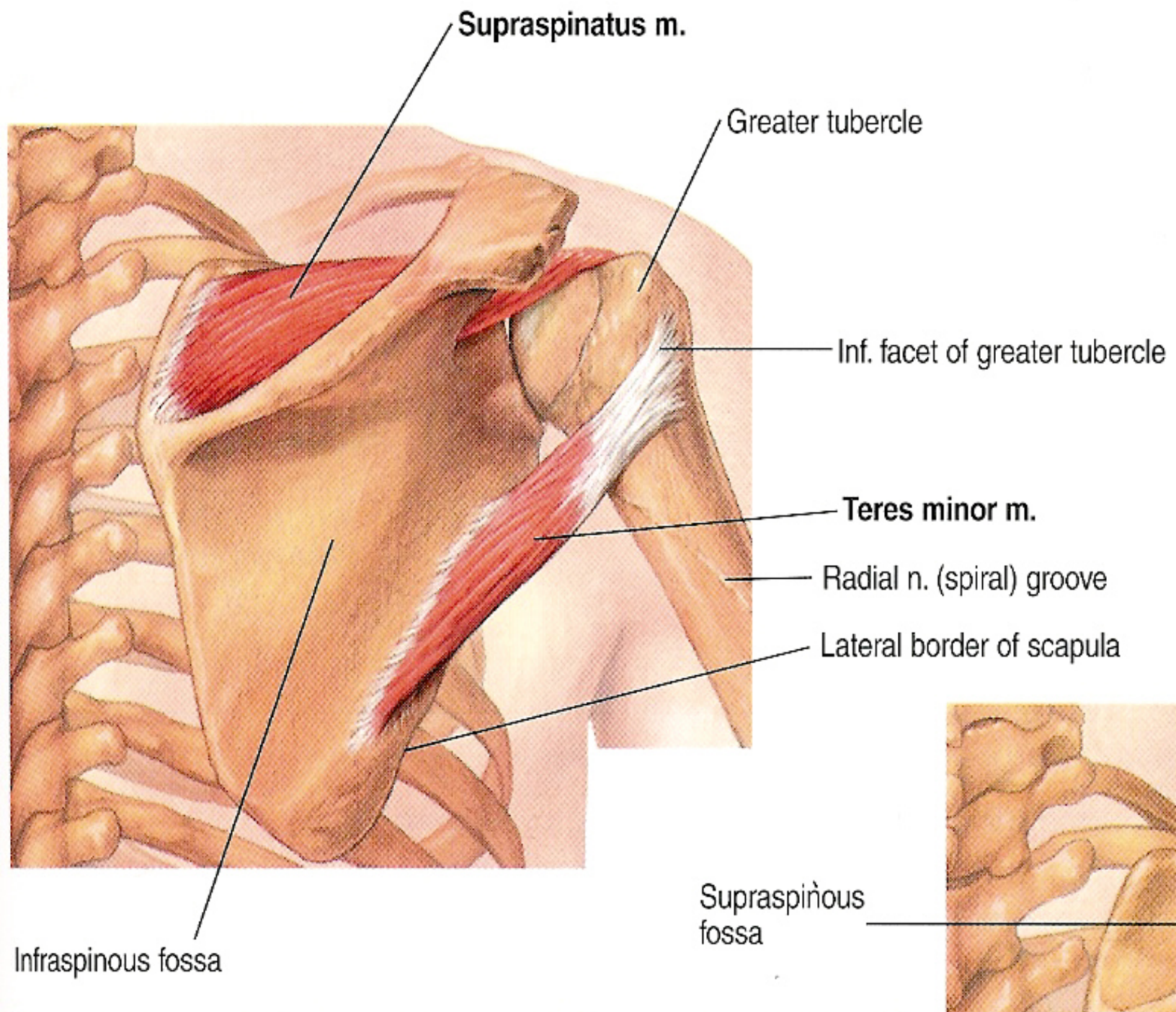
➤ Nerve Supply:

From the axillary nerve (C5,6).

➤ Action:

A. Laterally rotates the arm.

B. Stabilizes and supports the shoulder joint (rotator cuff muscle).



Teres major

➤ Origin:

The lower third of the posterior surface of the lateral border of the scapula.

➤ Insertion:

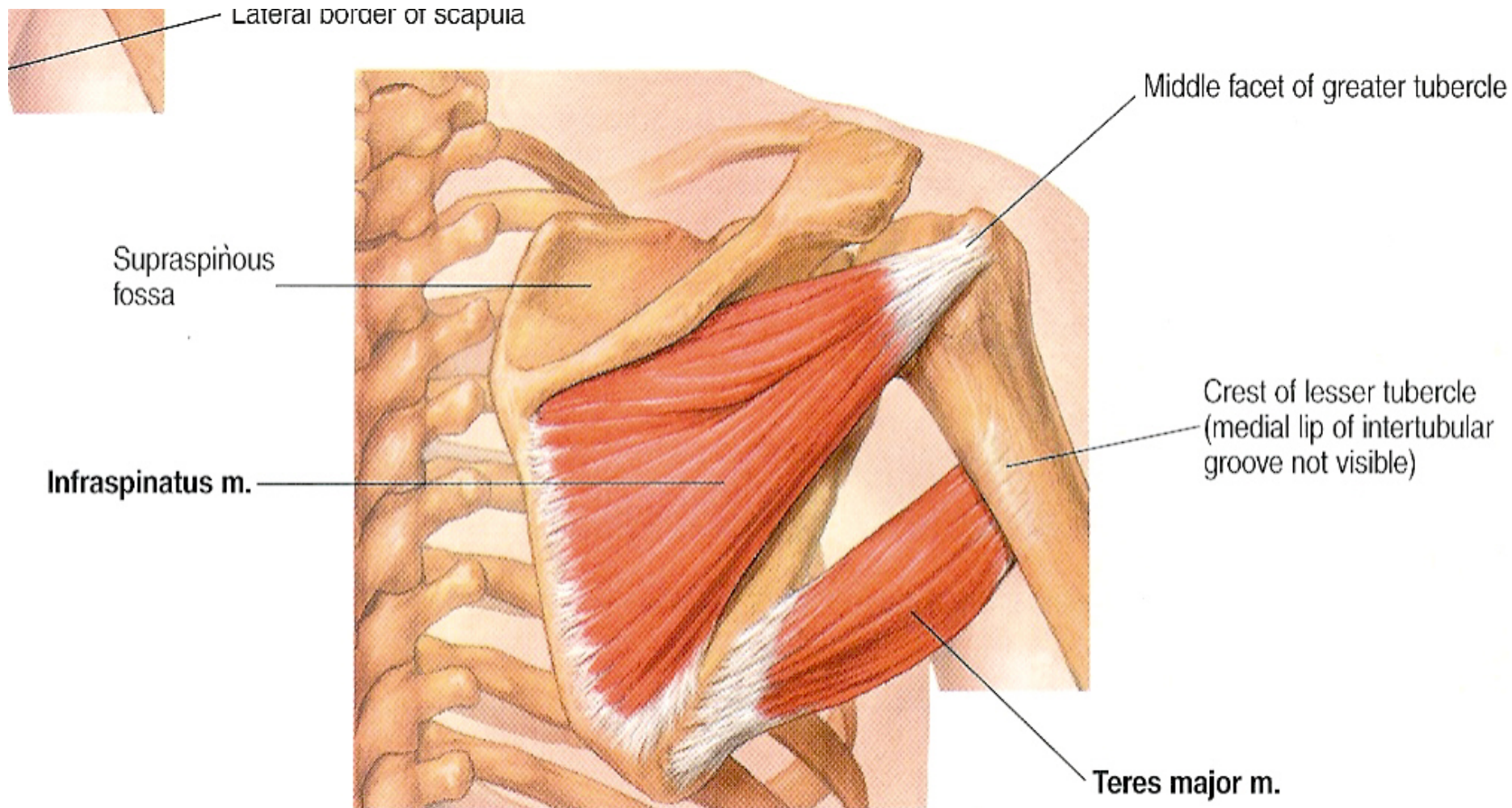
The medial lip of the bicipital groove of the humerus.

➤ Nerve Supply:

Lower subscapular nerve.

➤ Action:

It adducts, extends and medial rotates the arm.



Subscapularis

➤ Origin:

The medial 2/3 of the subscapular fossa of the anterior surface of the scapula and from the inner surface of the subscapular fascia.

➤ Insertion:

The lesser tuberosity of the humerus.

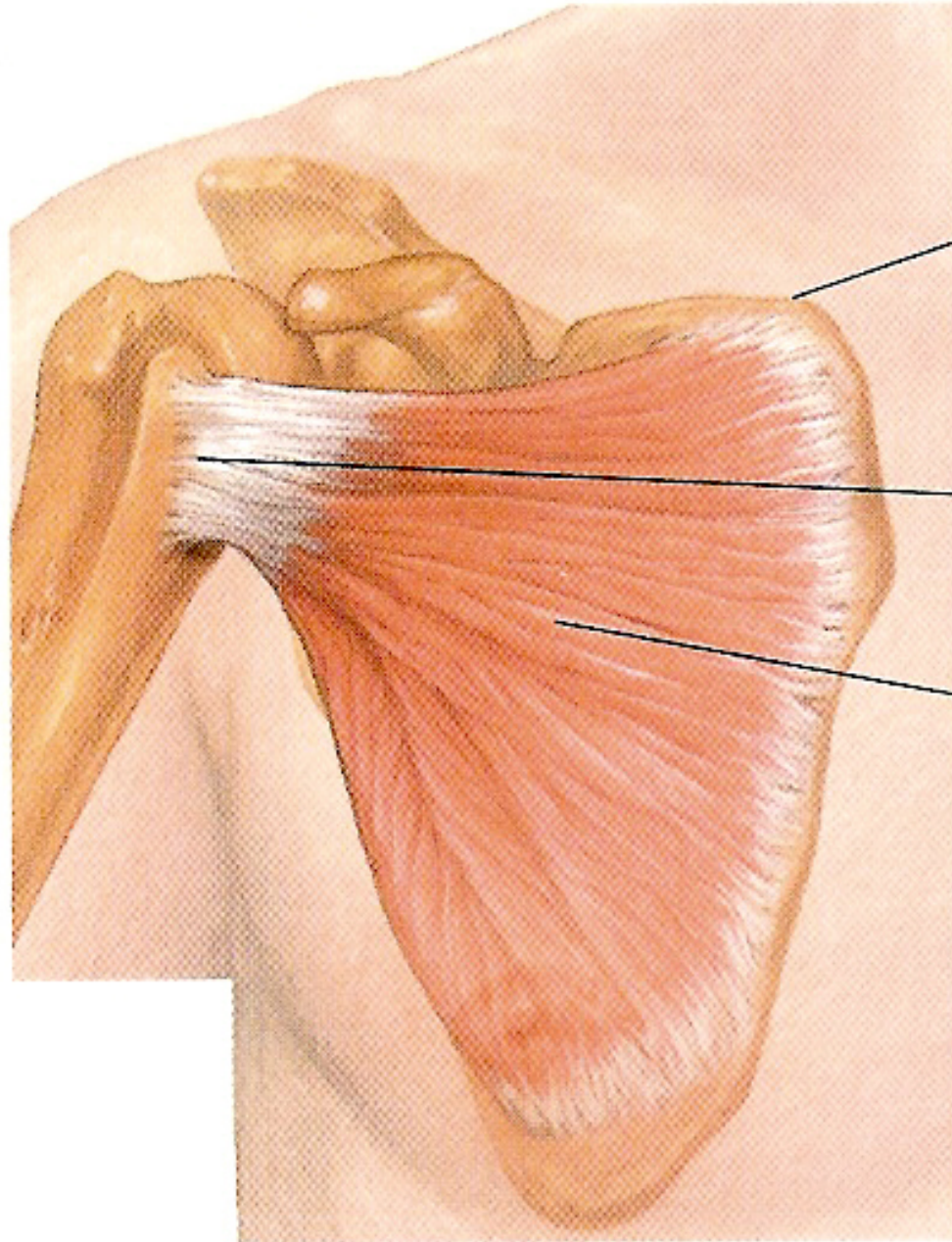
➤ Nerve Supply:

Upper and lower subscapular nerves.

➤ Action:

A. It adducts and medial rotates the arm.

B. It stabilizes the shoulder joints.



Sup. angle of scapula

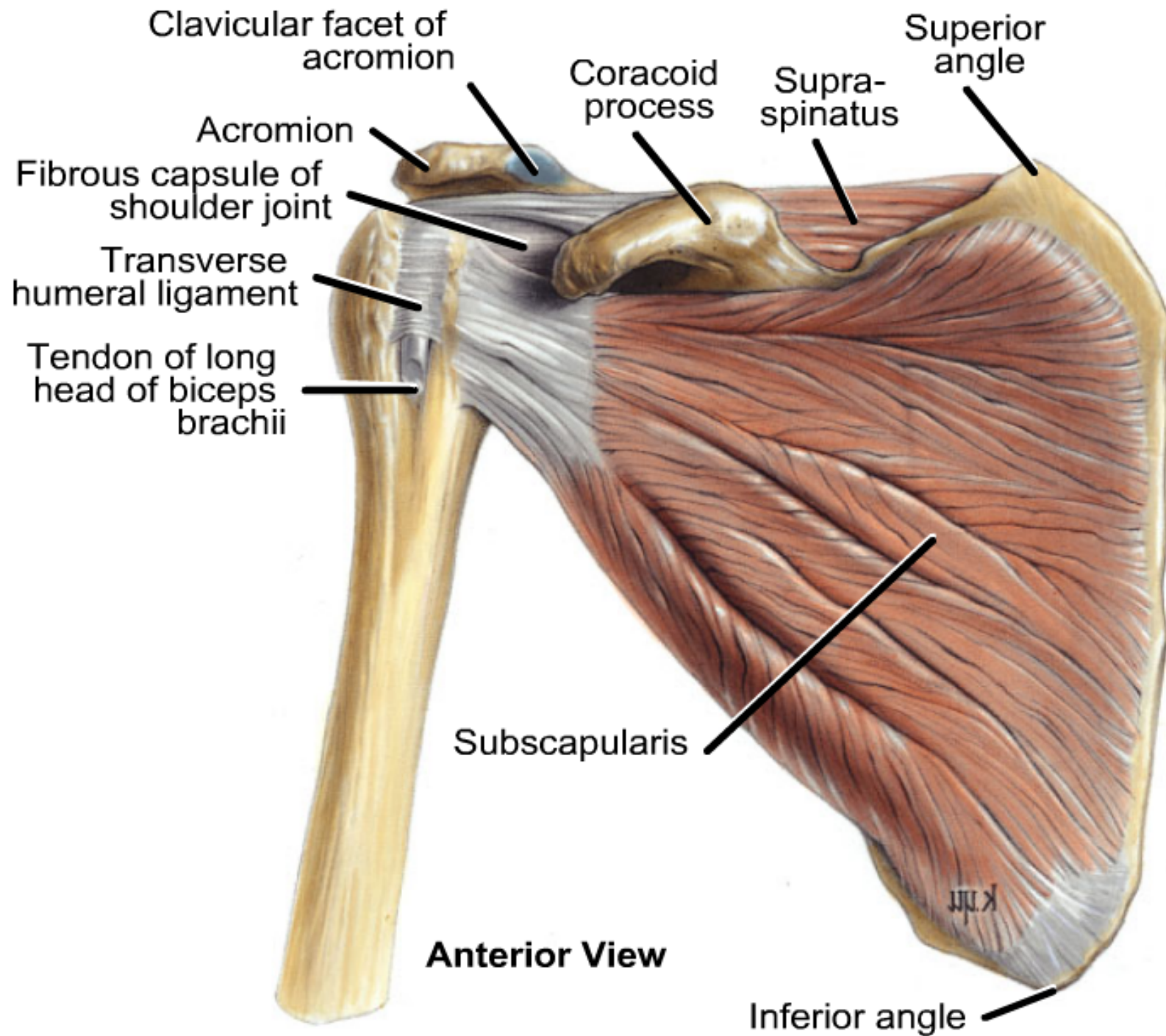
C1

Lesser tubercle of humerus

Subscapularis m.

Crest of

ANTERIOR



Serratus anterior

➤ Origin:

By 8 digitations from the outer surface of the upper 8 ribs.

➤ Insertion:

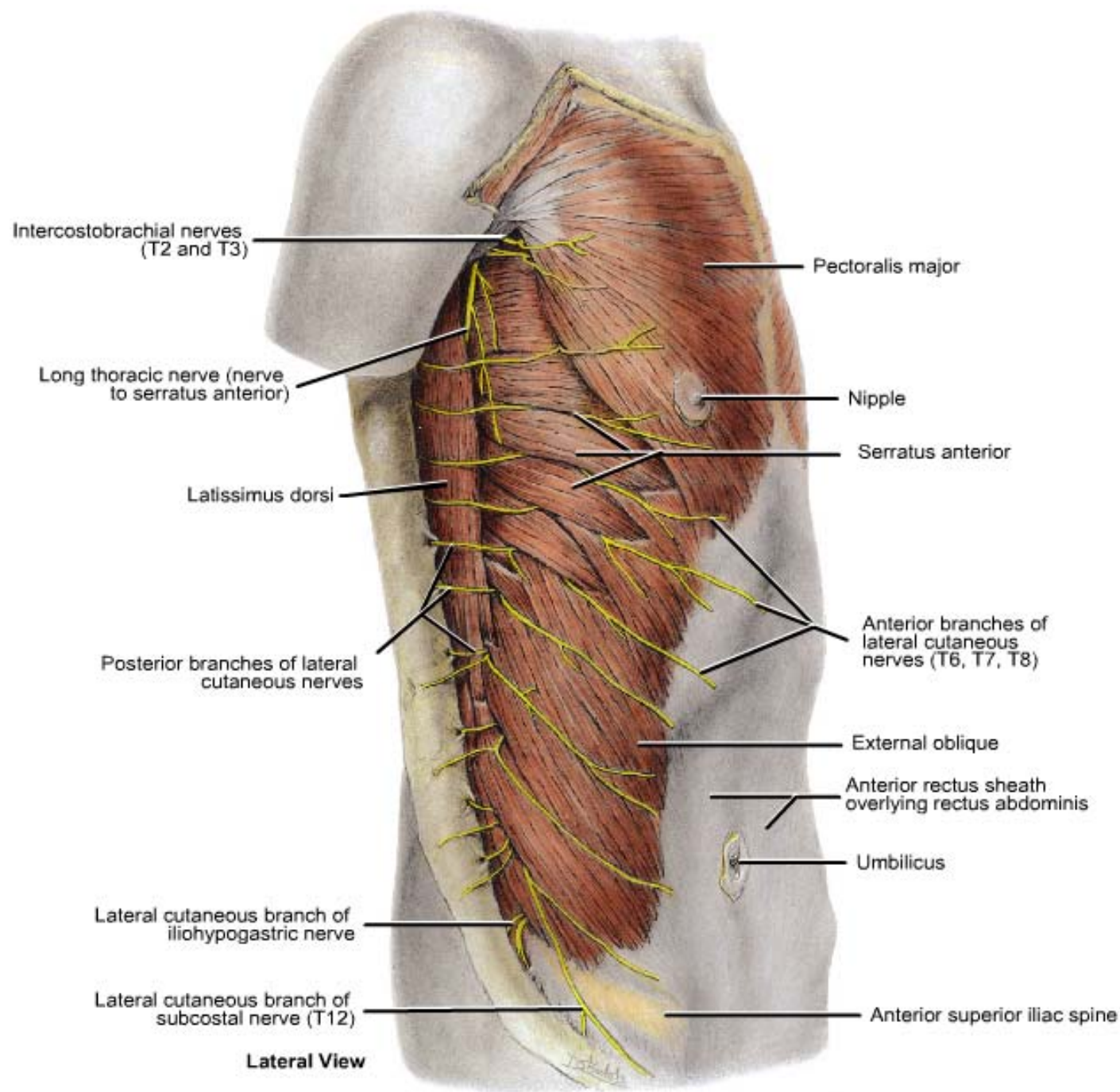
To the anterior surface of the medial border of the scapula, mainly near the inferior angle.

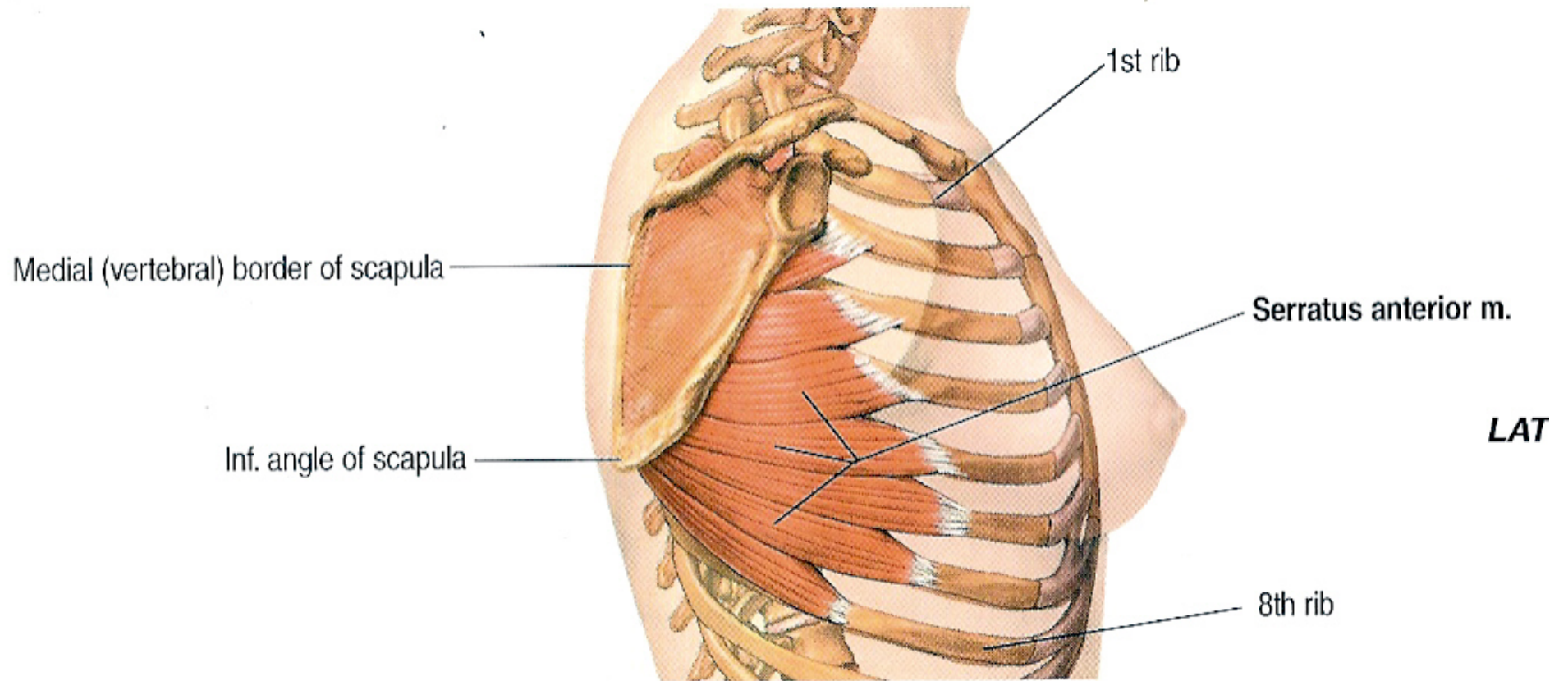
➤ Nerve Supply:

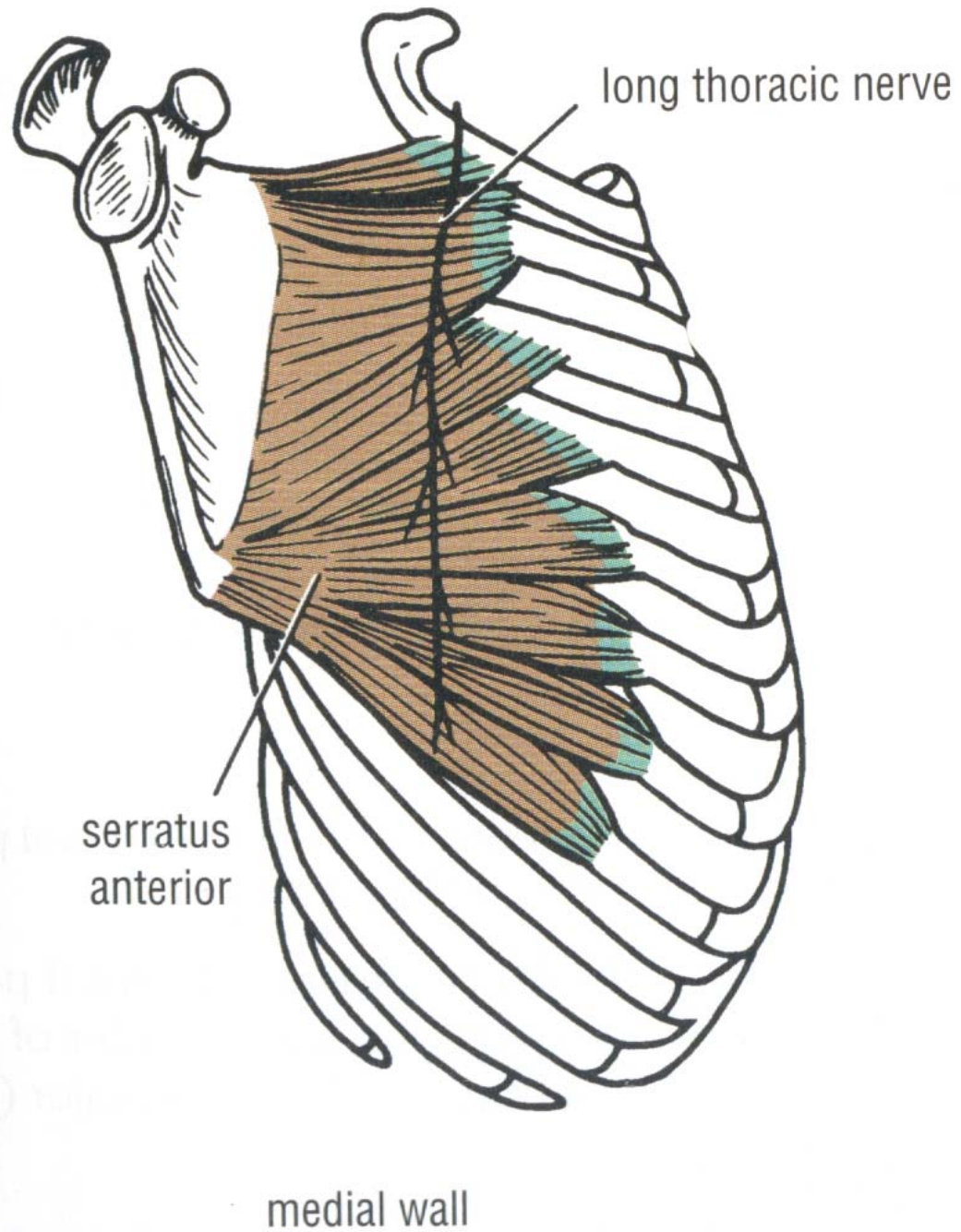
Long thoracic nerve (from root of brach. plex.).

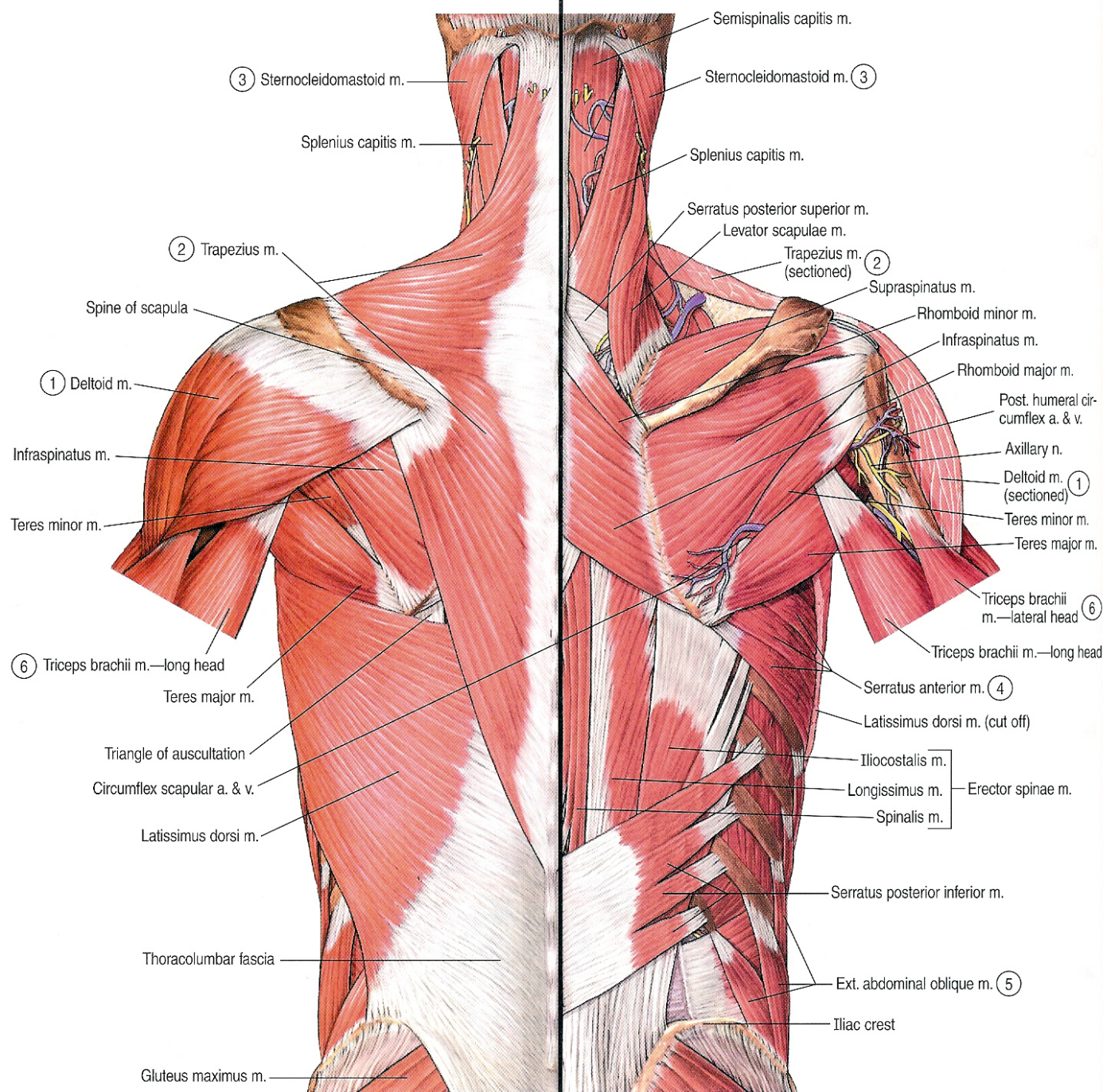
➤ Action:

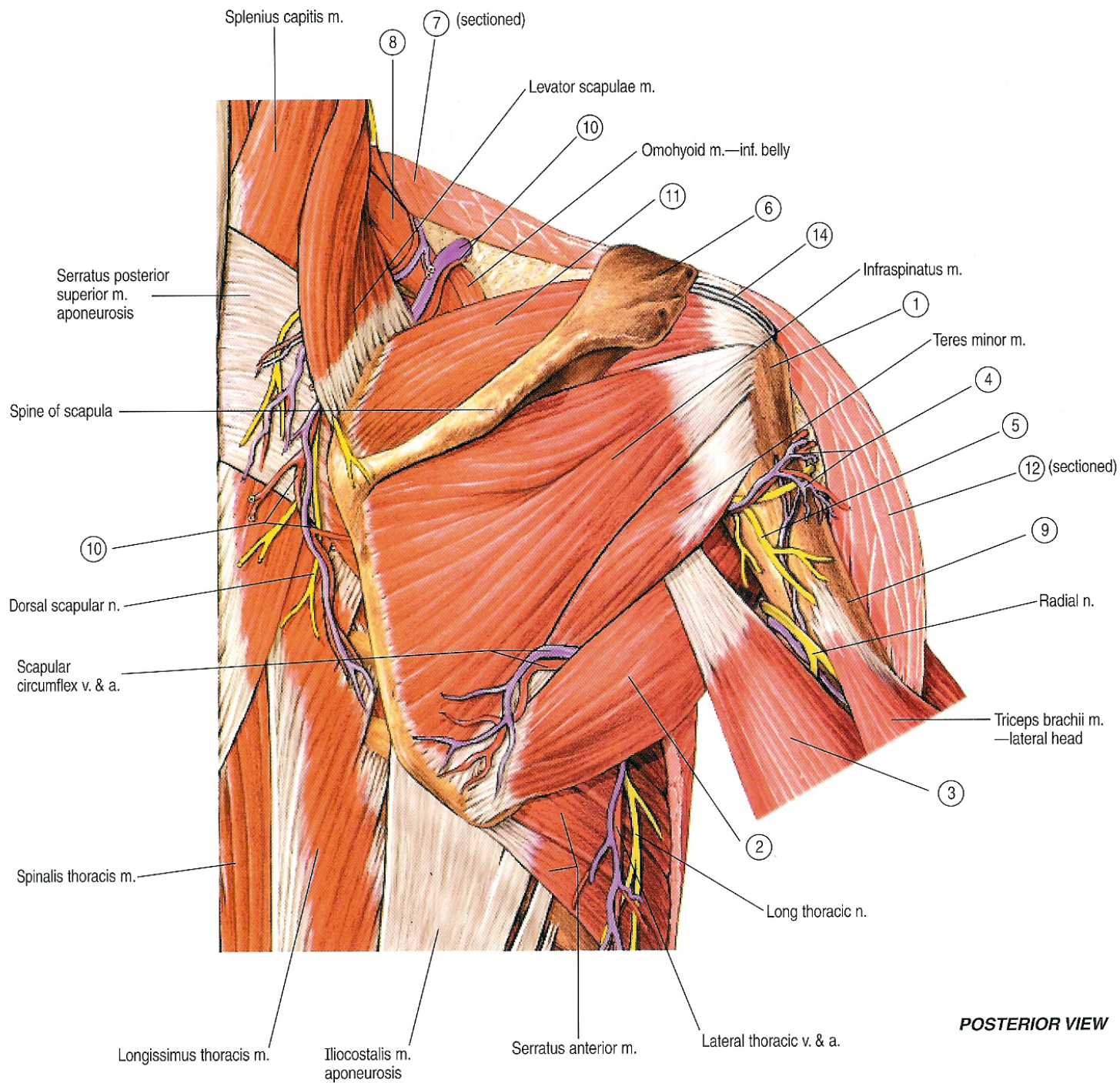
- A. It protracts the scapula anteriorly and fixes it to the thoracic wall.
- B. With the trapezius, it rotates the scapula upward.
- C. It acts as a strong accessory muscle of inspiration.







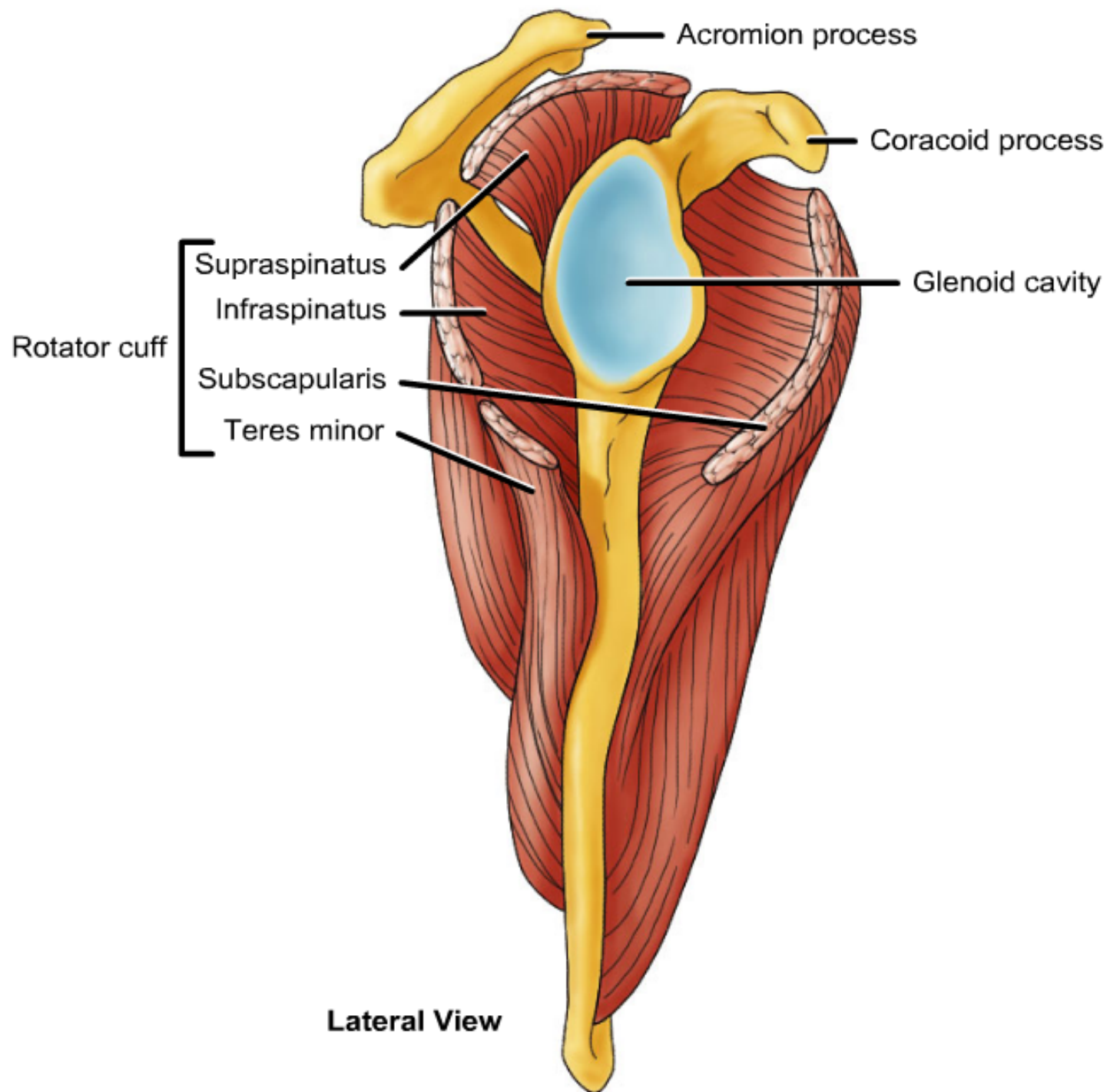




POSTERIOR VIEW

Rotator cuff Muscles

- They are the supraspinatus, infraspinatus, teres minor and subscapularis muscle.
- They surround the shoulder joint, except from the inferior aspect (weak point).
- Their tone helps in holding the head of humerus in the glenoid cavity.
- They maintain the stability of the shoulder joint.



Anterior Compartment of the Arm

Biceps brachii

➤ Origin:

1. Long head: from the supraglenoid tubercle of the scapula.
2. Short head: from the tip of coracoid process of the scapula.

➤ Insertion:

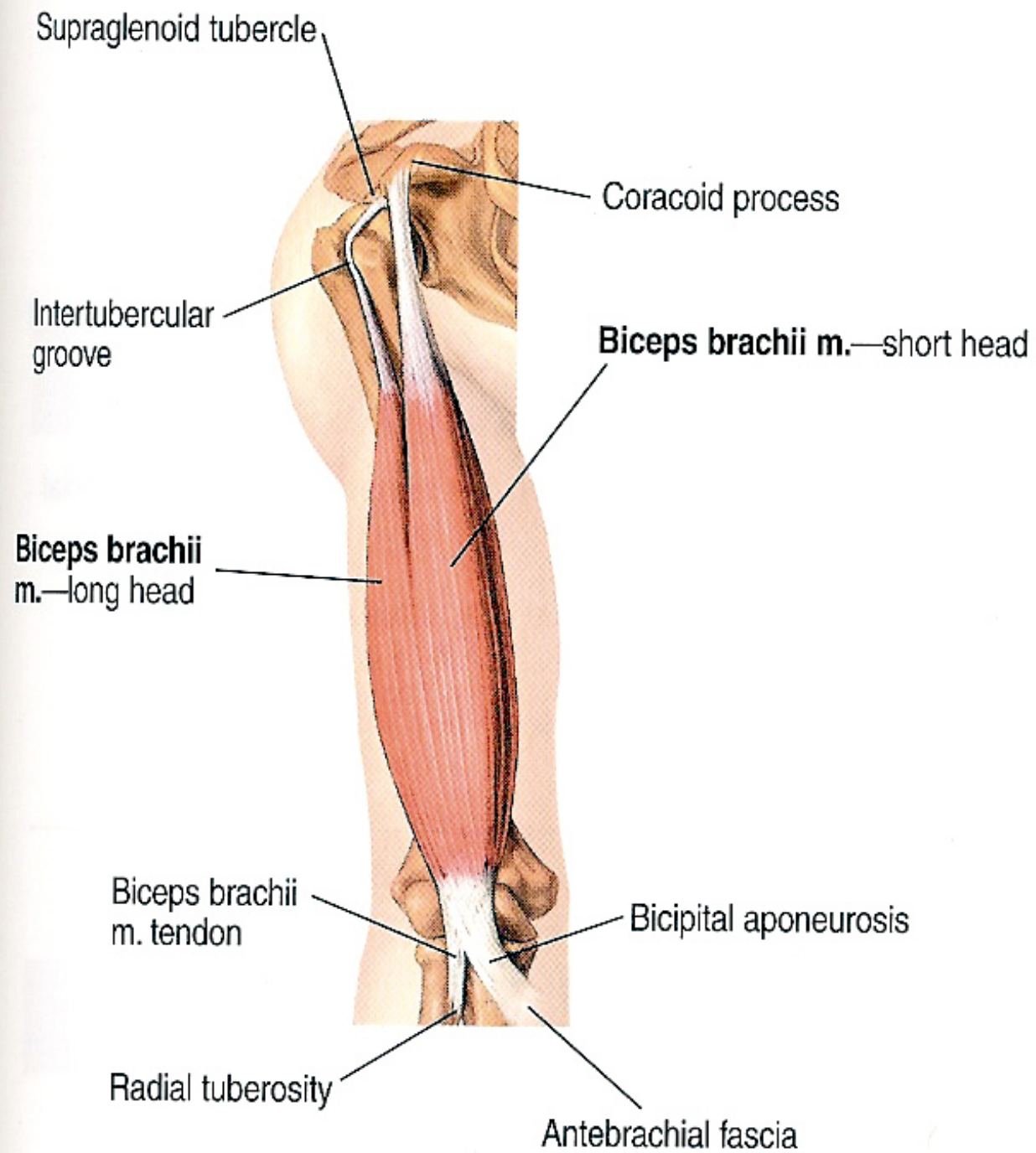
1. Into the **posterior part** of the radial tuberosity of the radius.
2. Forms the bicipital aponeurosis which is inserted into the deep fascia of the upper part of the medial side of the forearm.

➤ Nerve Supply:

From musculocutaneous nerve.

➤ Action:

1. Supination of the forearm at the radio-ulnar joints.
2. Flexion of the forearm at the elbow joint.
3. Weak flexion of the shoulder joint.



Coracobrachialis

➤ Origin:

From the tip of coracoid process of the scapula (with short head of biceps).

➤ Insertion:

Into the **middle third** of the medial side of the shaft of the humerus.

➤ Nerve Supply:

From musculocutaneous nerve.

➤ Action:

1. Flexion of the shoulder joint.
2. Weak adduction of the shoulder joint.

la

Coracoid process of scapula

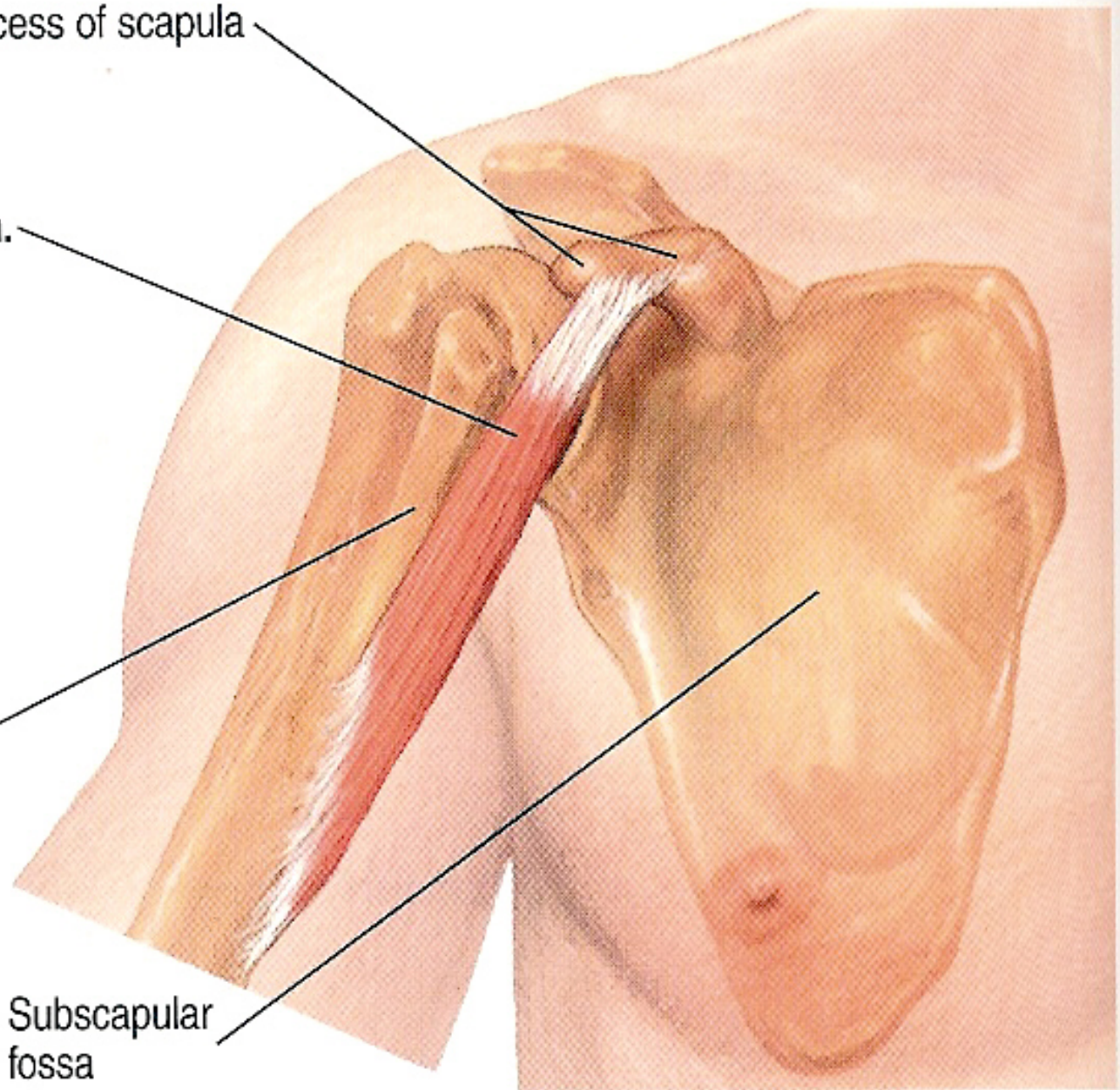
Coracobrachialis m.

humerus

Crest of lesser tubercle

Subscapular
fossa

ANTERIOR VIEWS



Brachialis

➤ Origin:

From the lower half of the anterior surface of the shaft of the humerus and the adjoining parts of the medial and lateral intermuscular septa.

➤ Insertion:

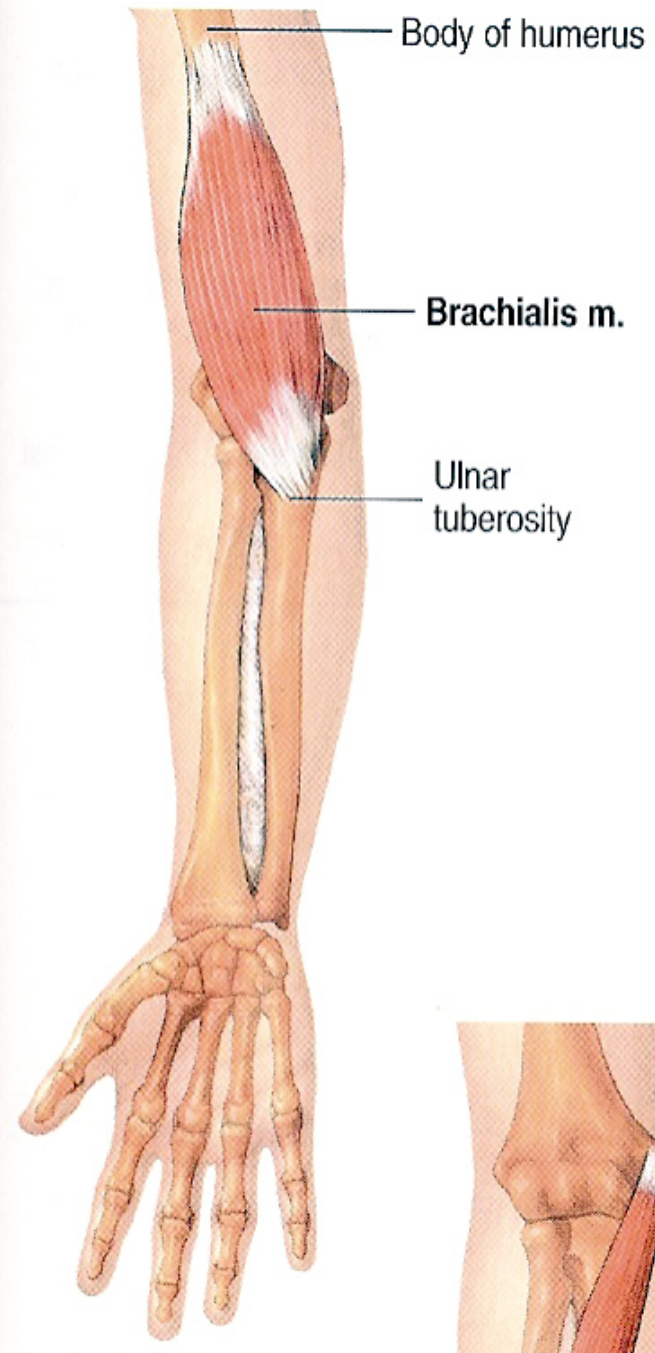
Into the **anterior surface** of the coronoid process of the ulna.

➤ Nerve Supply:

1. Majority of the muscle from musculocutaneous nerve.
2. Small lateral part by the radial nerve.

➤ Action:

Strong flexion of the elbow joint.



Posterior Compartment of the Arm

Triceps muscle

➤ Origin:

1. Long head: from the infraglenoid tubercle of the scapula.
2. Lateral head: from the upper half of the posterior surface of the shaft of the humerus, **above and lateral** to the spiral groove.
3. Medial head: from the lower half of the posterior surface of the shaft of the humerus, **below and medial** to the spiral groove.

➤ Insertion:

Into the **upper surface** of the olecranon process of the ulna.

➤ Nerve Supply:

From the radial nerve (through many branches at the axilla and the spiral groove).

➤ Action:

Extension of the forearm at the elbow joint.

Infraglenoid tubercle of scapula

Radial n. (spiral) groove

Triceps brachii m.—lateral head

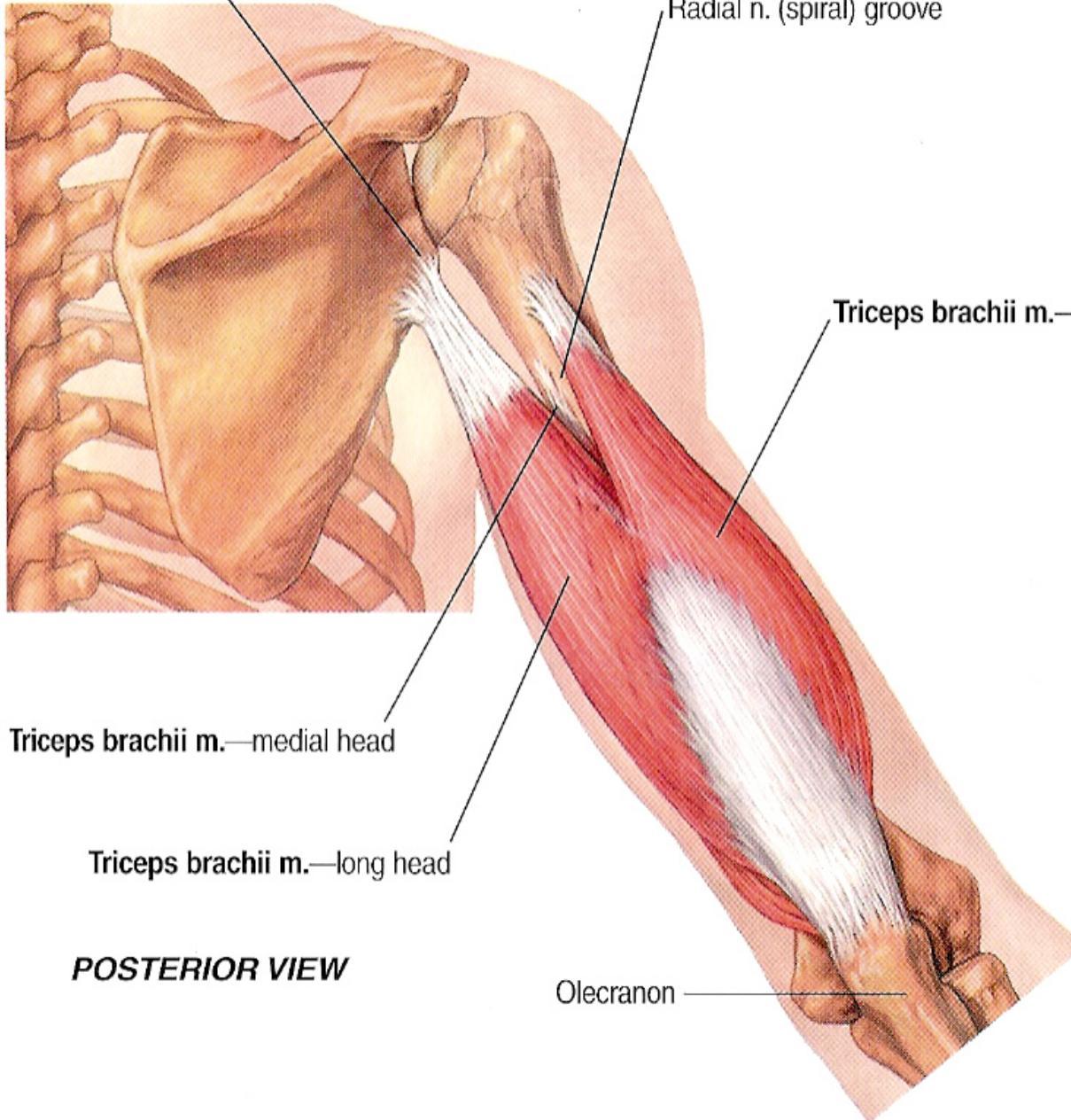
Triceps brachii m.—medial head

Triceps brachii m.—long head

POSTERIOR VIEW

Olecranon

Spine of



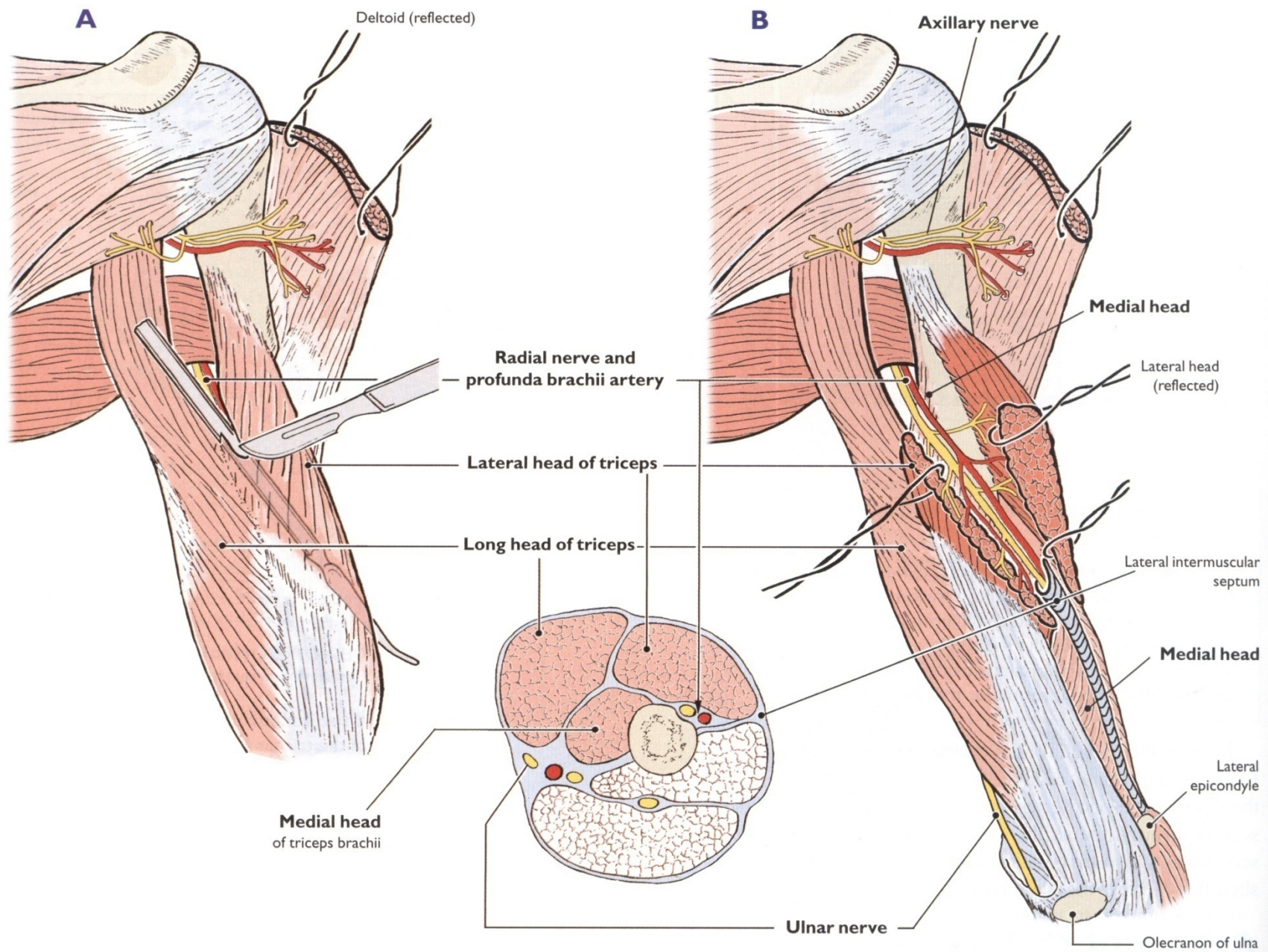
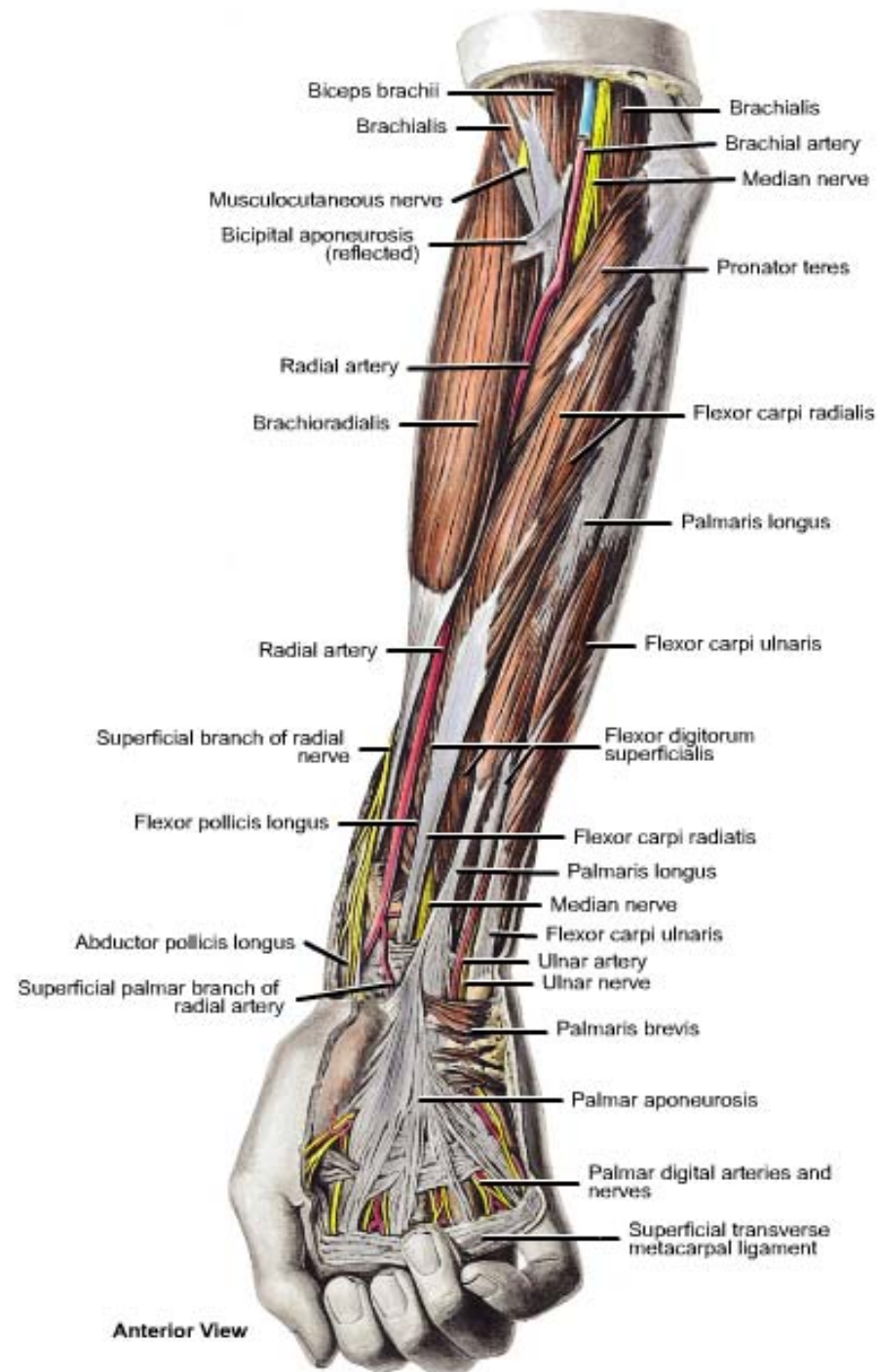


Figure 6.23. A, Division of the lateral head of the triceps brachii to expose the course of the radial nerve. **B,** Triceps brachii and its three related nerves.

FOREARM

**ANTERIOR (FLEXOR)
COMPARTMENT**

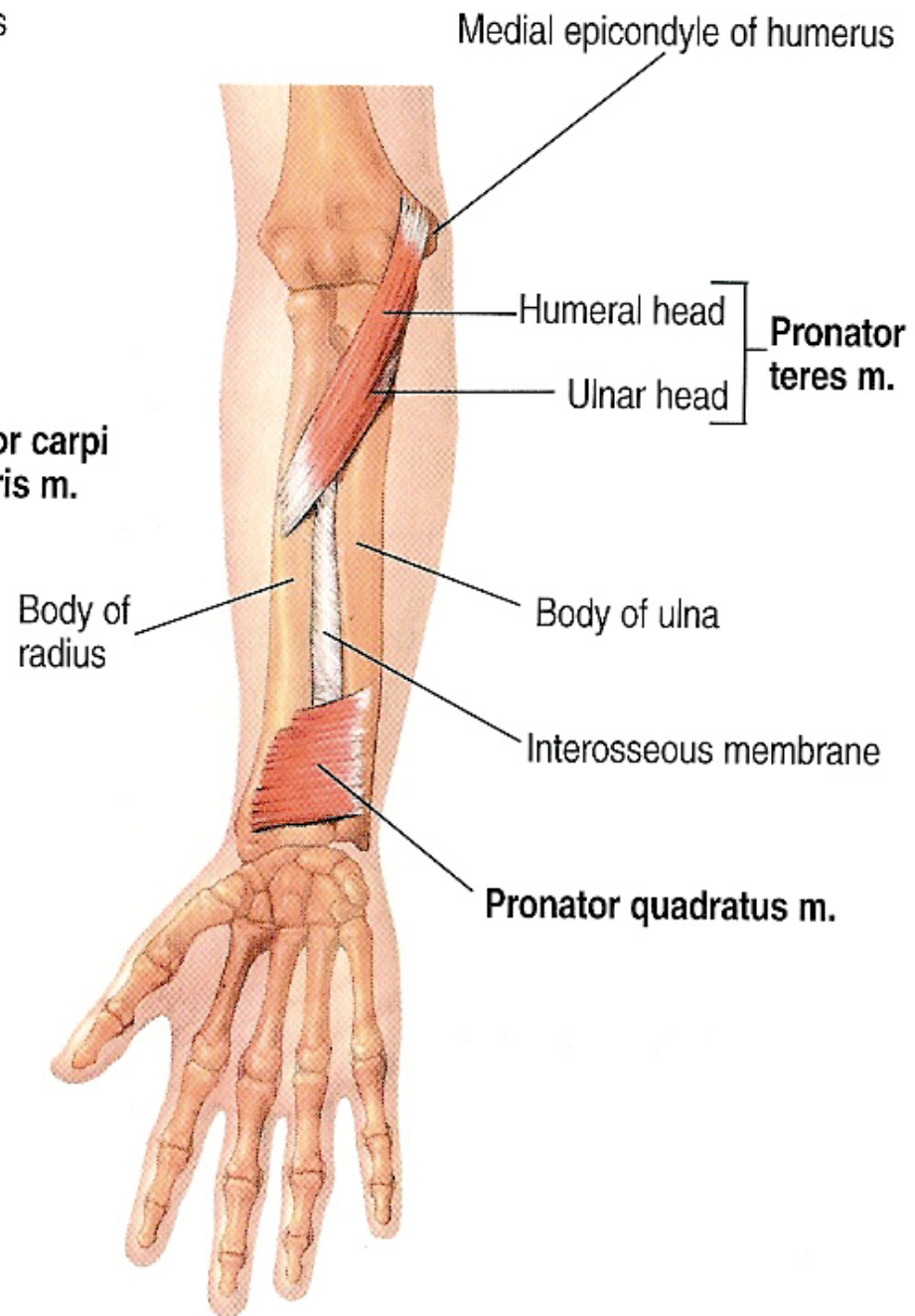


Muscles of the Anterior Compartment of the forearm

- A. Superficial Layer:** (1) Pronator teres, (2) flexor carpi radialis, (3) palmaris longus, (4) flexor digitorum superficialis and (5) flexor carpi ulnaris.
- B. Deep Layer:** (1) Flexor pollicis longus, (2) flexor digitorum profundus and (3) pronator quadratus.

US

or carpi
aris m.



Pronator teres

➤ Origin:

1. Humeral head: from the medial epicondyle of the humerus (common flexor origin).
2. Ulnar head: from the medial border of the coronoid process of the ulna.

➤ Insertion:

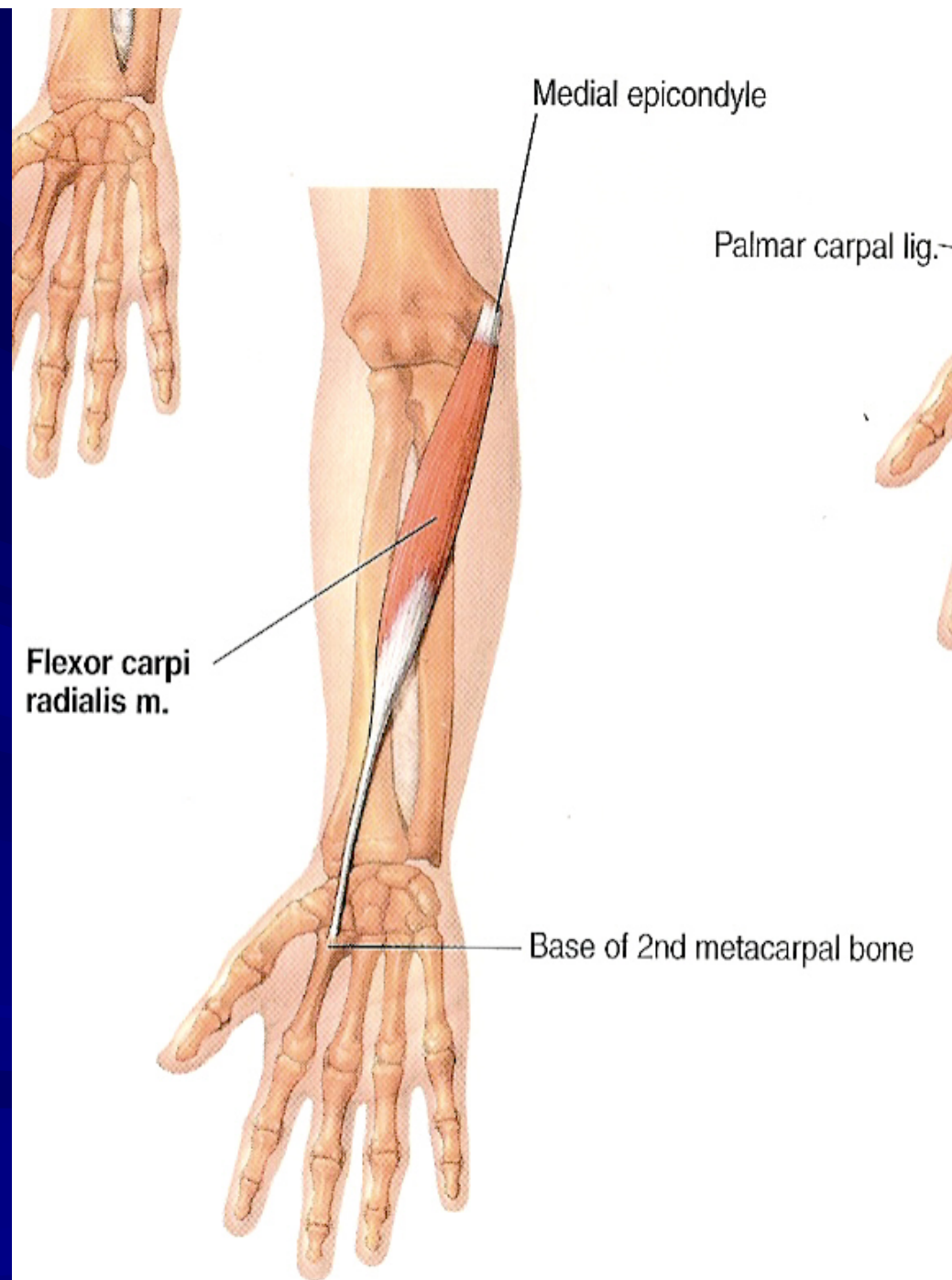
- Into the **pronator tuberosity** on the lateral surface of the middle part of the shaft of the radius.

➤ Nerve Supply:

From the median nerve.

➤ Action:

1. Pronation of the forearm at the radio-ulnar joints.
2. Flexion of the forearm at the elbow joint.



Flexor carpi radialis

➤ Origin:

- From the medial epicondyle of the humerus (common flexor origin).

➤ Insertion:

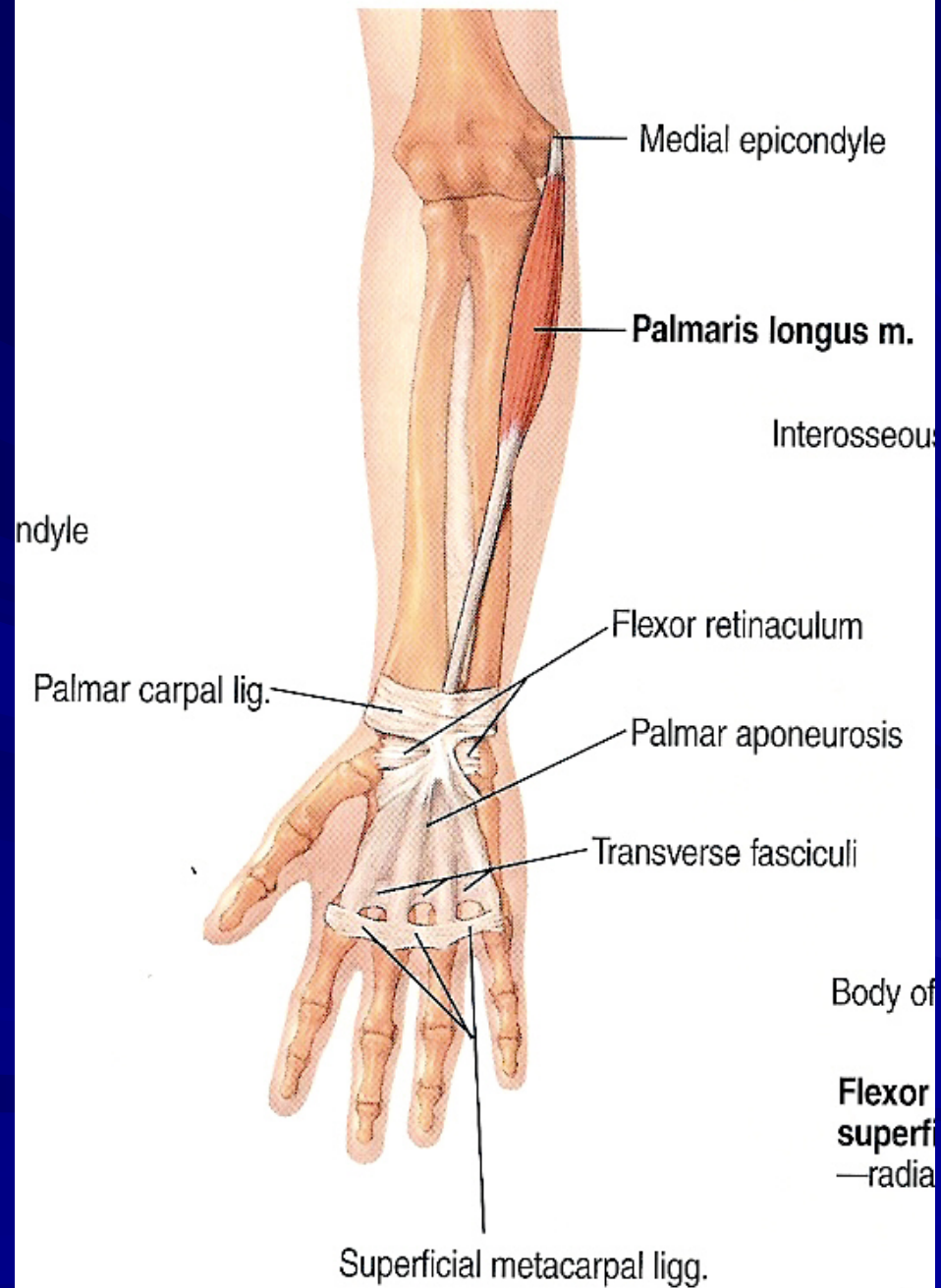
- Into palmar surface of the **bases** of the 2nd and 3rd metacarpal bones.

➤ Nerve Supply:

From the median nerve.

➤ Action:

1. Flexion of the hand at the wrist joint.
2. Abduction of the hand at the wrist joint.



Palmaris longus

➤ Origin:

- From the medial epicondyle of the humerus (common flexor origin).

➤ Insertion:

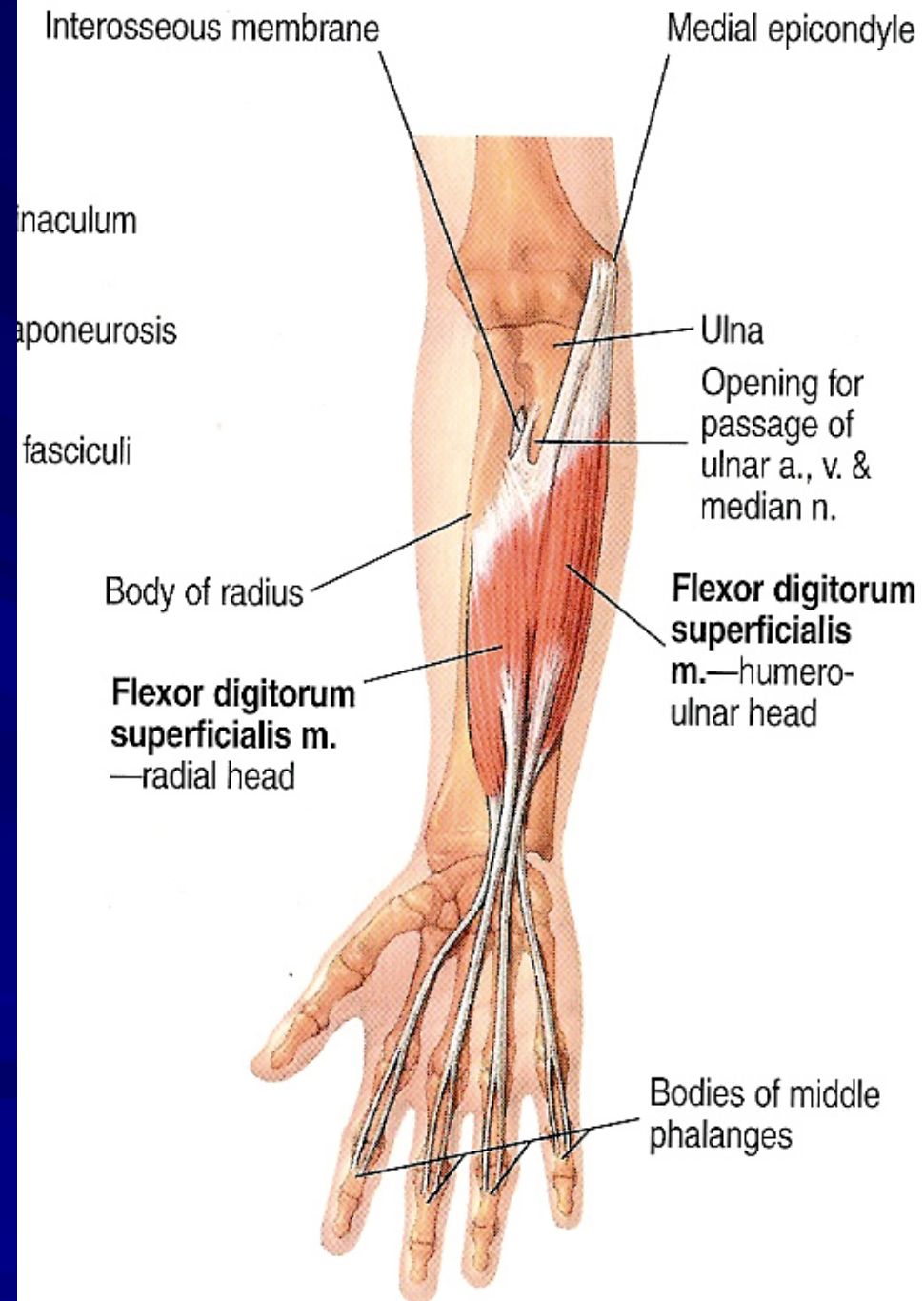
- Into the palmar aponeurosis and flexor retinaculum.

➤ Nerve Supply:

- From the median nerve.

➤ Action:

- Flexion of the hand at the wrist joint.



Flexor digitorum superficialis

➤ Origin:

1. Humero-ulnar head: from the medial epicondyle of the humerus (common flexor origin) and from the medial border of the coronoid process of the ulna.
2. Radial head: from the oblique line on the anterior surface of the shaft of the radius.

➤ Insertion:

- Its tendon divides into 4 tendons which are inserted into the sides of the middle phalanges of the medial 4 fingers.

➤ Nerve Supply:

- From the median nerve.

➤ Action:

1. Flexion of the proximal interphalangeal joints and metacarpophalangeal joints of the medial 4 fingers.
2. Helps of flexion of the hand at the wrist joint.

—short head

Medial epicondyle of humerus

osis

Humeral head

Ulnar head

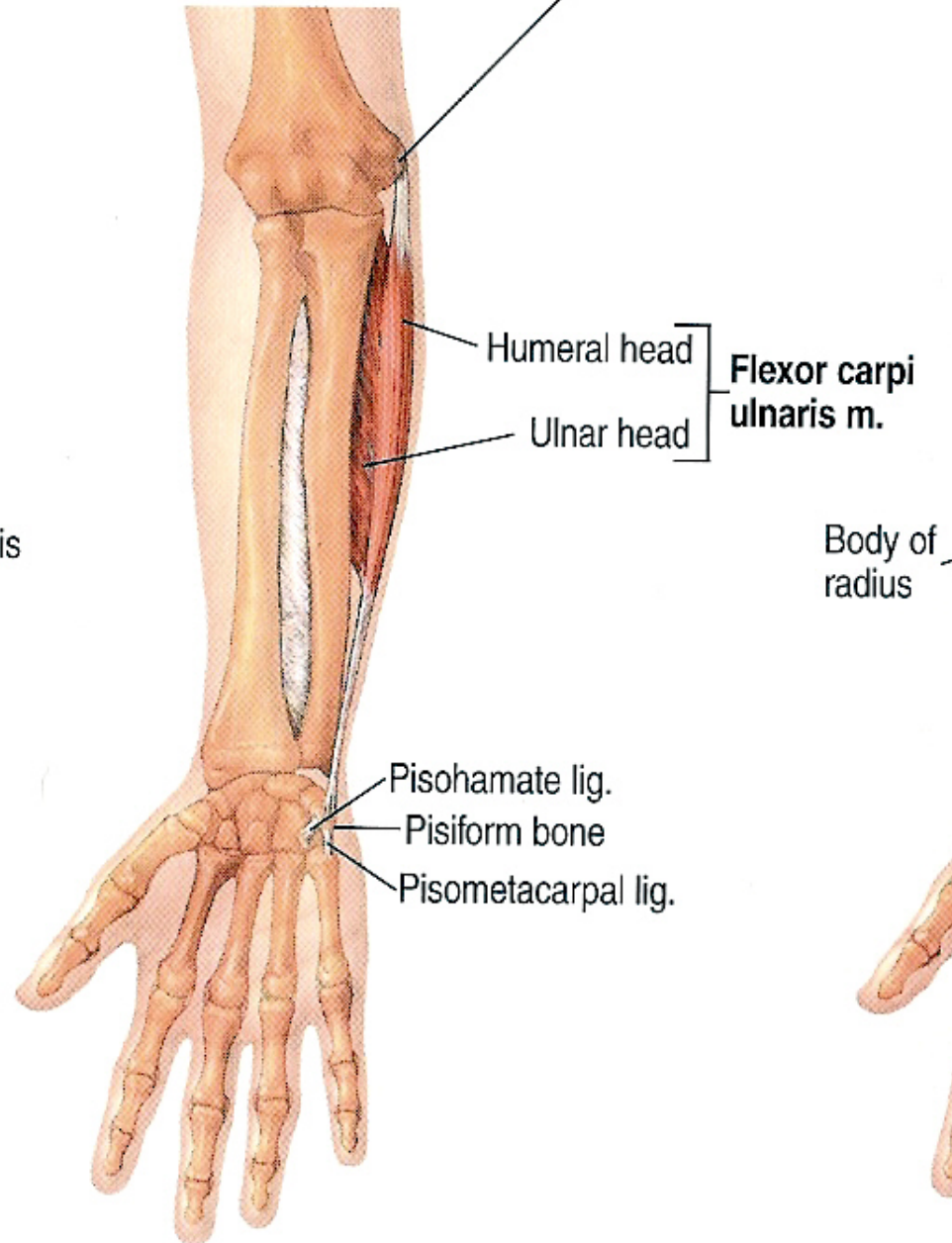
**Flexor carpi
ulnaris m.**

Body of
radius

Pisohamate lig.

Pisiform bone

Pisometacarpal lig.



Flexor carpi ulnaris

➤ Origin:

1. Humeral head: from the medial epicondyle of the humerus (common flexor origin).
2. Ulnar head: from the medial aspect of the olecranon process and form the posterior border of the shaft of the ulna.

➤ Insertion:

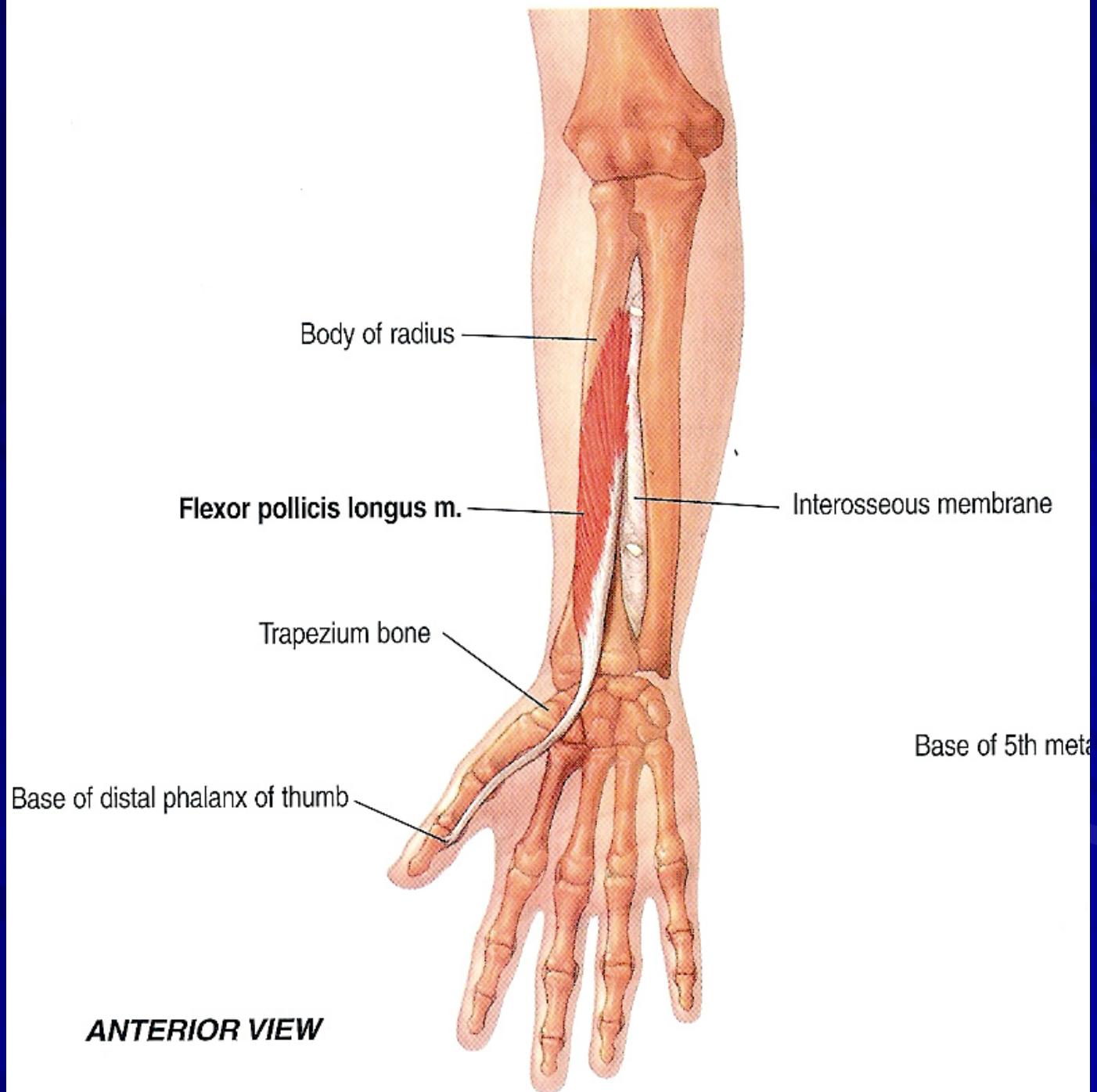
- Into the pisiform, hook of hamate and base of the 5th metacarpal bone.

➤ Nerve Supply:

- From the **ULNAR** nerve.

➤ Action:

1. Flexion of the hand at the wrist joint.
2. Adduction of the hand at the wrist joint.



Flexor pollicis longus

➤ Origin:

- From the anterior surface of the middle of the shaft of the radius and adjoining part of the interosseus membrane.

➤ Insertion:

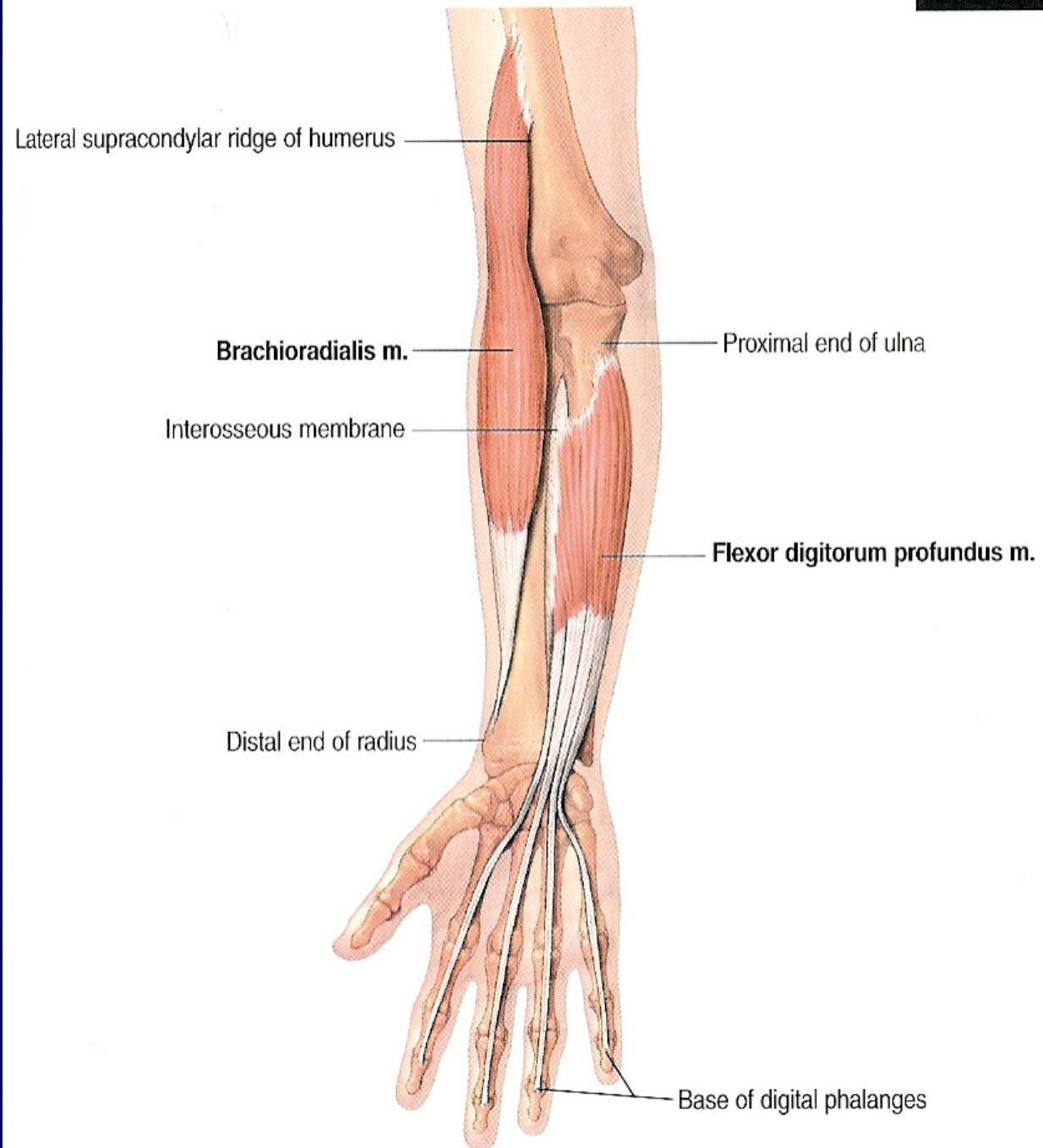
- Into the palmar surface of the base of the distal phalanx of the thumb.

➤ Nerve Supply:

- From the anterior interosseus nerve (branch of the median nerve).

➤ Action:

- Flexion of the thumb.



Flexor digitorum profundus

➤ Origin:

- From the upper $\frac{3}{4}$ of the anterior surface of the shaft of the ulna and adjoining part of the interosseus membrane.

➤ Insertion:

- The muscle divides into 4 tendons which pierce the tendons of the flexor digitorum superficialis and are inserted into the bases of the distal phalanges of the medial 4 fingers.

➤ Nerve Supply:

- **Its lateral half:** from the anterior interosseus nerve (branch of the median nerve).
- **It medial half:** from the ulnar nerve.

➤ Action:

1. Flexion of the distal interphalangeal joints of the medial 4 fingers.
2. Helps in flexion of the proximal interphalangeal joints and metacarpophalangeal joints of the medial 4 fingers.
3. Helps of flexion of the hand at the wrist joint.

US

or carpi
aris m.

Body of
radius

Medial epicondyle of humerus

Humeral head

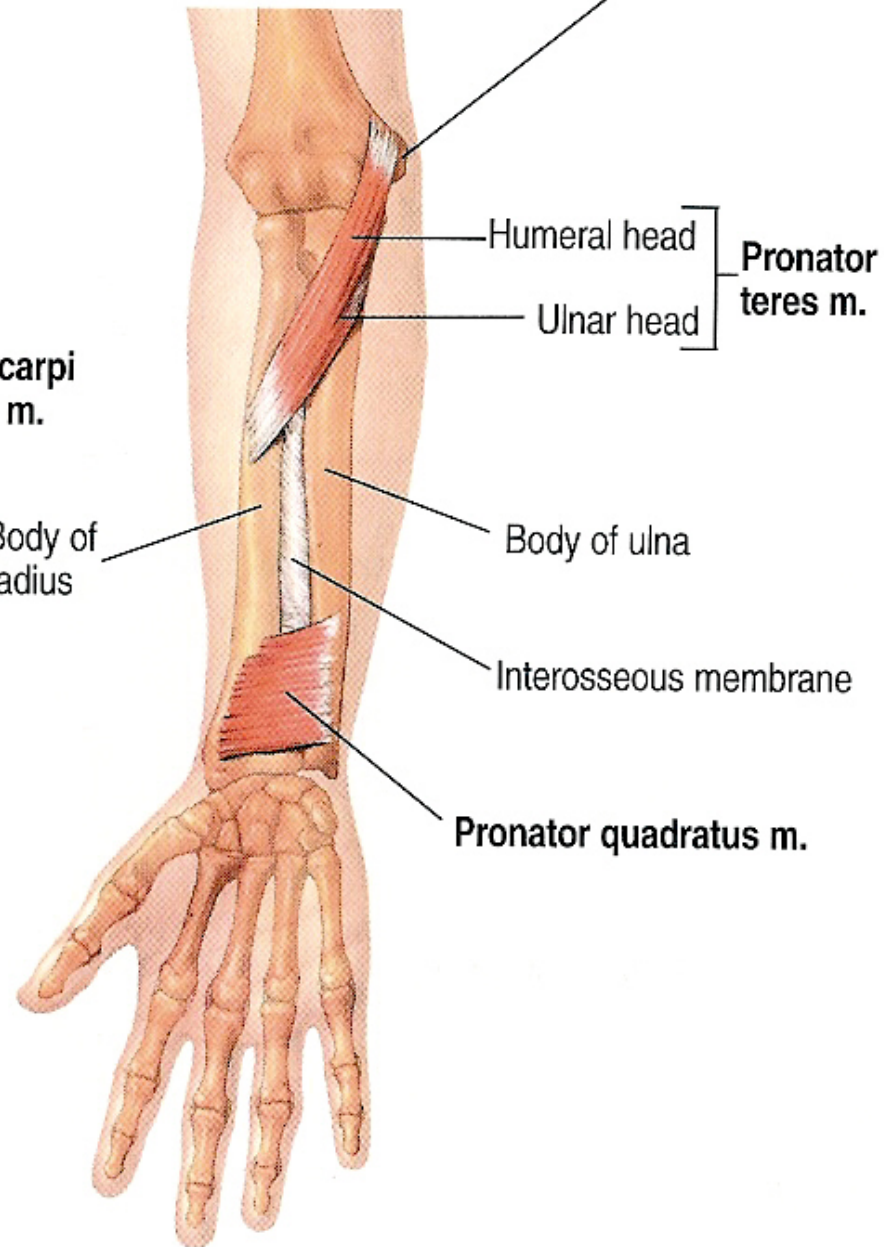
Ulnar head

Pronator
teres m.

Body of ulna

Interosseous membrane

Pronator quadratus m.



Pronator quadratus

➤ Origin:

- From the lower $\frac{1}{4}$ of the anterior surface of the shaft of the ulna.

➤ Insertion:

- Into the lower $\frac{1}{4}$ of the anterior surface of the shaft of the radius.

➤ Nerve Supply:

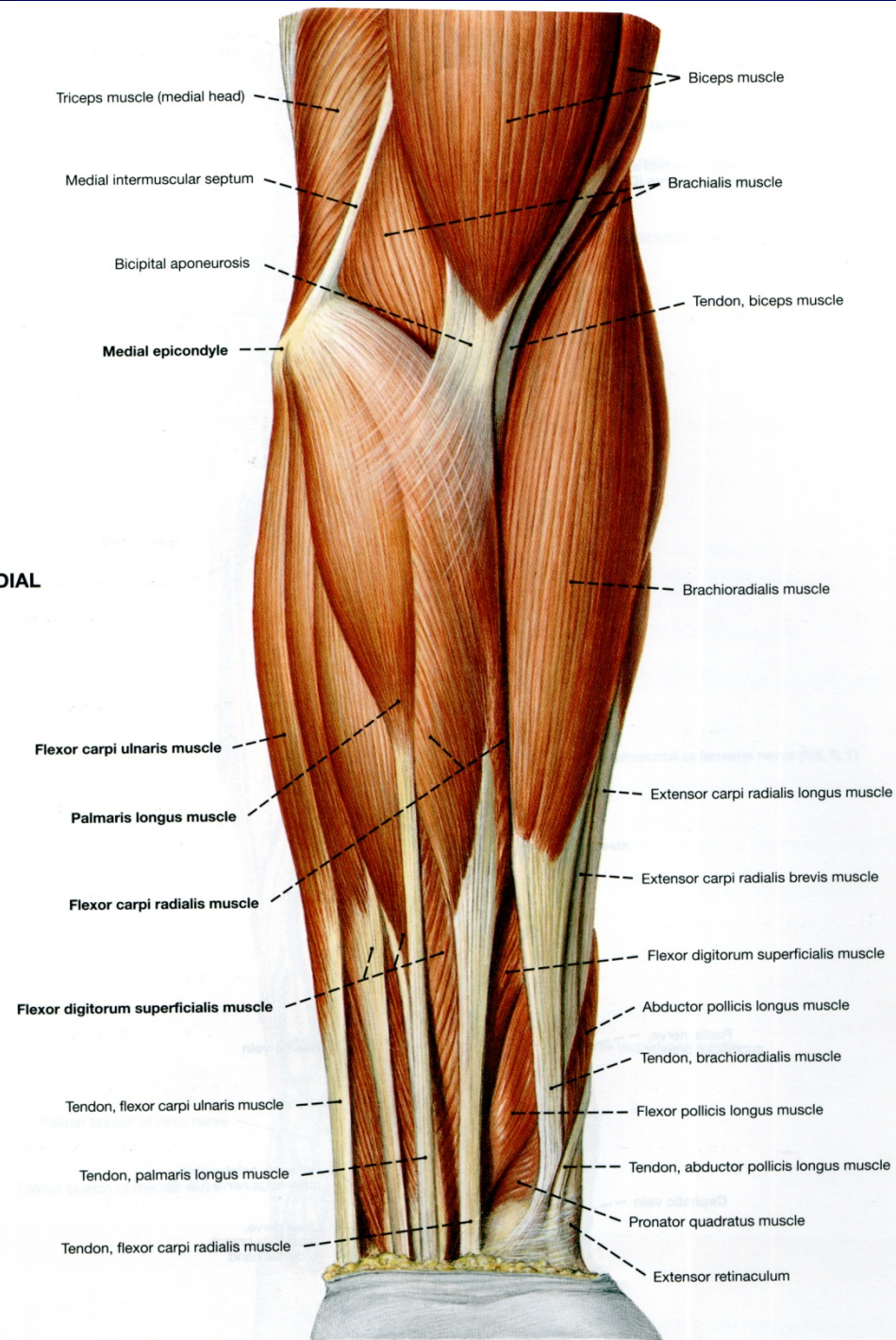
- From the anterior interosseus nerve (branch of the median nerve).

➤ Action:

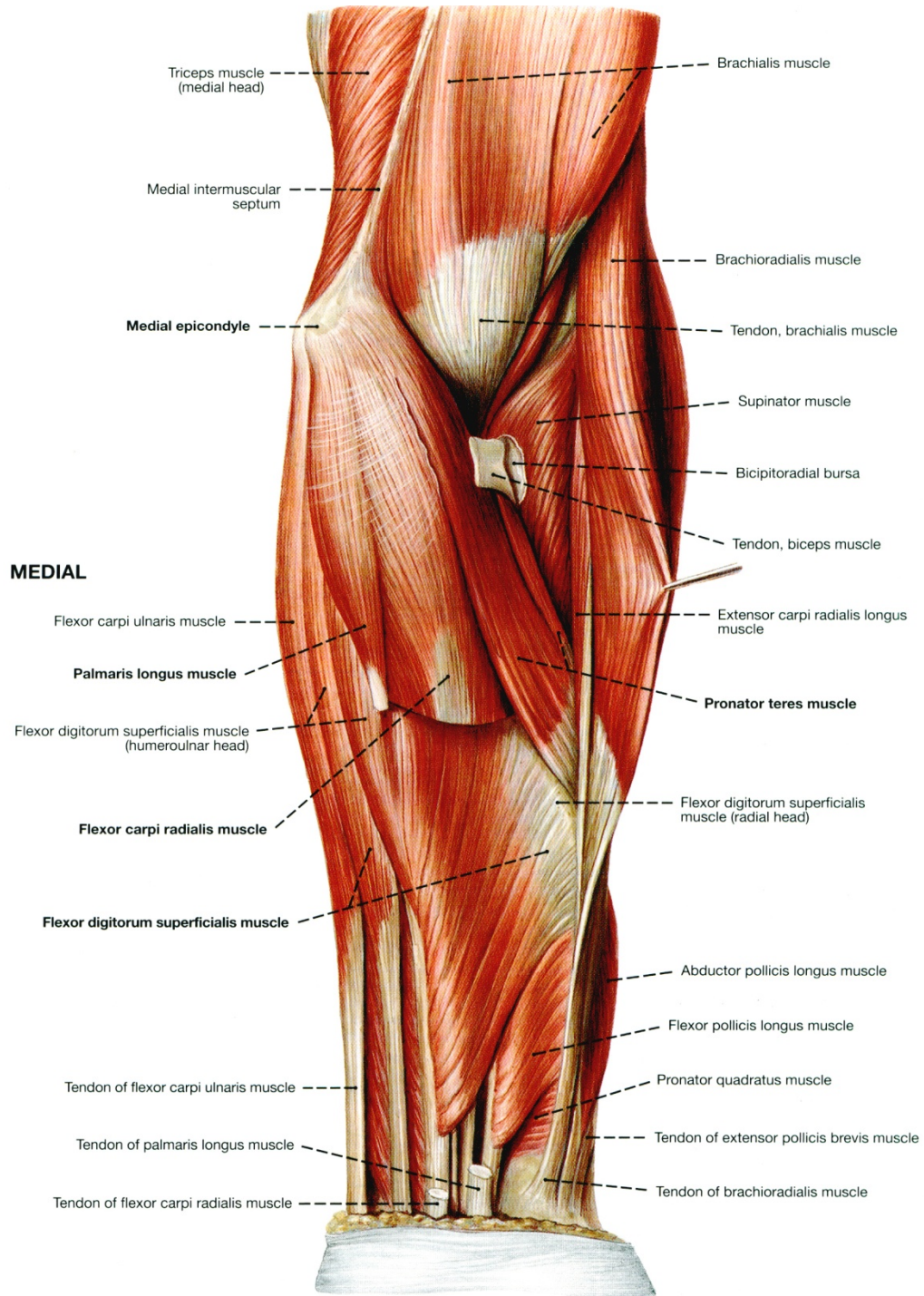
- Pronation of the forearm at the radio-ulnar joints.

MEDIAL

LATERAL



MEDIAL



Brachialis muscle

Brachioradialis muscle

Tendon, brachialis muscle

Supinator muscle

Bicipitoradial bursa

Tendon, biceps muscle

Extensor carpi radialis longus muscle

Pronator teres muscle

Flexor digitorum superficialis muscle (radial head)

Abductor pollicis longus muscle

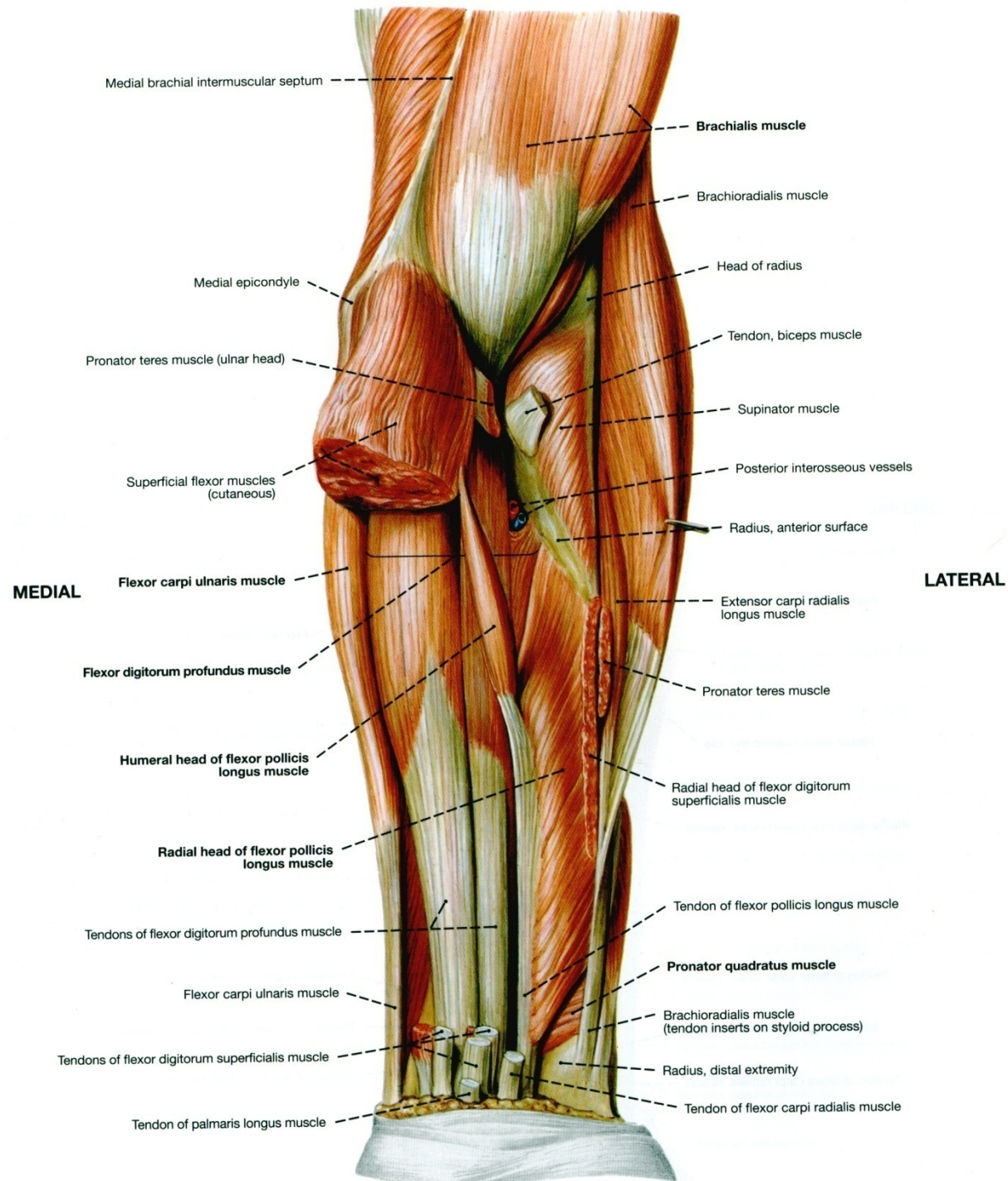
Flexor pollicis longus muscle

Pronator quadratus muscle

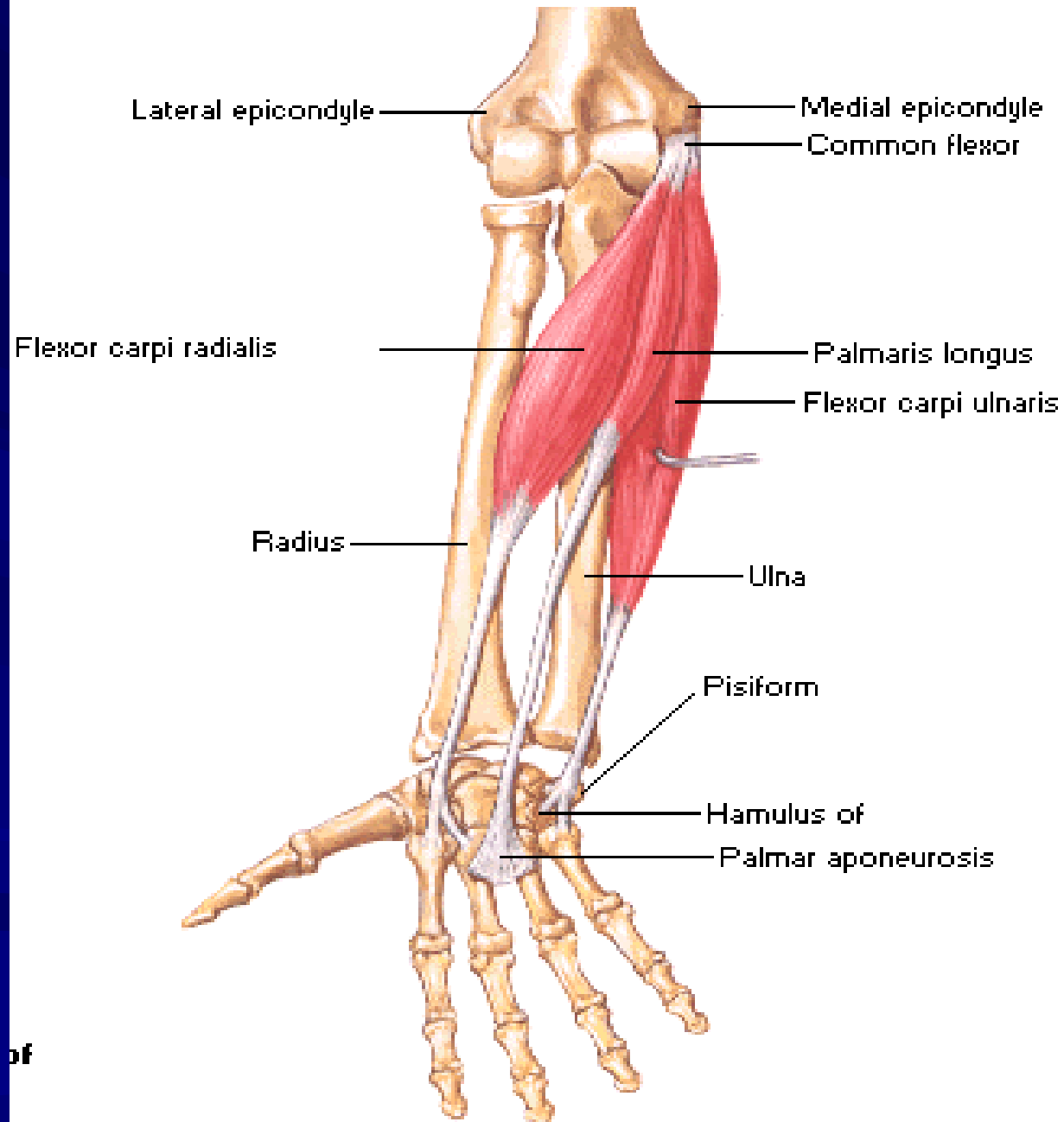
Tendon of extensor pollicis brevis muscle

Tendon of brachioradialis muscle

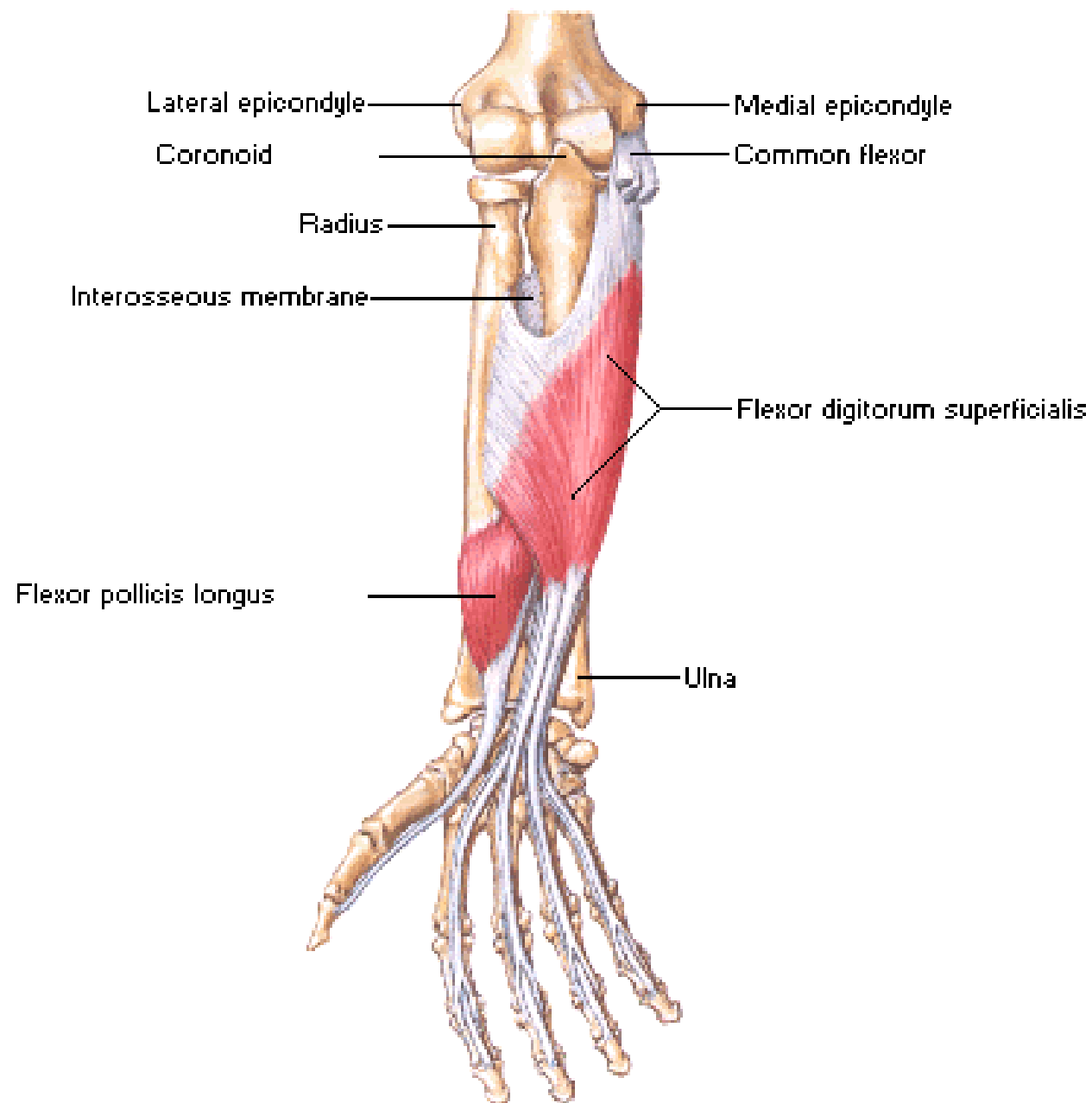
LATERAL



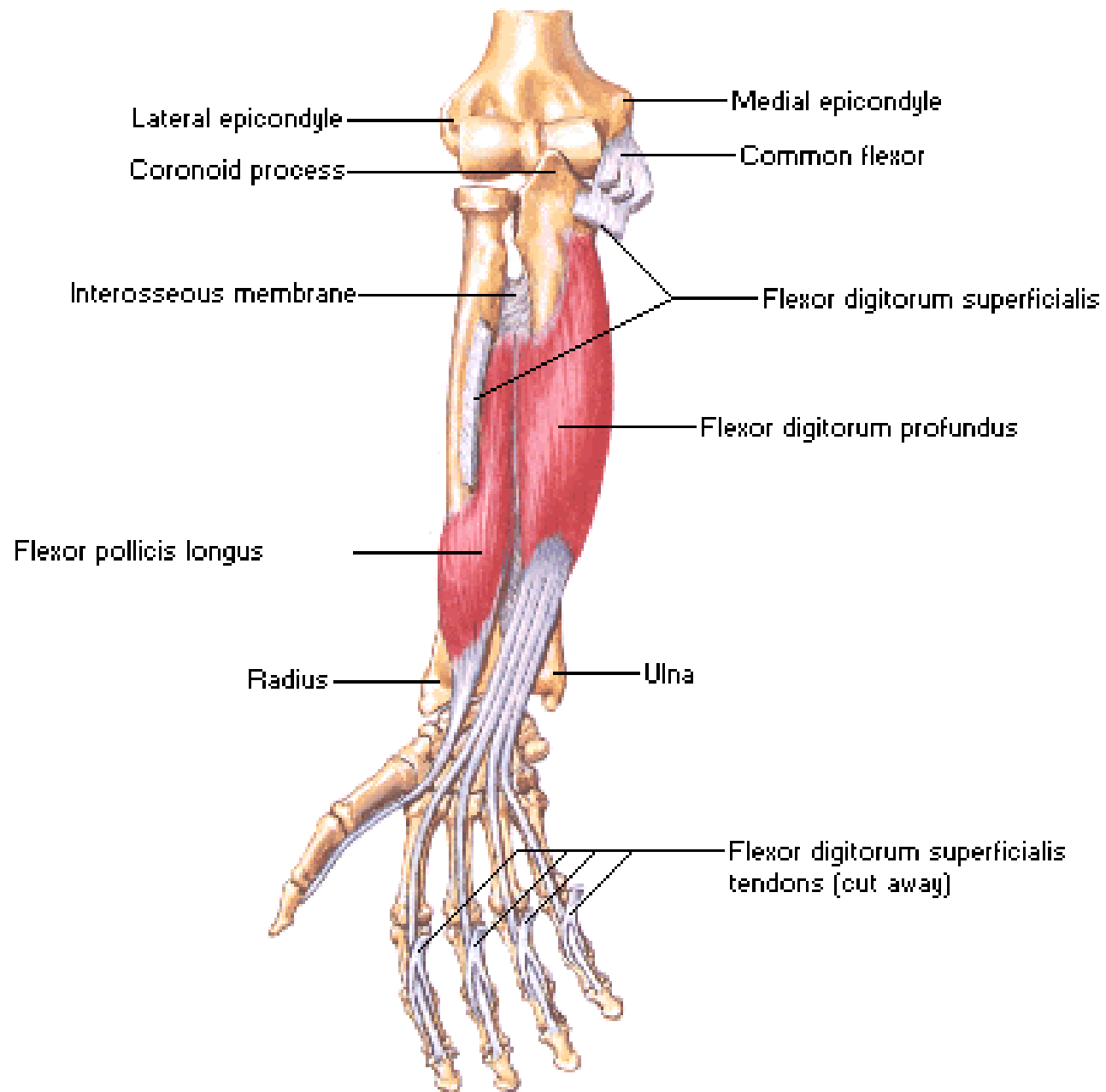
Flexors of Wrist



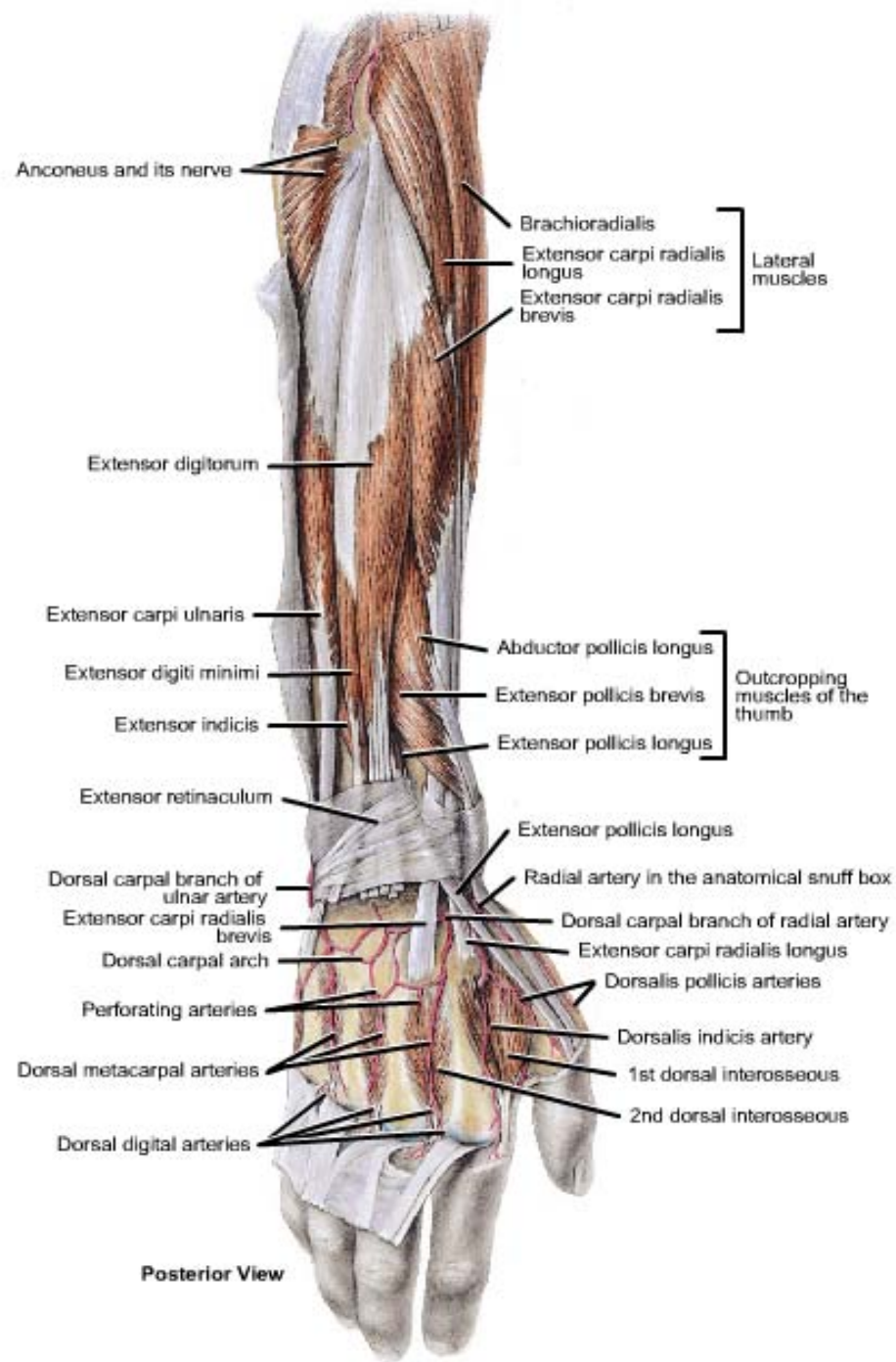
Flexors of Digits



Flexors of Digits



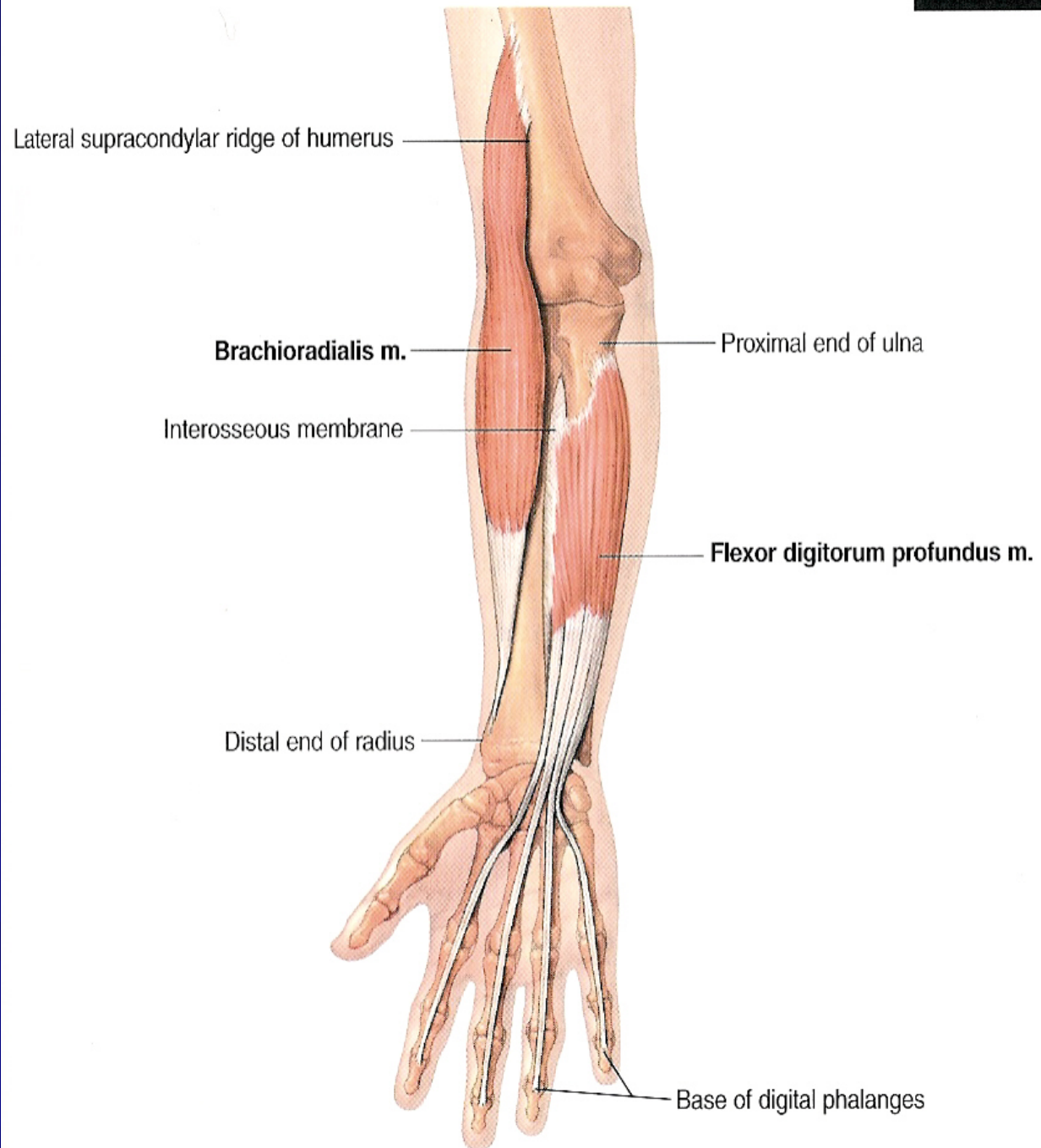
POSTERIOR (EXTENSOR) COMPARTMENT



Muscles of the posterior compartment of the forearm

A. Superficial Layer: (1) Brachioradialis, (2) extensor carpi radialis longus, (3) extensor carpi radialis brevis, (4) extensor digitorum, (5) extensor digiti minimi, (6) extensor carpi ulnaris and (7) anconeus.

B. Deep Layer: (1) Supinator, (2) abductor pollicis longus, (3) extensor pollicis brevis, (4) extensor pollicis longus and (5) extensor indicis.



Brachioradialis

➤ Origin:

- from the upper 2/3 of the lateral supracondylar ridge of the humerus.

➤ Insertion:

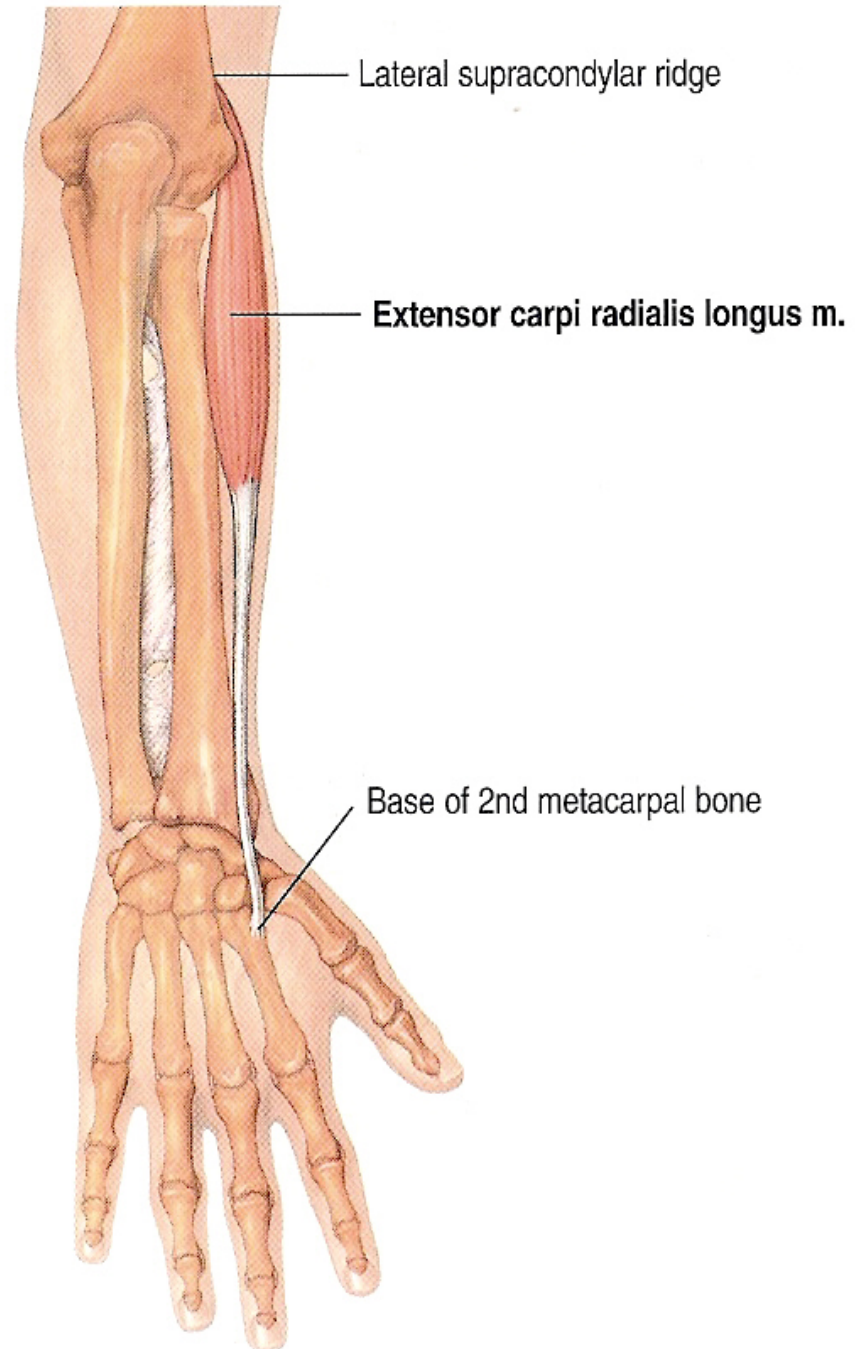
- Into the **base** of the styloid process of the radius.

➤ Nerve Supply:

- From the radial nerve.

➤ Action:

1. Flexion of the forearm (specially in midprone position).
2. Restoration of the forearm into the midprone position.



Extensor carpi radialis longus

➤ Origin:

- from the lower 1/3 of the lateral supracondylar ridge of the humerus.

➤ Insertion:

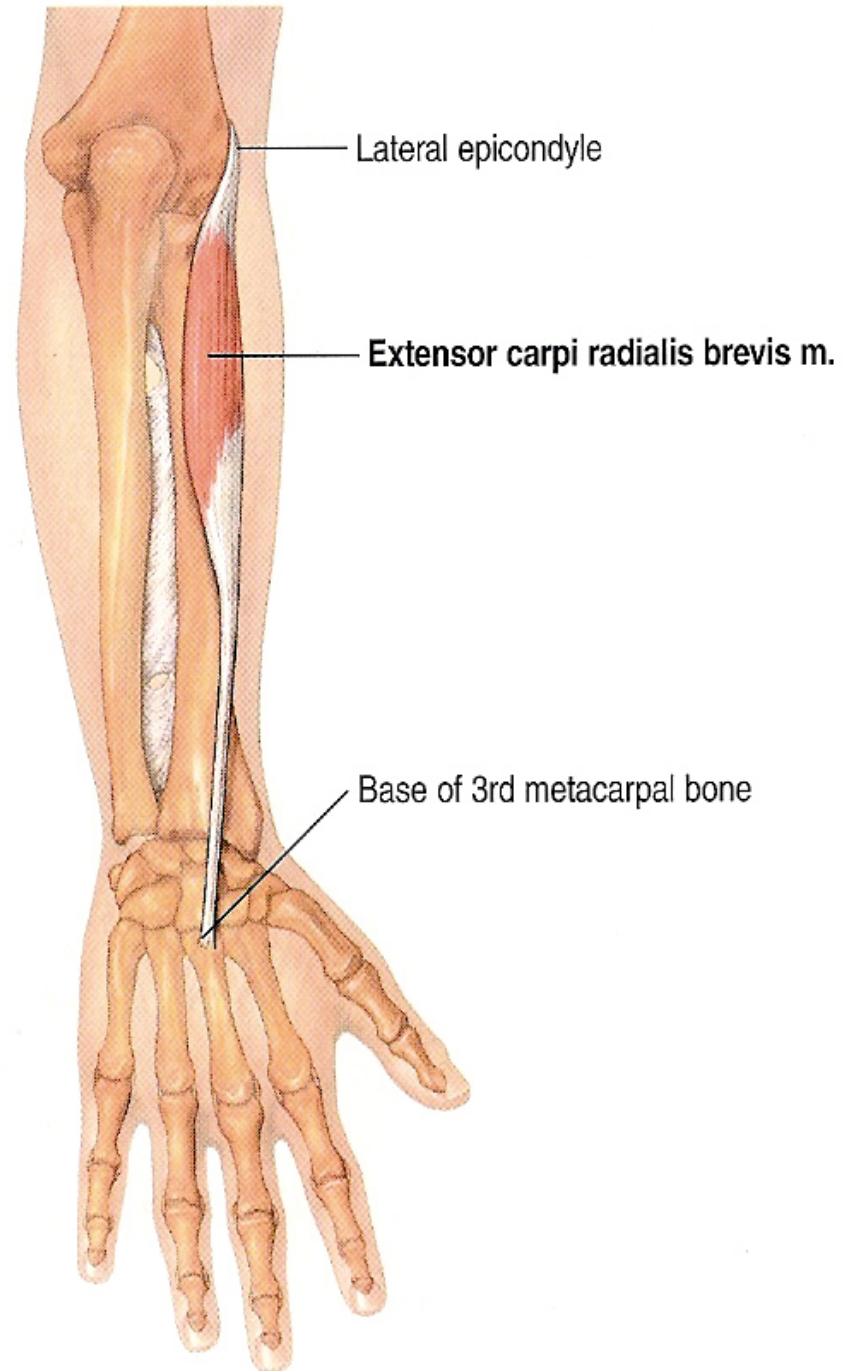
- Into the posterior surface of the **base** of the **2nd** metacarpal bone.

➤ Nerve Supply:

- From the **radial** nerve.

➤ Action:

1. Extension of the hand at wrist joint.
2. Abduction of the hand at wrist joint.



Extensor carpi radialis brevis

➤ Origin:

- from the lateral epicondyle of the humerus (common extensor origin).

➤ Insertion:

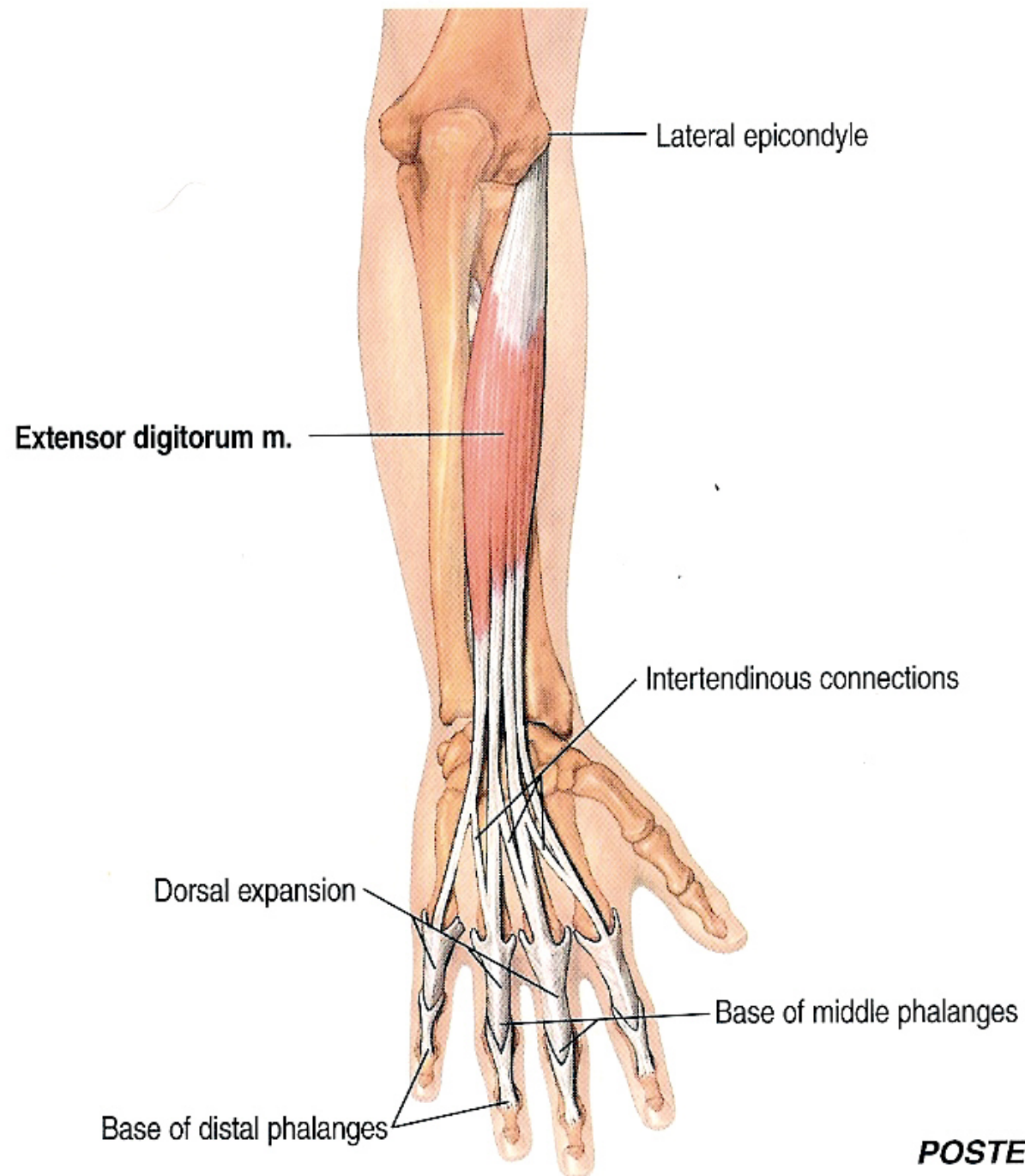
- Into the posterior surface of the **base** of the **3rd** metacarpal bone.

➤ Nerve Supply:

- From the **deep branch of radial** nerve.

➤ Action:

1. Extension of the hand at wrist joint.
2. Abduction of the hand at wrist joint.



POSTERIOR

Extensor digitorum

➤ Origin:

- from the lateral epicondyle of the humerus (common extensor origin).

➤ Insertion:

- Into the **extensor expansion** of the medial 4 fingers.

➤ Nerve Supply:

- From the **deep branch of radial** nerve.

➤ Action:

1. Extension of metacarpophalangeal and interphalangeal joints of the medial 4 fingers.
2. Extension of the hand at wrist joint.

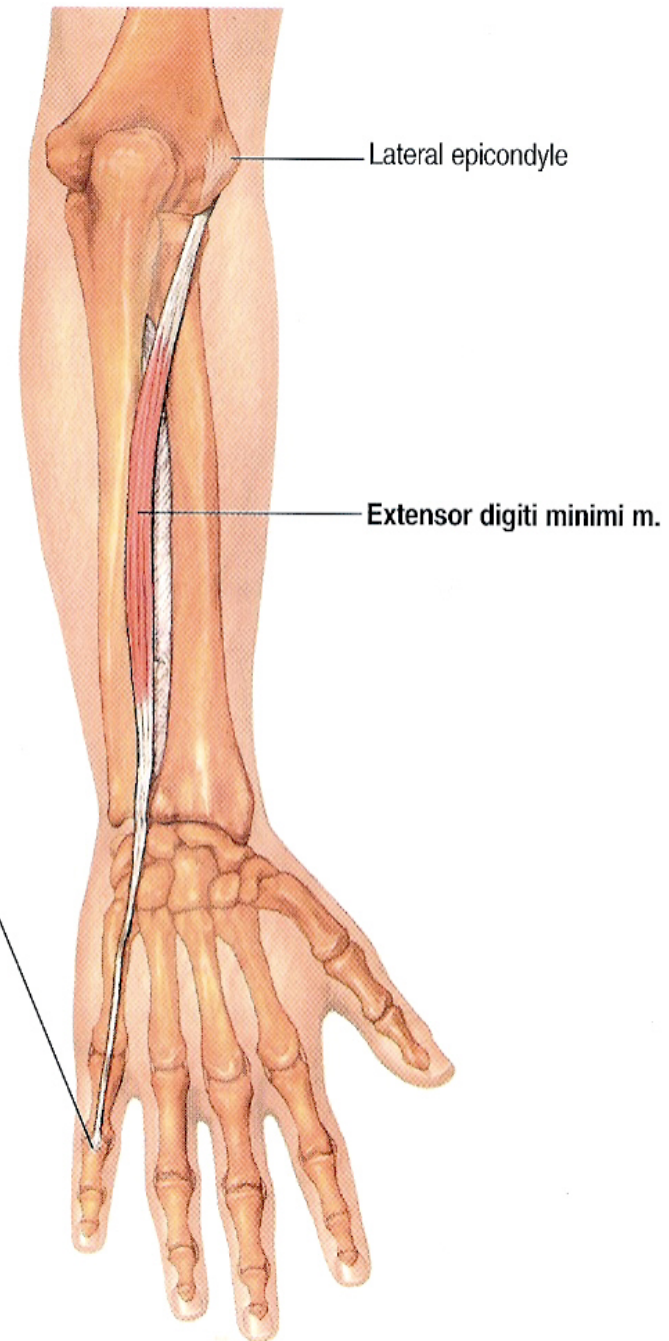
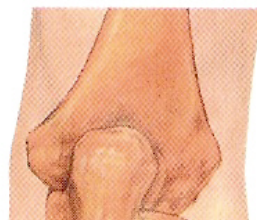ane

vis m.

roximal phalanx

Extensor expansion over base of 5th middle phalanx

POSTERIOR VIEWS



Extensor digiti minimi

➤ Origin:

- from the lateral epicondyle of the humerus (common extensor origin).

➤ Insertion:

- Into the **extensor expansion** of the little finger.

➤ Nerve Supply:

- From the **deep branch of radial** nerve.

➤ Action:

1. Extension of metacarpophalangeal and interphalangeal joints of the little finger.
2. Helps in extension of the hand at wrist joint.

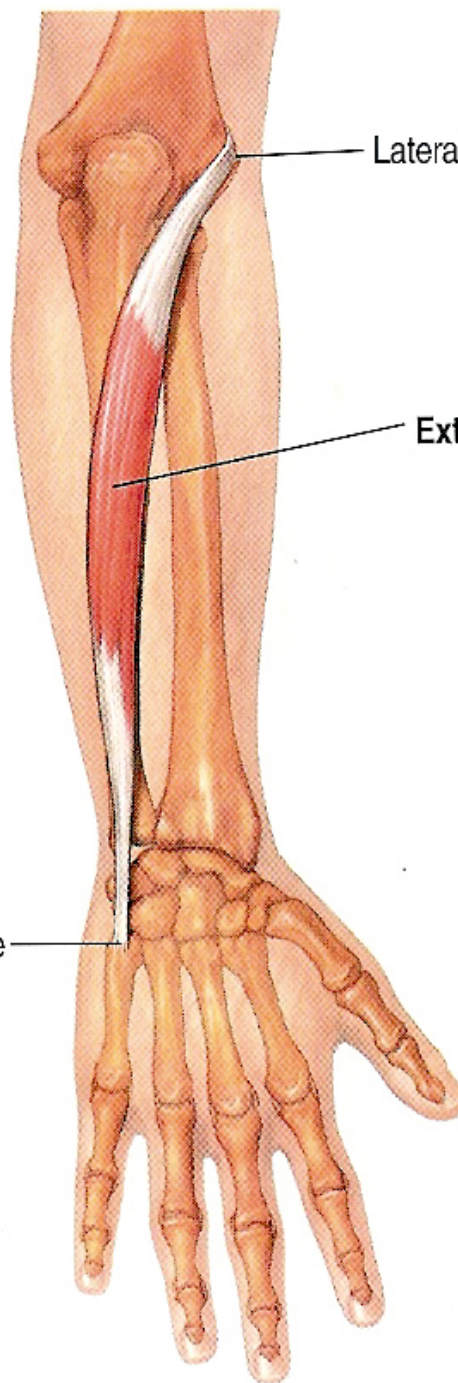
ous membrane

Base of 5th metacarpal bone

Lateral epicondyle

Extensor carpi ulnaris m.

POSTERIOR VIEW



Extensor carpi ulnaris

➤ Origin:

- from the lateral epicondyle of the humerus (common extensor origin).

➤ Insertion:

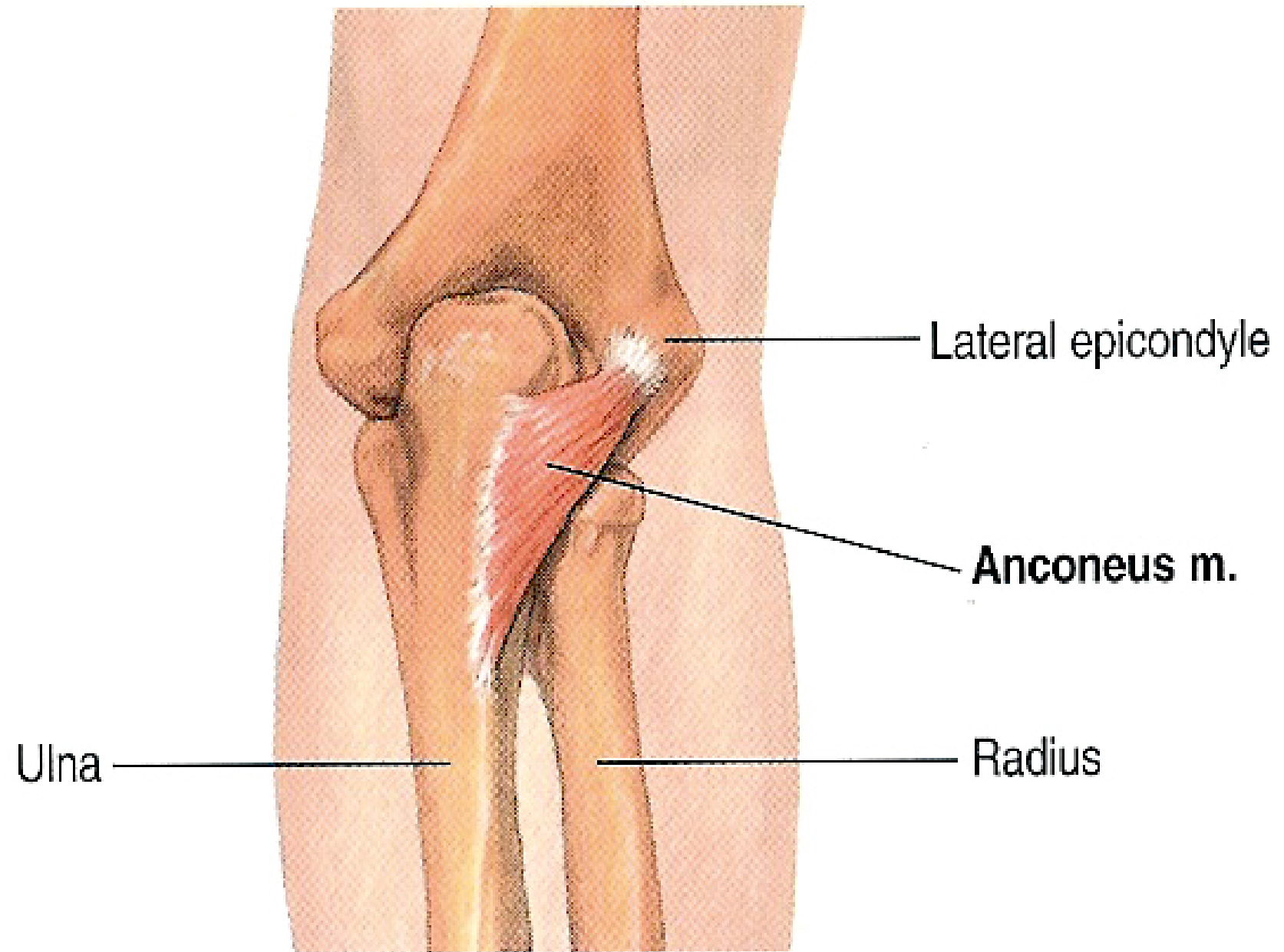
- Into the posterior surface of the base of the 5th metacarpal bone.

➤ Nerve Supply:

- From the **deep branch of radial** nerve.

➤ Action:

1. Extension of the hand at wrist joint.
2. Adduction of the hand at wrist joint.



Anconeus

➤ Origin:

- from the posterior aspect of the lateral epicondyle of the humerus.

➤ Insertion:

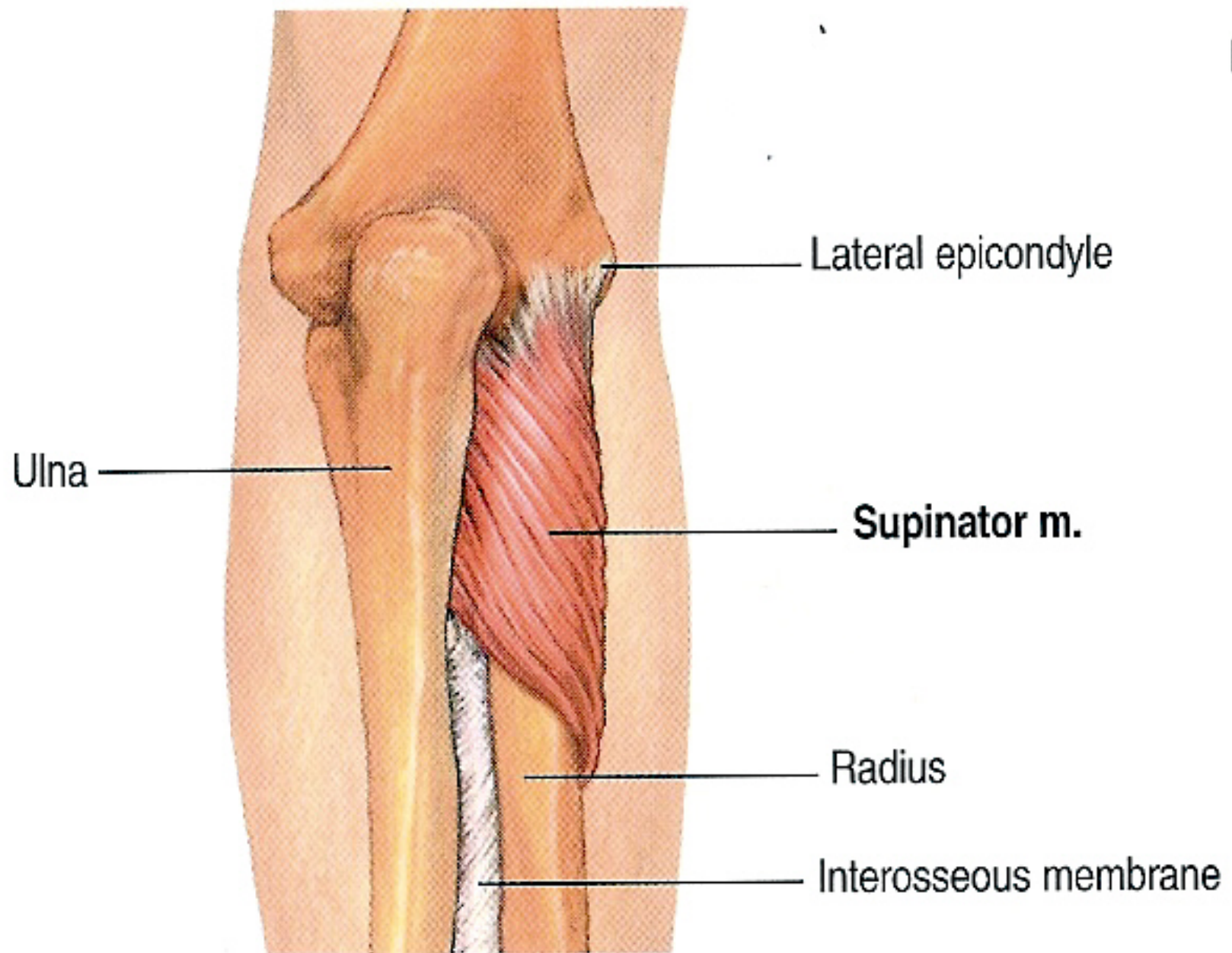
- Into the lateral surface of the olecranon process of the ulna.

➤ Nerve Supply:

- From the radial nerve.

➤ Action:

- It helps the triceps in extension of the elbow joint.



POSTER

Supinator

➤ Origin:

- from (1) the lateral epicondyle of the humerus, (2) lateral collateral ligament of the elbow joint, (3) annular ligament of the superior radio-ulnar joint, and (4) supinator fossa and crest of the ulna.

➤ Insertion:

- Into the upper 1/3 of the lateral surface of the shaft of the radius.

➤ Nerve Supply:

- From the deep branch of the radial nerve.

➤ Action:

- It helps the biceps in supination of the forearm at the radio-ulnar joints.

Posterior subcutaneous
border of ulna

Radius

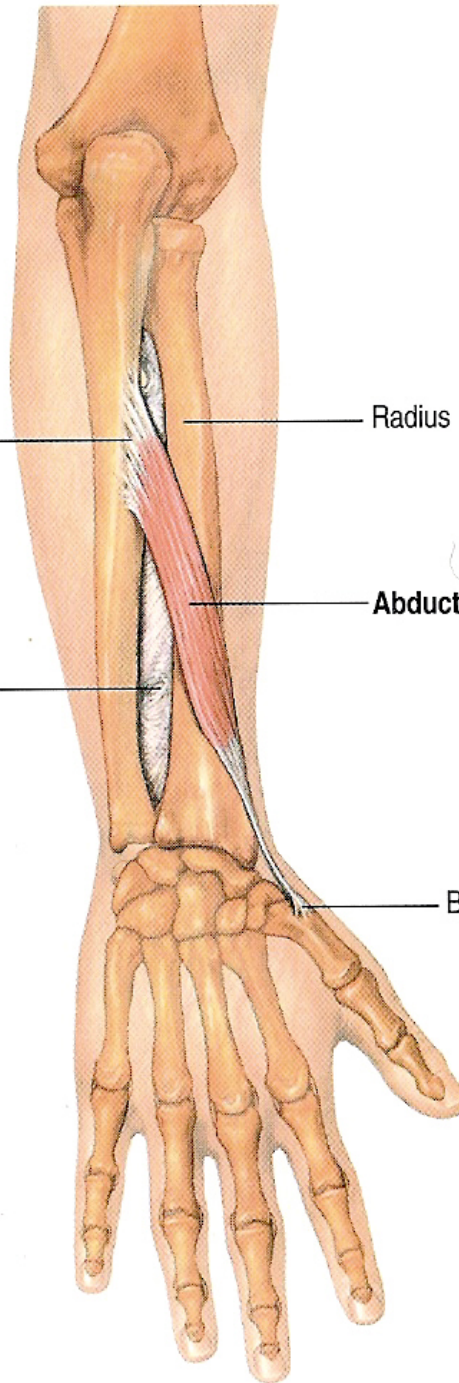
Abductor pollicis longus m.

Interosseous membrane

Base of 1st metacarpal bone

brane

POSTERIOR VIEWS



Abductor pollicis longus

➤ Origin:

- from the middle of the posterior surface of **radius and ulna** and intervening interosseus membrane.

➤ Insertion:

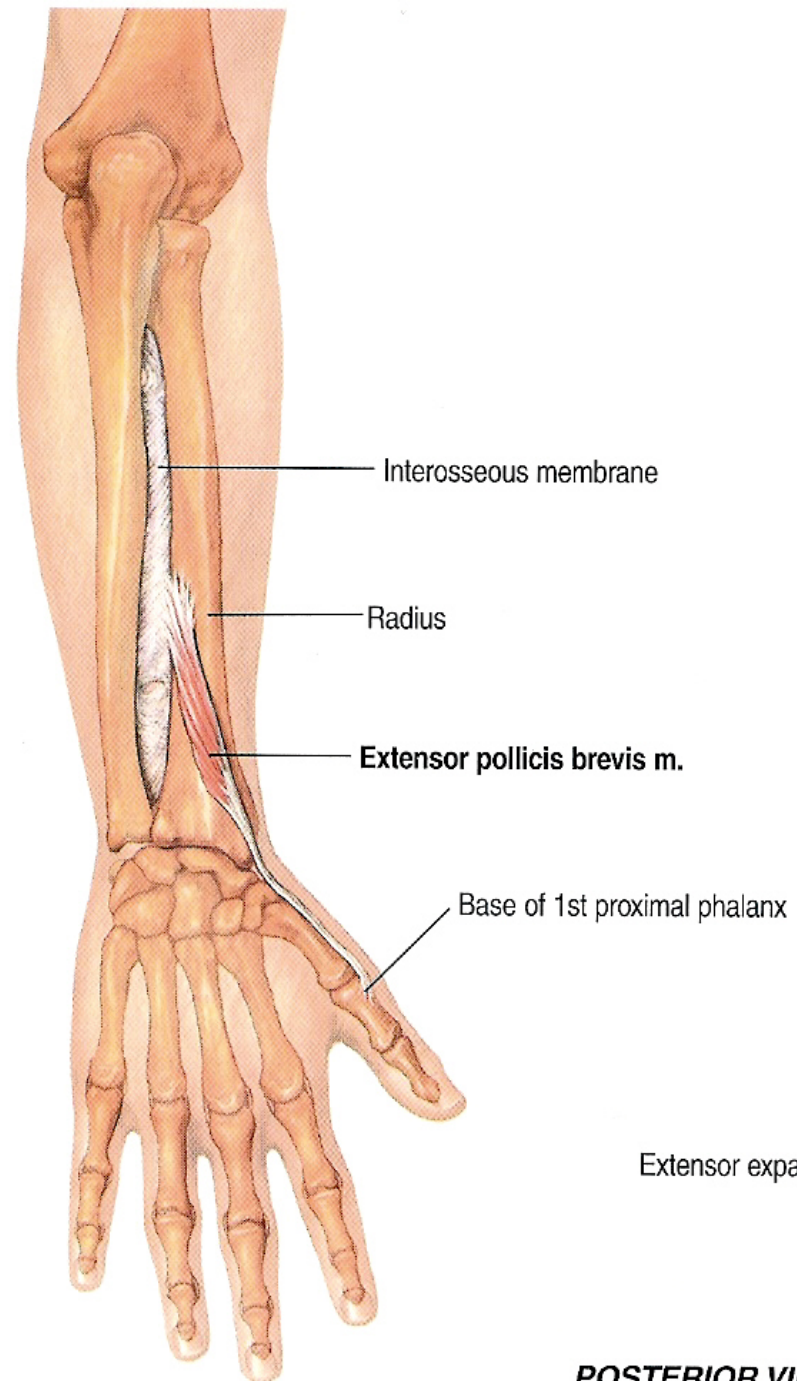
- Into the posterior surface of the base of **the 1st metacarpal bone**.

➤ Nerve Supply:

- From the deep branch of radial (posterior interosseus) nerve.

➤ Action:

- Abduction and extension of the thumb at the carpo-metacarpal joint.



Extensor pollicis brevis

➤ Origin:

- from the posterior surface of **radius** (below abductor pollicis longus) and adjoining interosseus membrane.

➤ Insertion:

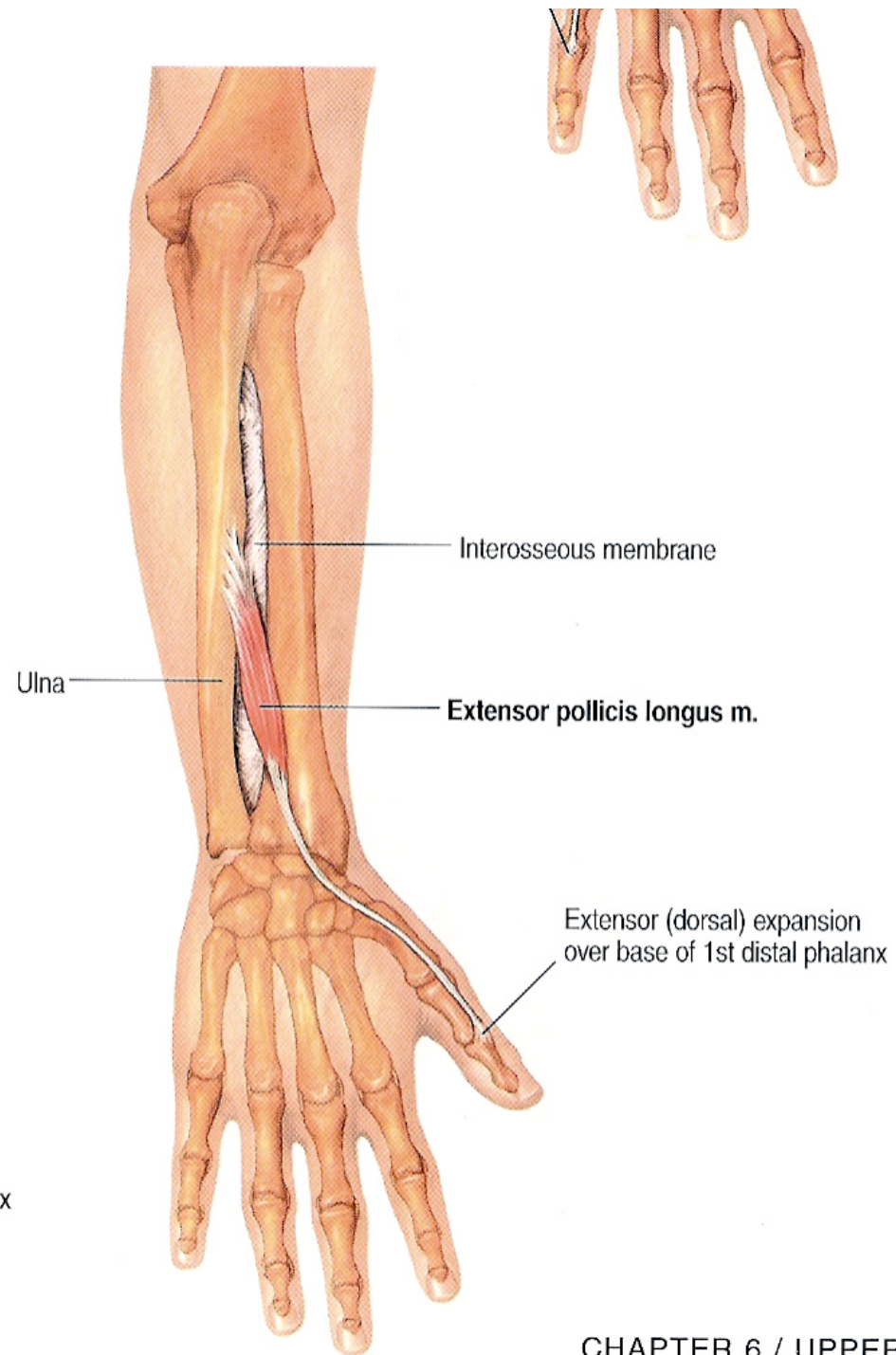
- Into the posterior surface of the base of the **proximal phalanx** of the thumb.

➤ Nerve Supply:

- From the deep branch of radial (posterior interosseus) nerve.

➤ Action:

- Extension of the metacarpophalangeal joint of the thumb.



Extensor pollicis longus

➤ Origin:

- from the posterior surface of **ulna** (below abductor pollicis longus) and adjoining interosseus membrane.

➤ Insertion:

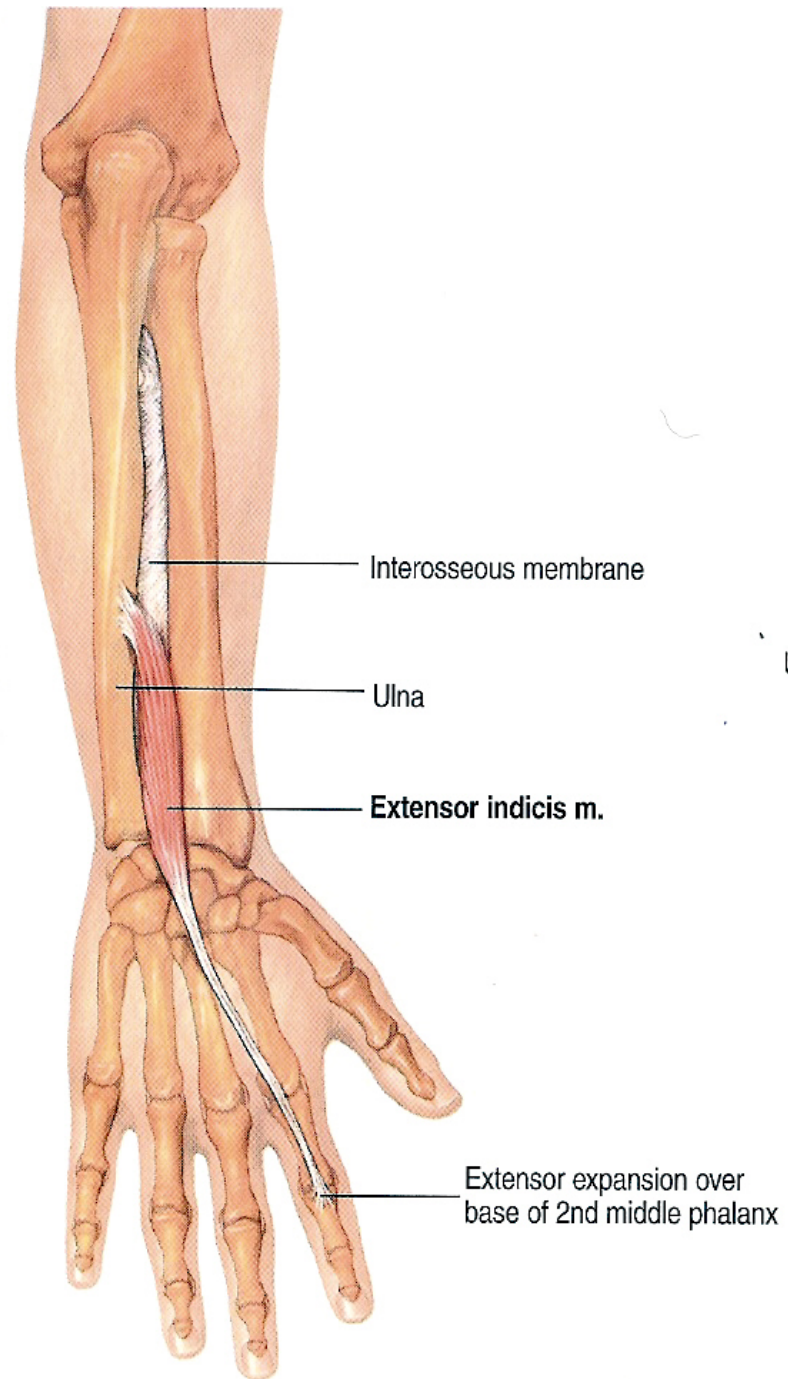
- Into the posterior surface of the base of the **distal phalanx** of the thumb.

➤ Nerve Supply:

- From the deep branch of radial (posterior interosseus) nerve.

➤ Action:

- Extension of the interphalangeal joint of the thumb.



Extensor indicis

➤ Origin:

- from the posterior surface of **ulna** (below extensor pollicis longus) and adjoining interosseus membrane.

➤ Insertion:

- Into the extensor expansion of the index finger.

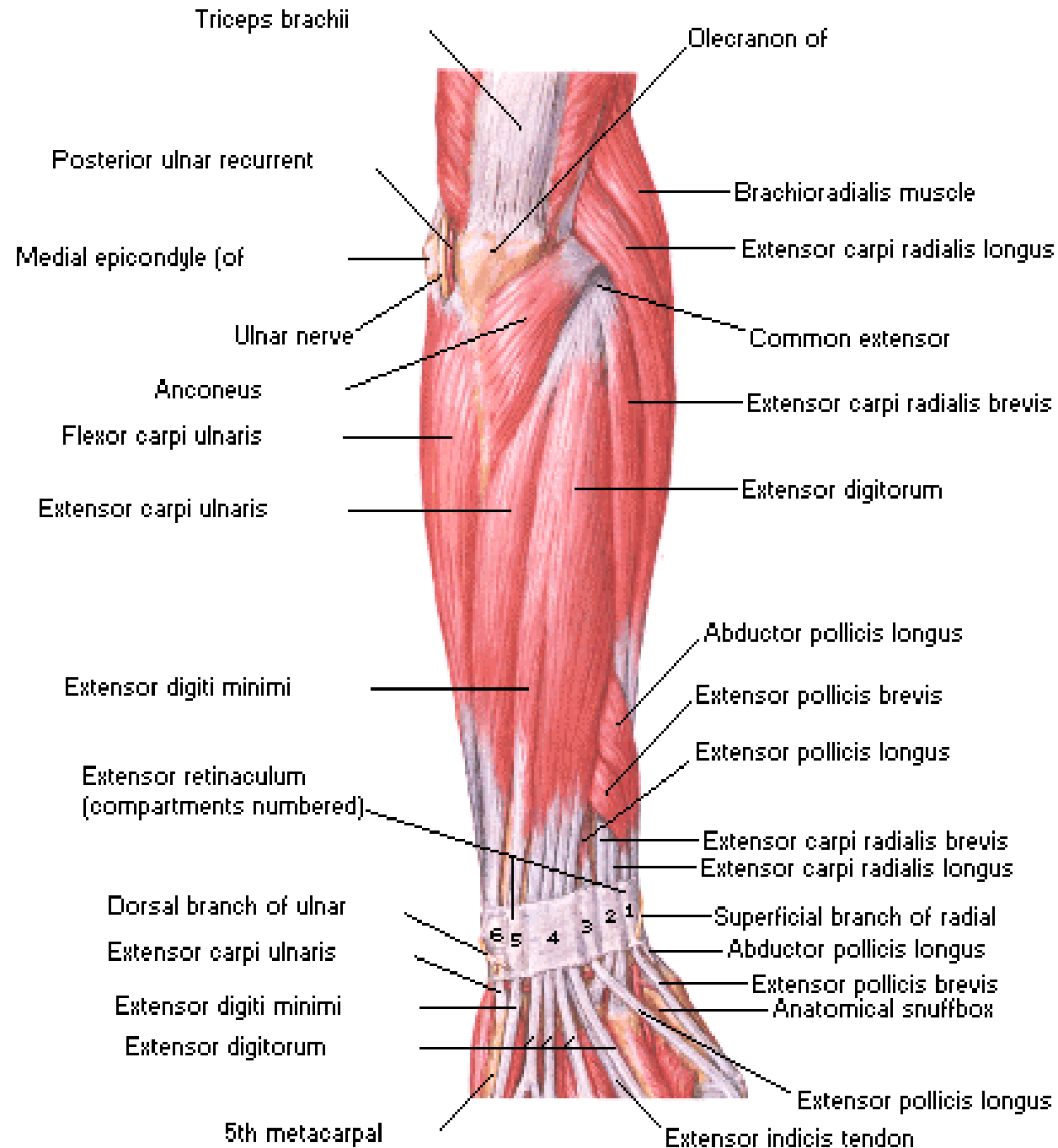
➤ Nerve Supply:

- From the deep branch of radial (posterior interosseus) nerve.

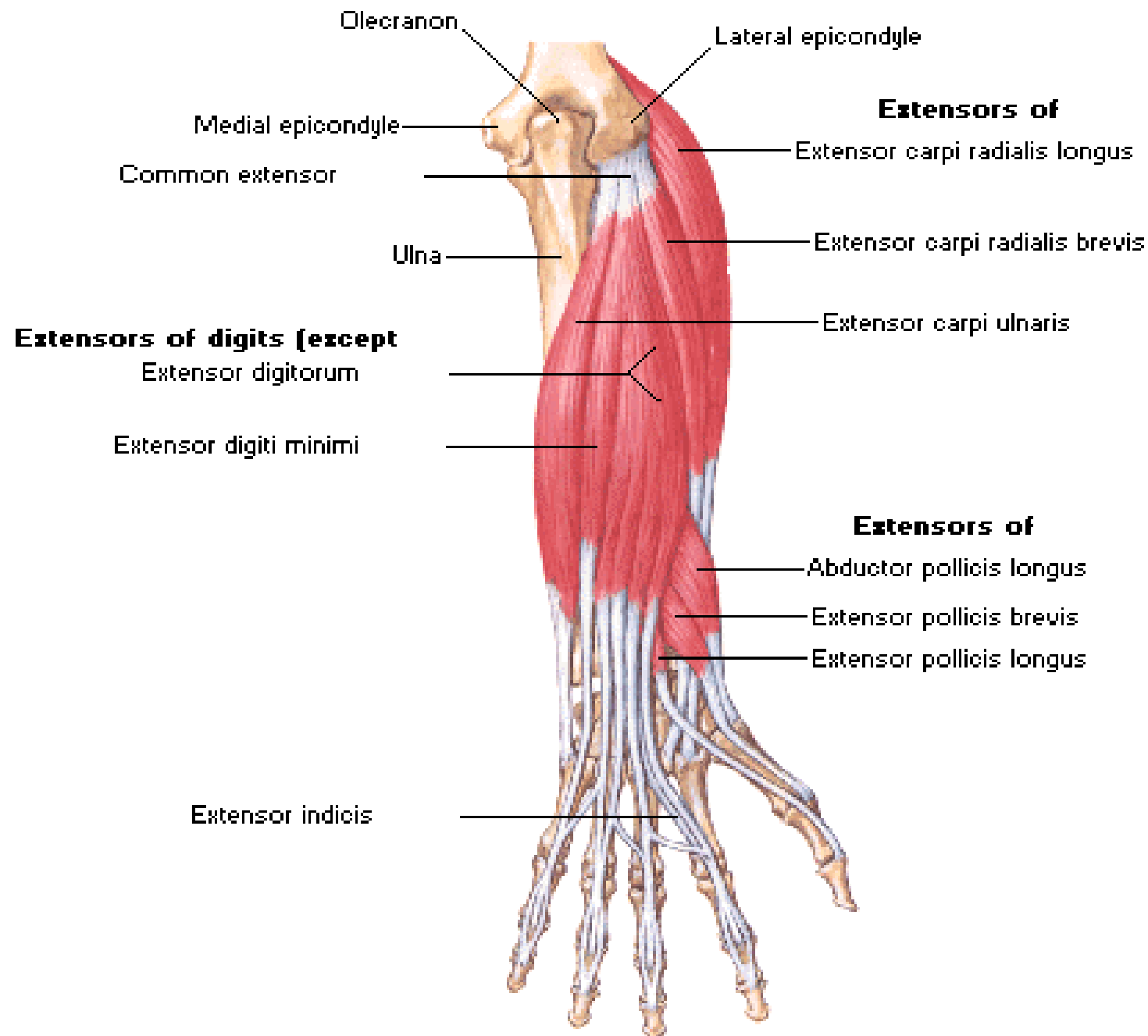
➤ Action:

- Extension of all joints of the index finger.
- It helps in extension of the wrist joint.

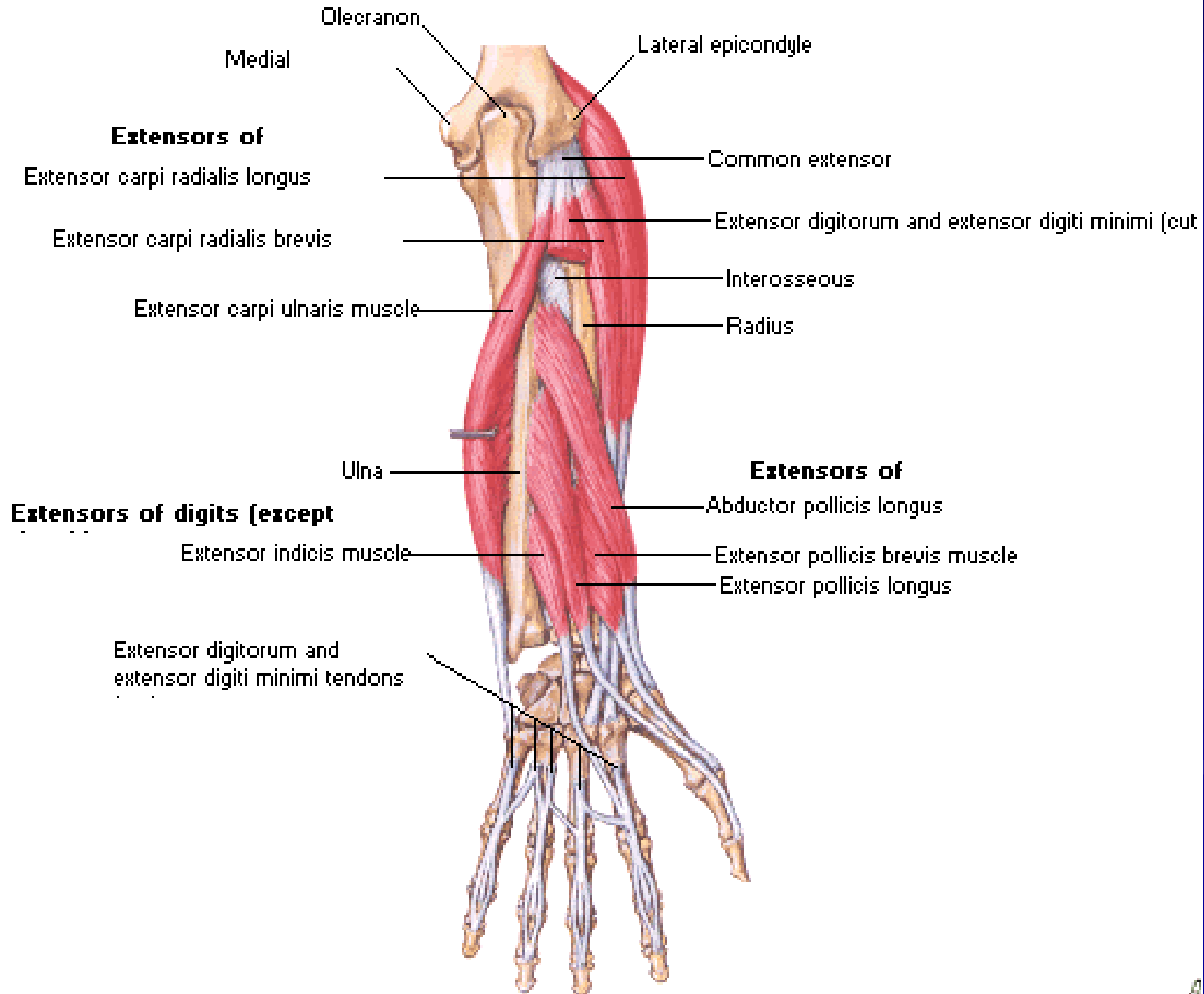
Posterior View



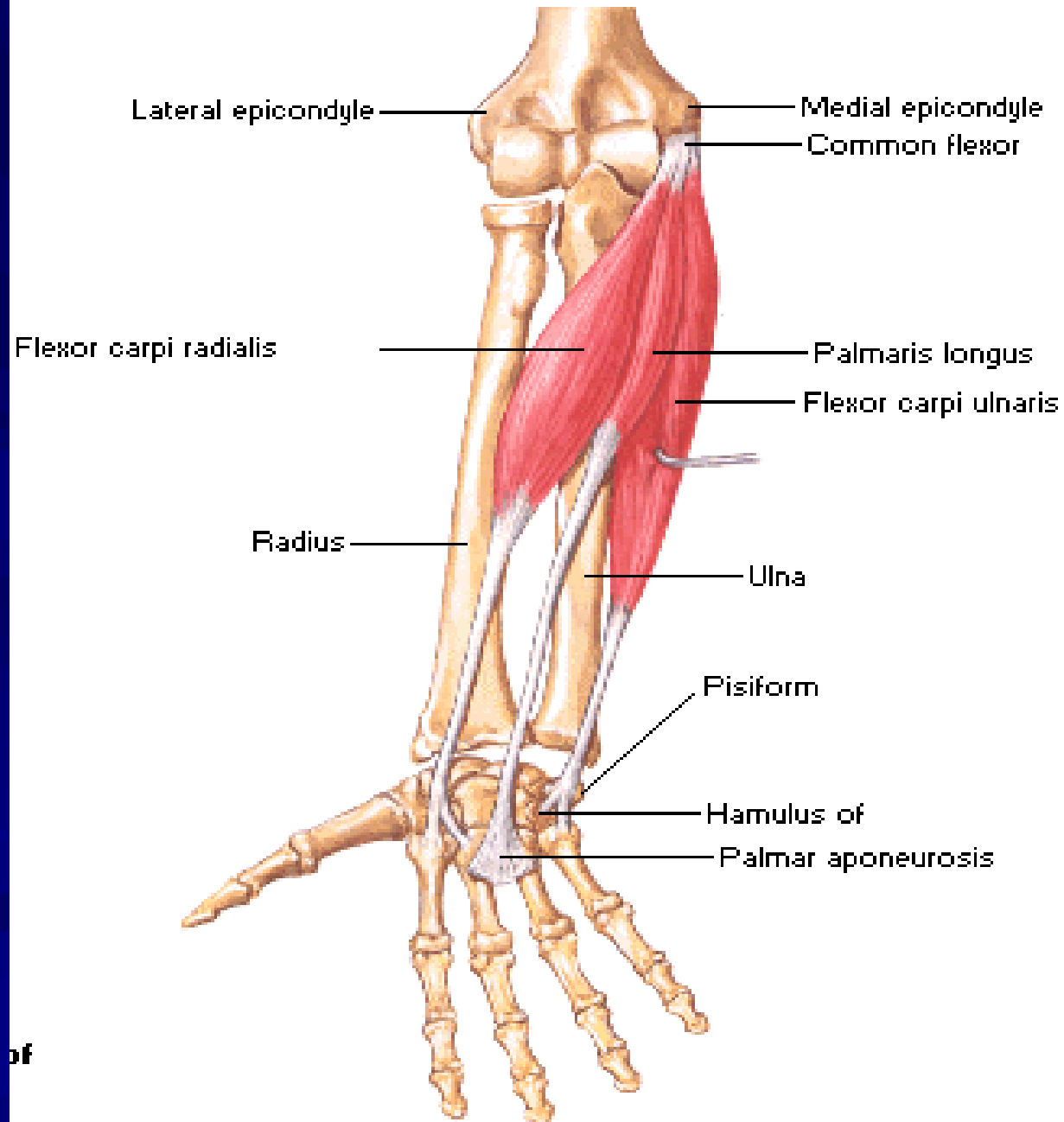
Extensors of Wrist and Digits



Extensors of Wrist and Digits



Flexors of Wrist

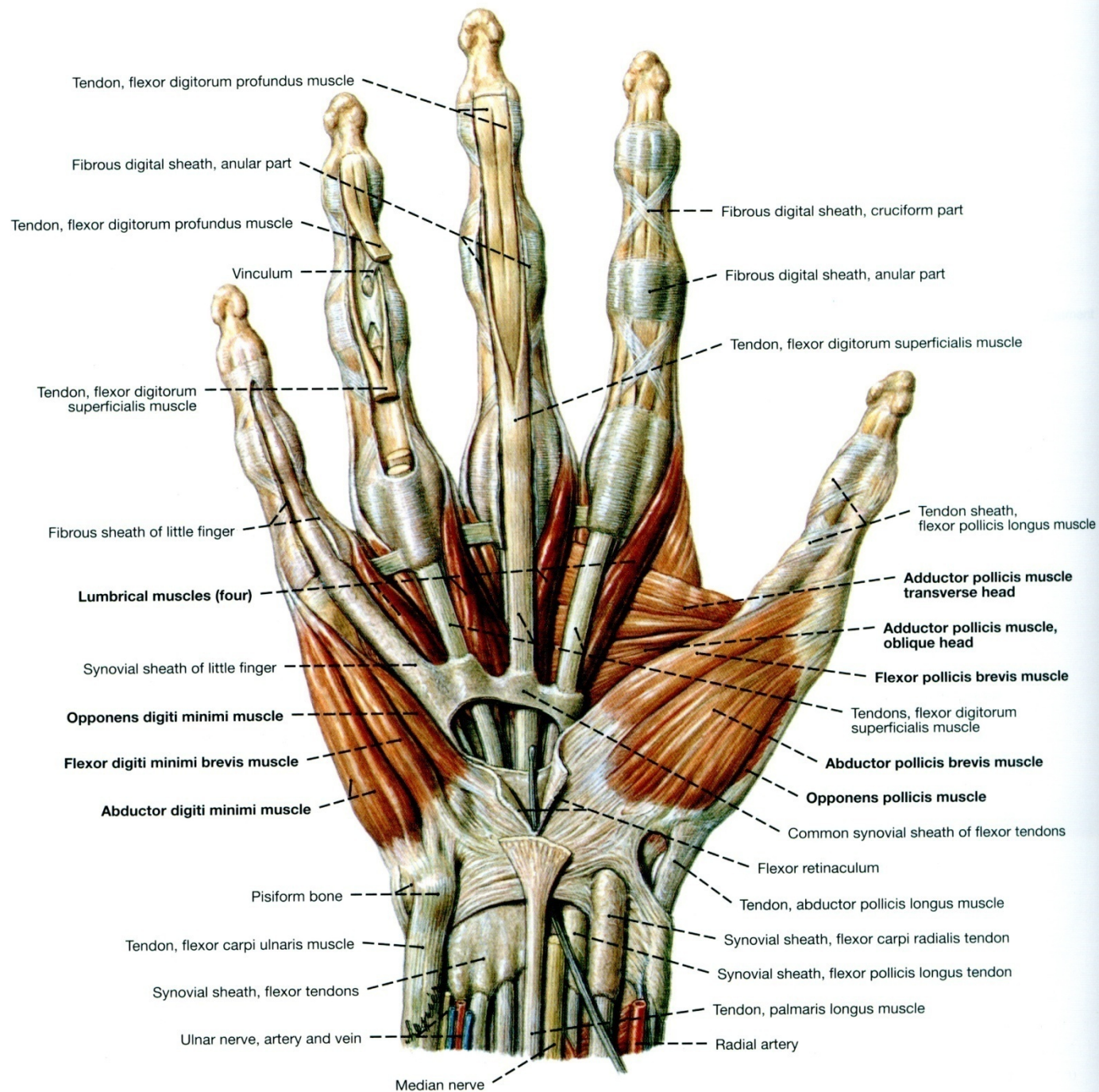


THE HAND

PALM OF THE HAND

MUSCLES OF THE HAND

www.fisiokinesiterapia.biz



Muscle of the hand

■ Thenar muscles:

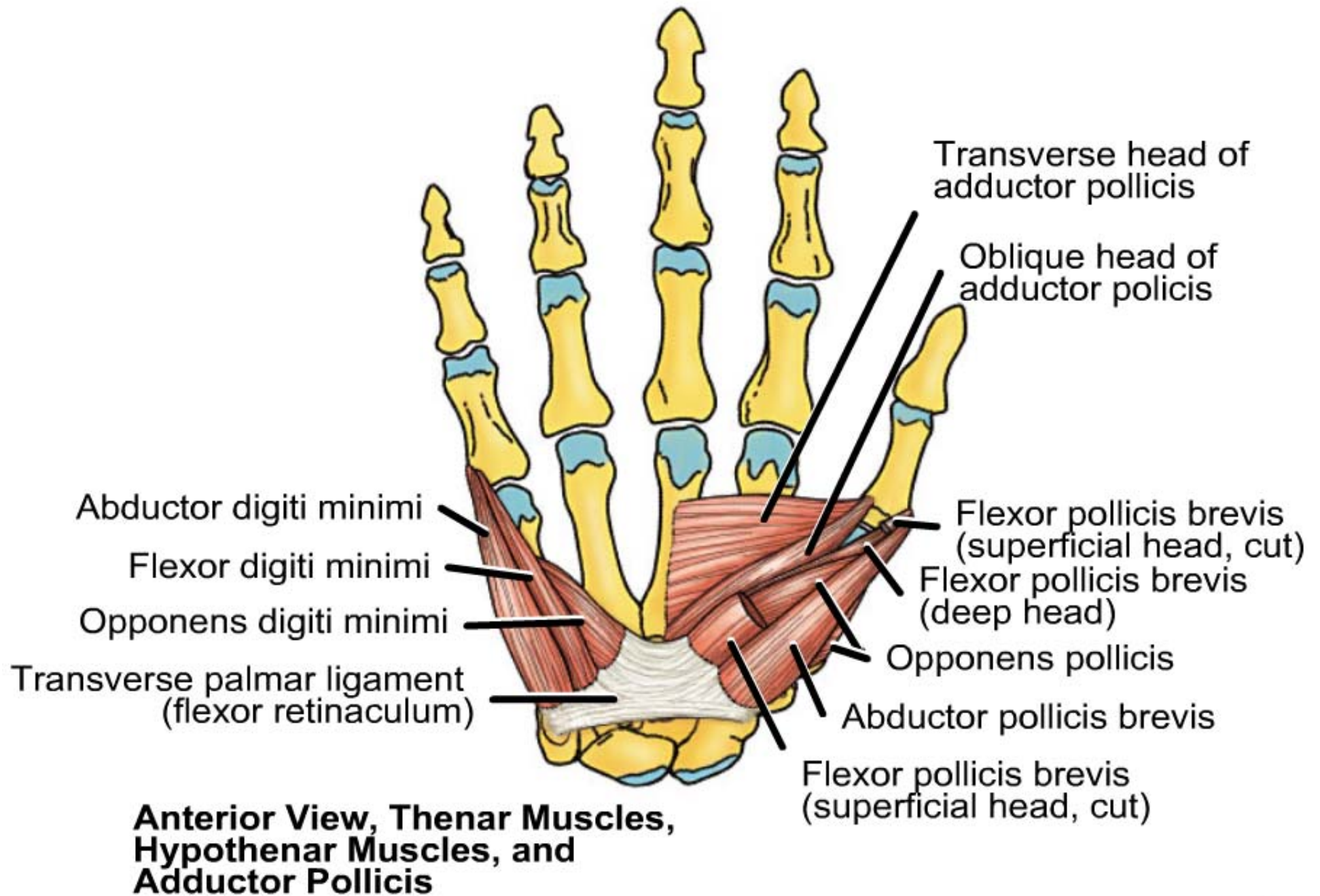
(1) Abductor pollicis brevis, (2) Flexor pollicis brevis and (3) opponens pollicis.

■ Hypothenar muscles:

(1) Abductor digiti minimi, (2) Flexor digiti minimi and (3) opponens digiti minimi.

■ Small muscles of the hand:

(1) Lumbricals, (2) interossei (palmar and dorsal), and (3) adductor pollicis.



Abductor pollicis brevis

➤ Origin:

- from the scaphoid, trapezium and flexor retinaculum.

➤ Insertion:

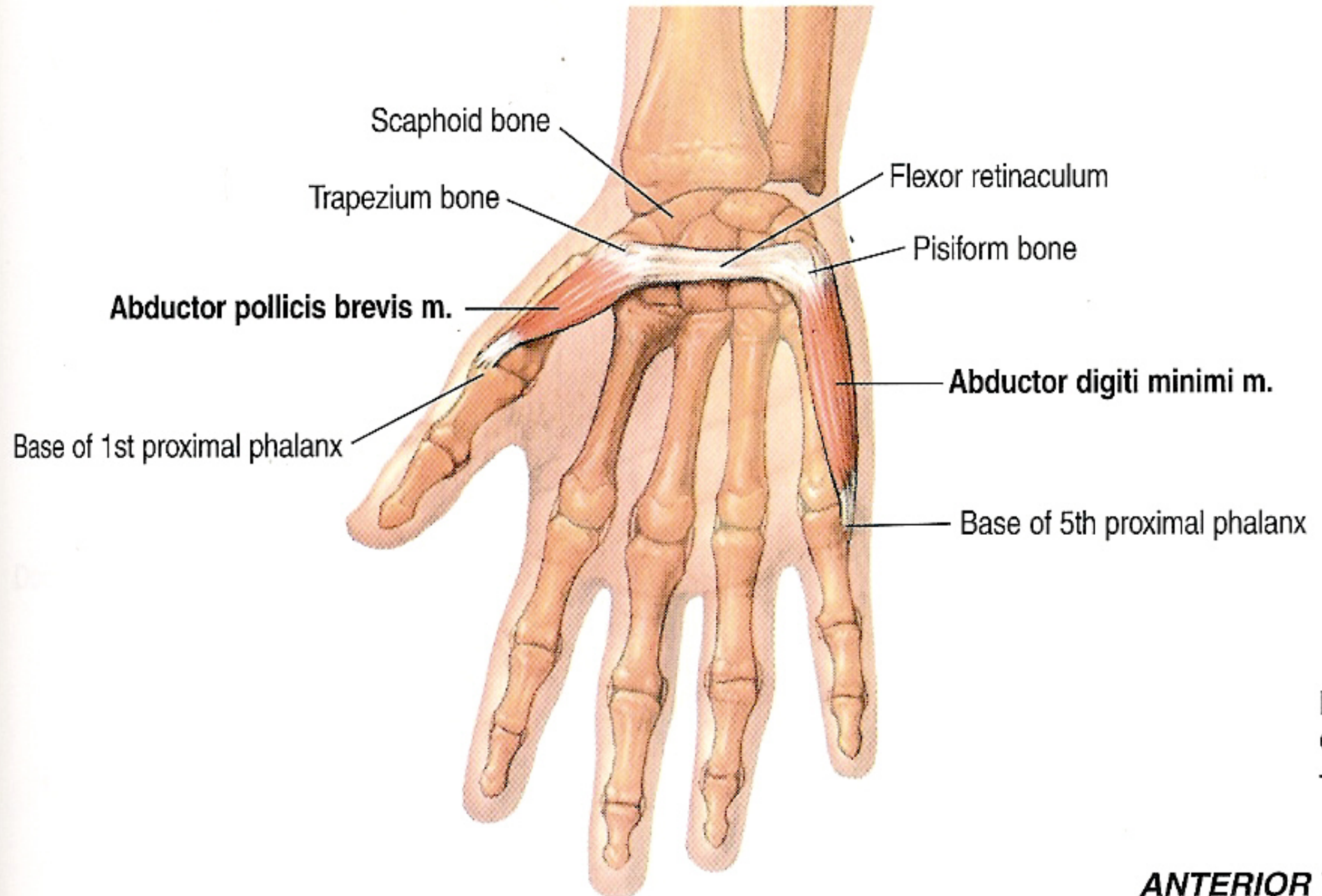
- Into the lateral aspect of the **base** of the proximal phalanx of the thumb.

➤ Nerve Supply:

- From the median nerve.

➤ Action:

- Abduction of the thumb at the carpo-metacarpal joint.



Flexor pollicis brevis

➤ Origin:

- from the flexor retinaculum.

➤ Insertion:

- Into the lateral aspect of the **base** of the proximal phalanx of the thumb.

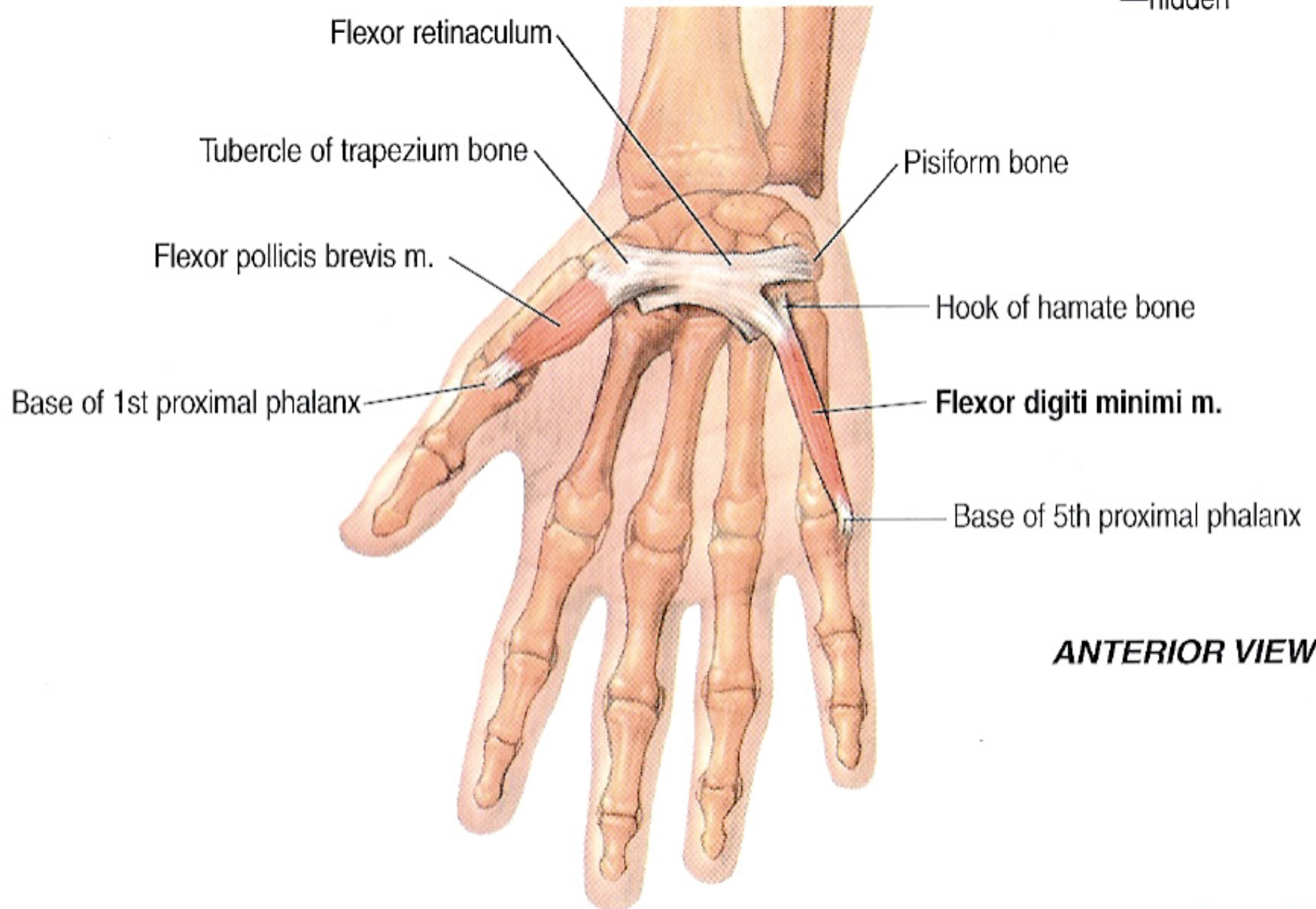
➤ Nerve Supply:

- From the median nerve.

➤ Action:

- Flexion of the thumb at the metacarpophalangeal joint.

extensor (dorsal) c
—hidden



Flexor digitor

Opponens pollicis

➤ Origin:

- from the flexor retinaculum.

➤ Insertion:

- Into the lateral border of the shaft of the 1st metacarpal bone.

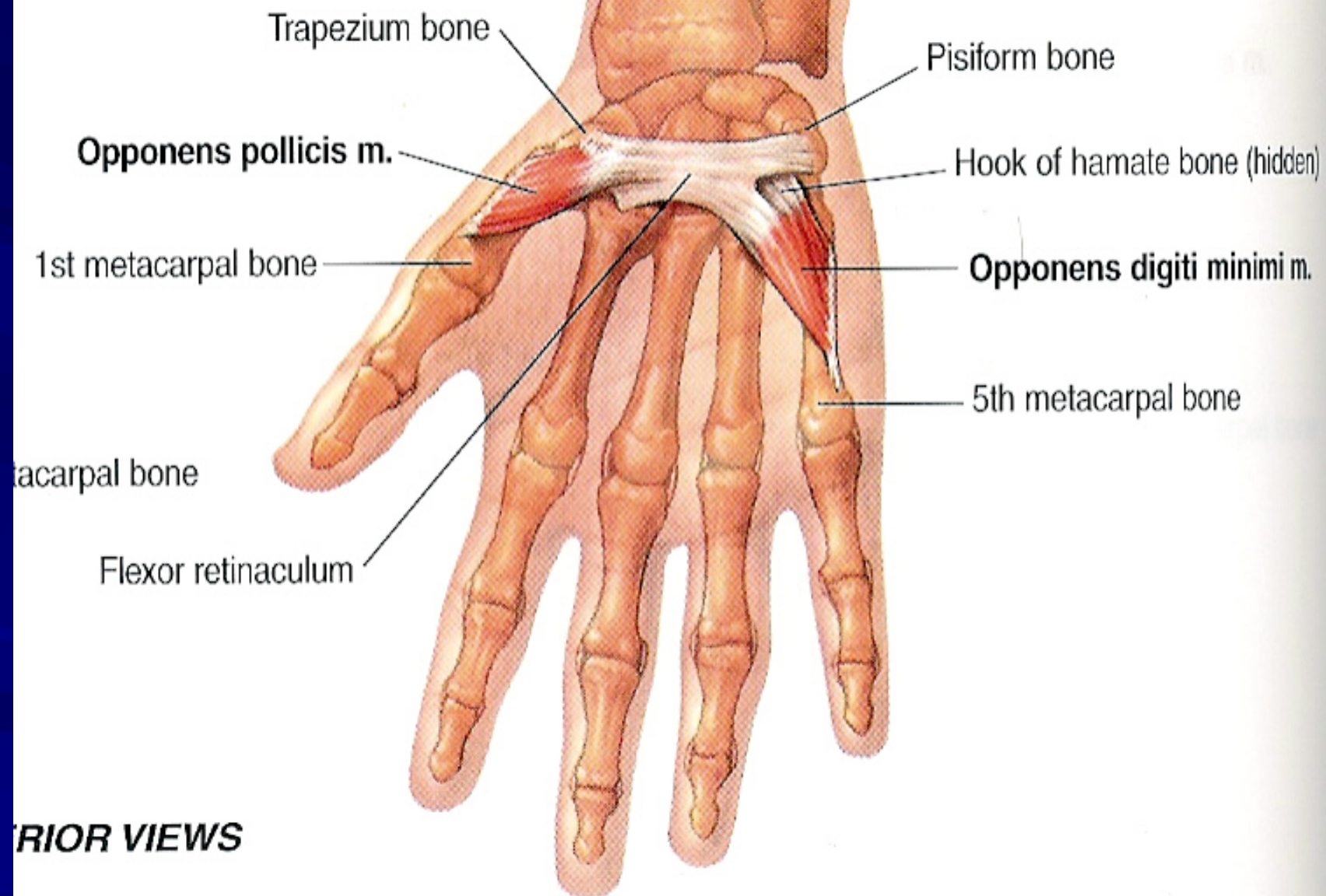
➤ Nerve Supply:

- From the median nerve.

➤ Action:

- Opposition of the thumb against other fingers.

e bone



metacarpal bone

ANTERIOR VIEWS

Abductor digiti minimi

➤ Origin:

- from the pisiform and flexor retinaculum.

➤ Insertion:

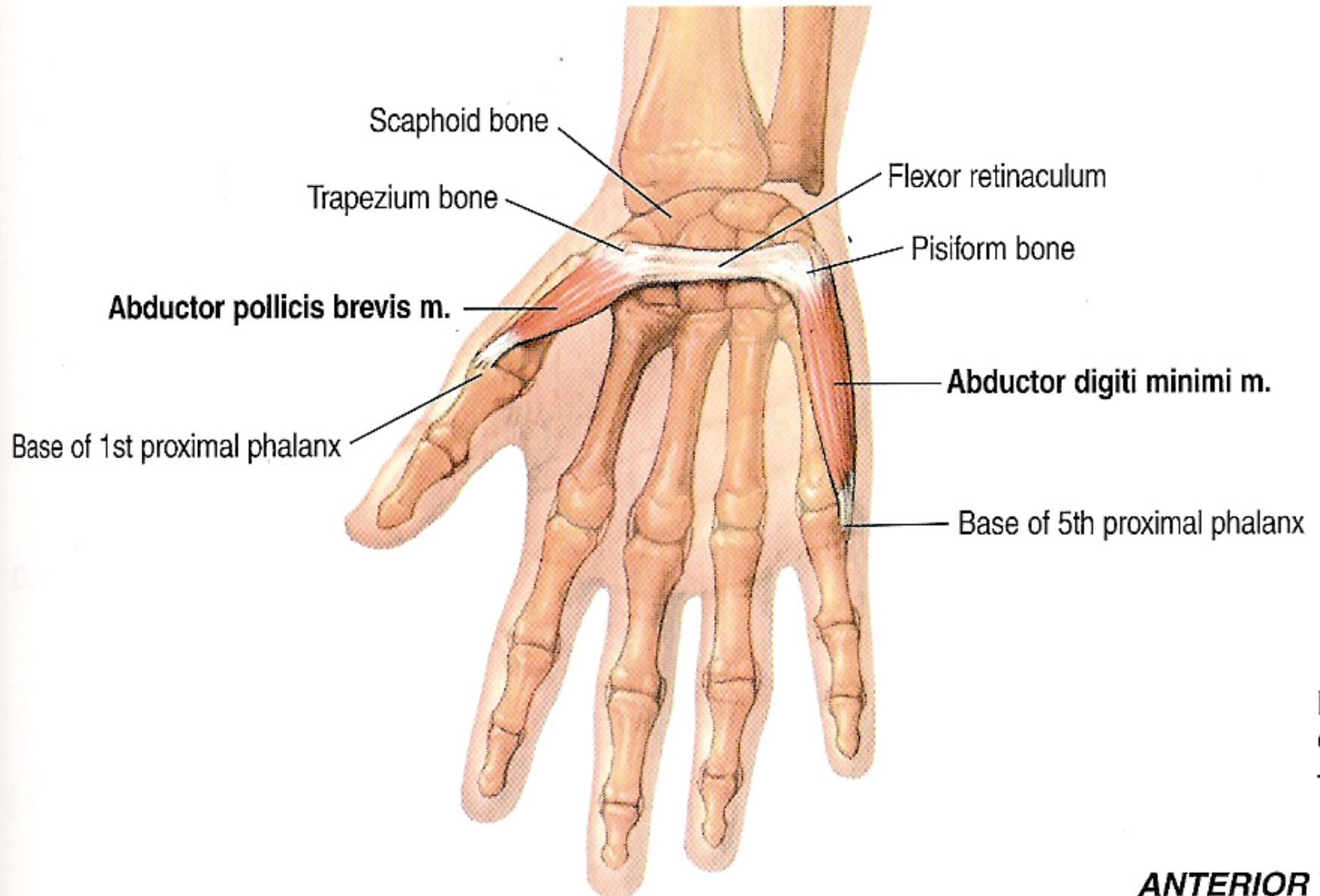
- Into the medial aspect of the **base** of the proximal phalanx of the little finger.

➤ Nerve Supply:

- From the deep branch of ulnar nerve.

➤ Action:

- Abduction of the little finger at the metacarpophalangeal joint.



Flexor digiti minimi

➤ Origin:

- from the flexor retinaculum.

➤ Insertion:

- Into the medial aspect of the **base** of the proximal phalanx of the little finger.

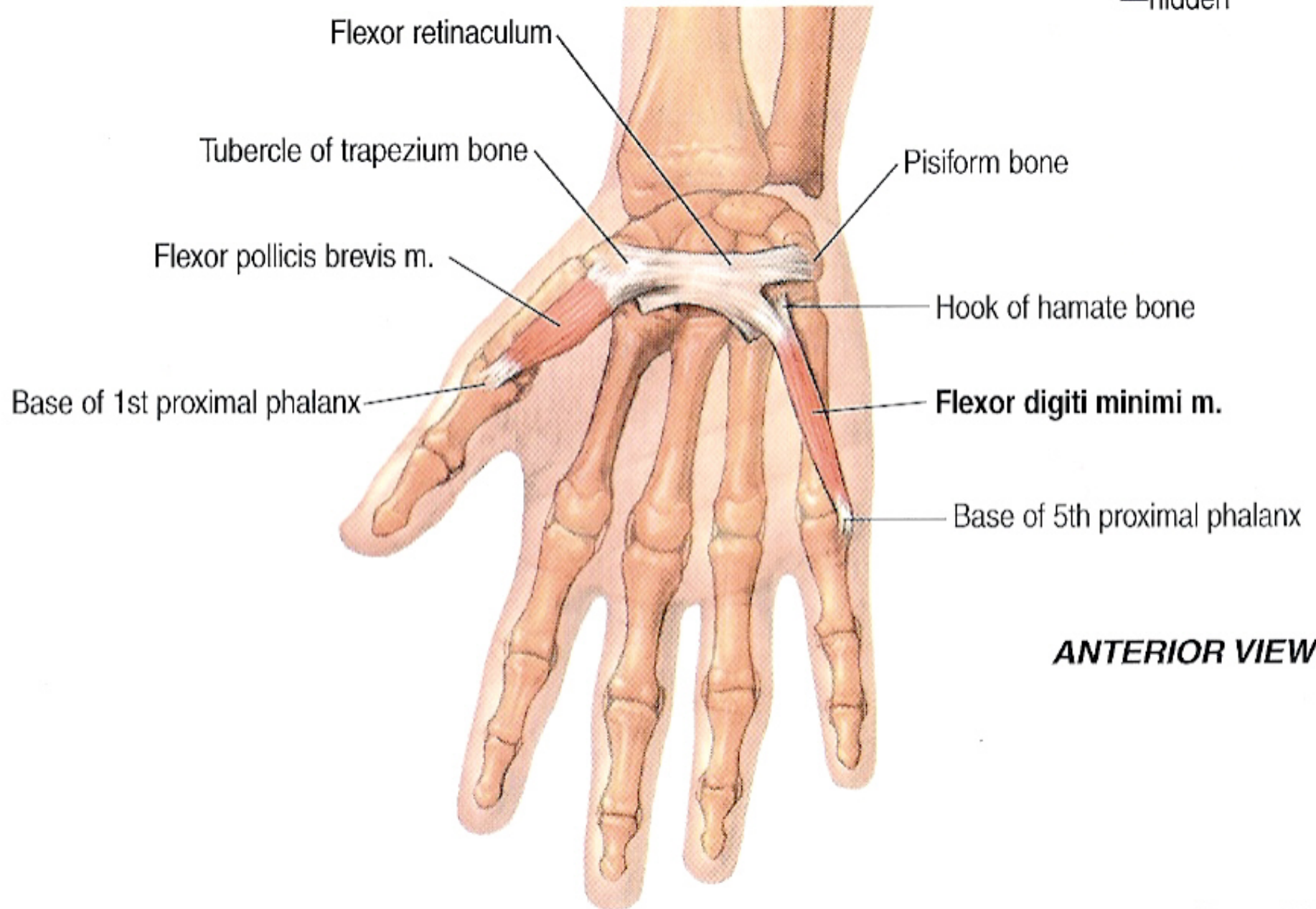
➤ Nerve Supply:

- From the deep branch of ulnar nerve.

➤ Action:

- Flexion of the little finger at the metacarpophalangeal joint.

extensor (dorsal) c
—hidden



Flexor digitor

Opponens digiti minimi

➤ Origin:

- from the flexor retinaculum.

➤ Insertion:

- Into the medial border of the shaft of the 5th metacarpal bone.

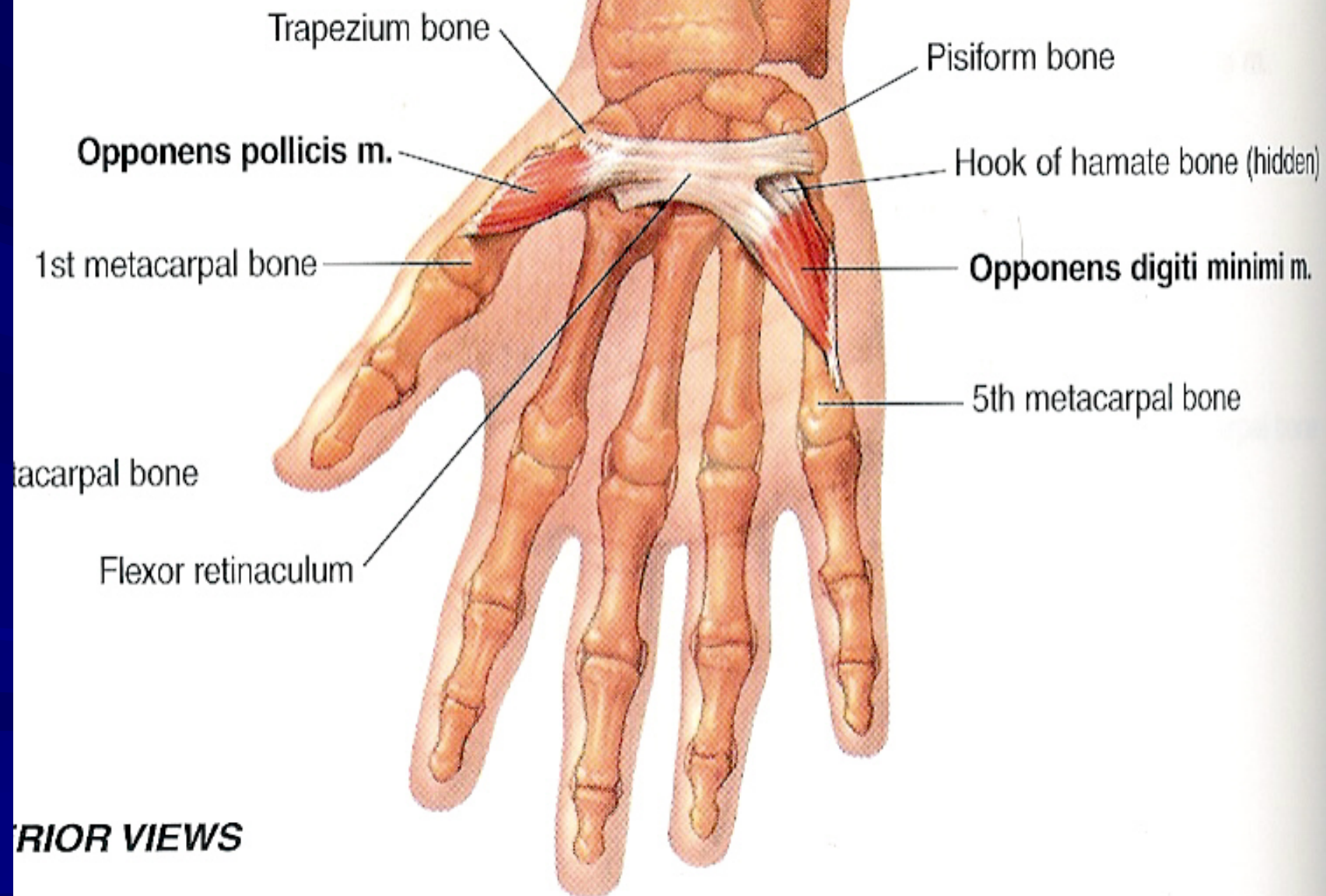
➤ Nerve Supply:

- From the deep branch of ulnar nerve.

➤ Action:

- Opposition of the little finger against the thumb.

bone



RIOR VIEWS

4 Lumbricals

➤ Origin:

- **1st and 2nd** from the lateral side of the tendon of index and middle fingers of the flexor digitorum profundus.
- **3rd and 4th** from the adjacent sides of the tendon of middle, ring and little fingers of the flexor digitorum profundus.

➤ Insertion:

- Into the extensor expansions of the fingers.

➤ Nerve Supply:

- 1st and 2nd (lateral two) from the median nerve.
- 3rd and 4th (medial two) from the deep branch of ulnar nerve.

➤ Action:

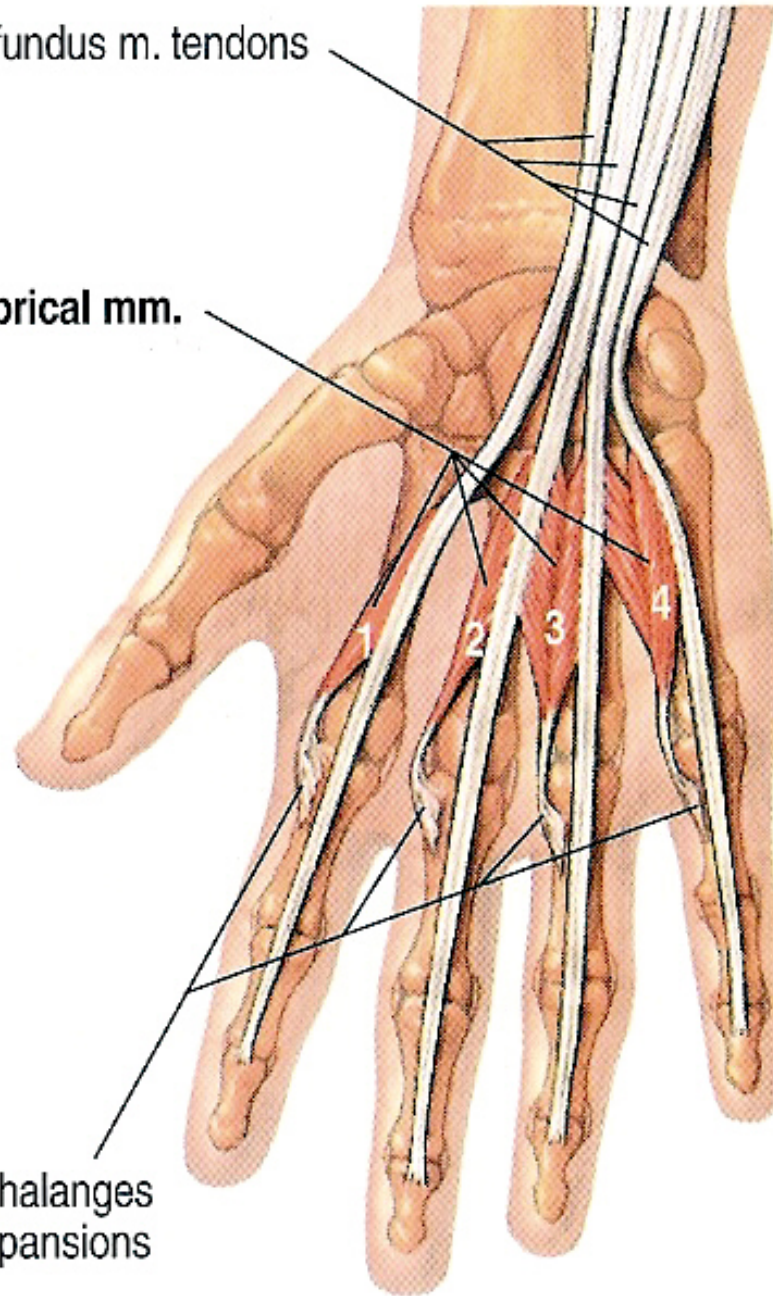
- Flexion of the metacarpophalangeal joints.
- Extension of the interphalangeal joints.

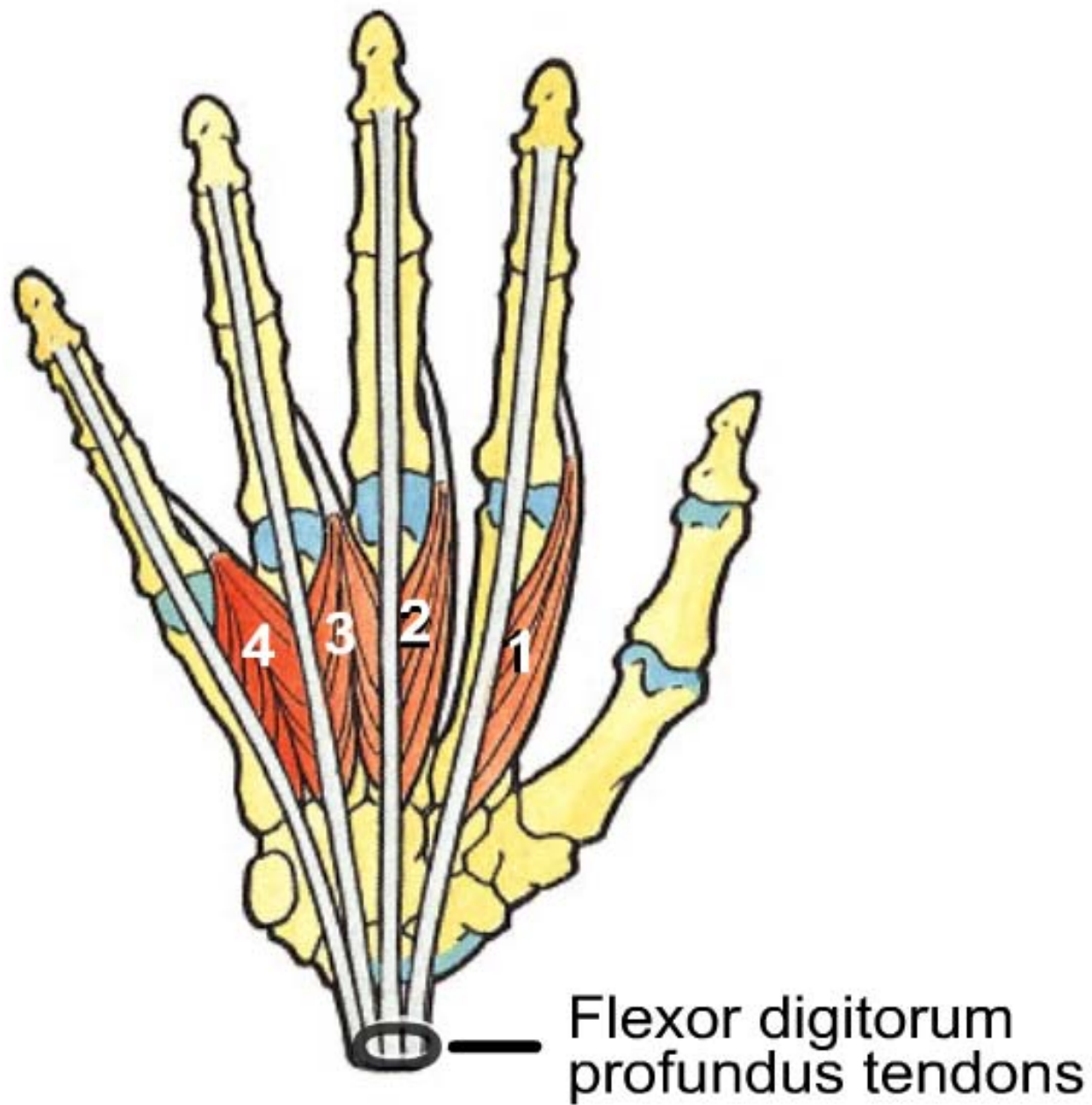
Flexor digitorum profundus m. tendons

Lumbrical mm.

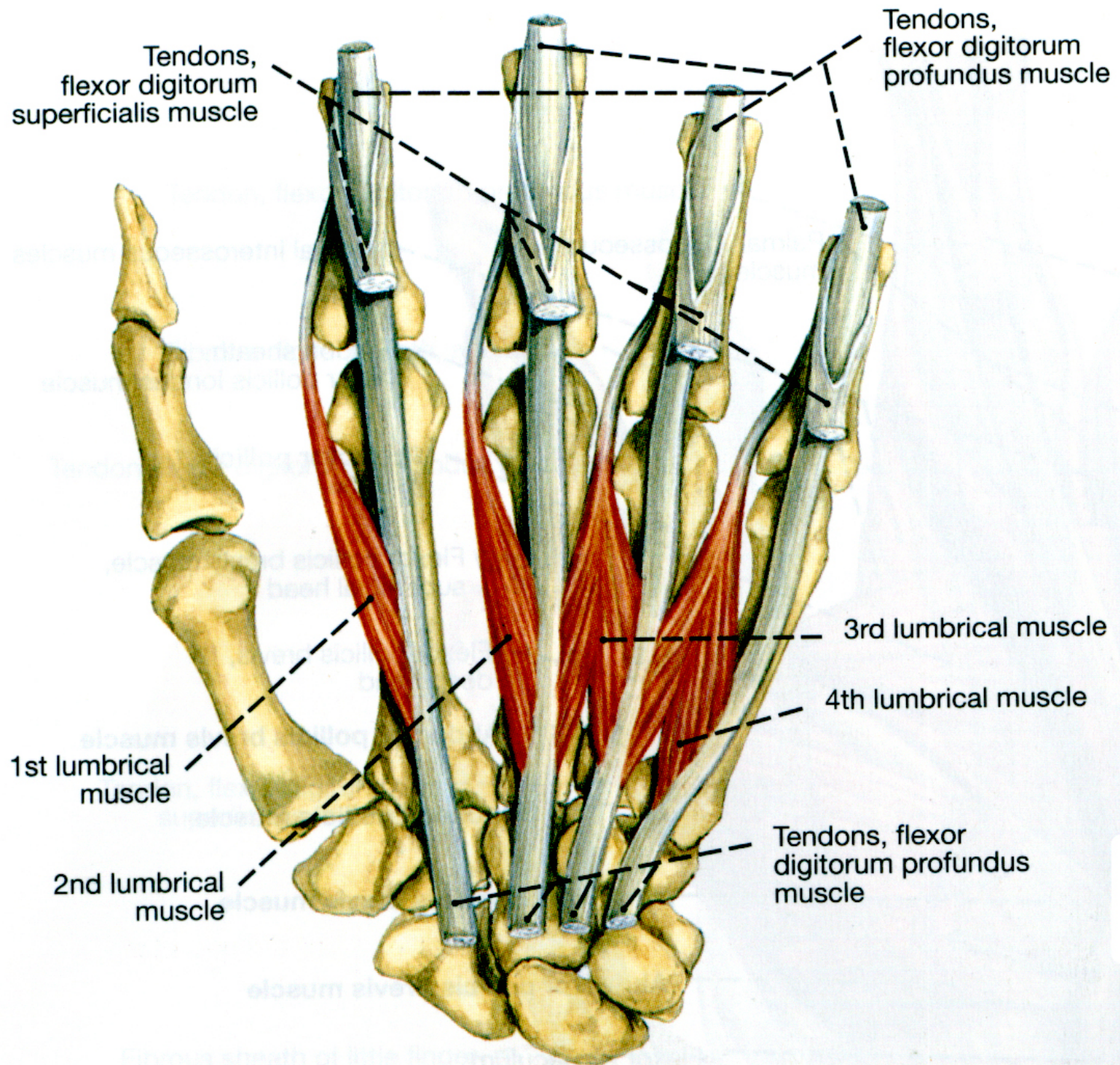
x

Bases of proximal phalanges
extensor (dorsal) expansions
—hidden





Anterior View, Lumbricals (1-4)



3 Palmar interossei



Origin:

- **1st** from the medial side of the metacarpal bone of index finger.
- **2nd and 3rd** from the lateral side of the metacarpal bones of the ring and little fingers.



Insertion:

- **1st** into the medial side of the base of the proximal phalanx of the index finger.
- **2nd and 3rd** into the lateral side of the base of the proximal phalanges of the ring and little fingers.
- They also are inserted into the extensor expansions of the index, ring and little fingers.



Nerve Supply:

- From the deep branch of ulnar nerve.



Action:

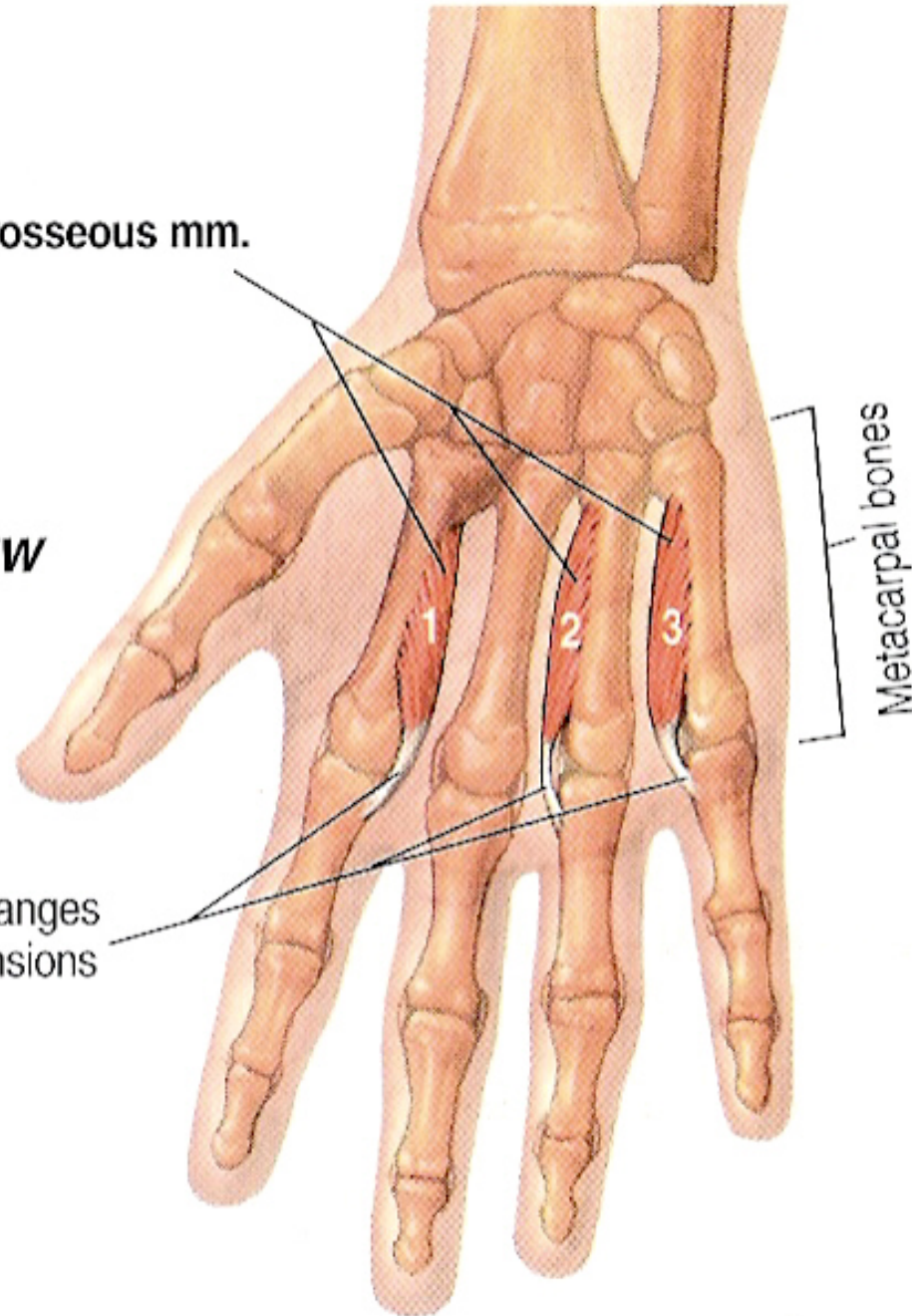
1. Adduction of the index, ring and little fingers.
2. Flexion of their metacarpophalangeal joints.
3. Extension of their interphalangeal joints.

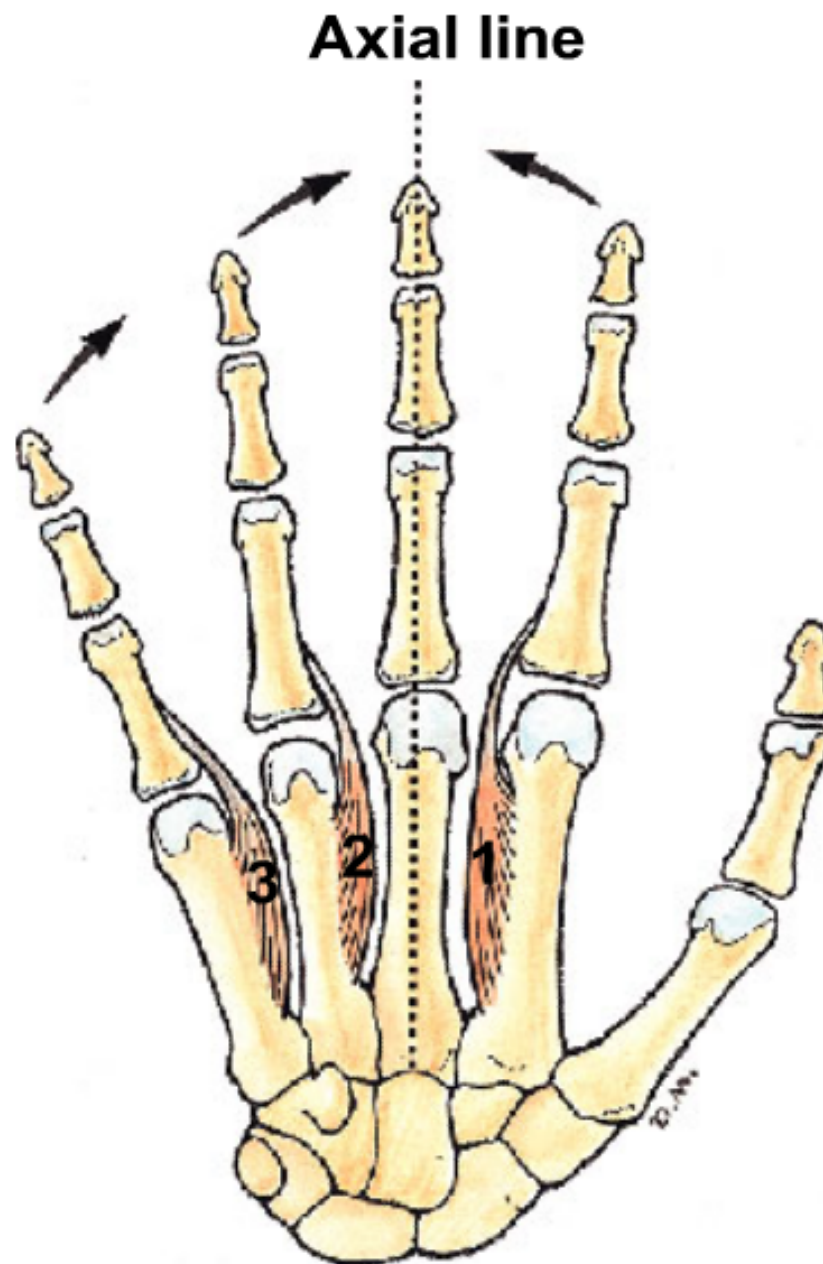
ANTERIOR VIEW

Palmar interosseous mm.

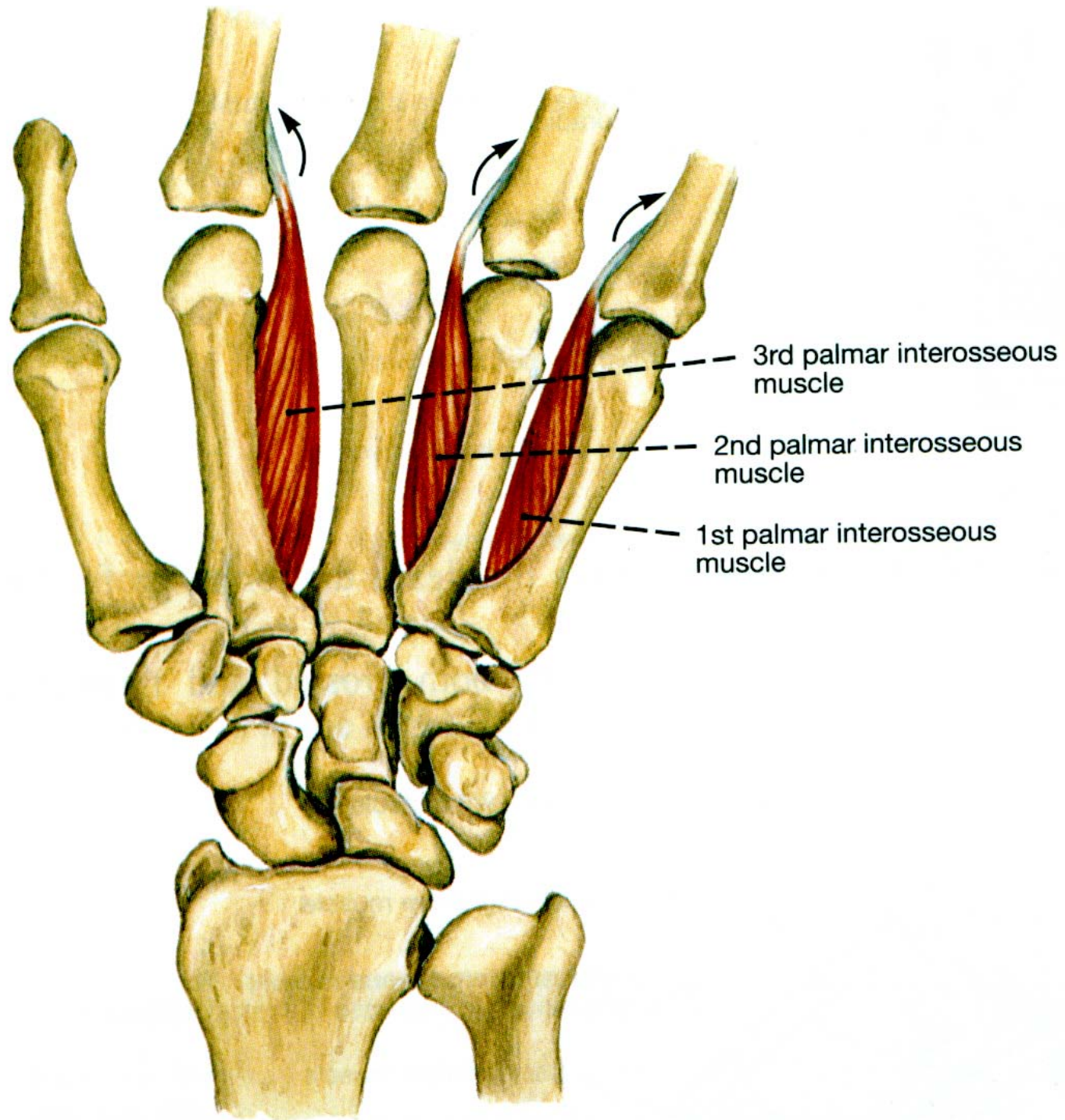
Metacarpal bones

Bases of proximal phalanges
extensor (dorsal) expansions
—hidden





**Anterior View, Palmar
Interossei (Adduction)**



4 Dorsal interossei

➤ Origin:

- From the adjacent sides of the metacarpal bones.

➤ Insertion:

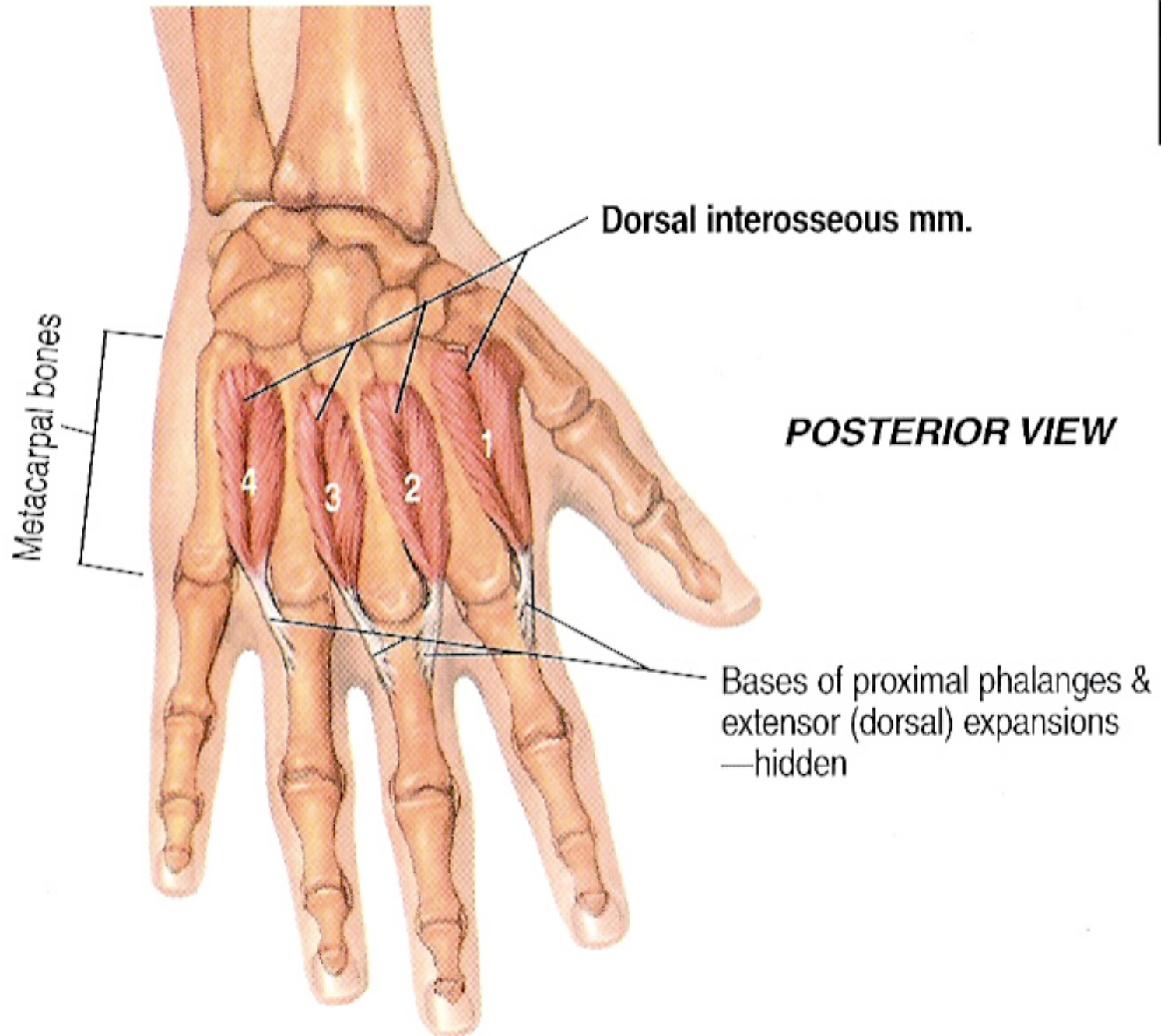
- **1st and 2nd** into the lateral sides of the bases of the proximal phalanx of the index and middle fingers.
- **3rd and 4th** into the medial sides of the bases of the proximal phalanges of the middle and ring fingers.
- They also are inserted into the extensor expansions of the index, ring and little fingers.

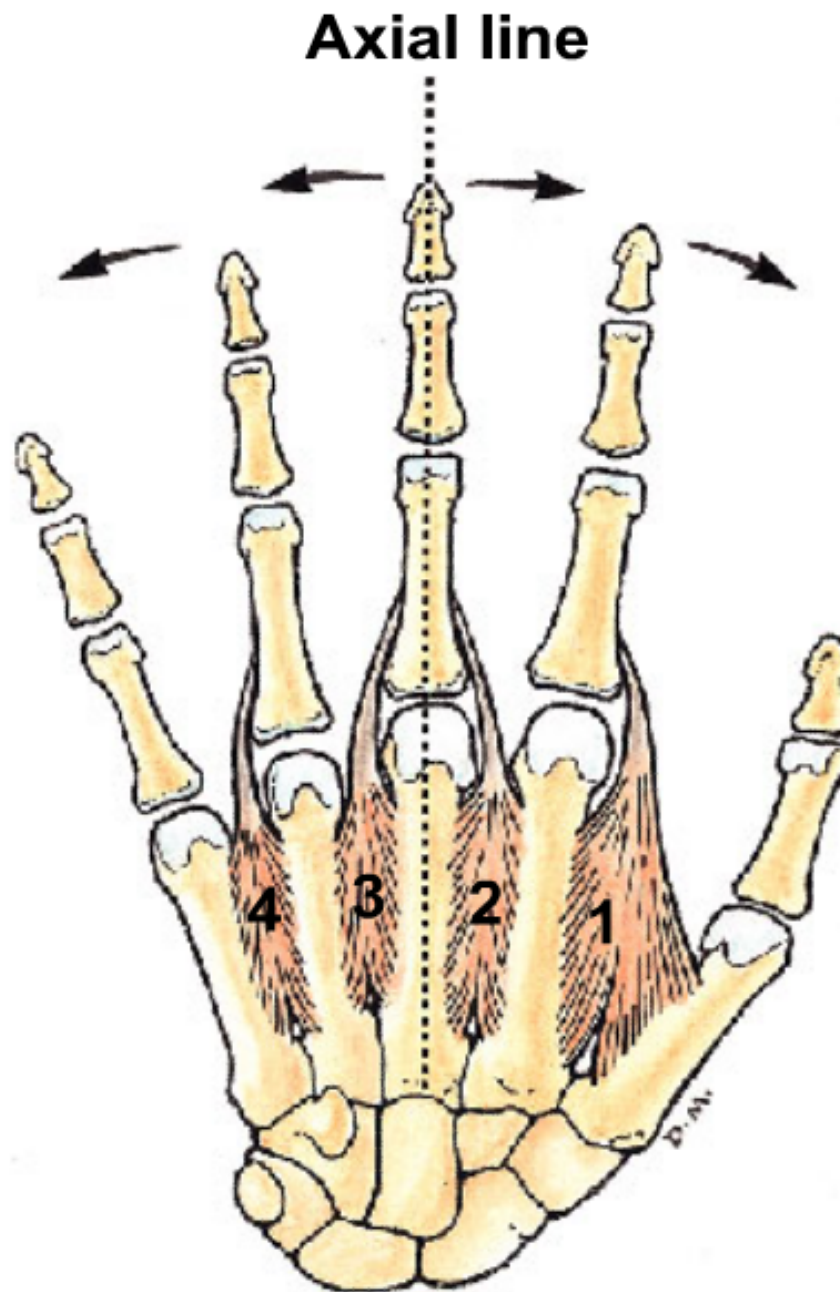
➤ Nerve Supply:

- From the deep branch of ulnar nerve.

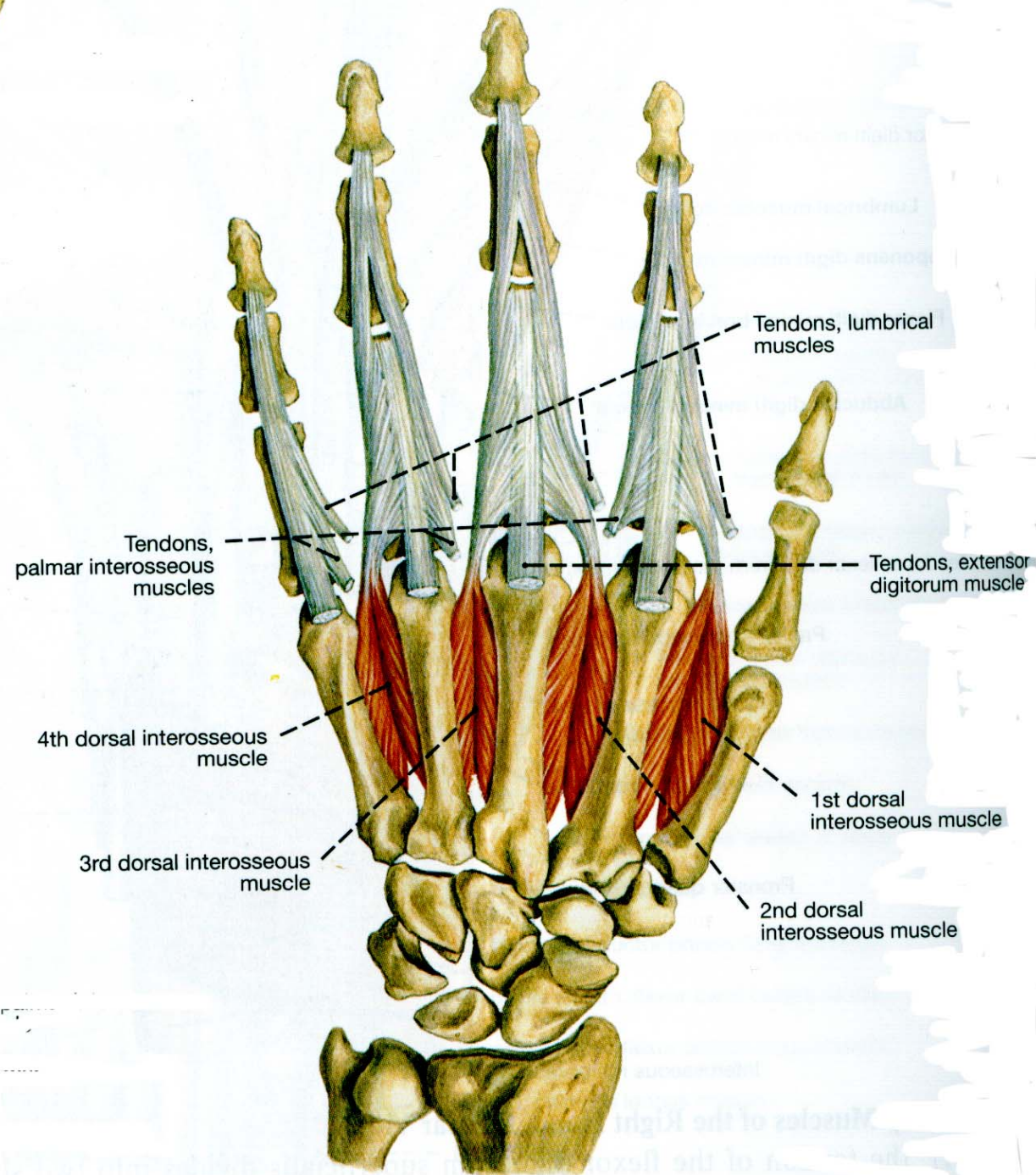
➤ Action:

1. Abduction of the index, middle and ring fingers.
2. Flexion of their metacarpophalangeal joints.
3. Extension of their interphalangeal joints.





**Anterior View, Dorsal
Interossei (Abduction)**



Adductor pollicis

➤ Origin:

- **Oblique head** from the bases of the 2nd and 3rd metacarpal bones and the adjoining carpal bones.
- **Transverse head** from the anterior surface of the shaft of the 3rd metacarpal bone.

➤ Insertion:

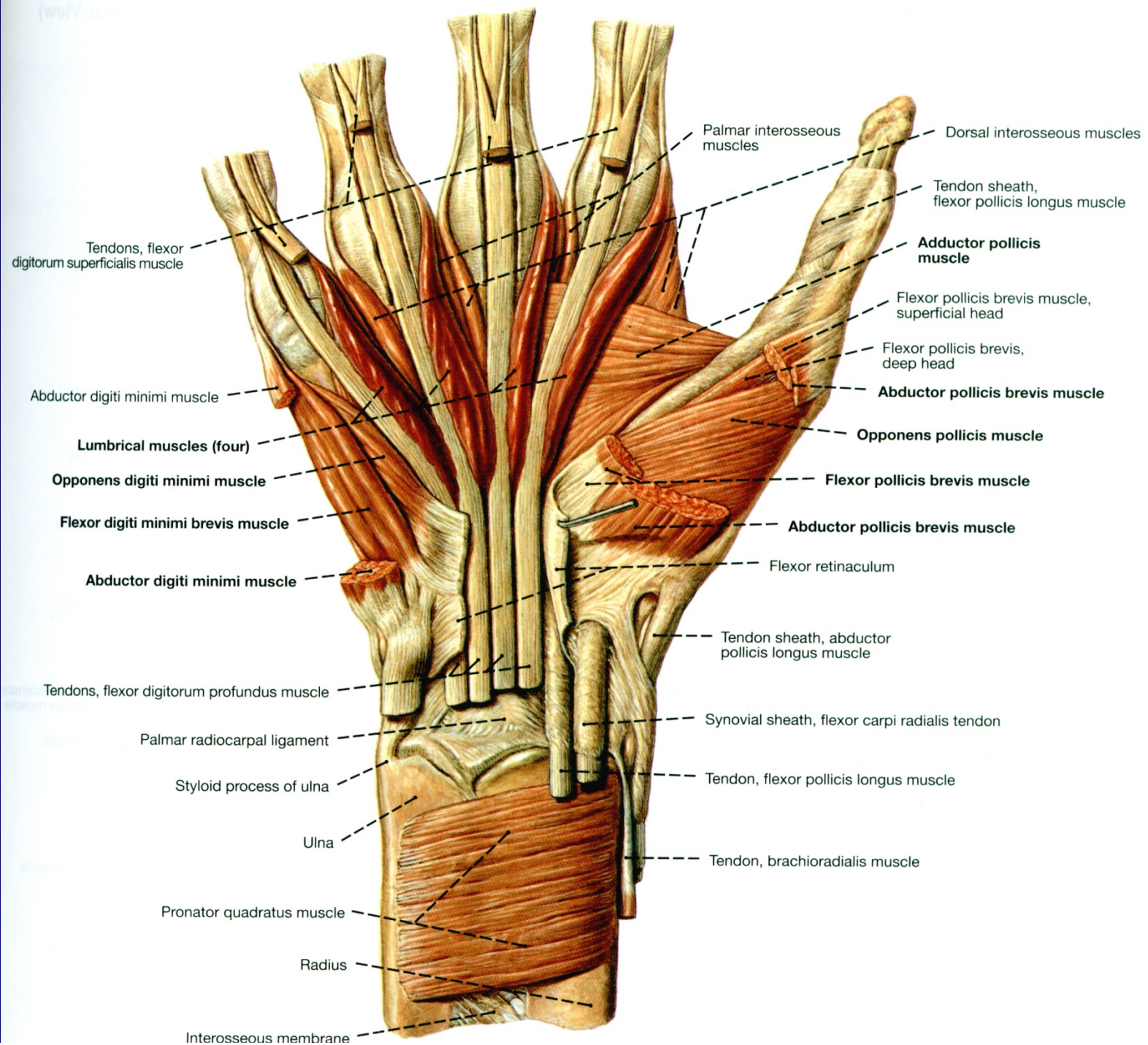
- Into the medial side of the base of the proximal phalanx of the thumb.

➤ Nerve Supply:

- From the deep branch of ulnar nerve.

➤ Action:

- Adduction of the thumb at the carpometacarpal joint.



Muscles of the Shoulder, Thorax and Abdominal Wall

	Muscle	Action	Nerve supply
Pectoral muscles	<i>Pectoralis major</i>	Flexes, adducts & rotates arm	Medial & lateral pectoral nerves
	<i>Pectoralis minor</i>	Protract shoulder	
	<i>Serratus anterior</i>	Stabilizes scapula, elevates ribs	Long thoracic nerve
Shoulder muscles	<i>Deltoid</i>	Abducts, flexes, extends & rotates arm	Axillary nerve
Back muscles	<i>Trapezius</i>	Elevates & rotates scapula	Spinal part of accessory nerve
	<i>Latissimus dorsi</i>	Adducts & rotates arm	Nerve to latissimus dorsi
Abdominal muscles	<i>Rectus abdominis</i> <i>External oblique</i> <i>Internal oblique</i> <i>Transversus abdominis</i>	Protect intra-abdominal viscera Flex & rotate the trunk Compress abdomen	Lower 5 intercostal & subcostal nerves
Diaphragm	The diaphragm is a dome-shaped, musculotendinous partition separating the thoracic and abdominal cavities. It has peripheral origin from the margins of the thoracic outlet and a central tendon. It is the chief muscle of inspiration.		Phrenic nerve

Muscles of the upper limb

	Muscle	Action	Nerve supply
Front of arm	<i>Coracobrachialis</i>	flexes & adducts the arm	Musculo-cutaneous nerve
	<i>Biceps brachii</i>	supinates & flexes the forearm	
	<i>Brachialis</i>	flexes the forearm	
Back of arm	<i>Triceps brachii</i>	extends forearm	Radial nerve
Front of forearm	<i>Pronator teres</i> <i>Pronator quadratus</i>	pronate forearm	Median & ulnar nerves
	<i>Flexor carpi radialis</i> <i>Flexor carpi ulnaris</i>	flexes & abducts wrist flexes & adducts wrist	
	<i>Flexor digitorum superficialis & profundus</i>	flex wrist & fingers	
Back of forearm	<i>Supinator</i>	supinates forearm	Radial nerve
	<i>Extensor carpi radialis</i> <i>Extensor carpi ulnaris</i>	extends & abducts wrist extends & adducts wrist	
	<i>Ext digitorum</i>	extends wrist & fingers	
	<i>Extensor pollicis brevis</i> <i>Extensor pollicis longus</i>	extend thumb	
	<i>Abductor pollicis longus</i>	abducts thumb	