HEAD/NECK: Cranial Nerves

- Special Sense Nerves
  - –I,II,VIII
- Somatic Motor Nerves
  - –Eye—III,IV,VI
  - –Tongue--XII
- “Rest of body” nerves
  - –IX,X,XI
- Face and jaws
  - –VII, V

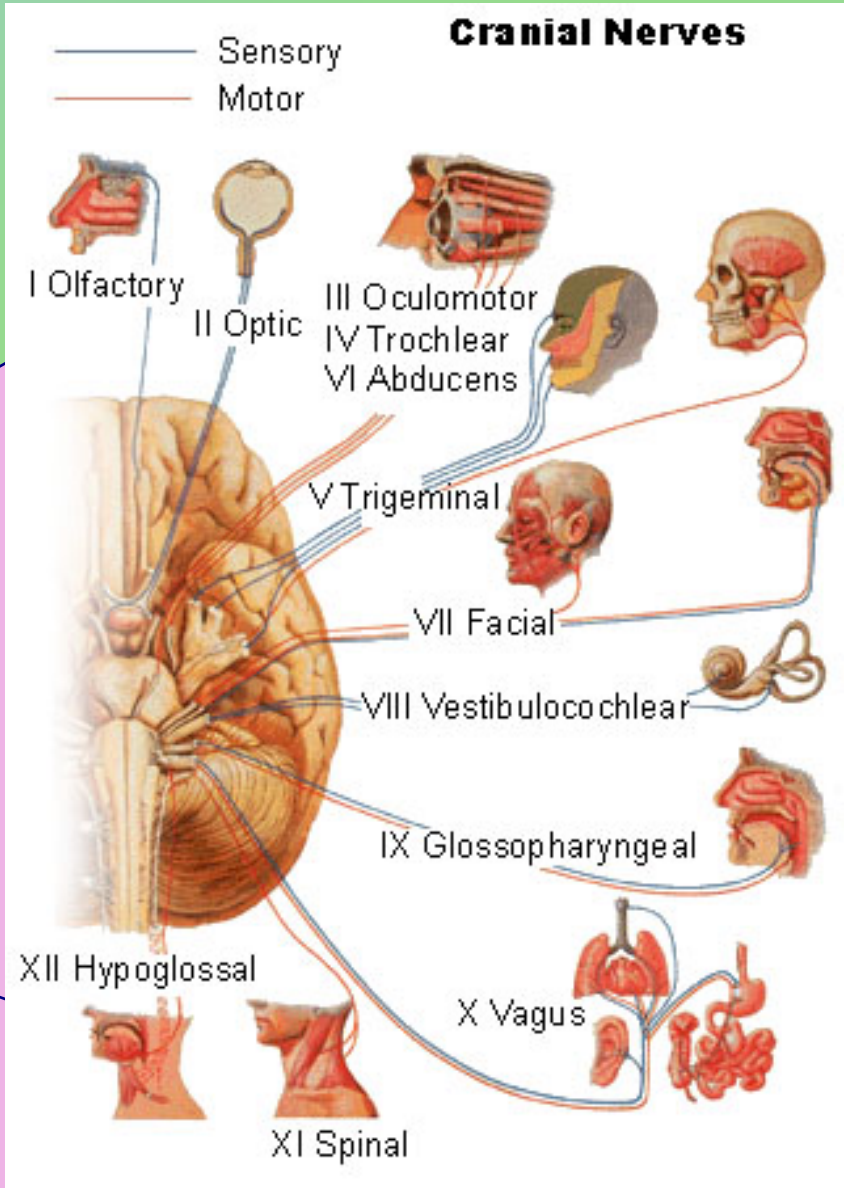

Overview Head/Neck I-IV

- Head I: Skull—a framework to hang on
  - Overall organization of skull
  - Base of the skull—the hard part
    - Developmental view
    - Cranial nerves out (to “targets”)
- Head II: Throat targets
- Head III: Special Sense targets
- Head IV: Cranial nerves in depth

Nerve “targets” in head

- SENSORY

Special	General
Smell	skin
Vision	teeth
Hearing	eye
	tongue
	oral cavity
	nasal cavity
	middle ear
	throat
	meninges

- MOTOR

Muscles	Glands
eyes	salivary
extrinsic	sweat
intrinsic	lacrimal
jaws	mucous
facial expression	
larynx	
tongue	
throat	
ear	

Base of the skull—cranial nerves out

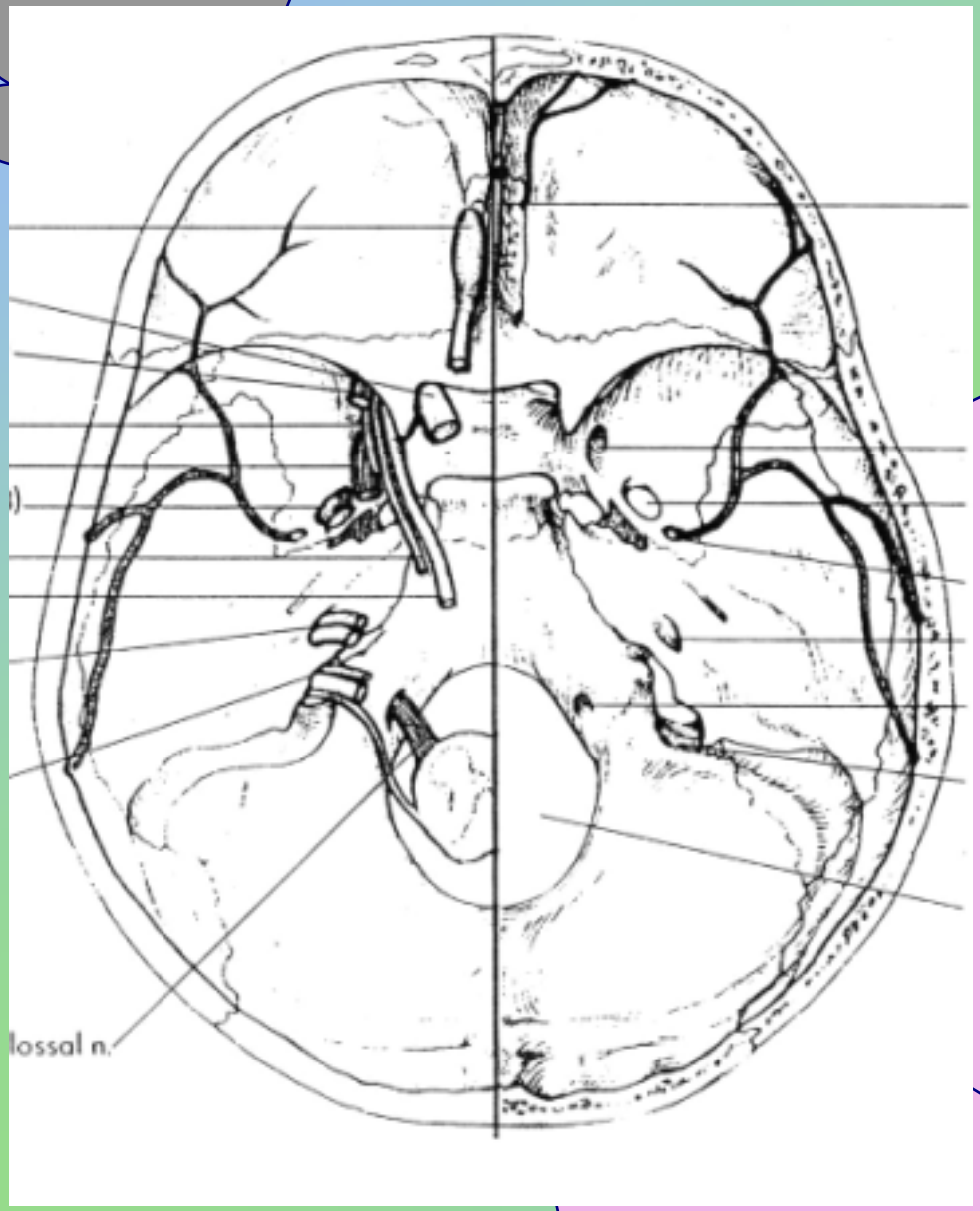

- <u>Ethmoid (olfactory)</u>
  I. Olfactory
- <u>Sphenoid (optic)</u>
  II. Optic
  III. Oculomotor
  IV. Trochlear
  VI. Abducens
- <u>Temporal (otic)</u>
  VII. Acoustic/Auditory/
  Vestibulocochlear
- <u>Face/Jaws</u>
  V. Trigeminal
  VII. Facial
- <u>Throat (rest of body)</u>
  IX Glossopharyngeal
  X. Vagus
  XI. Spinal Accessory
  XII. Hypoglosal

Special Sense Nerves

NERVE	TARGET	EXIT FROM CRANIAL CAVITY
I. Olfactory	Olfactory epithelium	Cribiform plate (ethmoid)
II. Optic	Retina	Optic canal (sphenoid)
VIII. Auditory	Inner ear	Internal auditory meatus (temporal)

M&M, Table 14.3

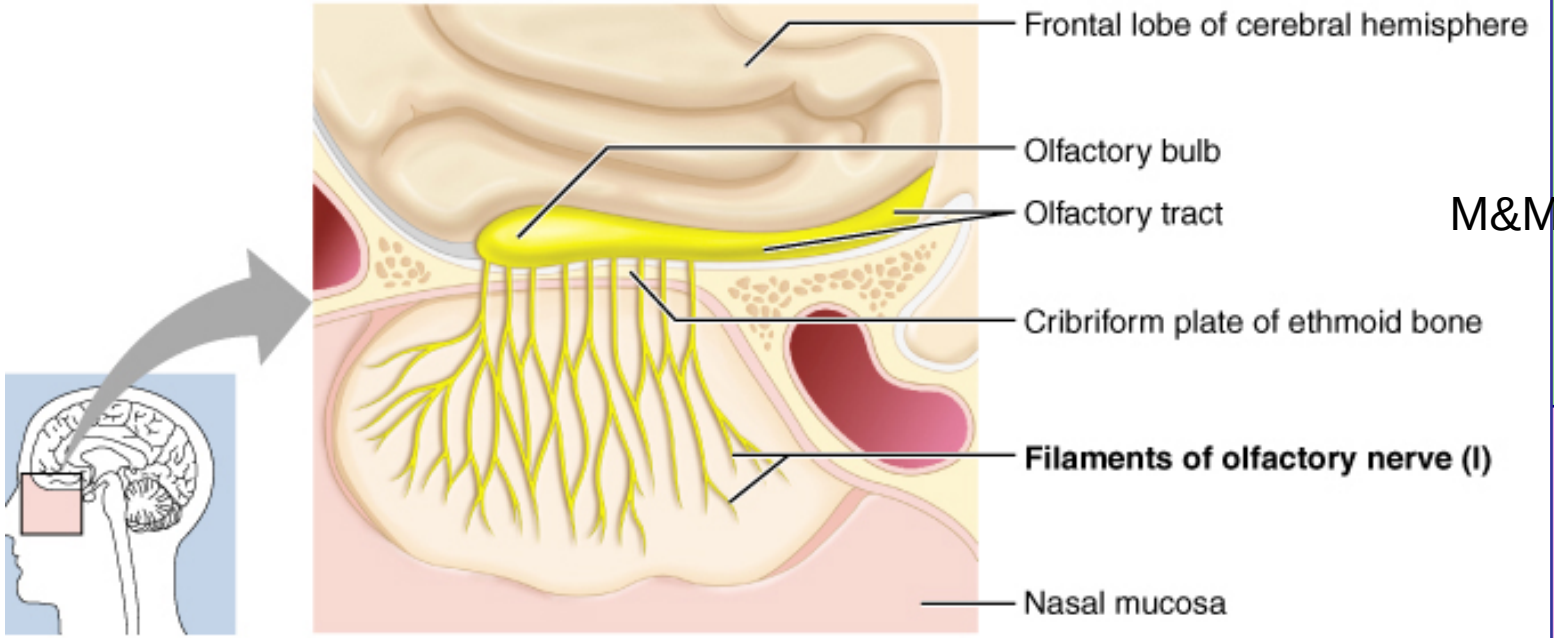

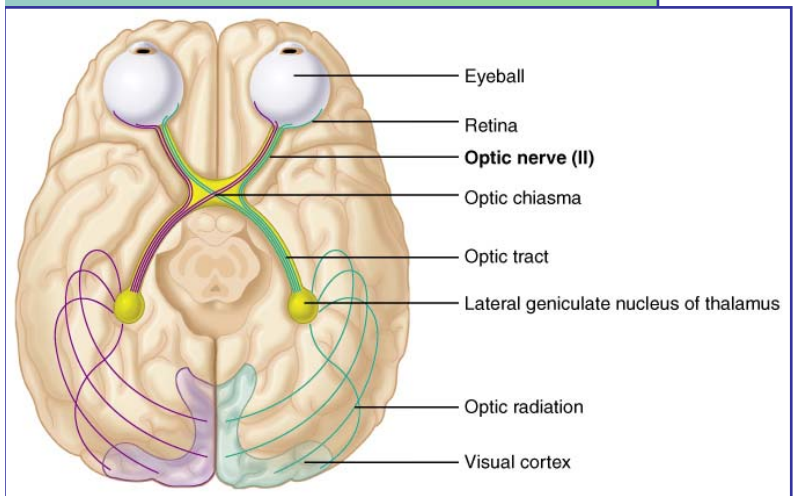

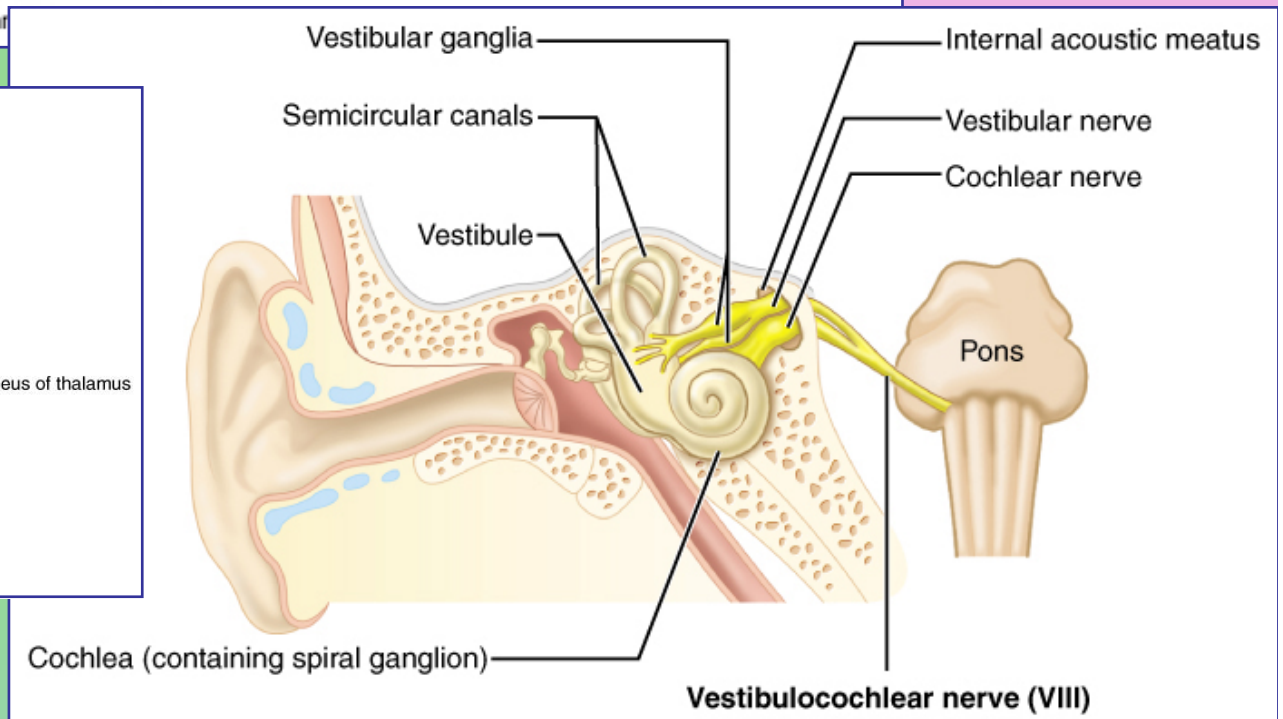

Somatic Motor Nerves

(eye muscles and tongue)

NERVE	TARGET	EXIT CR. CAVITY
IV. Trochlear	Superior oblique m. (with trochlea)	Sup. Orbital fissure (sphenoid)
VI. Abducens	Lateral rectus	“
III. Oculomotor (Also parasympathetic to ciliary mm, constrictor pupillae)	•Sup.,med.,inf.rectus • Inferior Oblique •Levator palpebrae superioris	“
XII. Hypoglossal	Intrinsic, extrinsic mm. of tongue	Hypoglossal canal (occipital)

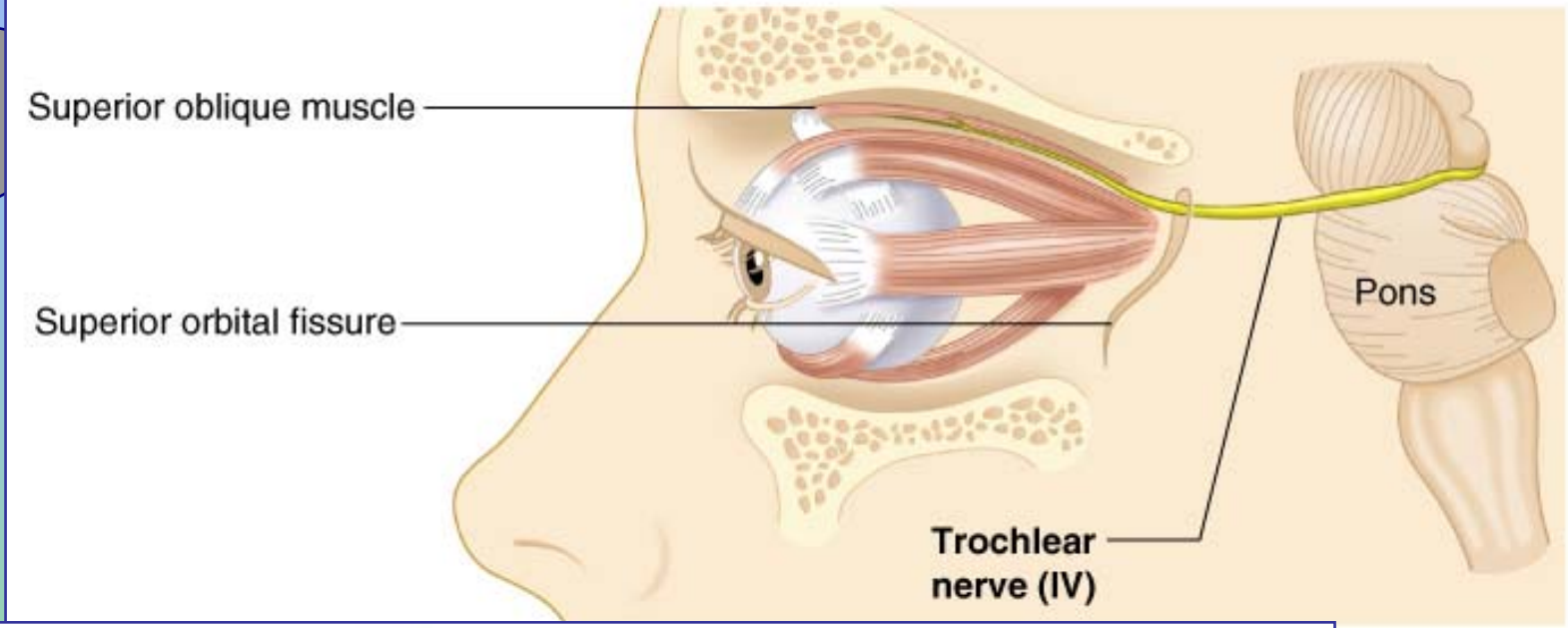

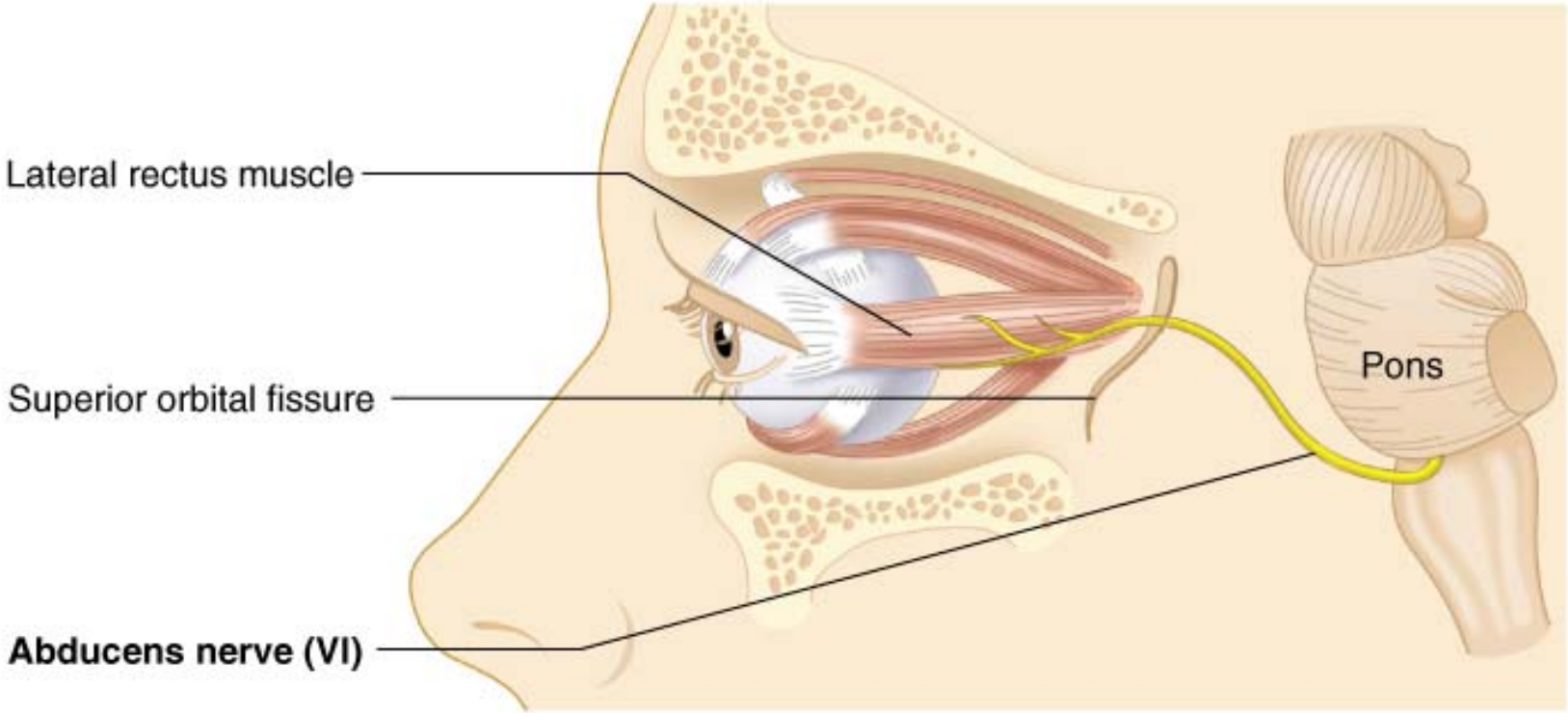

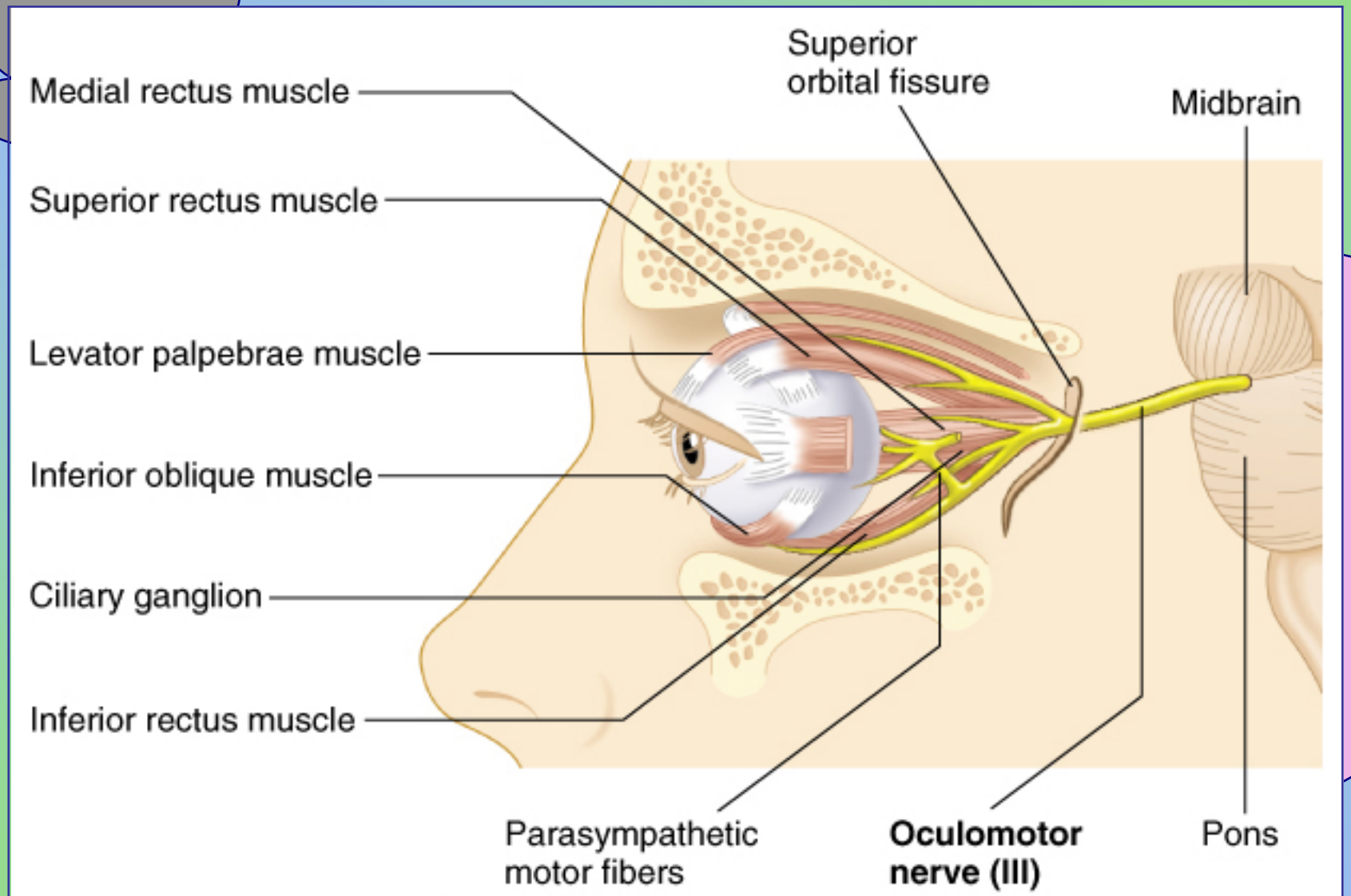

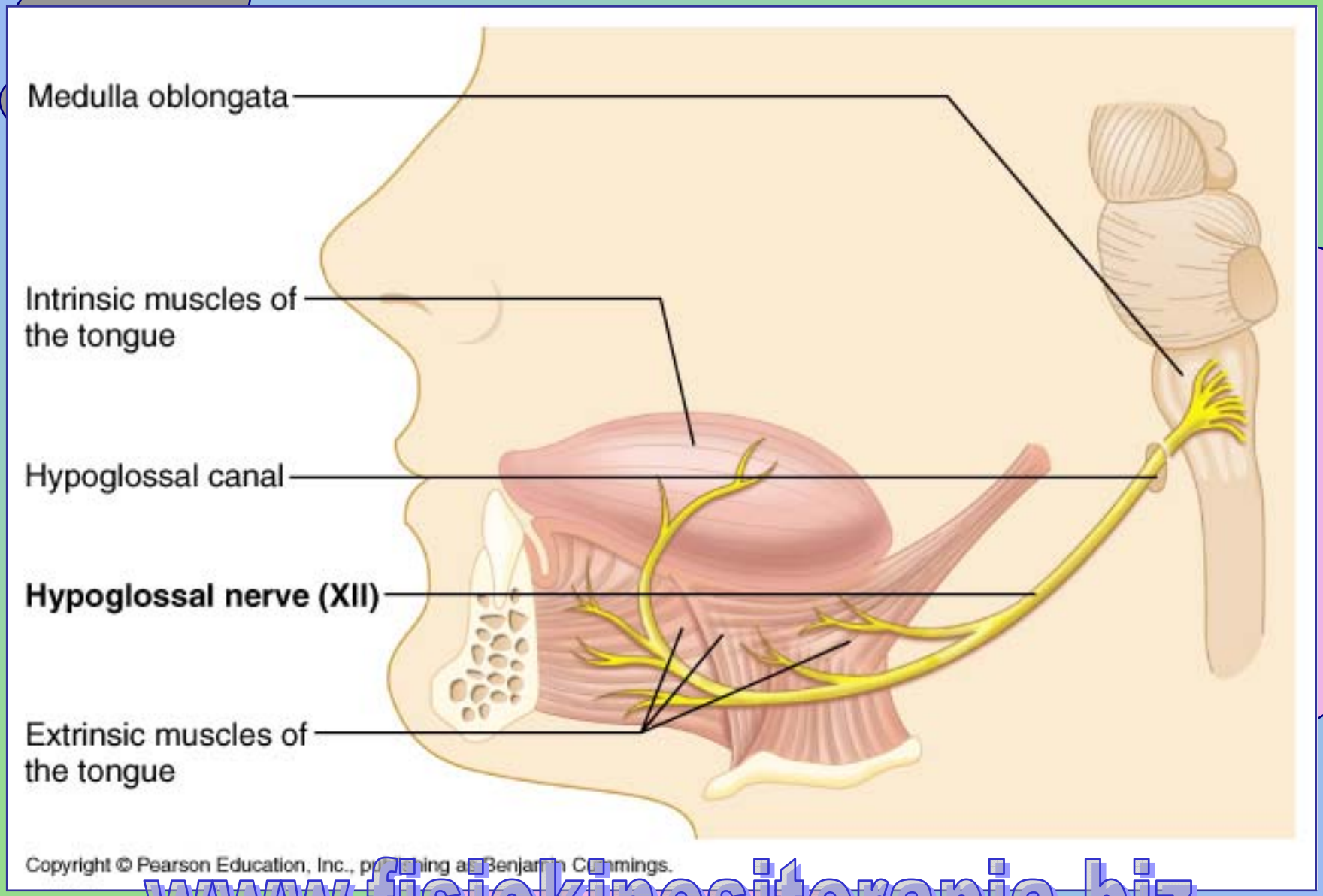

“Rest of body” nerves
(all exit from jugular foramen)

NERVE	TARGET
X: Vagus	• Somatic motor to larynx/pharynx • Parasympathetic to most of gut • Taste to back posterior pharynx
XI: (Spinal) Accesory	• Motor to traps, sternocleidomastoid
IX: Glosso-pharyngeal	• Sensory to carotid body/sinus • Taste to posterior tongue • Sensory to ear opening/middle ear • Parotid salivary gland

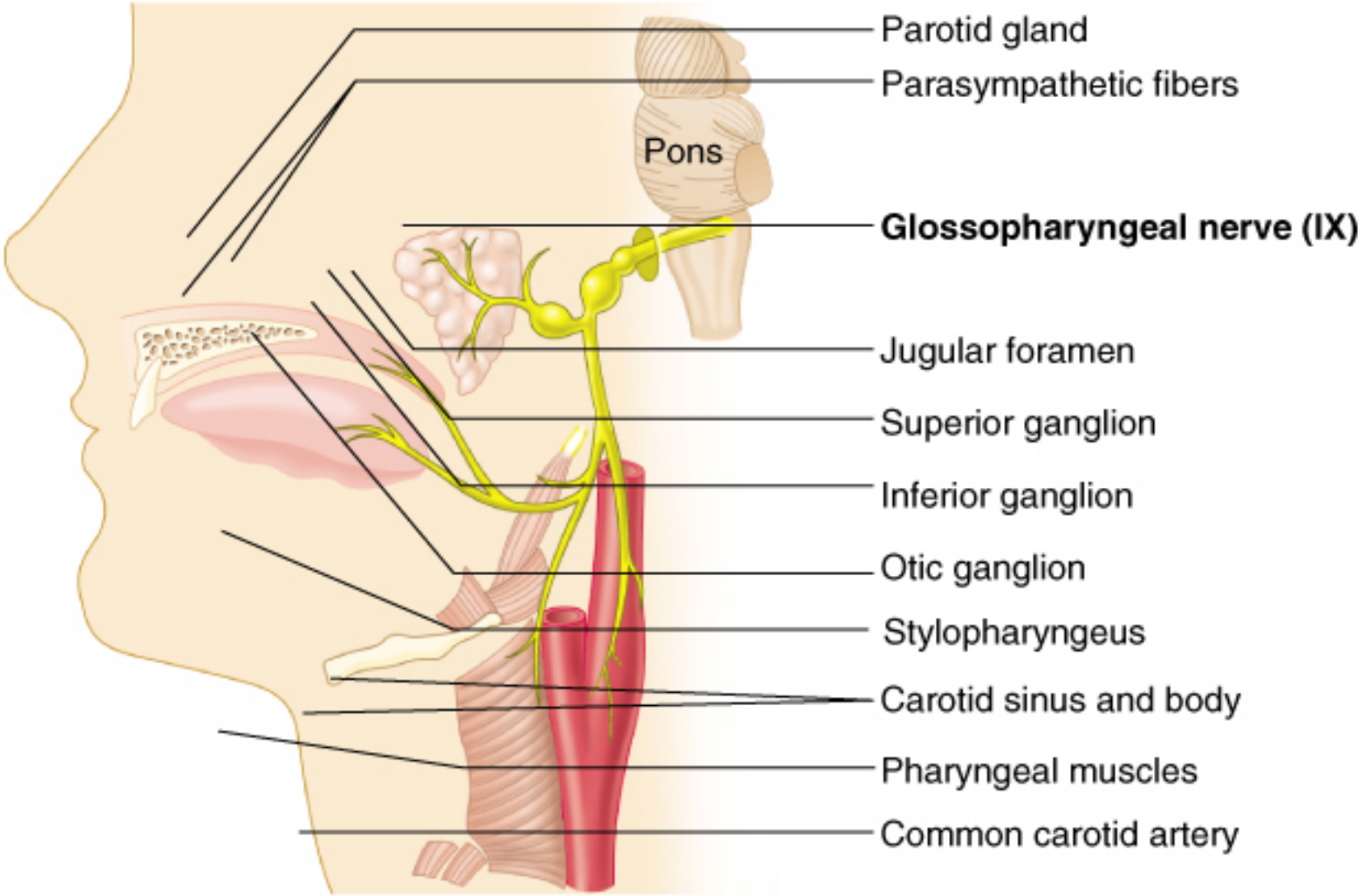

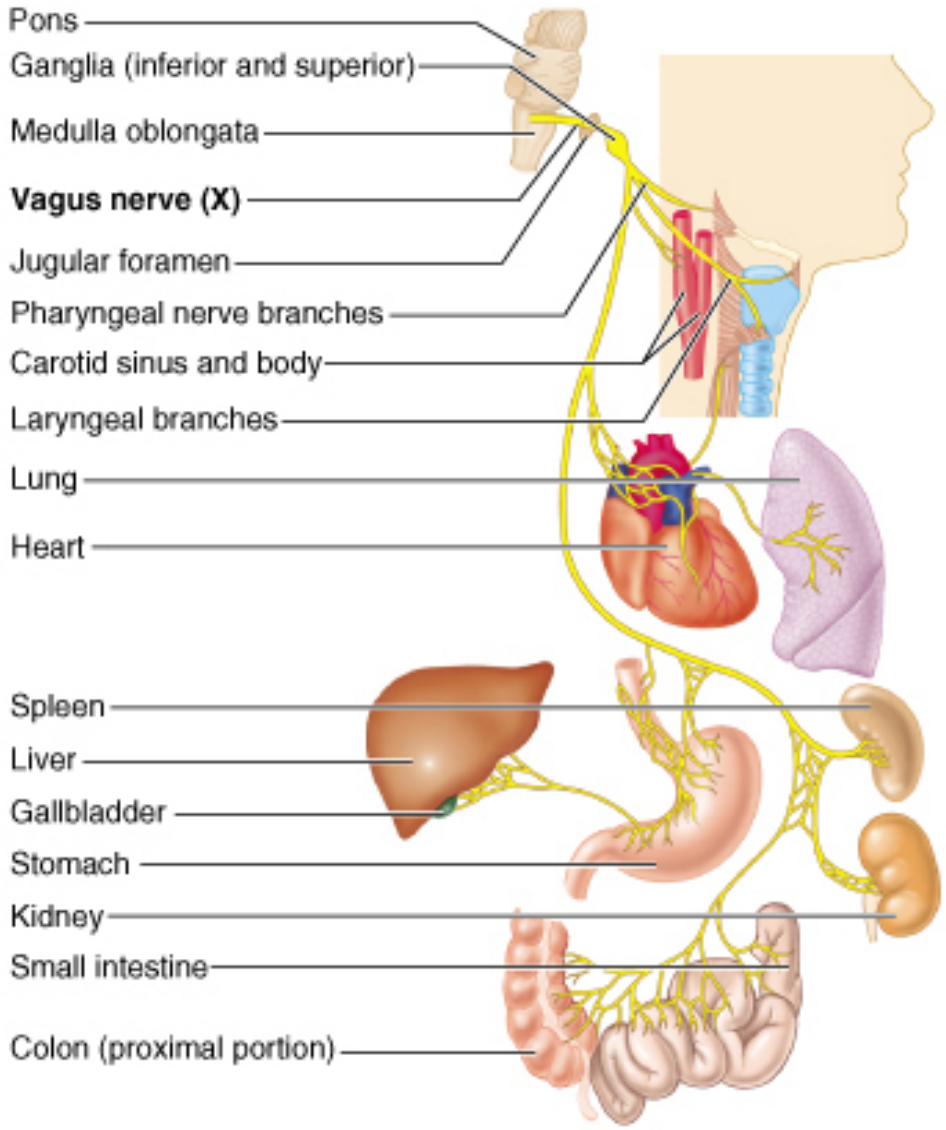

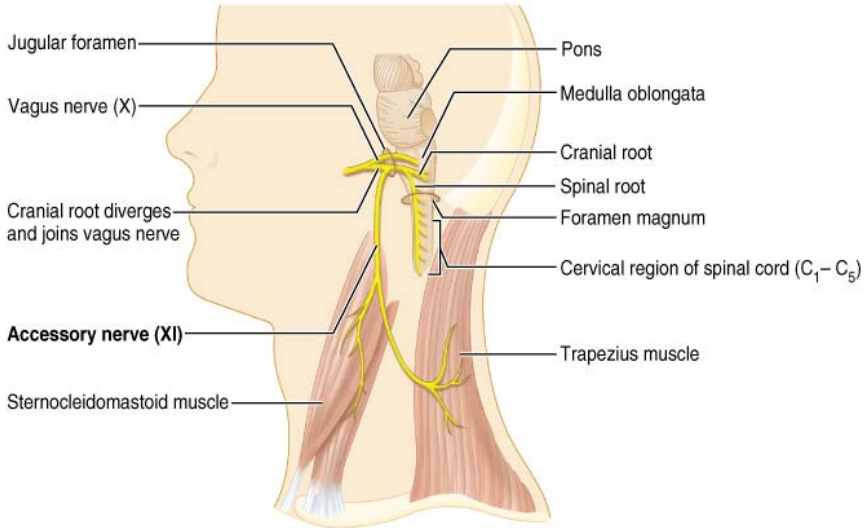

VII: Facial Nerve

(exits cranial cavity with VIII--internal auditory meatus)

- Facial muscles (five branches fan out over face from stylomastoid foramen)
  - Temporal
  - Zygomatic
  - Buccal
  - Mandibular
  - Cervical
- "chorda tympani" (crosses interior ear drum to join V_3)
  - Taste to anterior 2/3 of tongue
  - Submandibular, sublingual salivary glands
- Lacrimal glands

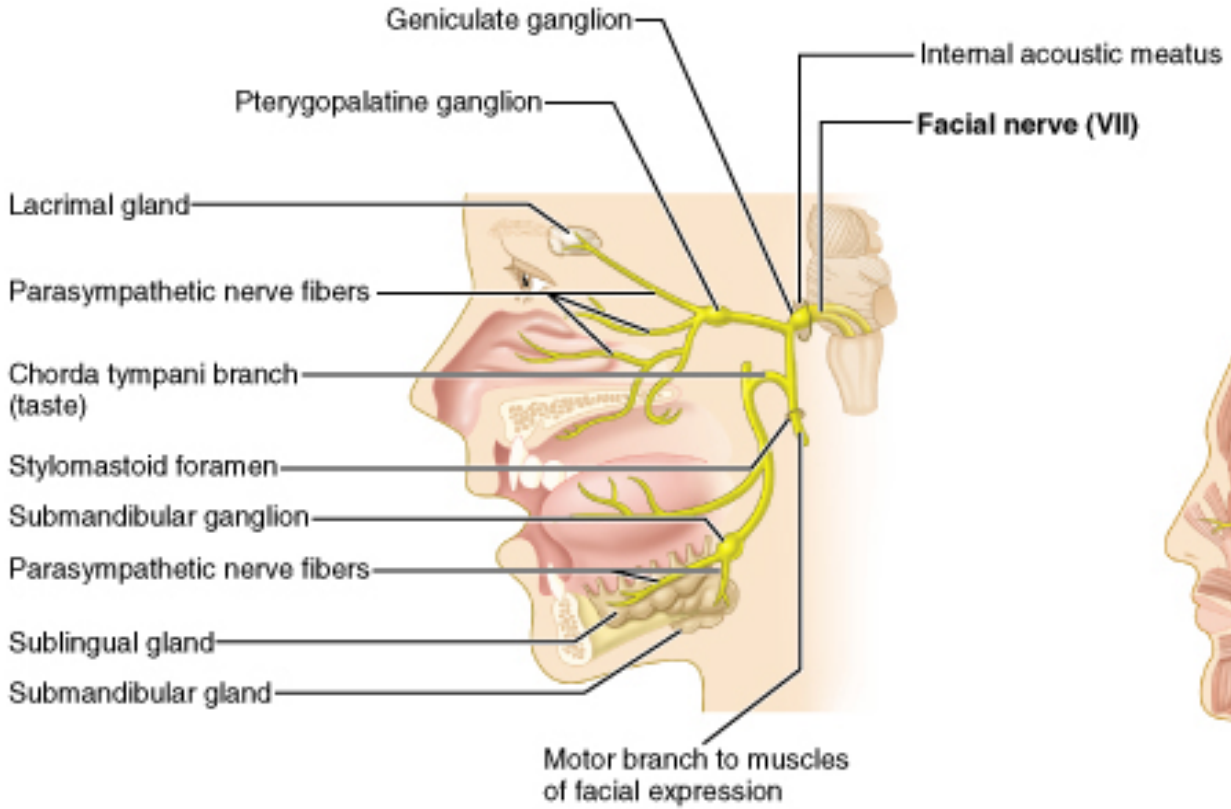

(a) Parasympathetic efferents and sensory afferents

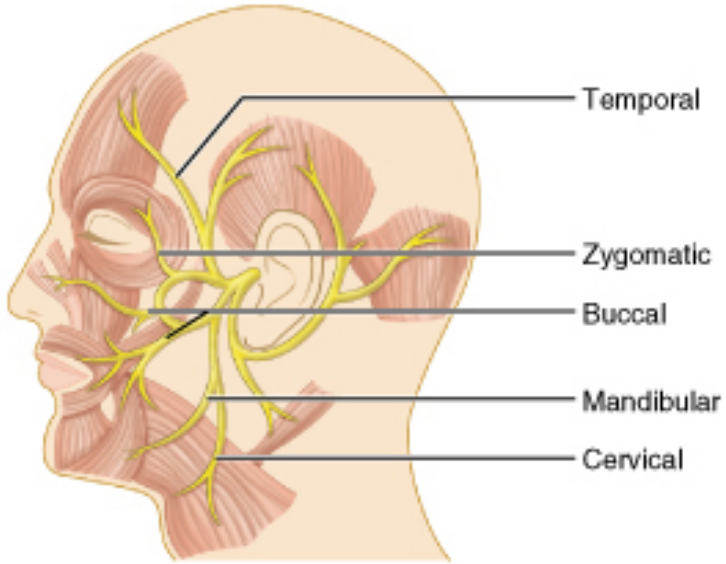

(b) Motor branches to muscles of facial expression and scalp muscles

V: Trigeminal (3 nerves in 1!)

- V1. Ophthalmic
  - Exits with eye muscle group (superior orbital fissure, through orbit to superior orbital notch/foramina)
  - Sensory to forehead, nasal cavity
- V2. Maxillary
  - Exits foramen rotundum through wall of maxillary sinus to inferior orbital foramina)
  - Sensory to cheek, upper lip, teeth, nasal cavity
- V3. Mandibular
  - Exits foramen ovale to mandibular foramen to mental foramen
  - Motor to jaw muscles--Masseter, temporalis, pterygoids, digastric
  - Sensory to chin
  - Sensory to tongue

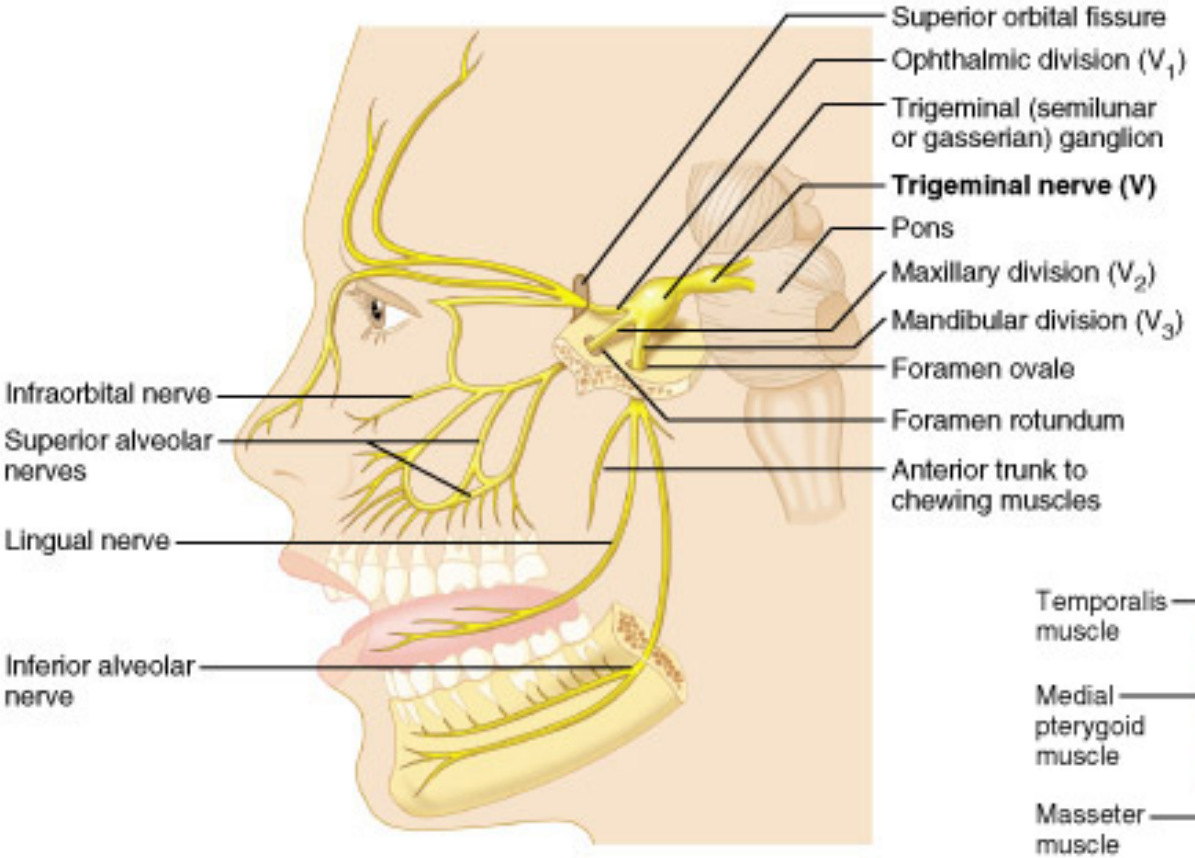

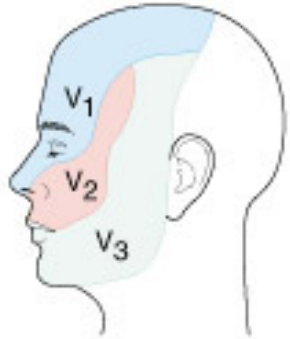

Distribution of sensory fibers of each division

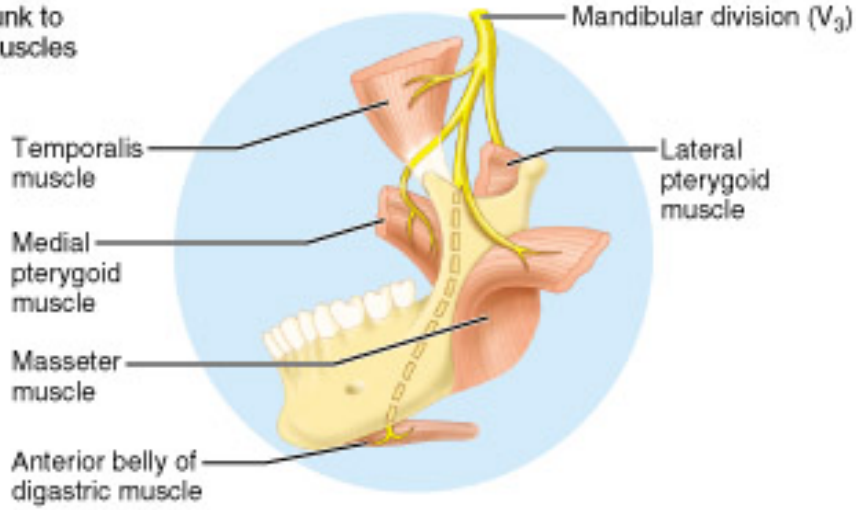

Inset shows motor branches of the mandibular division (V_3)

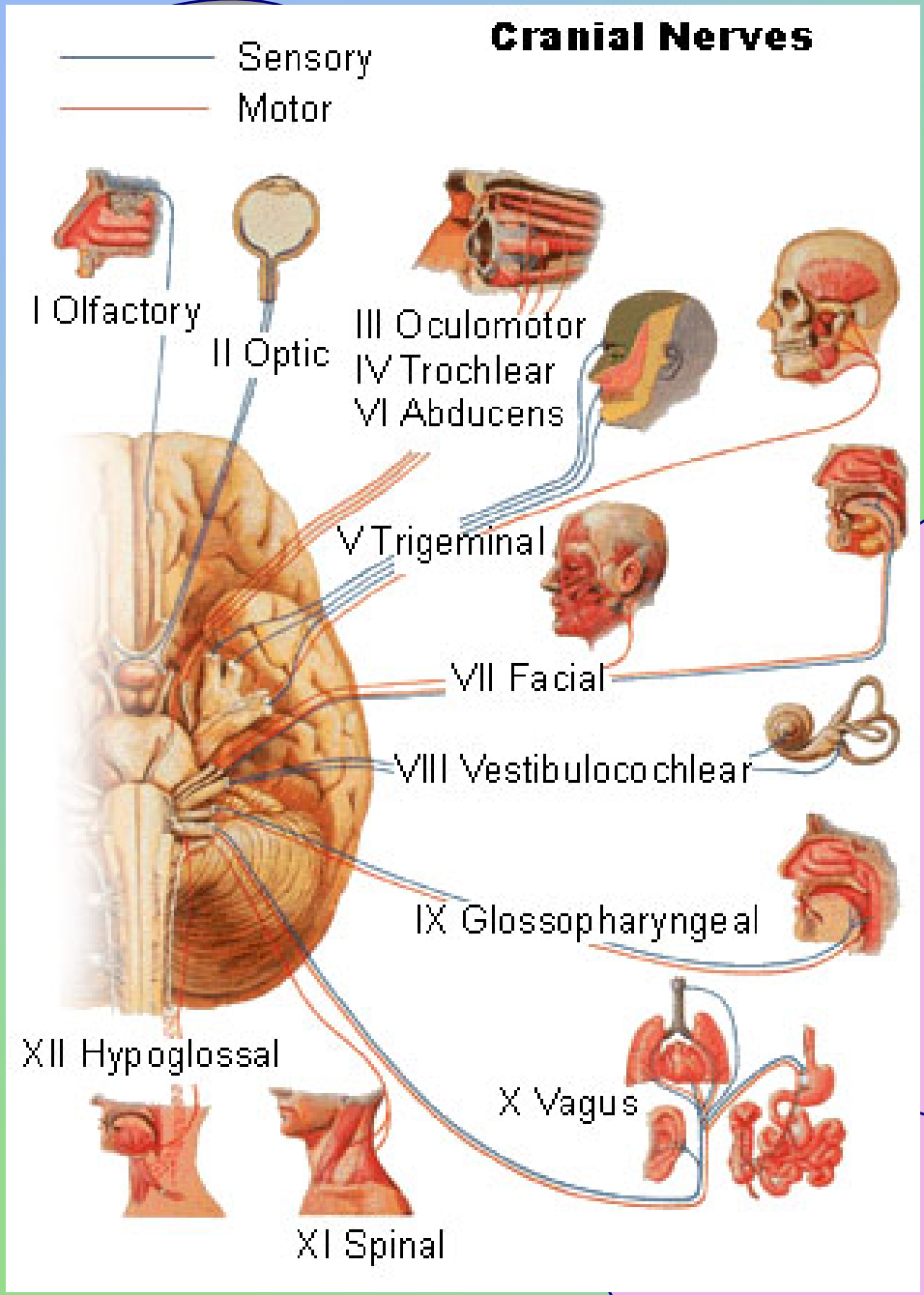

Cranial Nerve Web Sites

Clinical tests for cranial nerves with photos in clinic (New York U)

More detail cranial nerves, but some missing (Yale Medical)

NIce review of cranial nerves--includes clinical tests for nerves and cryptogram puzzle of nerves (Washington U)