

[www.fisiokinesiterapia.biz](http://www.fisiokinesiterapia.biz)

# Advanced Assessment of Upper Extremity Injuries

Elbow and Forearm Anatomy  
and Evaluation

# Anatomy

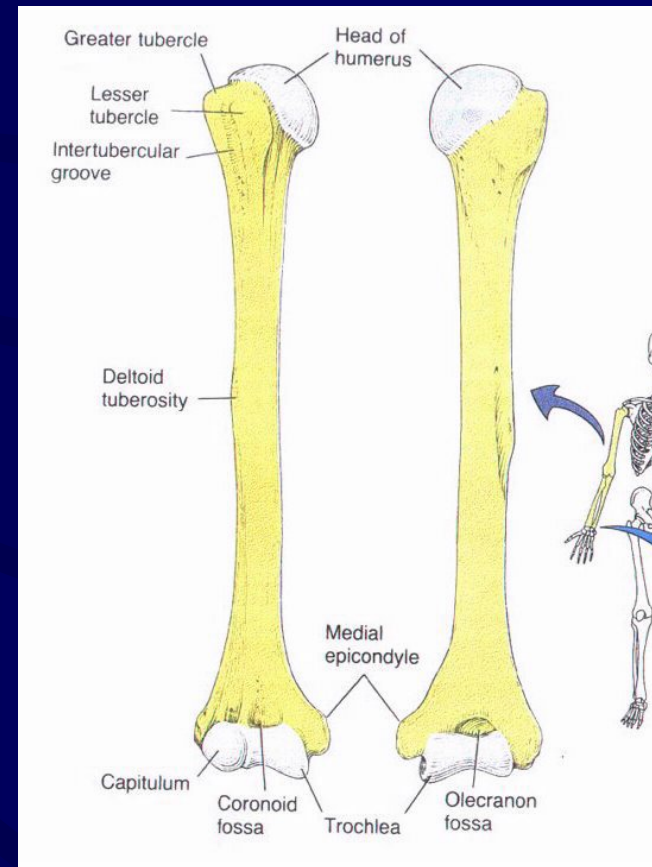
# Anatomy

- Bony anatomy
- Articulations and ligamentous anatomy
- Muscular anatomy
- Neurological and vascular anatomy
- Bursa of the elbow

# *Bony Anatomy*

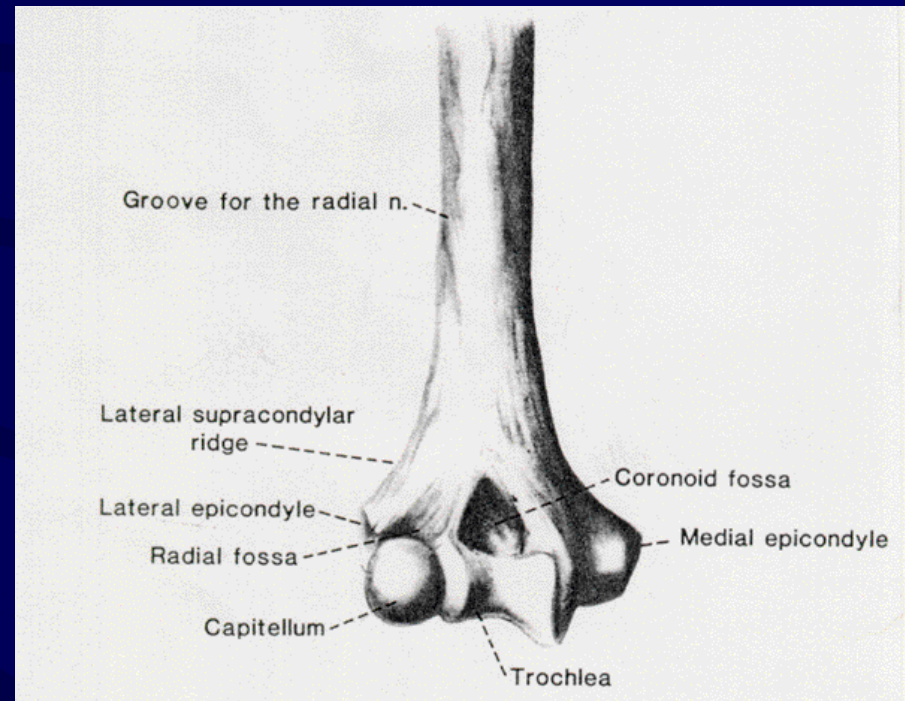
# Bony Anatomy: Humerus

- Distally – 2 condyles forming articular surfaces of trochlea and capitellum
- Proximally – neck and head articulate with glenoid fossa of scapula



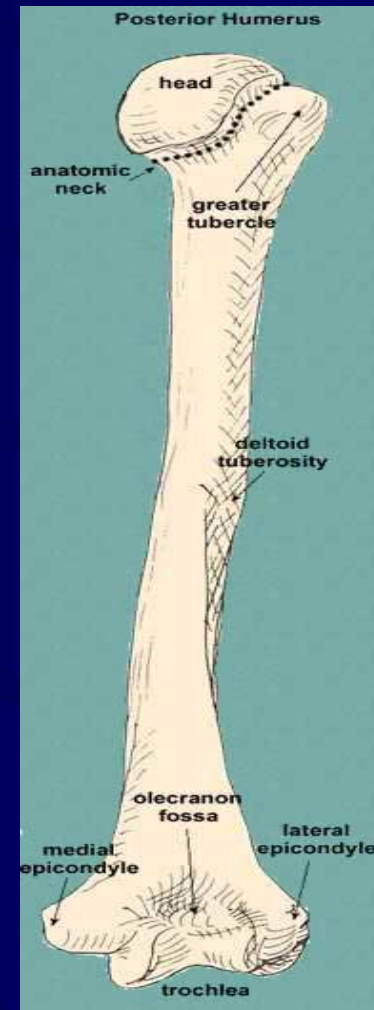
# Distal Humerus Anatomy

- Medial epicondyle proximal to trochlea – attachment site for UCL and flexor/pronator ms.
- Lateral epicondyle proximal to capitellum – attachment site for RCL, extensor/supinator ms.
- Radial fossa – accommodates margin of radial head during flexion
- Coronoid fossa – accepts coronoid process of ulna during flexion



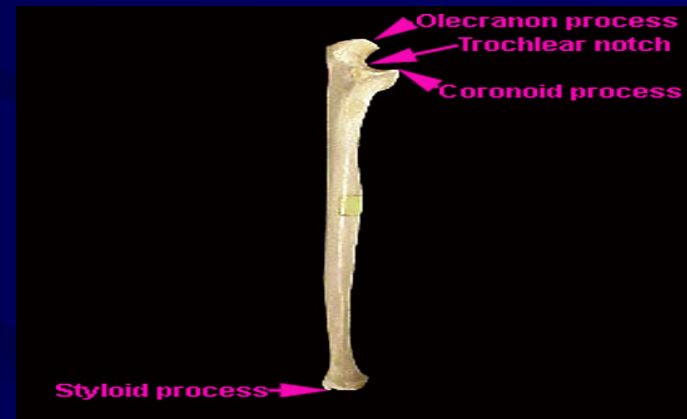
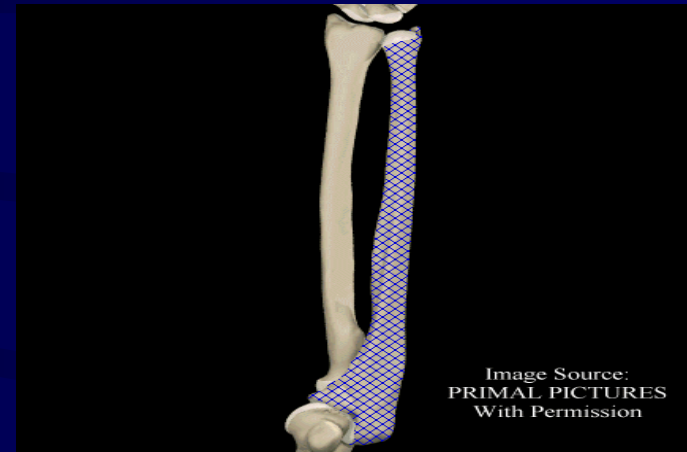# Distal Humerus – Posterior

- Olecranon fossa accepts olecranon process of ulna during extension



# Ulnar Anatomy

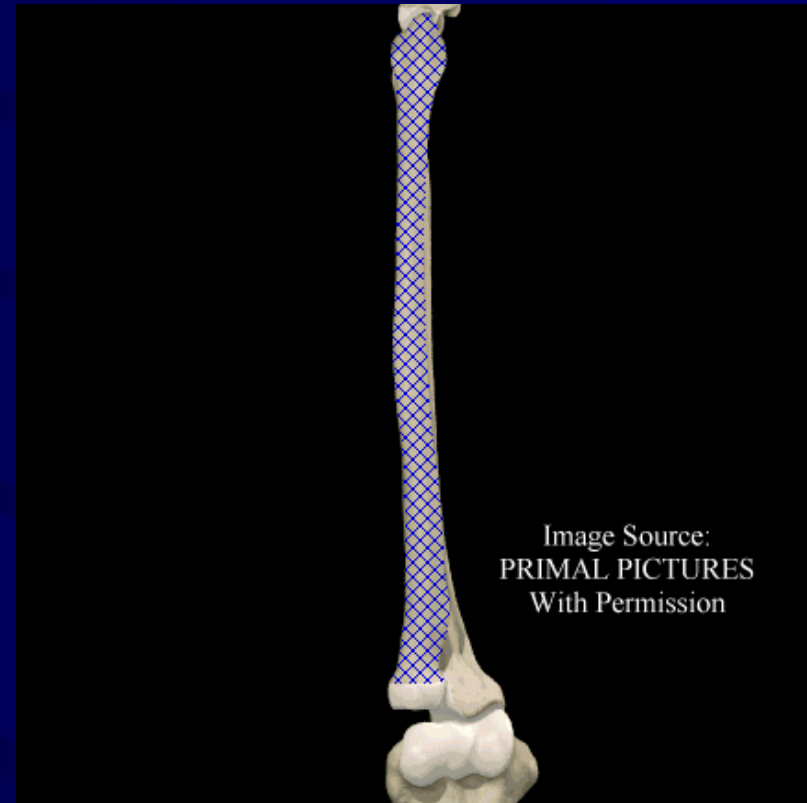
- Sigmoid/semilunar/  
trochlear notch
  - Anteriorly composed  
of coronoid process
  - Posteriorly composed  
of olecranon process
  - Articulates with  
trochlea of humerus





# Radial Anatomy

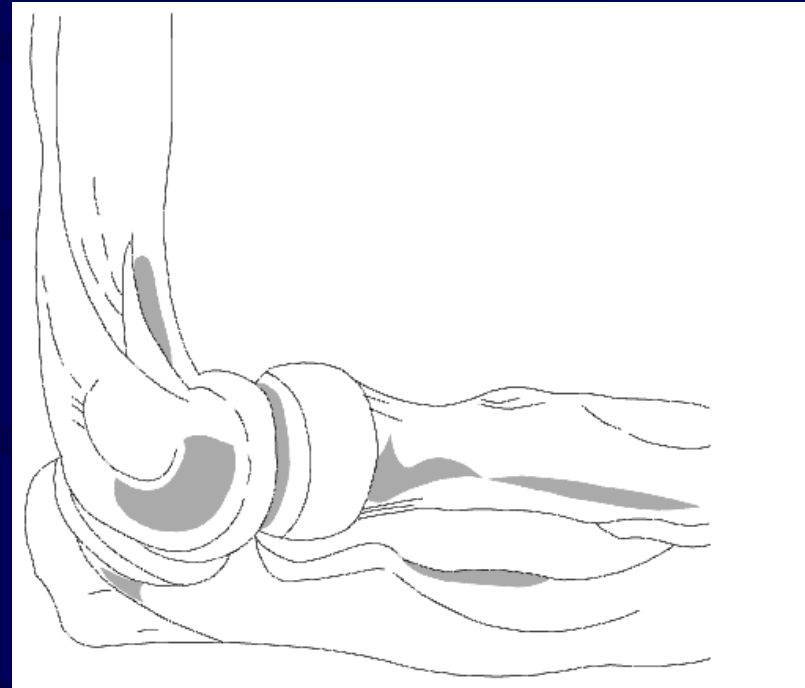
- Radial head articulates with capitellum
- Radial neck tapers to radial tuberosity which is insertion for biceps brachii tendon



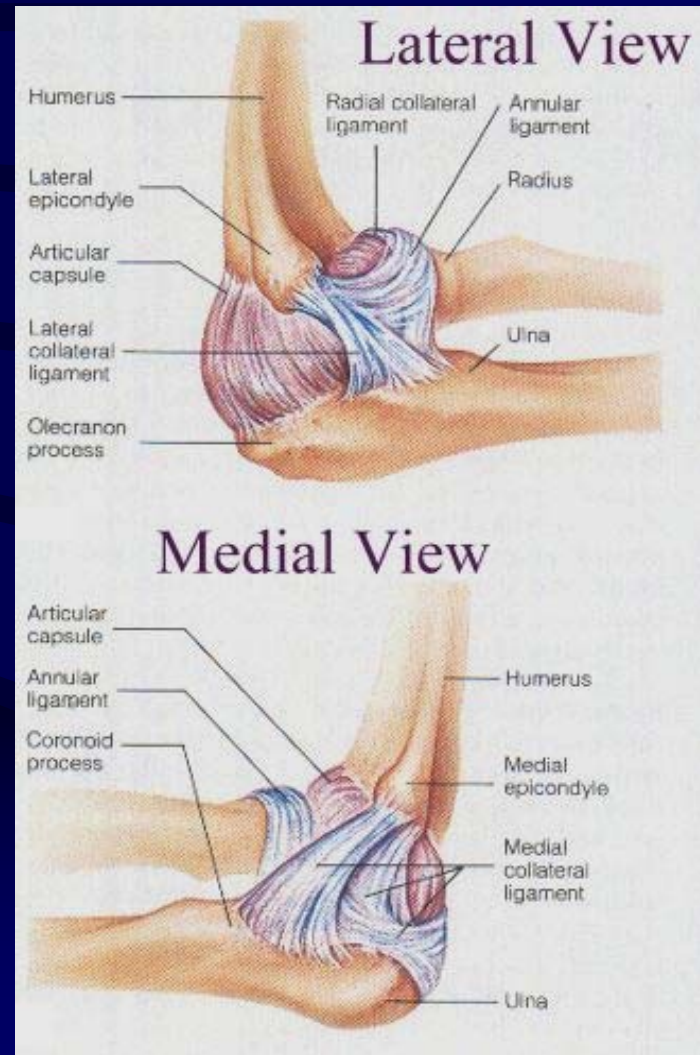
# Articulations and Ligamentous Anatomy

# Elbow Joint Articulation

- Elbow consists of 3 articulations:
  - Ulnohumeral (elbow flexion/extension)
  - Radiohumeral (forearm pronation/supination)
  - Radioulnar (forearm pronation/supination)

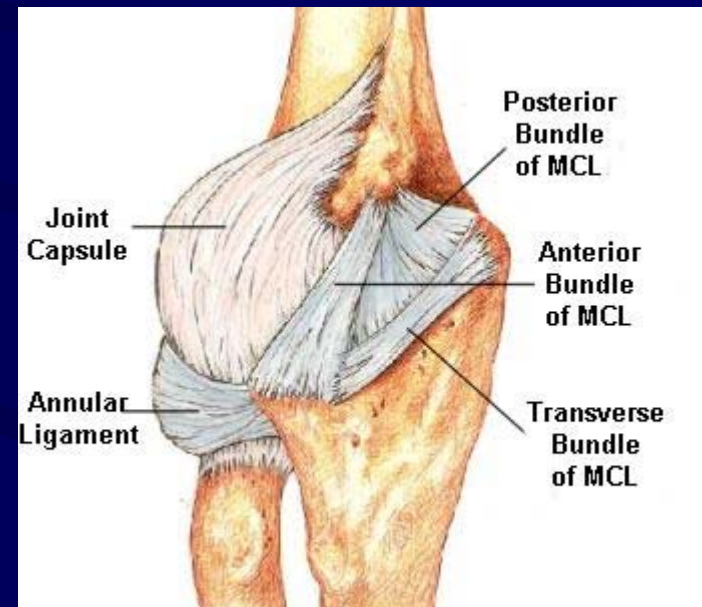


# Elbow Ligamentous Structures



# Medial Ligamentous Structures

- Medial/Ulnar Collateral Ligament
  - Anterior bundle – most discrete segment
  - Posterior bundle – thickening of posterior capsule
  - Transverse bundle – spans medial border of semilunar notch, little/no contribution to elbow stability

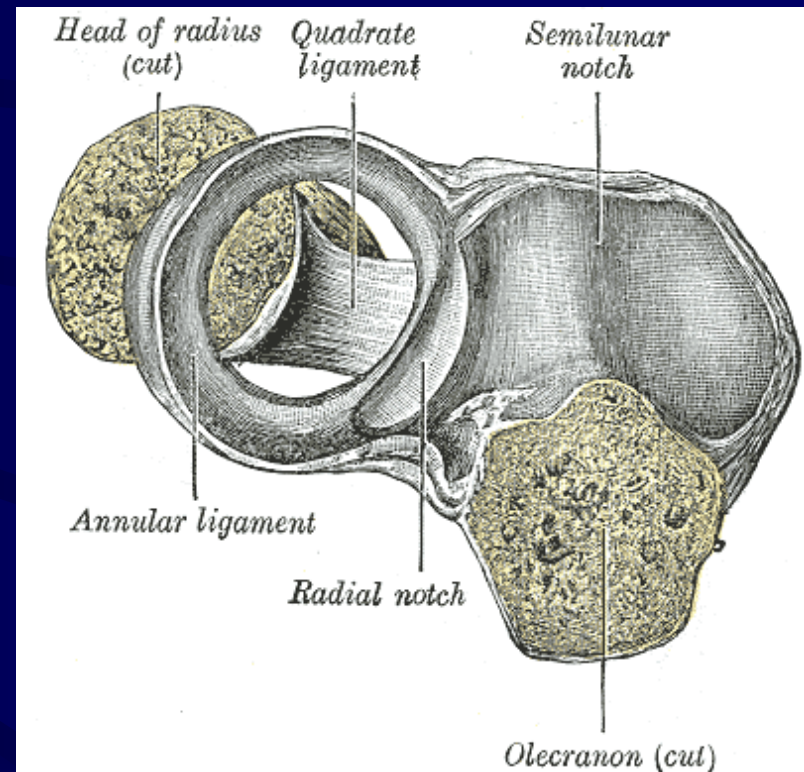


# Medial Ligamentous Structures

- Origin of anterior bundle is inferior to axis of motion (flexion/extension), so some fibers tight during flexion and some during extension (major stabilizing component)
- Origin of posterior bundle is inferior and posterior to the axis, so fibers are tight during flexion and not during extension

# Lateral Ligamentous Structures

- Lateral/radial collateral ligament – origin is near axis of elbow flexion/extension, so fibers uniformly tight throughout ROM
- Annular ligament – inserts on anterior/posterior margins of lesser (radial) semilunar notch, maintains radial head in contact with ulna (forms 4/5 of fibro-osseous ring)



# Lateral Ligamentous Structures

- Lateral medial/ulnar collateral ligament – present in approximately 50% of population
- Accessory lateral/radial collateral ligament – tight only during varus stress maneuvers and assists annular ligament when varus stress applied to elbow



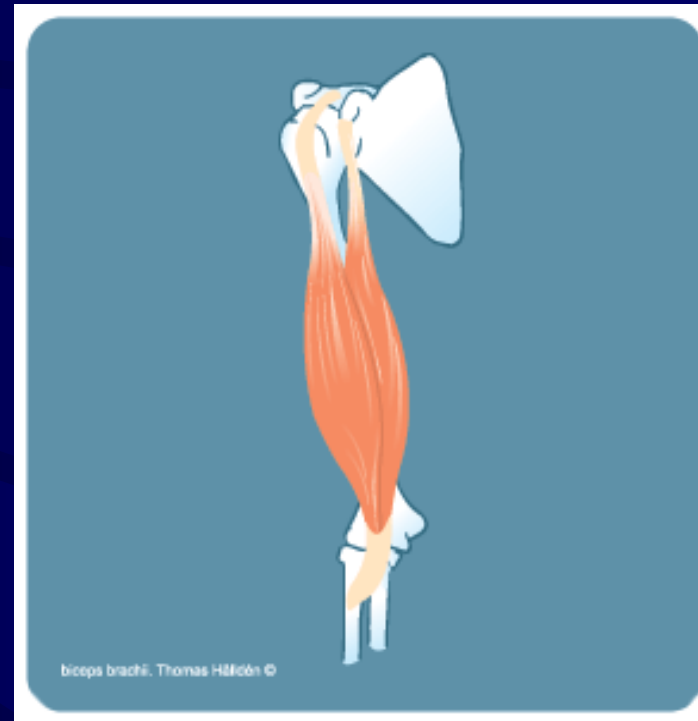
# Muscular Anatomy

# Muscular Anatomy

- Muscles acting on elbow
  - Anterior arm
  - Posterior arm
- Muscles originating at elbow, acting on forearm, wrist and hand
  - Flexor/pronator group (hand reference)
  - Extensor/supinator group (3 medial, 3 lateral, 3 “outcropping”, 3 “accessory”)

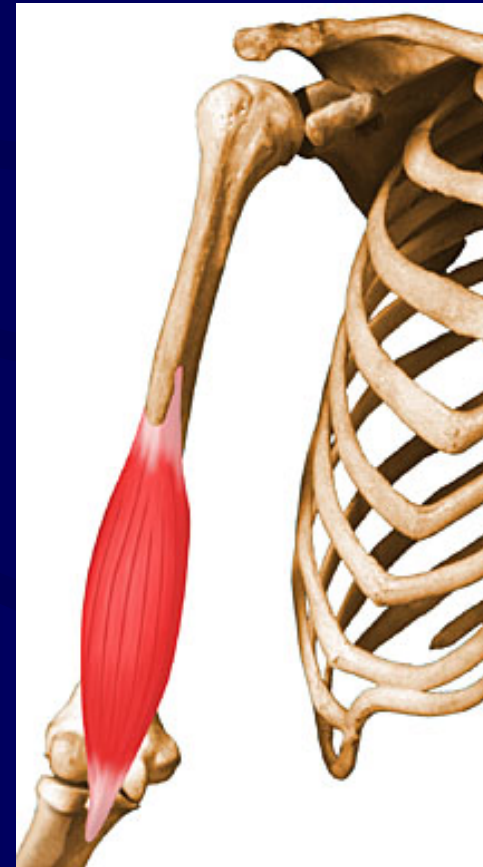# Muscular Anatomy – Anterior Arm

- Biceps brachii
  - Origin: long head from supraglenoid rim, short head from coracoid process
  - Insertion: radial tuberosity
  - Innervation: musculocutaneous nerve
  - Action: elbow flexion, forearm supination, shoulder flexion



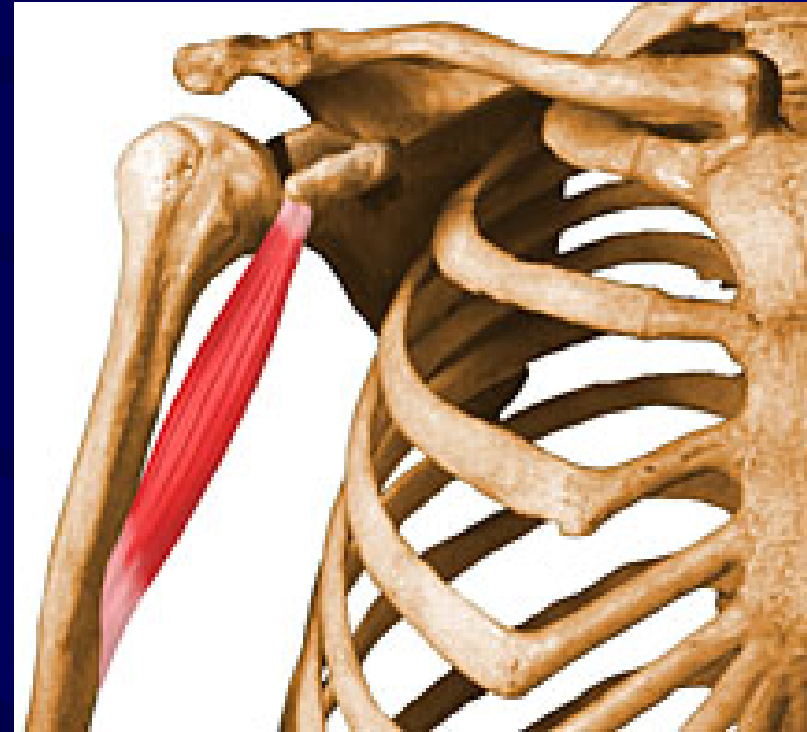
# Muscular Anatomy – Anterior Arm

- Brachialis
  - Origin: distal anterior humerus
  - Insertion: ulnar tuberosity and coronoid process
  - Innervation: musculocutaneous nerve
  - Action: elbow flexion



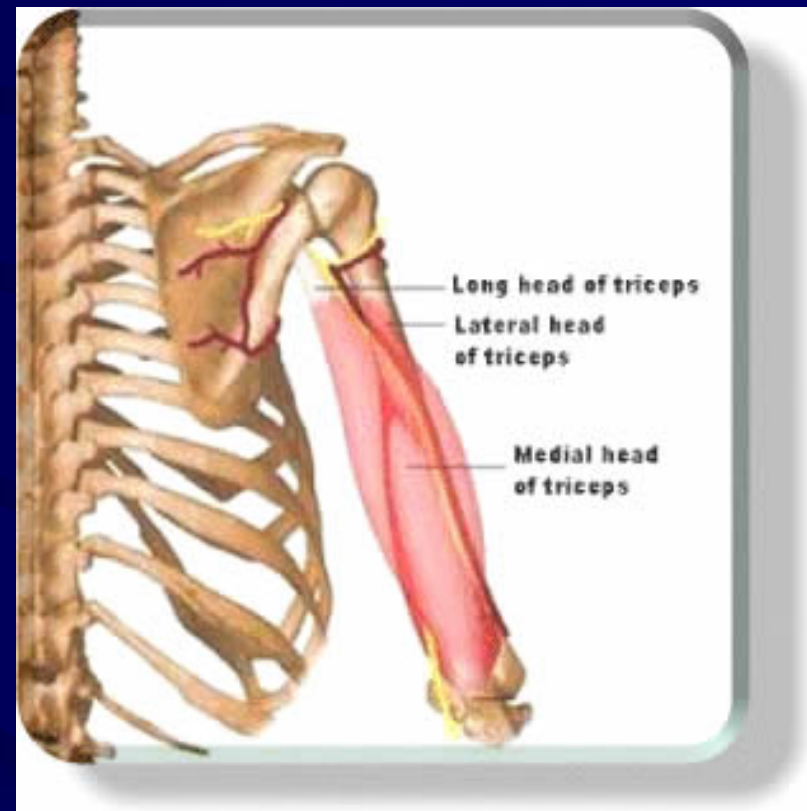
# Muscular Anatomy – Anterior Arm

- Coracobrachialis
  - Origin: coracoid process
  - Insertion: medial humerus opposite deltoid tuberosity
  - Innervation: musculocutaneous nerve
  - Action: shoulder flexion



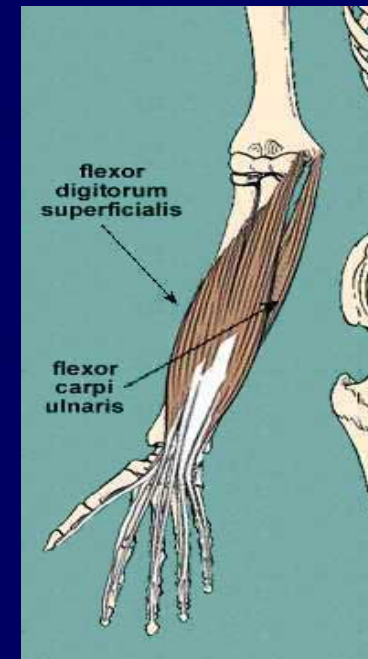
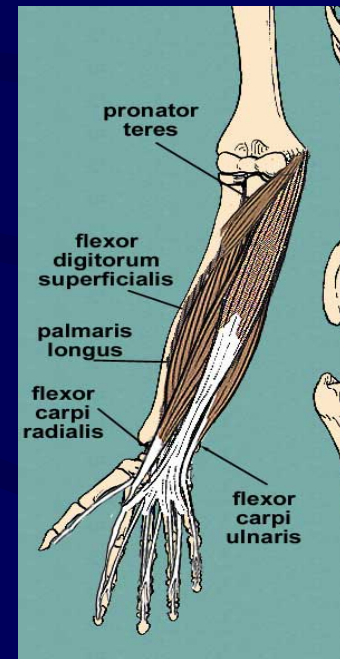
# Muscular Anatomy – Posterior Arm

- Triceps brachii
  - Origin: long head from inferior glenoid rim, lateral head from posterior humeral ridge, medial head from distal 2/3 of posteromedial humerus
  - Insertion: olecranon process
  - Innervation: radial nerve
  - Action: elbow extension



# Muscular Anatomy – Elbow Origin

- Flexor/pronator group
  - Pronator teres
  - Flexor carpi radialis
  - Flexor digitorum superficialis
  - Flexor digitorum profundus
  - Palmaris longus
  - Flexor carpi ulnaris
  - Pronator quadratus



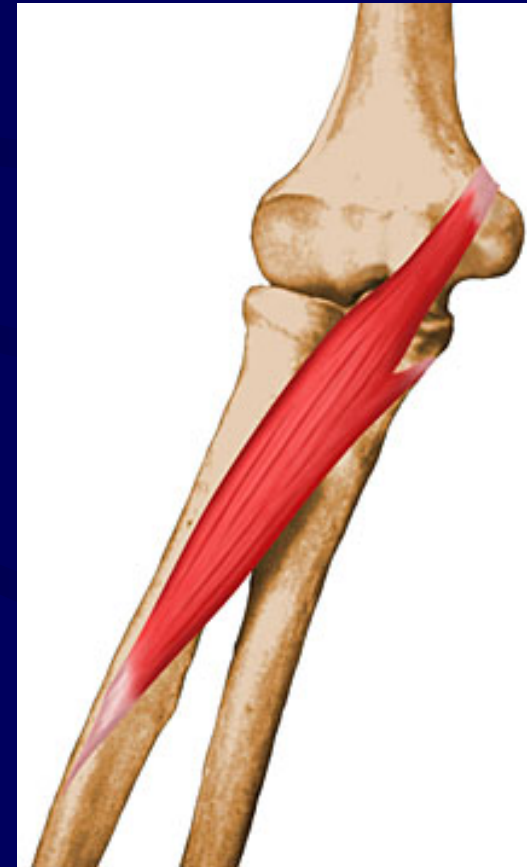# Hand Reference

- “Heel” of hand at medial epicondyle
- Superficial layer
  - Thumb = pronator teres, index finger = flexor carpi radialis, ring finger = palmaris longus, little finger = flexor carpi ulnaris
- Intermediate layer
  - Middle finger = flexor digitorum superficialis
- Deep layer
  - Flexor digitorum profundus, pronator quadratus, flexor pollicis longus



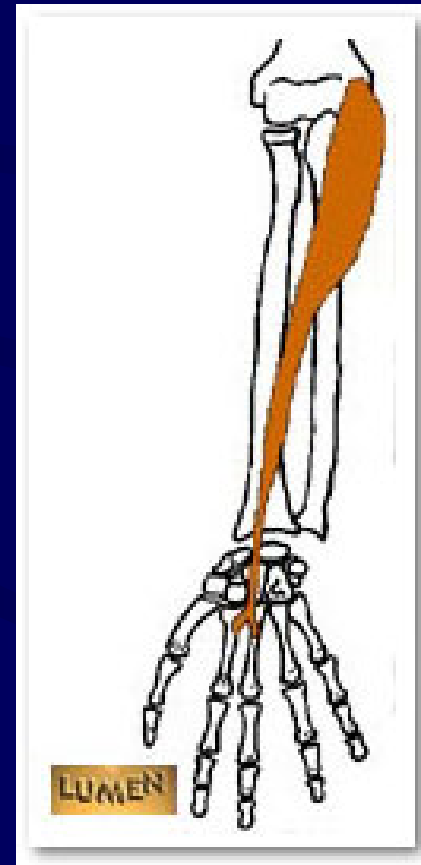
# Pronator Teres

- Origin: common flexor tendon at medial epicondyle and medial coronoid process
- Insertion: lateral surface of radial shaft
- Innervation: median nerve
- Action: forearm pronation



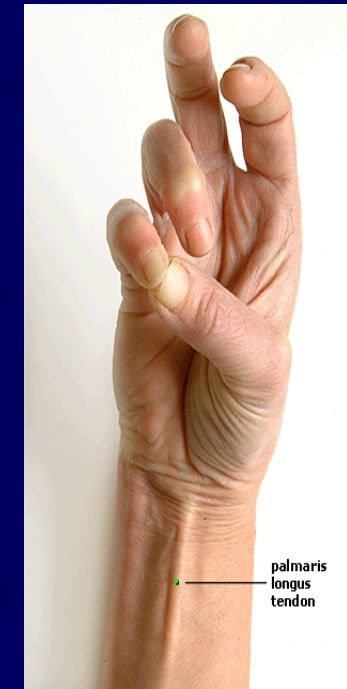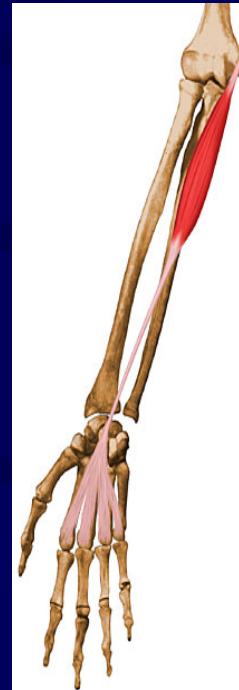# Flexor Carpi Radialis

- Origin: common flexor tendon at medial epicondyle
- Insertion: base of 2<sup>nd</sup> and 3<sup>rd</sup> metacarpals
- Innervation: median nerve
- Action: flexes and abducts/radial deviate the wrist



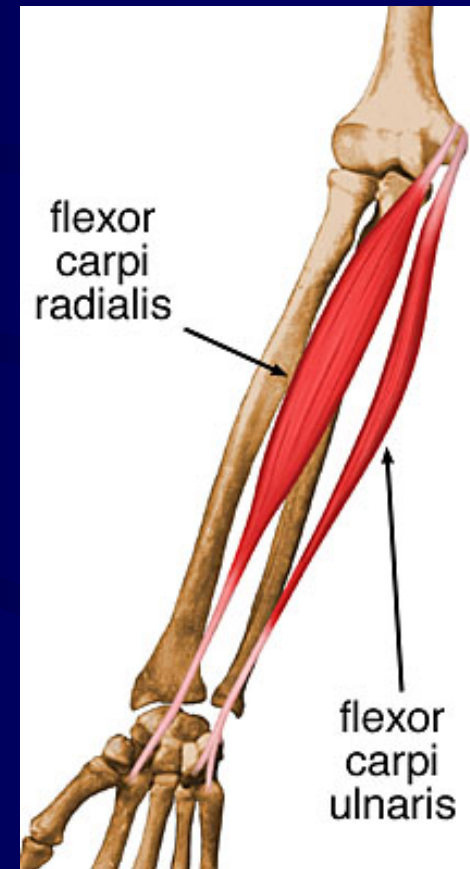
# Palmaris Longus

- Present in approximately 70% of population
- Origin: common flexor tendon at medial epicondyle
- Insertion: palmar aponeurosis
- Action: flexes wrist and tenses palmar aponeurosis



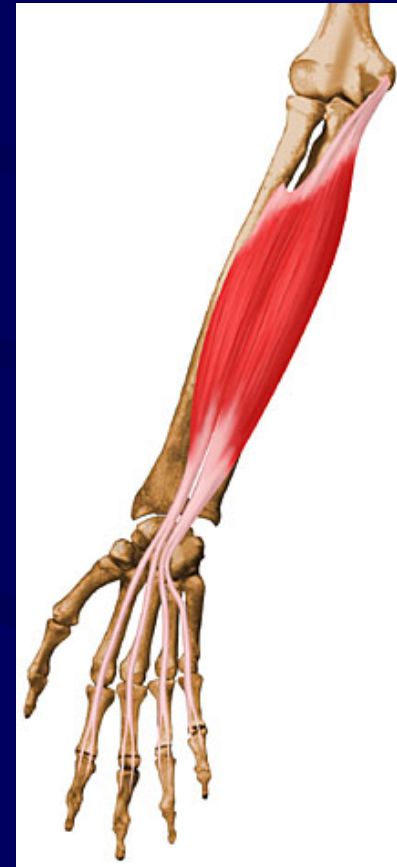
# Flexor Carpi Ulnaris

- Origin: common flexor tendon at medial epicondyle and proximal 2/3 of posterior ulnar border
- Insertion: pisiform, hamate and 5<sup>th</sup> metacarpal
- Innervation: ulnar
- Action: flexes and adducts/ulnar deviate the wrist



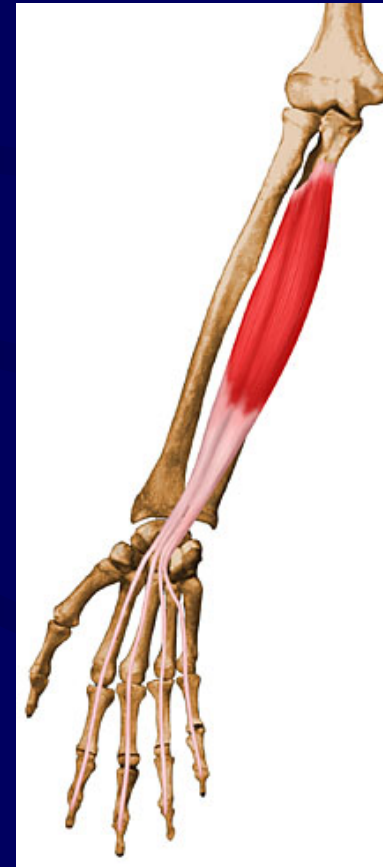
# Flexor Digitorum Superficialis

- Origin: common flexor tendon at medial epicondyle, medial aspect of coronoid process and oblique line of radius
- Insertion: sides of middle phalanges of 2<sup>nd</sup> – 5<sup>th</sup> digits
- Innervation: median nerve
- Action: flexes PIP joints, assists flexion of MCP and wrist joints



# Flexor Digitorum Profundus

- Origin: anteriomedial proximal ulna
- Insertion: bases of distal phalanges (anteriorly) of 2<sup>nd</sup>-5<sup>th</sup> digits
- Innervation: 1<sup>st</sup> and 2<sup>nd</sup> tendons by anterior interosseous nerve (median nerve), 3<sup>rd</sup> and 4<sup>th</sup> tendons by ulnar nerve
- Action: flexes DIP joints, assists in flexion of PIP and MCP joints



# Flexor Pollicis Longus

- Origin: anterior radius
- Insertion: palmar surface of base of distal phalanx of thumb
- Innervation: palmar interosseous nerve
- Action: flexion of 1<sup>st</sup> interphalangeal and metacarpophalangeal joints



# Pronator Quadratus

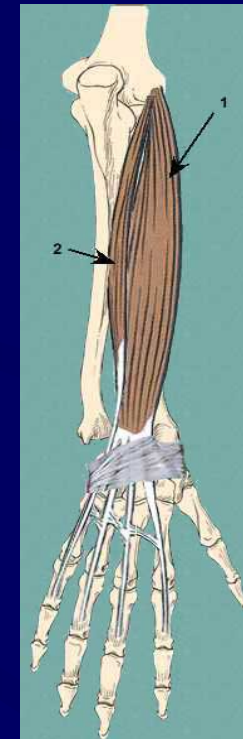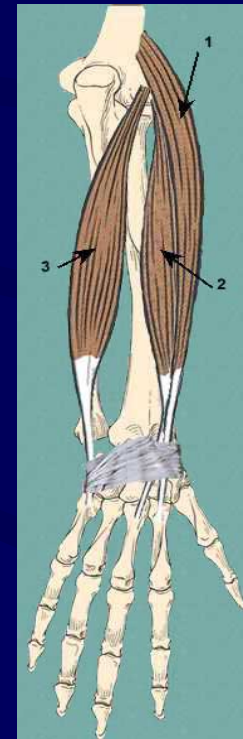
- Origin: anterior, distal ulna
- Insertion: lateral, distal radius
- Innervation: anterior interosseous nerve
- Action: forearm pronation





# Muscular Anatomy – Elbow Origin

- Extensor/supinator group
  - Brachioradialis
  - Extensor carpi radialis longus
  - Extensor carpi radialis brevis
  - Extensor carpi ulnaris
  - Extensor digitorum
  - Extensor digiti minimi
  - Supinator
  - Anconeus
  - Extensor indicis

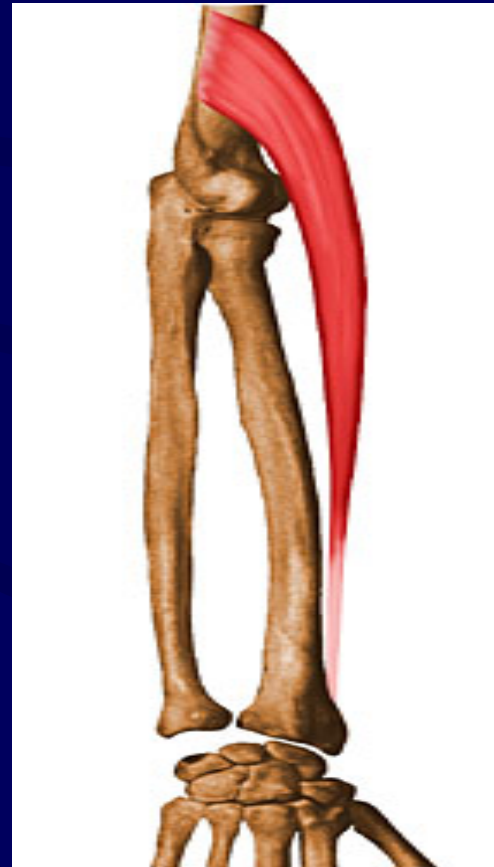

# Lateral Muscles

- Brachioradialis
- Extensor carpi radialis longus
- Extensor carpi radialis brevis

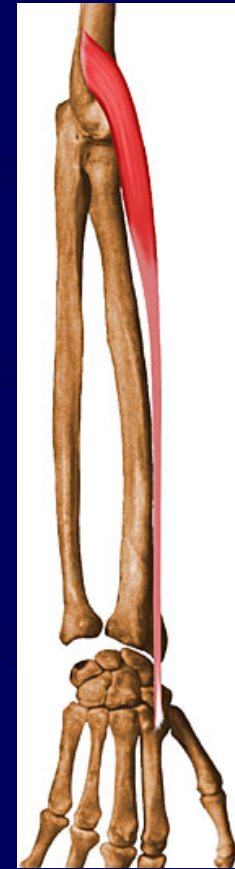
# Brachioradialis

- Brachioradialis
  - Origin: lateral supracondylar ridge of humerus
  - Insertion: lateral aspect of radial styloid process
  - Innervation: radial nerve
  - Action: elbow flexion, especially w/ forearm in neutral position



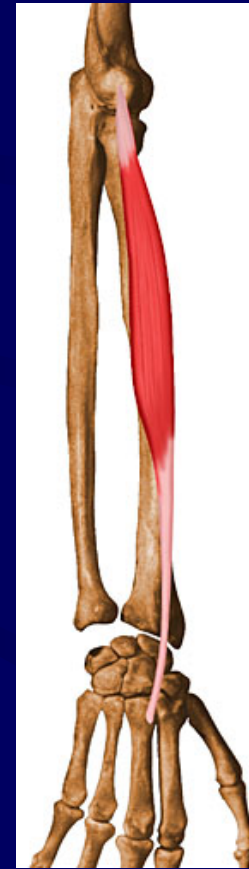# Extensor Carpi Radialis Longus

- Origin: lateral supracondylar ridge of humerus
- Insertion: dorsal base of 2<sup>nd</sup> metacarpal
- Innervation: radial nerve
- Action: extend and abduct/radial deviate the wrist



# Extensor Carpi Radialis Brevis

- Origin: common extensor tendon at lateral epicondyle
- Insertion: dorsal base of 3<sup>rd</sup> metacarpal
- Innervation: radial nerve
- Action: extend and abduct/radial deviate the wrist

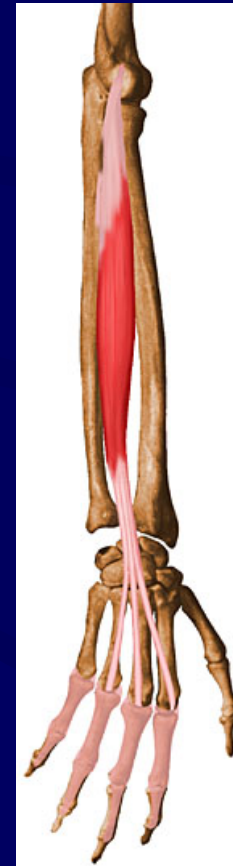


# Medial Muscles

- Extensor digitorum
- Extensor carpi ulnaris
- Extensor digiti minimi

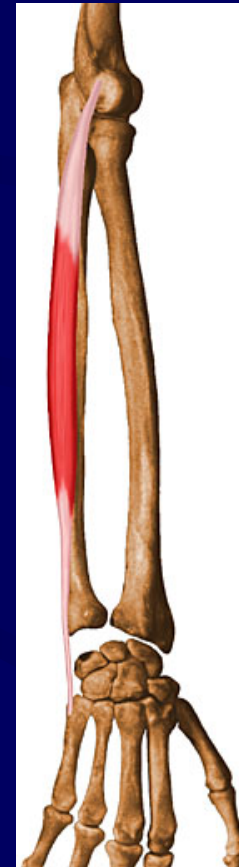# Extensor Digitorum

- Origin: common tendon from lateral epicondyle
- Insertion: bases of middle and distal phalanges via bands of 4 tendons
- Innervation: radial nerve
- Action: MCP/IP joint extension



# Extensor Carpi Ulnaris


- Origin: common extensor tendon at lateral epicondyle
- Insertion: ulnar side of base of 5<sup>th</sup> metacarpal
- Innervation: radial nerve
- Action: extend and adduct/ulnar deviate the wrist





# Extensor Digiti Minimi

- Origin:
- Insertion:
- Innervation:
- Action:



# “Outcropping” Muscles

- Abductor pollicis longus
- Extensor pollicis longus
- Extensor pollicis brevis

# Abductor Pollicis Longus

- Origin: posterior, distal radius and ulna
- Insertion: base of 1<sup>st</sup> metacarpal
- Innervation: median nerve
- Action: extension, abduction of 1<sup>st</sup> carpometacarpal joint



# Extensor Pollicis Longus/Brevis

- Origin: longus – posterior, middle ulna, brevis – posterior, distal radius
- Insertion: dorsal aspect of base of distal phalanx of thumb
- Innervation: deep radial nerve
- Action: extension of 1<sup>st</sup> carpometacarpal and metacarpophalangeal joints

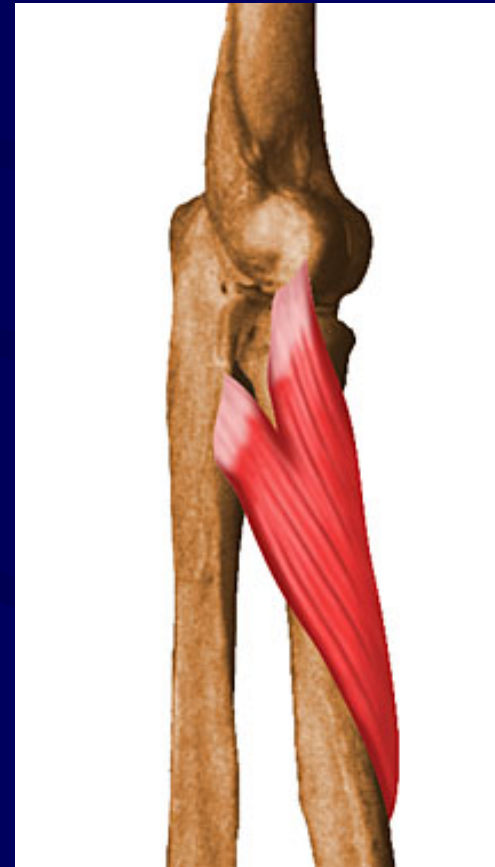

# “Accessory” Muscles

- Supinator
- Anconeus
- Extensor indicis

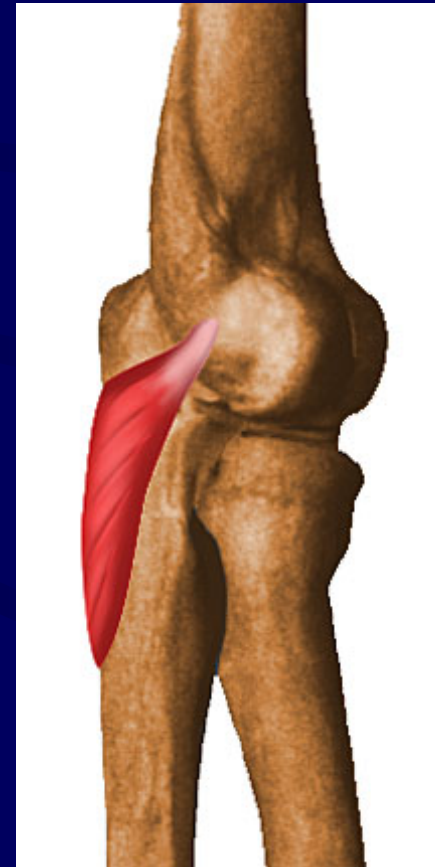
# Supinator

- Origin: lateral epicondyle, annular ligament/RCL and supinator crest of ulna
- Insertion: lateral proximal 1/3 of radius
- Innervation: posterior interosseous nerve (deep branch of radial nerve)
- Action: forearm supination




# Anconeus

- Anconeus
  - Origin: lateral epicondyle of humerus
  - Insertion: lateral aspect of olecranon and posterior ulna
  - Innervation: radial nerve
  - Action: assists elbow extension



# Extensor Indicis

- Origin:
- Insertion:
- Innervation:
- Action:





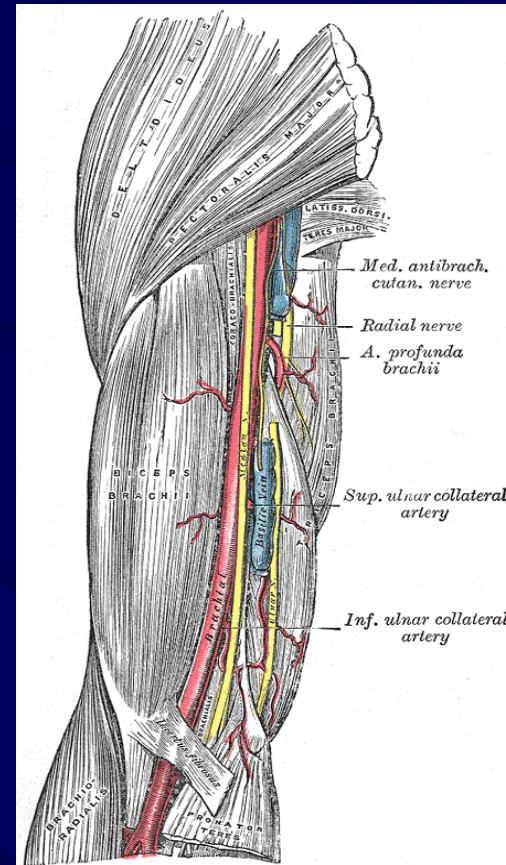
# Vascular Anatomy

# Vascular Structures

- Brachial artery
  - Radial artery
  - Ulnar artery
- 
- Elbow vascular anastamosis

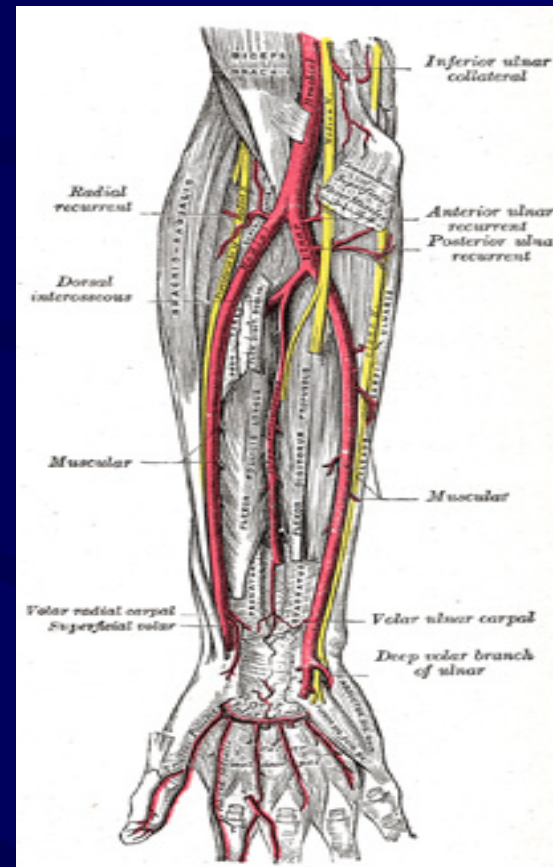
# Vascular Structures

- Brachial artery
  - Descends along arm along medial aspect of brachialis muscle
  - Enters antecubital fossa medial to biceps brachii tendon and lateral to median nerve
  - Terminates at radial head as radial/ulnar arteries



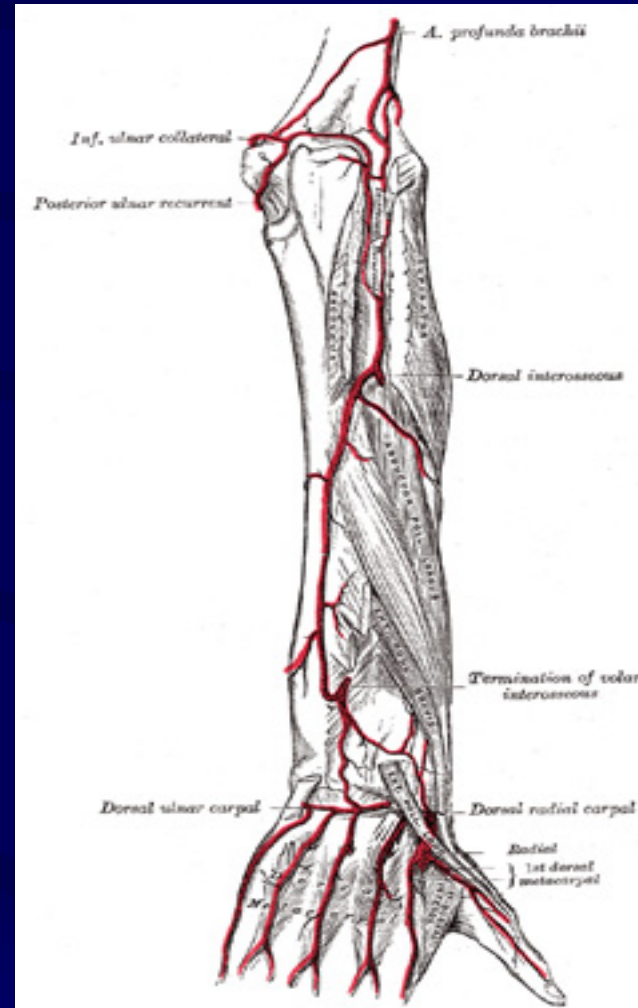
# Vascular Structures

- Radial artery
  - Originates at radial head, emerges from antecubital fossa between brachioradialis and pronator teres muscles
  - Continues laterally along forearm deep to brachioradialis muscle



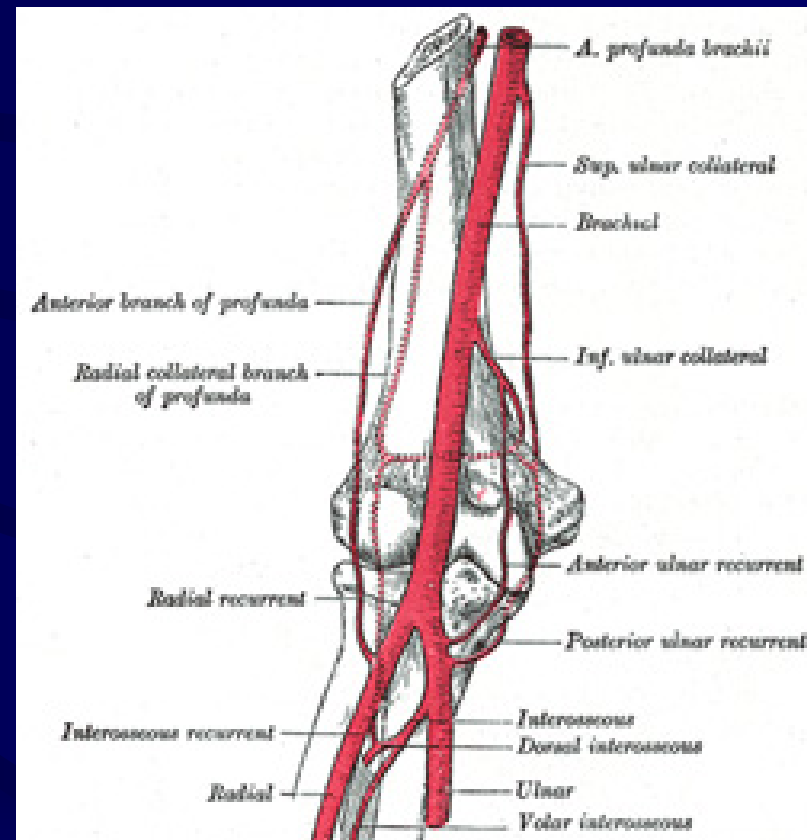
# Vascular Structures

- Ulnar artery
  - Originates at radial head, continues medially down forearm



# Elbow Vascular Anastamosis

- Laterally – profunda brachii artery meets radial recurrent artery
- Medially – inferior ulnar collateral artery meets anterior ulnar recurrent artery and superior ulnar collateral artery meets posterior ulnar recurrent artery



# Neurological Anatomy

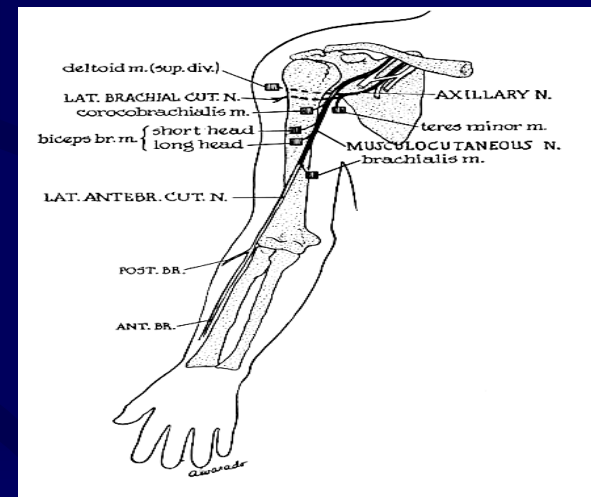
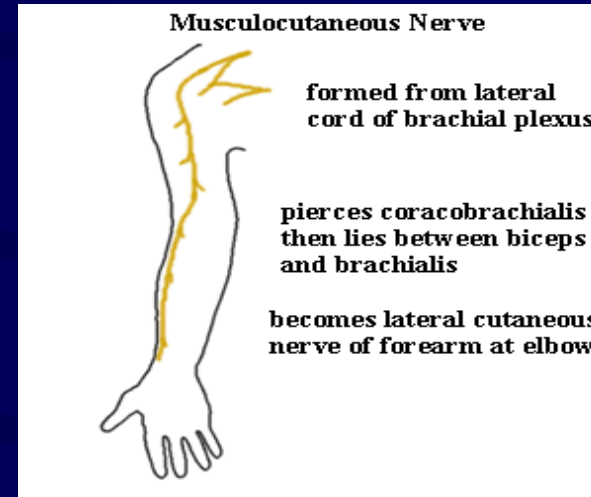
# Neurological Structures

- Terminal branches of brachial plexus
  - Axillary
  - Musculocutaneous
  - Median
  - Radial
  - Ulnar
- Anterior interosseous nerve
- Dermatomes and myotomes



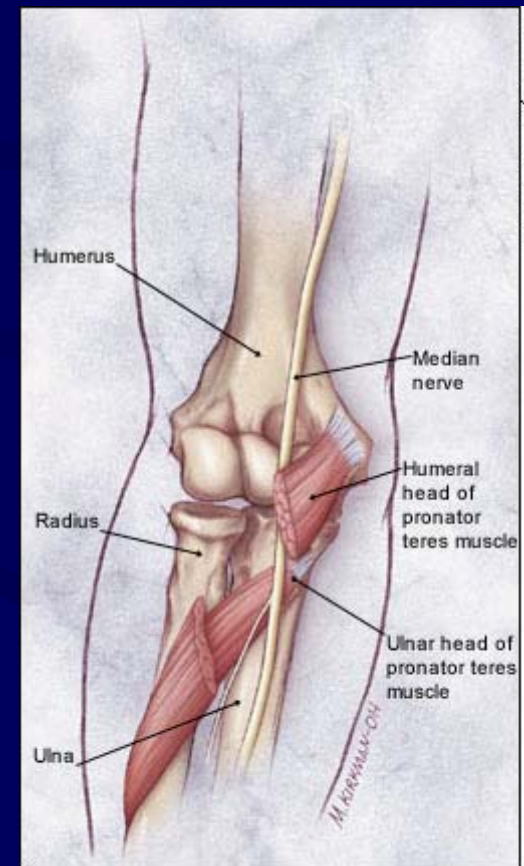
# Musculocutaneous/Axillary Nerves

- **Musculocutaneous nerve**
  - Innervates biceps brachii, coracobrachialis and brachialis muscles
  - Sensory distribution is anterior arm
- **Axillary nerve**
  - Innervates deltoid and teres minor muscles
  - Sensory distribution is lateral arm



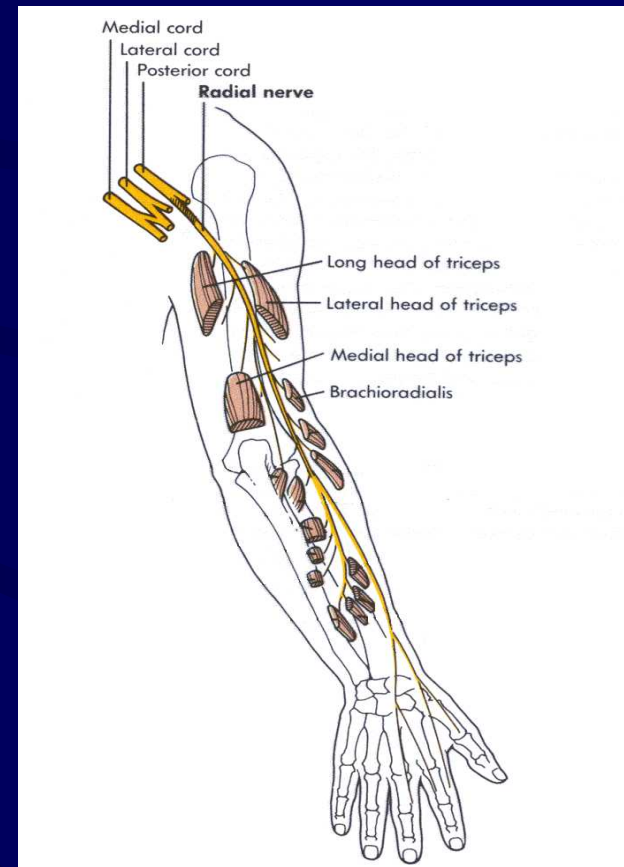
# Median Nerve

- Median nerve
  - Enters antecubital fossa medial to biceps brachii tendon and brachial artery
  - Courses down medial forearm to hand/wrist distribution
  - Sensory distribution is pad of index finger



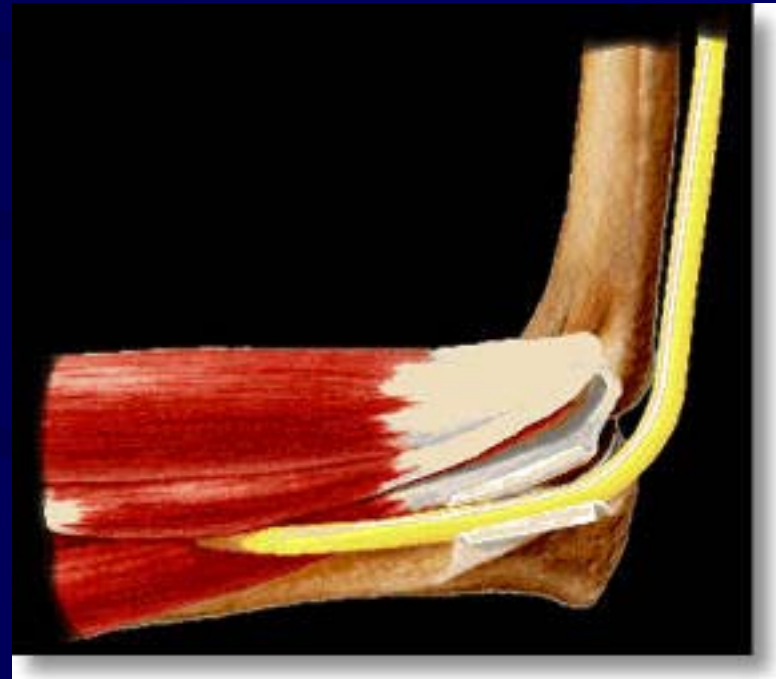
# Radial Nerve

- Radial nerve
  - Enters antecubital fossa posterior to brachialis muscle
  - Divides into superficial and deep (posterior interosseous) branches
  - Courses down lateral forearm to hand/wrist distribution
  - Sensory distribution is 1<sup>st</sup> dorsal webspace



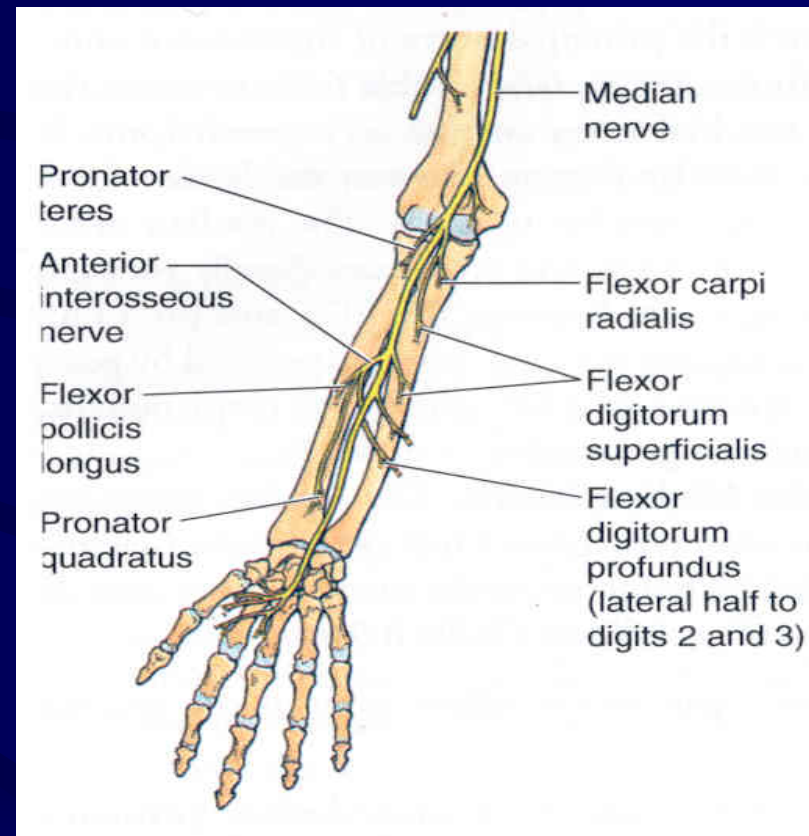
# Ulnar Nerve

- Ulnar nerve
  - Courses in cubital tunnel posterior to medial epicondyle
  - Superficial and susceptible to compression or entrapment
  - Courses down medial forearm to hand/wrist distribution
  - Sensory distribution is pad of little finger



# Anterior Interosseous Nerve

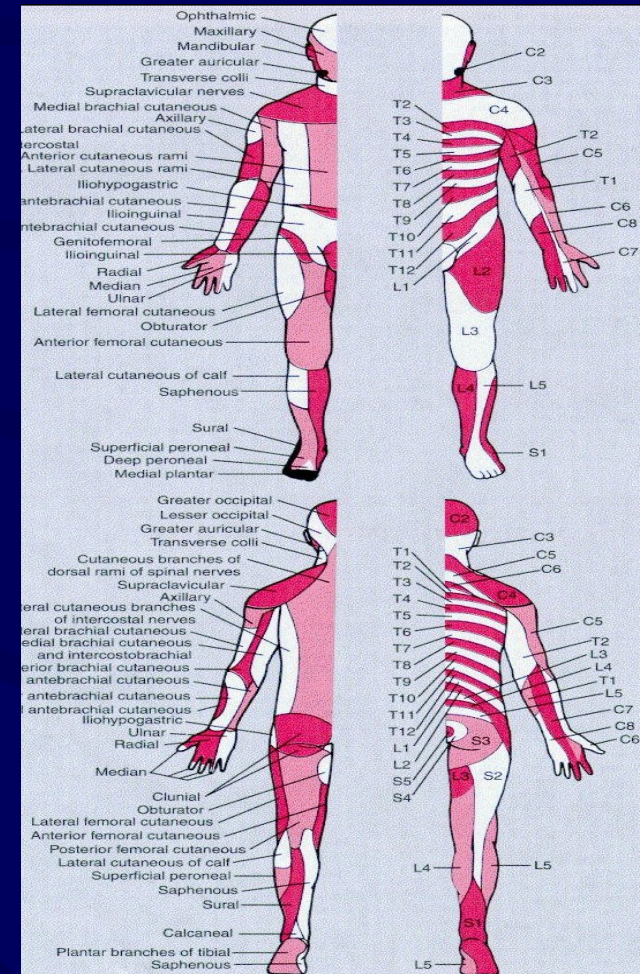
- Anterior interosseous nerve (branch of median nerve)
- Passes between 2 heads of pronator teres muscle, may be impinged upon
- Anterior interosseous nerve syndrome characterized by abnormal pinch deformity (inability to extend DIP of thumb and index finger)





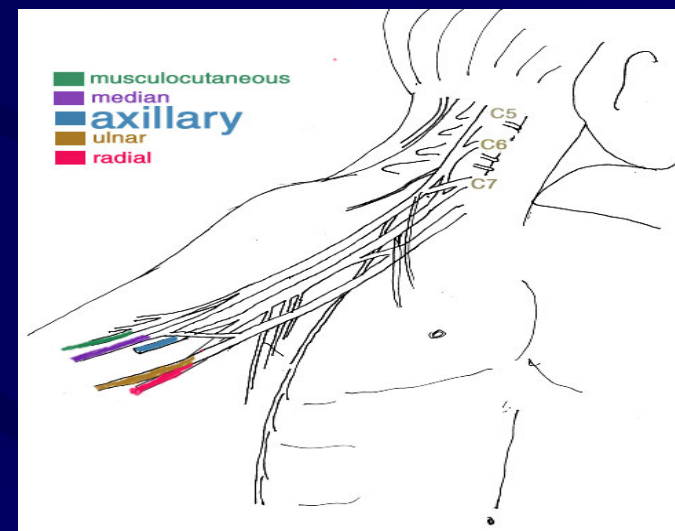
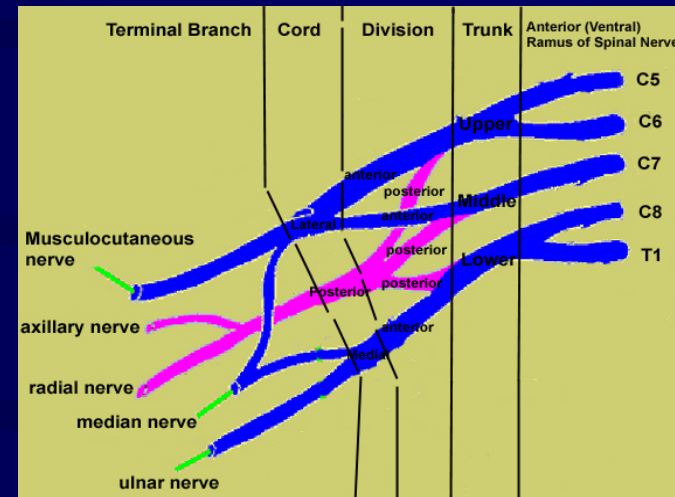
# Dermatomes

- C5 – lateral arm
- C6 – lateral forearm, thumb and index finger
- C7 – posterior forearm and middle finger
- C8 – medial forearm, ring and little fingers
- T1 – medial arm



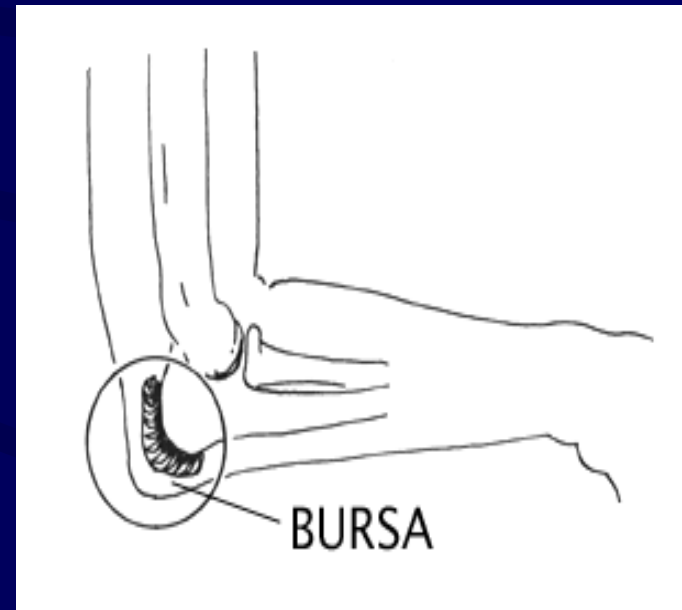
# Myotomes

- C5 – shoulder abduction
- C6 – elbow flexion, wrist extension
- C7 – elbow extension, wrist flexion
- C8 – finger flexion/grip strength
- T1 – finger abduction/adduction



# Olecranon Bursa

- Most frequently injured bursa in the elbow
- Lays between skin and olecranon process
- Allows unrestricted/fluid movement of skin over olecranon process





# Evaluation of Elbow and Forearm Injuries

# History

# History

- Location of symptoms
- Onset of symptoms
- Mechanism of injury (etiology)
- Unusual sounds/sensations
- Prior history of injury/general health
- Technique (associated with overuse injuries)

# Location of Symptoms

- Generally associated with tissue damaged
- Must be conscious of potential for referred pain secondary to cervical and/or shoulder pathologies

# Onset of Symptoms

- Acute injury typically associated with traumatic onset – specific mechanism
- Chronic injury typically associated with gradual onset of symptoms – insidious mechanism

# Mechanism of Injury (Etiology)

- Fall on outstretched arm
- Direct trauma or force application
- Repetitive stresses (throwing, hand/wrist movements)

# Unusual Sounds/Sensations

- Feeling of “giving way” of elbow with throwing motion
- “Pop” or “snap” often associated with ligament or tendon rupture
- Clicking/grating often associated with osteochondritis dissecans (“joint mice”)

# Prior History/General Health

- Must consider residual effects from previous injury on current symptoms
- Must consider neurovascular, inflammatory and systemic conditions/illnesses (ischemic contracture, neuropathy, arthritis, etc.)



# Technique

- Especially important for overhead activities and athletes
- Must consider changes in training
  - Duration
  - Intensity
  - Frequency
  - Biomechanics
  - Equipment

# Inspection

# Inspection

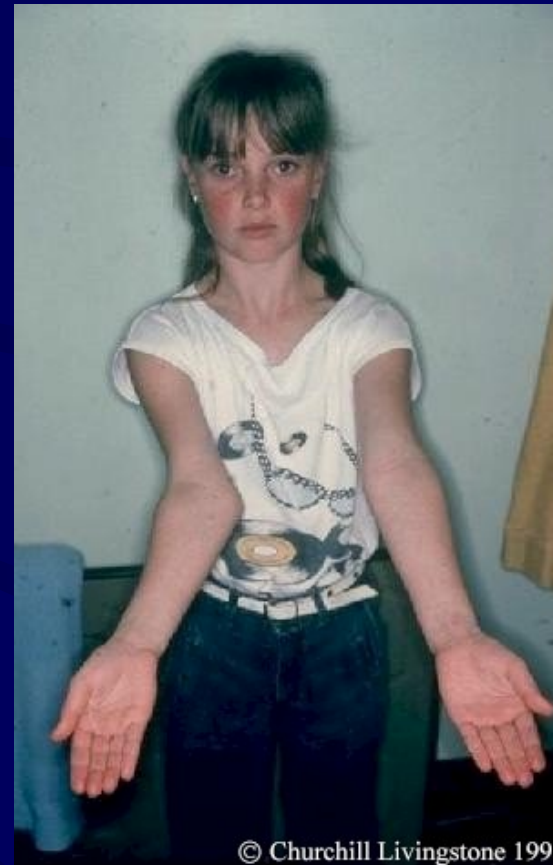- Anterior structures
- Medial structures
- Lateral structures
- Posterior structures

# Anterior Structures

- Carrying angle
  - Cubitus valgus (carrying angle)
  - Cubitus varus (gunstock deformity)
- Cubital fossa

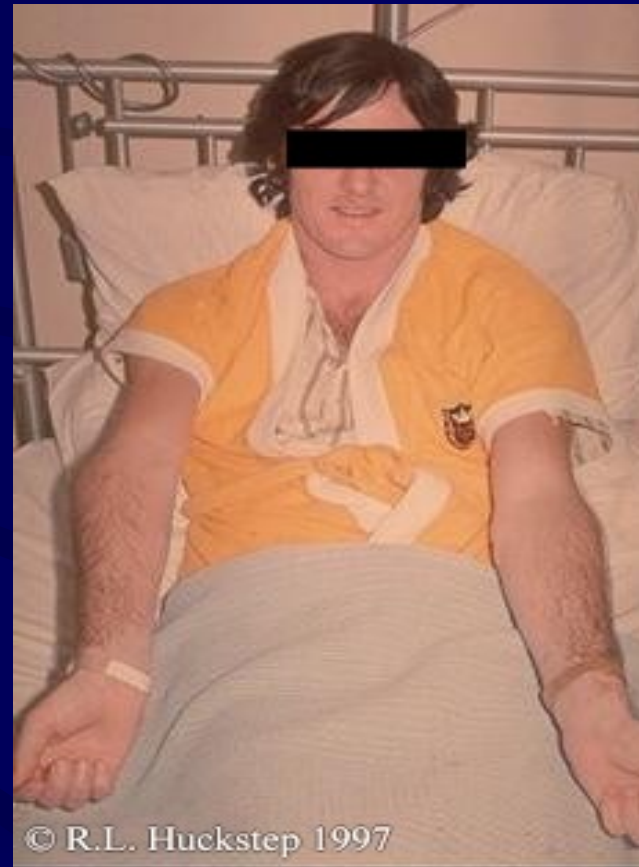# Carrying Angle/Cubitus Valgus

- Formed by long axis of humerus and midline of forearm
- Male norms – 11-14 degrees
- Female norms – 13-16 degrees
- Larger angles are considered abnormal



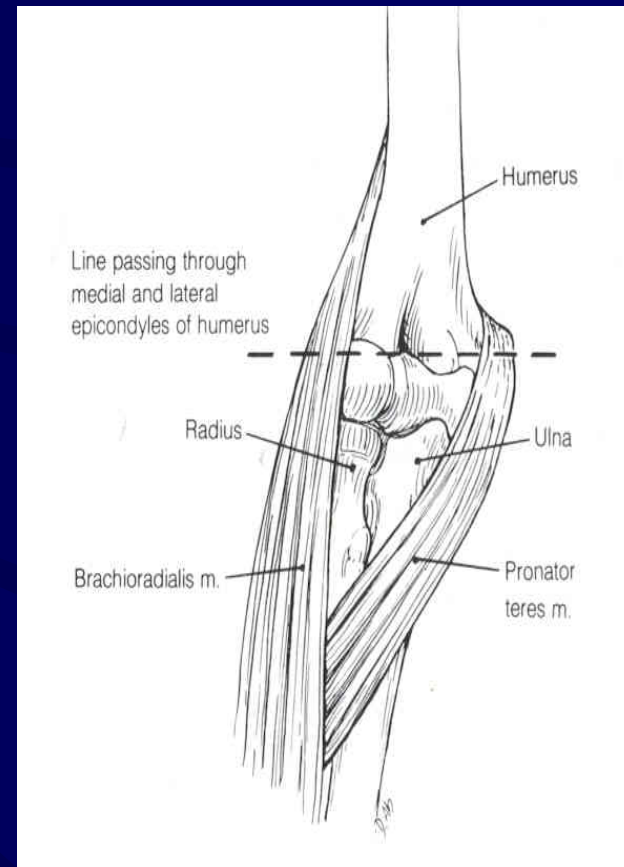
# Gunstock Deformity/Cubitus Varus

- Usually develops secondary to condylar humerus fracture



# Cubital Fossa

- Superior border – imaginary line between medial/lateral epicondyles
- Medial border – pronator teres muscle
- Lateral border – brachioradialis muscle
- Contents – brachial artery and median nerve



# Medial Structures

- Medial epicondyle
- Flexor/pronator group



# Lateral Structures

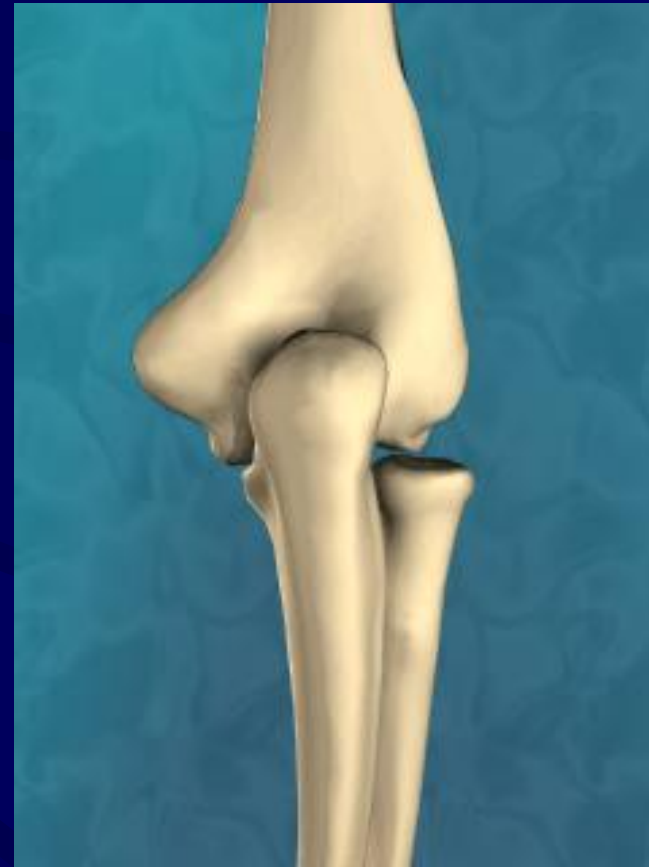- Wrist/forearm alignment
- Cubital recurvatum (hyperextension)
- Extensor/supinator group

# Posterior Structures

- Bony alignment
- Olecranon process/bursa

# Bony Alignment

- With elbow extended, straight line between medial/lateral epicondyles and tip of olecranon process'
- With elbow flexed, isosceles triangle connects these points



# Palpation

# Palpation – Anterior Structures

- Biceps brachii – tendon
- Cubital fossa
  - Borders, brachial artery
- Brachioradialis
  - Elbow flexion with thumb up
- Flexor-pronator group

# Palpation – Medial Structures

- Medial epicondyle
- Ulna (length of shaft)
- Medial (ulnar) collateral ligament
- Ulnar nerve (cubital tunnel posterior to medial epicondyle)

# Palpation – Lateral Structures

- Lateral epicondyle
- Radial head (forearm movement)
- Lateral (radial) collateral ligament
  - Between radial head and lateral epicondyle, difficult to isolate
- Capitellum (area at articulation with radius)
- Annular ligament (area)
- Lateral ulnar collateral ligament (difficult)

# Palpation – Posterior Structures

- Olecranon process
- Olecranon fossa
  - Elbow flexed and triceps relaxed
- Triceps brachii
- Anconeus
  - Between lateral epicondyle and olecranon process
- Extensor/supinator group



# Special Tests

# Special Tests

- Ranges of motion
- Neurological evaluation
- Vascular evaluation
- Ligamentous/capsular stress tests

# Range of Motion

- Flexion/extension – ginglymus joint (ulnohumeral articulation)
- Flexion typically 0-150 degrees, stops due to soft tissue approximation
- Extension typically 0-10 degrees (hyperextension, especially in females), stops due to bony opposition

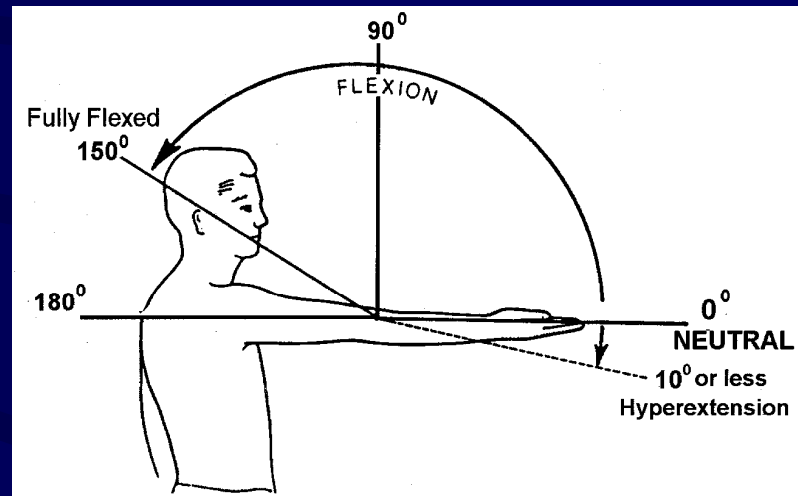
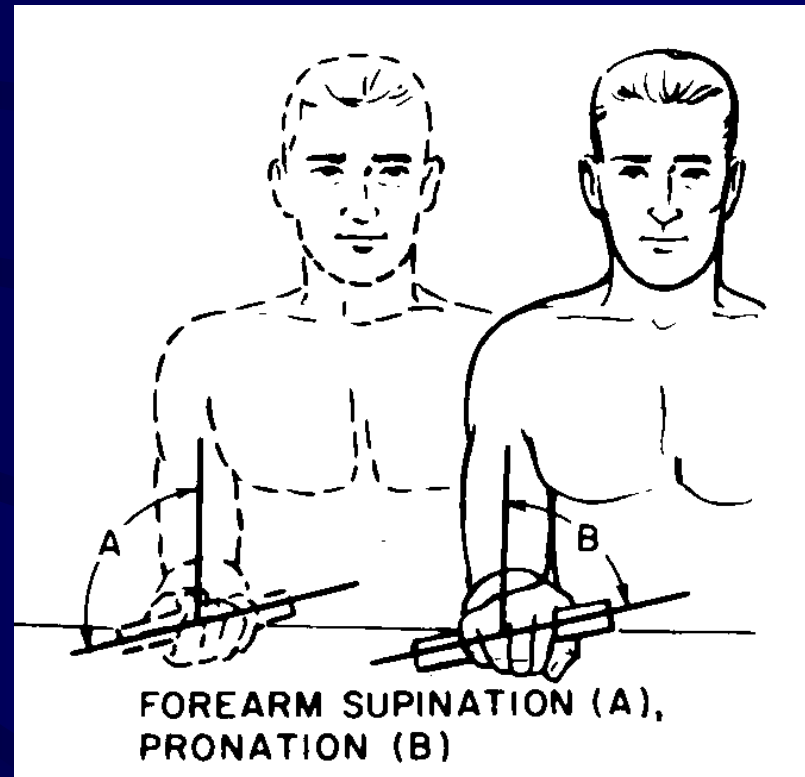


Figure 3. Range of motion at elbow joint  
(Source: American Academy of Orthopaedic Surgeons)

# Range of Motion

- Forearm pronation and supination – trochoid joint (radiohumeral and proximal radioulnar articulations)
- Pronation/supination typical 0-85/90 degrees each from neutral point (thumb up), stops due to tissue tensions/stretch from opposing tissue
- Elbow ROM has 2 degrees of freedom



# Range of Motion

- Elbow motion/s serve to adjust height and length of limb to reach any point within sphere of shoulder motion and also to rotate forearm to place hand in the most effective operating position

# Neurovascular Evaluation

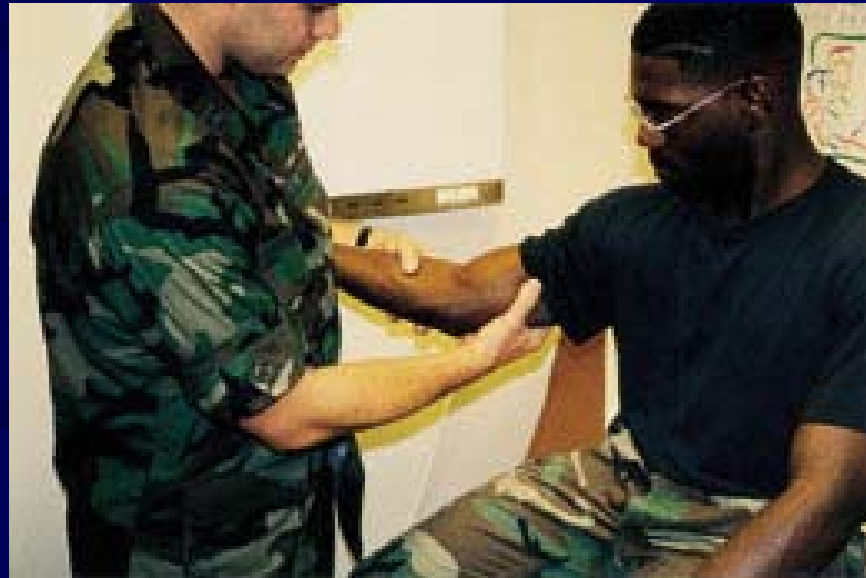- Brachial plexus dermatomes/myotomes
- Peripheral nerve sensory and motor function
- Pulse points
  - Brachial artery
  - Radial artery
- Capillary refill
- Skin color/temperature

# Ligamentous Stress Tests

- Valgus stress test
  - Assesses medial (ulnar) collateral ligament (anterior bundle)
- Varus stress test
  - Assesses lateral (radial) collateral ligament and annular ligament

# Valgus Stress Test

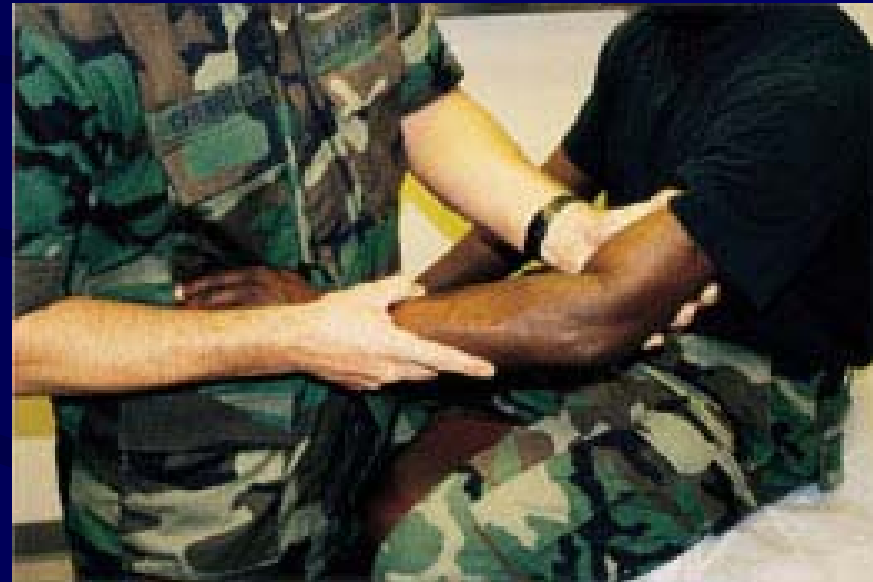- Performed in 25-30 degrees of elbow flexion





# Varus Stress Test

- Performed in 25-30 degrees of elbow flexion



# Elbow Kinematics

- One of the most congruous and stable joints
- In extension, anterior capsule provides most restraint, while MCL becomes primary stabilizer at 90 degrees flexion
- Valgus stress in extension equally resisted by bone structure (proximal  $\frac{1}{2}$  of semilunar notch), MCL and medial joint capsule – in flexion, resisted primarily by MCL (anterior bundle)
- Varus stress in extension resisted by bone structure (distal  $\frac{1}{2}$  of coronoid process), LCL and lateral joint capsule – in flexion, resisted primarily by bone structure

# Elbow Biomechanics – Injury Contribution and Rehab Considerations

- Significant valgus torques present during arm cocking phase of throwing (medial distraction and lateral compression)
  - UCL is static stabilizer and flexor/pronators, triceps and anconeus are dynamic stabilizers to valgus loads
- Rapid extension velocity during acceleration phase of throwing (low biceps activity and high centrifugal forces from trunk)
  - High distraction forces at elbow during extension countered by muscular activity
- Large deceleration forces through elbow flexors during deceleration phase of throwing
  - High distraction forces countered by ligamentous stabilization and muscular activity